

# Technical evaluation of Exoseal-Cordis® vascular closure device

## *Avaliação técnica do dispositivo de fechamento vascular Exoseal-Cordis®*

Altino Ono Moraes<sup>1</sup>, Rogério Yoshikazu Nabeshima<sup>2</sup>, Ericsson Fernando Viotto<sup>1</sup>, Marcelo Hiroshi Estevam Yoshida<sup>3</sup>, Jihad Mohamad Mansour Abdallah<sup>2</sup>, Patrícia Gaio<sup>2</sup>

### Abstract

**Background:** Vascular closure devices (VCD) make it possible to rapidly remove the introducer sheath from an arterial access, thereby reducing the length of time in hemostasis, the time patients are restricted to their beds, and the number of puncture site complications. **Objectives:** To evaluate the efficacy and possible complications associated with use of an arterial occlusion device compared with manual compression. **Methods:** This was a prospective, randomized, longitudinal study of 20 patients conducted from December 2014 to July 2015 in Maringá, PR, Brazil. They were divided into two groups: those who were treated using a VCD (VCD group) and those for whom only manual compression was used (MC group). Doppler ultrasound examination was used to determine skin-artery depth before and after the procedure and the length of time compression was maintained and the delay before mobilization were also recorded. Data were analyzed using the program Statistical Analysis Software. **Results:** A total of 60% of the patients were male and the mean age of both groups was approximately 60 years. There was no difference in skin-artery depth between the groups. The duration of compression in the VCD group was 2 minutes and in the MC group it was  $21 \pm 2.11$  minutes ( $p = 0.0005$ ), while the delay before return to mobility of the lower limb that had been punctured was  $2.35 \pm 0.75$  hours in the VCD group and 6 hours in the MC group ( $p = 0.0005$ ). There were no complications. **Conclusions:** In this study, hemostasis by manual compression exhibited equal efficacy to use of a VCD, but the duration of compression and delay before resumption of activity were shorter in the patients for whom the device was employed.

**Keywords:** vascular closure device; duration of hemostasis; manual compression.

### Resumo

**Contexto:** Os dispositivos de oclusão vascular (DOV) permitem rápida remoção da bainha introdutora de um acesso arterial, reduzindo o tempo de hemostasia, a restrição do paciente ao leito e as complicações no sítio de punção. **Objetivos:** Avaliar a eficácia e possíveis complicações do uso de dispositivo de oclusão arterial comparado com a compressão manual. **Métodos:** Estudo longitudinal prospectivo randomizado com 20 pacientes no período de dezembro de 2014 a julho de 2015 em Maringá (PR). Foram divididos em dois grupos: aqueles que utilizaram DOV (grupo DOV) e aqueles submetido apenas a compressão manual (grupo CM). Realizaram-se exames de ultrassom Doppler para avaliar a espessura pele-artéria pré e pós-procedimento e verificou-se o tempo de compressão e de deambulação. Os dados foram analisados pelo Programa Statistical Analysis Software. **Resultados:** Um total de 60% dos pacientes eram do sexo masculino e a média de idade de ambos os grupos foi de aproximadamente 60 anos. Não houve diferença na espessura pele-artéria entre os grupos. O tempo de compressão no grupo DOV foi de 2 minutos e no grupo CM foi de  $21 \pm 2,11$  minutos ( $p = 0,0005$ ), e o tempo para retorno de movimentos no membro inferior puncionado foi de  $2,35 \pm 0,75$  horas no grupo DOV e de 6 horas no grupo CM ( $p = 0,0005$ ). Não houve complicações. **Conclusões:** Neste estudo a hemostasia por compressão manual foi tão efetiva quanto o uso de DOV, embora o tempo de compressão e o tempo para retorno às atividades sejam menores nos pacientes submetidos ao uso do dispositivo.

**Palavras-chave:** dispositivo de oclusão vascular; tempo de hemostasia; compressão manual.

<sup>1</sup>Instituto de Moléstias Vasculares, Departamento de Cirurgia Vascular, Maringá, PR, Brazil.

<sup>2</sup>Hospital Santa Rita, Departamento de Cirurgia Vascular, Maringá, PR, Brazil.

<sup>3</sup>Hospital Santa Casa de Cianorte, Departamento de Cirurgia Vascular, Cianorte, PR, Brazil.

Financial support: None.

Conflicts of interest: No conflicts of interest declared concerning the publication of this article.

Submitted: February 19, 2017. Accepted: April 04, 2017.

The study was carried out at Hospital Santa Rita and Hospital Maringá, Maringá, PR, Brazil.

## INTRODUCTION

Vascular closure devices (VCD) were developed to allow rapid removal of the introducer sheath from an arterial access after endovascular procedures, reducing the duration of hemostasis and reducing the length of time that the patient is restricted to the bed and, theoretically, reducing the rate of complications at the puncture site. Its limited use is a response to the increases in the cost of the procedure with which its use is associated and the lack of data demonstrating a significant reduction in vascular complications compared with manual compression.<sup>1</sup>

There are two categories of occluders: the first are known as passive devices and this class includes external prothrombin patches and mechanical compression assistance and does not offer immediate hemostasis (in less than 5 minutes); and the second group comprises active methods, in which hemostasis is achieved with some type of substance or with sutures, offering immediate hemostasis.<sup>2</sup>

ExoSeal<sup>®</sup> is an active arterial occlusion device that employs a polyglycolic acid plug released in an extravascular position after puncture of the femoral artery, offering hemostasis with shorter duration of compression and enabling early mobilization, 2 hours after completion of the procedure.<sup>2,3</sup>

The objective of this study is to compare the efficacy and safety of the Exoseal<sup>®</sup> Cordis device compared with manual compression.

## METHODS

The study sample comprises 20 patients who underwent diagnostic or therapeutic endovascular surgery procedures between December 2014 and July 2015 at two hospitals (Hospital Santa Rita and Hospital Maringá), both located in Maringá, PR, Brazil. These patients were randomized into one of two groups: patients treated using the ExoSeal<sup>®</sup> Cordis VCD (VCD group) and patients who were treated with manual compression alone (MC group). This is a prospective, randomized, longitudinal study.

The device is easy to use, starting by inserting it into the introducer with its indicator window upwards so it is easily viewed by the surgeon. The device is advanced until its ring meets the hemostatic valve of the introducer, when there is an audible “click” and correct coupling is confirmed by pulsing bleed-back via the side. The device and sheath are withdrawn together at an angle of 30-45° until bleed back stops and the indicator window changes from black-white to black-black, indicating that the plug is in the correct position for release. At this point the plug is released

and the pair (introducer + ExoSeal<sup>®</sup>) of devices are removed together, exerting mild compression on the puncture site, and then a dressing is applied according to the routine protocol used at the service<sup>2,3</sup> (Figures 1, 2, and 3).

A questionnaire was administered to the patients and they were examined using Doppler arterial ultrasonography before and after the procedure to determine the thickness of the subcutaneous tissue between the skin and the artery (termed “skin-artery depth” for the purposes of this study) and to detect any possible complications. The duration of compression after the procedure and the interval of time before the punctured lower limb was mobilized once more were both recorded.

For patients treated using the VCD, after the procedure was complete and the introducer + ExoSeal<sup>®</sup> pair had been removed, compression was applied over the puncture site for 2 minutes, in accordance with the product’s specifications. For patients in the

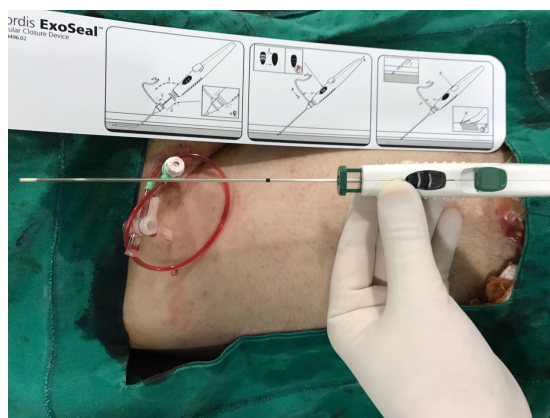


Figure 1. Vascular closure device.

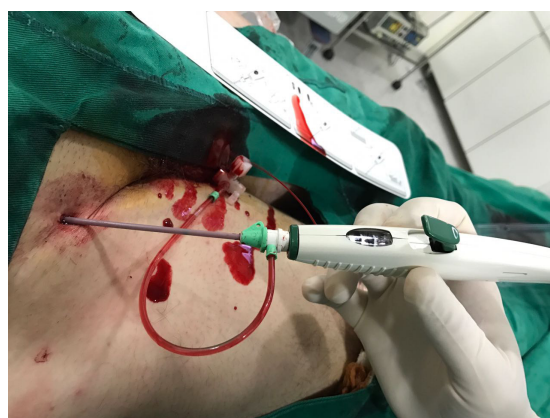

Figure 2. Insertion of device in the introducer.

manual compression group, compression was applied with both hands over the puncture site for 20 minutes. Patients who did not exhibit hemostasis after these measures were subjected to mechanical compression for an additional period, depending on the magnitude of the bleeding observed. The interval until mobilization was measured from the time at which hemostasis was achieved. It was observed that some patients who had been given spinal/peridural anesthetic blockade exhibited a longer duration interval before recovering movement, depending on each type of anesthesia. The technical specifications for the device mention a 2-hour interval for mobilization, while the routine at our service is to allow 6 hours for patients treated using manual compression.

After the procedure, patients who had undergone diagnostic examinations were not given medications that could interfere with coagulation mechanisms. However, patients who had undergone angioplasty were treated with double platelet antiaggregation with 200 mg of aspirin and 150 mg of clopidogrel during the immediate postoperative period.

Only patients over the age of 18 who underwent retrograde puncture of the femoral artery using sheath sizes 5Fr to 7Fr and who agreed to take part, signing a free and informed consent form were enrolled on

the study. Patients were excluded from the study if the arteries punctured were highly calcified, because this is one of the contraindications for VCD.

To test the difference between skin-artery depth before and after the procedure and with and without the device, the Shapiro-Wilk and Wilcoxon tests were used to determine homogeneity of groups. Statistical significance was set at a 95% confidence level ( $\alpha = 0.05$ ), i.e. *p*-values less than 0.05. Data were analyzed using the program Statistical Analysis Software (SAS, version 9.0) and compiled in a database constructed using Excel.<sup>4</sup>

## RESULTS

The sample comprised eight (40%) female patients and 12 (60%) male patients and mean age was similar in both groups: 60.8±14.5 years in the VCD group and 63.9±16.8 years in the MC group. Six (30%) procedures were for diagnostic examinations and 14 (70%) procedures were for treatment, and the mean duration of procedures was 72.0±39.1 minutes for the VCD group and 81.0±73.6 minutes for the MC group. There were no failures or complications in either of the groups studied. The variables for risk factors in the sample of patients are listed in Table 1.

In order to test for differences in skin-artery depth before and after the procedure and with and without the device, the Shapiro-Wilk test was used to verify the normality of the variable “skin-artery depth” before the surgical procedure (Table 2). Data were only normally distributed for the group in which the device was not used: depth before ( $p=0.0200$ ) and depth after ( $p=0.0407$ ). In the group in which the device was used, data were not normal: depth before ( $p=0.9017$ ) and depth after ( $p=0.3392$ ). In view of this, the results for both groups were compared using the Wilcoxon test (Table 3) to determine whether there were significant difference between baseline thickness (before the procedure) for patients allocated to each group (with and without device). The objective of this test was to test whether the sample of patients was

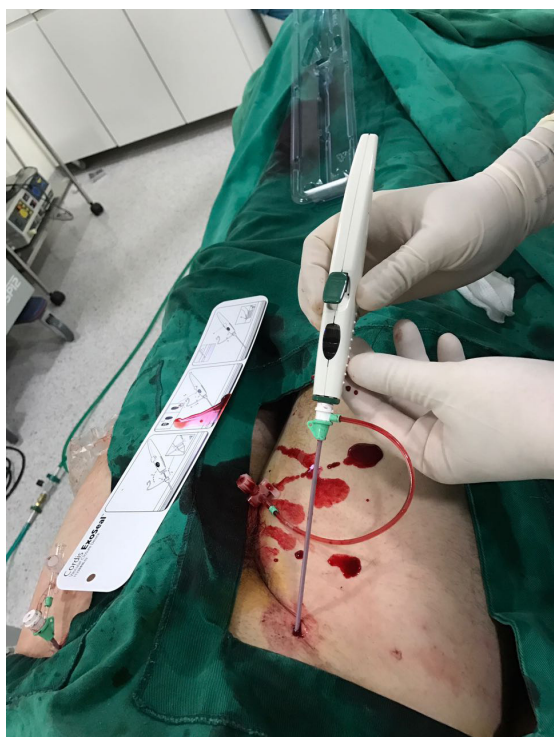

Figure 3. Proper positioning of the device.

Table 1. Frequency distributions of associated risk factors.

|   | Yes      | No       |
|---|----------|----------|
| Arterial hypertension                             | 13 (65%) | 7 (35%)  |
| Diabetes mellitus                                 | 9 (45%)  | 11 (55%) |
| Dyslipidemia                                      | 8 (40%)  | 12 (60%) |
| Smoking   | 12 (60%) | 8 (40%)  |
| Obesity   | 5 (25%)  | 15 (75%) |
| Myocardial revascularization/coronary angioplasty | 2 (10%)  | 18 (90%) |
| Stroke/transitory ischemic attack                 | 3 (15%)  | 17 (85%) |

**Table 2.** Test of normality for the variable skin-artery depth before and after the surgical procedure for groups treated with and without the device.

| Depth              | Without device |        | With device |        |
|--------------------|----------------|--------|-------------|--------|
|                    | Before         | After  | Before      | After  |
| Mean               | 2.0830         | 2.3820 | 1.9000      | 2.258  |
| Standard deviation | 0.3848         | 0.3428 | 0.5375      | 0.6689 |
| Shapiro-Wilk       | 0.8115         | 0.8371 | 0.9712      | 0.9178 |
| p-value            | 0.0200         | 0.0407 | 0.9017      | 0.3392 |

**Table 3.** Wilcoxon test, to analyze difference in skin-artery depth before surgical procedure between groups with and without device.

| Device? | Mean score | W      | Approximation (Z) | p-value |
|---------|------------|--------|-------------------|---------|
| No      | 11.60      |        |                   |         |
| Yes     | 9.40       | 116.00 | 0.7952            | 0.4265  |

**Table 4.** Wilcoxon test, to analyze difference in skin-artery depth after surgical procedure between groups with and without device.

| Device? | Mean score | W     | Approximation (Z) | p-value |
|---------|------------|-------|-------------------|---------|
| No      | 9.50       |       |                   |         |
| Yes     | 11.50      | 95.00 | -0.7189           | 0.4809  |

homogeneous in terms of the variable “skin-artery depth” before the surgical procedure. No significant difference was observed ( $p = 0.4265$ ) and the sample was therefore considered homogeneous. The last step in this analysis was to determine whether there was a significant difference between groups in patients’ skin-artery depth after the surgical procedure. No difference between the groups was observed ( $p = 0.4809$ ) as shown in Table 4.

With relation to duration of compression after the procedure, i.e., soon after removal of the introducer, all patients in the VCD group exhibited adequate hemostasis after 2 minutes of compression, while duration of compression in the MC group was  $21 \pm 2.11$  minutes ( $p = 0.0005$ ). With regard to the time taken to mobilize the punctured lower limb, the VCD group took  $2.35 \pm 0.75$  hours, while the MC group had an interval of 6 hours ( $p = 0.0005$ ), showing that patients with whom the device was used required the professional applying compression to spend less time doing so and were able to resume basic activities more quickly.

There were no complications in any of the patients who took part in this study.

## DISCUSSION

ExoSeal® is an active percutaneous mechanical device for arterial occlusion that employs a bioabsorbable polyglycolic acid plug that is placed

in an extravascular position. The device is indicated for retrograde punctures of the common femoral artery for which 5Fr to 7Fr introducers are used, reducing the time taken to achieve hemostasis and enabling early mobilization (after 2 hours). ExoSeal® is contraindicated in highly calcified arteries, arteries with diameters of less than 5 mm, and in patients with an allergy to polyglycolic acid. Complications may occur, but are limited to the puncture site, and include hematoma, bleeding, and others.<sup>5</sup>

We were unable to find studies in the literature that compared the distance from the skin to the artery punctured. Perhaps this is not mentioned in studies because it does not necessarily have any influence on complications such as fistulas, pseudoaneurysms, major bleeding, or hematoma, among others. In our study, we did not observe any statistical difference in this measurement after puncture between patients with whom the VCD had or had not been used.

With relation to the reduction in recovery time and increased comfort for patients undergoing endovascular procedures, there is no doubt about the benefits for patients with whom a VCD is used.<sup>6-10</sup> Our study confirms already-published data, demonstrating that there was an important difference both in terms of shorter duration of compression exerted by the professional over the puncture site and in terms of shorter time before mobilization.

However, the advantages in terms of efficacy, safety, and cost that would justify use of the device in a more deliberate manner have not yet been established. The efficacy, or success rate, i.e. the percentage of patients for whom complete hemostasis is achieved with just one device, varies from 87% to 96% and does not differ significantly from the results for manual compression.<sup>11</sup> In our study, there were no failures in the group in which the device was used, which can be explained by the small sample size.

The incidence of complications after endovascular procedures is highly variable, because of the diversity of definitions used in studies and the countless factors that contribute to their occurrence (aspects inherent to the patients, precautions related to the puncture

technique, size and duration of placement of the introducer sheath, and others).<sup>12-15</sup> This wide range of variations leads to studies reporting conflicting results that range from protective effects to an increased risk of complications.<sup>16-18</sup>

Another controversial subject is the financial impact. Some authors have demonstrated cost reductions from a shorter hospital stay after the procedure and reduced expenditure on the personnel required to provide compression.<sup>19,20</sup> Other studies have shown that this advantage is wiped out by the high cost of the VCD itself.<sup>21</sup> Analyzing this debate in our setting (in Brazil), Gioppato et al. conducted a study that investigated the total cost, summing the amounts spent on treatment of complications (pseudoaneurysms treated with Doppler-guided thrombin injections) that only occurred in the group treated using manual compression.<sup>11</sup> The authors came to the conclusion that, despite the per-individual cost of treatment of complications related to hemostasis by compression being considerably higher, when costs were analyzed by group, the total cost for the VCD group was significantly greater than the cost for the group subjected to manual compression.<sup>11</sup>

## CONCLUSIONS

The results observed in this study allow for the conclusion that the technique of achieving hemostasis by manual compression, when correctly carried out, is equally effective as achieving hemostasis with a VCD. Notwithstanding, duration of compression exerted by the health professional and the time taken to recover mobility were both longer in the group treated using manual compression.

## REFERENCES

- Dauerman HL, Applegate RJ, Cohen DJ. Vascular closure devices: the second decade. *J Am Coll Cardiol*. 2007;50(17):1617-26. PMID:17950141. <http://dx.doi.org/10.1016/j.jacc.2007.07.028>.
- Lobato AC. *Cirurgia endovascular*. 3rd ed. São Paulo: ICVE; 2015.
- Exoseal® Vascular Closure Device. *Angio-Seal evolution instructions for use*. St. Paul, Minnesota: St. Jude Medical.
- Stokes ME, Davis CS, Koch GG. *Categorical data analysis using SAS system*. 2nd ed. Cary: Statistical Analysis System Institute; 2000.
- Wong SC, Bachinsky W, Cambier P, et al. A randomized comparison of a novel bioabsorbable vascular closure device versus manual compression in the achievement of hemostasis after percutaneous femoral procedures: the ECLIPSE (Ensure's Vascular Closure Device Speeds Hemostasis Trial). *J Am Coll Cardiol Interv*. 2009;2(8):785-93. PMID:19695549. <http://dx.doi.org/10.1016/j.jcin.2009.06.006>.
- Cox T, Blair L, Huntington C, Lincourt A, Sing R, Heniford BT. Systematic review of randomized controlled trials comparing manual compression to vascular closure devices for diagnostic and therapeutic arterial procedures. *Surg Technol Int*. 2015;27:32-44. PMID:26680377.
- Brito FS Jr, Magalhães MA, Nascimento TCDC, et al. Incidência e preditores contemporâneos de complicações vasculares após intervenção coronária percutânea. *Rev Bras Cardiol Invasiva*. 2007;15(4):394-9. <http://dx.doi.org/10.1590/S2179-83972007000400014>.
- Duffin DC, Muhlestein JB, Allison SB, et al. Femoral arterial puncture management after percutaneous coronary procedures: a comparison of clinical outcomes and patient satisfaction between manual compression and two different vascular closure devices. *J Invasive Cardiol*. 2001;13(5):354-62. PMID:11385148.
- Legrand V, Doneux P, Martinez C, Gach O, Bellekens M. Femoral access management: comparison between two different vascular closure devices after percutaneous coronary intervention. *Acta Cardiol*. 2005;60(5):482-8. PMID:16261778. <http://dx.doi.org/10.2143/AC.60.5.2004968>.
- Martin JL, Pratsos A, Magargee E, et al. A randomized trial comparing compression, Perclose Proglide and Angio-Seal VIP for arterial closure following percutaneous coronary intervention: the CAP trial. *Catheter Cardiovasc Interv*. 2008;71(1):1-5. PMID:18098171. <http://dx.doi.org/10.1002/ccd.21333>.
- Gioppato S, Castello HJ Jr, Conforti TB, Gonçalves SLP, Morais FGS, Cantarelli MJC. Análise da relação custo-efetividade do dispositivo de oclusão vascular AngioSeal™ comparado à compressão manual e/ou mecânica após intervenções endovasculares. *Rev Bras Cardiol Invasiva*. 2011;19(2):189-93. <http://dx.doi.org/10.1590/S2179-83972011000200015>.
- Zukowski CN, Costa RJ Jr, Costa R, et al. Preditores e impacto clínico intra-hospitalar do sangramento associado à intervenção coronária percutânea. *Rev Bras Cardiol Invasiva*. 2010;18(3):281-7. <http://dx.doi.org/10.1590/S2179-83972010000300009>.
- Bogart DB, Bogart MA, Miller JT, Farrar MW, Barr WK, Montgomery MA. Femoral artery catheterization complications: a study of 503 consecutive patients. *Cathet Cardiovasc Diagn*. 1995;34(1):8-13. PMID:7728861. <http://dx.doi.org/10.1002/ccd.1810340304>.
- Piper WD, Malenka DJ, Ryan TJ Jr, et al. Predicting vascular complications in percutaneous coronary interventions. *Am Heart J*. 2003;145(6):1022-9. PMID:12796758. [http://dx.doi.org/10.1016/S0002-8703\(03\)00079-6](http://dx.doi.org/10.1016/S0002-8703(03)00079-6).
- Applegate RJ, Sacrinty MT, Kutcher MA, et al. Propensity score analysis of vascular complications after diagnostic cardiac catheterization and percutaneous coronary intervention 1998-2003. *Catheter Cardiovasc Interv*. 2006;67(4):556-62. PMID:16532497. <http://dx.doi.org/10.1002/ccd.20677>.
- Biancari F, D'Andrea V, Di Marco C, Savino G, Tiozzo V, Catania A. Meta-analysis of randomized trials on the efficacy of vascular closure devices after diagnostic angiography and angioplasty. *Am Heart J*. 2010;159(4):518-31. PMID:20362708. <http://dx.doi.org/10.1016/j.ahj.2009.12.027>.
- Vaitkus PT. A meta-analysis of percutaneous vascular closure devices after diagnostic catheterization and percutaneous coronary intervention. *J Invasive Cardiol*. 2004;16(5):243-6. PMID:15152128.
- Koreny M, Riedmüller E, Nikfardjam M, Siostrzonek P, Müllner M. Arterial puncture closing devices compared with standard manual compression after cardiac catheterization: systematic review and meta-analysis. *JAMA*. 2004;291(3):350-7. PMID:14734598. <http://dx.doi.org/10.1001/jama.291.3.350>.
- Rickli H, Unterweger M, Süttsch G, et al. Comparison of costs and safety of a suture-mediated closure device with conventional manual compression after coronary artery interventions. *Catheter Cardiovasc Interv*. 2002;57(3):297-302. PMID:12410501. <http://dx.doi.org/10.1002/ccd.10294>.

20. Carere RG, Webb JG, Buller CE, et al. Suture closure of femoral arterial puncture sites after coronary angioplasty followed by same-day discharge. *Am Heart J.* 2000;139(1 Pt 1):52-8. PMID:10618562. [http://dx.doi.org/10.1016/S0002-8703\(00\)90308-9](http://dx.doi.org/10.1016/S0002-8703(00)90308-9).
21. Noguchi T, Miyazaki S, Yasuda S, et al. A randomized controlled trial of Prostar Plus for haemostasis in patients after coronary angioplasty. *Eur J Vasc Endovasc Surg.* 2000;19(5):451-5. PMID:10828223. <http://dx.doi.org/10.1053/ejvs.1999.1071>.

---

**Correspondence**

Altino Ono Moraes  
Av. Cidade de Leiria, 445  
CEP 87014-100 - Maringá (PR), Brazil  
Tel.: +55 (44) 3224-6704 / +55 (44) 98802-4822  
E-mail: altino\_moraes@uol.com.br

**Author information**

AOM - MSc in Surgery from Universidade Federal de São Paulo (UNIFESP); Board-certified in Vascular Surgery, Endovascular Surgery, and Angioradiology by Sociedade Brasileira de Angiologia e de Cirurgia Vascular (SBACV); Chief Preceptor, Programa de Residência Médica em Cirurgia Vascular, Associação Beneficente Bom Samaritano.

RYN - Vascular Surgeon; Board-certified in Vascular Surgery by Sociedade Brasileira de Angiologia e de Cirurgia Vascular (SBACV).

EFV - Vascular Surgeon; Board-certified in Vascular Surgery by Sociedade Brasileira de Angiologia e de Cirurgia Vascular (SBACV); Preceptor, Programa de Residência Médica em Cirurgia Vascular, Associação Beneficente Bom Samaritano.

MHEY - Vascular Surgeon and Technical Director, Hospital Santa Casa de Cianorte.

JMMA and PG - Resident in Vascular Surgery at Associação Beneficente Bom Samaritano.

**Author contributions**

Conception and design: AOM

Analysis and interpretation: AOM, RYN

Data collection: AOM, RYN, MHEY, JMMA

Writing the article: AOM, RYN

Critical revision of the article: AOM

Final approval of the article\*: AOM, RYN, EFV, MHEY, JMMA, PG

Statistical analysis: AOM, RYN

Overall responsibility: AOM

\*All authors have read and approved of the final version of the article submitted to *J Vasc Bras*.