

A New Species of *Henneguya*, a Gill Parasite of *Astyanax altiparanae* (Pisces: Characidae) from Brazil, with Comments on Histopathology and Seasonality

Bianca Barassa⁺, Nelson S Cordeiro, Sarah Arana*

Departamento de Parasitologia *Departamento de Histologia e Embriologia, Instituto de Biologia, Universidade Estadual de Campinas, Caixa Postal 6109, 13083-970 Campinas, SP, Brasil

A new species of Myxosporea, Henneguya chydadea, is described parasitizing the gills of Astyanax altiparanae collected from a lake on Rio das Pedras farm near Campinas, state of São Paulo, Brazil. Of the fish examined, 88.3% had gills parasitized by myxosporeans. The prevalence of the parasite ranged from 80% in the spring and fall, 93% in the summer and 100% in the winter. The parasite induced the formation of white, oval-shaped cysts measuring 40-64 µm x 64-80 µm which deformed the gill lamellae, compressed the capillaries, and caused retraction of the neighboring lamellae. The mature spores were elongated and had two identical, parallel elongate polar capsules. Each capsule contained a polar filament with 9-10 turns. There was no mucous envelope or iodophilous vacuole. Morphometric differences between this parasite and other species of the genus Henneguya indicated, that the parasite observed in A. altiparanae is a new species. This is the first report of a myxosporean parasitizing A. altiparanae.

Key words: Myxozoa - *Henneguya chydadea* sp. n. - *Astyanax altiparanae* - histopathology - Brazil

The fish fauna of the neotropical region is the most diversified of the world, and represent about 24% of the global marine and freshwater fish species (Schaefer 1998). With the growth of aquaculture in several regions of the world since 1990 (Kent et al. 2001), the study of fish pathologies has become increasingly important. Among agents responsible for diseases in fish are the myxosporeans, which cause serious damage to economically important fish species. There are approximately 1 350 species of myxosporeans distributed in 52 genera, most of which parasitize freshwater fish (Kent et al. 2001).

Among myxosporeans, the genus *Henneguya* Thélohan, 1892 is the most abundant in South America, with 29 known species. The importance of this genus as a pathogen of freshwater fish has been described by several authors (Dyková & Lom 1978, Kalavati & Narasimhamurti 1985, Lom & Dyková 1995, Martins & Souza 1997, Martins et al. 1999a). Among freshwater fish, the genus *Astyanax* Baird & Girard, 1854 contains approximately 100 species and subspecies that are widely distributed throughout South and Central America (Garutti & Britski 1997). These small size fish, popularly known as lambari in Brazil, occupy a fundamental position in the food chain of aquatic ecosystems, were they serve as food for several predators (Esteves 1996). In addition to their commercial value as a source of food in several regions, lambari are also much appreciated for sport fishing (Barbieri & Marins 1995).

The presence of myxosporeans in lambari has been

reported, with eight species of *Henneguya* having been described so far (Cordeiro et al. 1983, Gióia et al. 1986, Gióia & Cordeiro 1987), although none in *A. altiparanae* Garutti & Britski, 2000.

During a study of the myxosporean fauna in *A. altiparanae* collected near the city of Campinas, in the state of São Paulo, Brazil, we observed a new species of *Henneguya* parasitizing the gills of this species. In this paper, we describe this new species, and report the prevalence and histopathological modifications caused by this parasite.

MATERIALS AND METHODS

Ten juvenile and adult specimens of *A. altiparanae* were collected monthly from January to December, 2001 from a lake located on Rio das Pedras farm, close to the city of Campinas and examined for the presence of myxosporeans. The fish were transported alive to the laboratory where they were killed, measured and necropsied. Twenty spores from freshly prepared material obtained from different fish specimens were measured immediately (Lom & Arthur 1989) using a micrometer incorporated into a microscope. The spores were treated with Lugol solution to determine the presence of iodophilous vacuoles in the sporoplasma, and with India ink to detect the presence of a mucous envelope (Lom & Vávra 1963). Rubbings containing free spores were fixed in methanol, stained with Giemsa solution (pH 7.2) and mounted in Cytoseal™. For histopathological analysis, fragments of gill containing cysts obtained from the same specimens of *A. altiparanae*, were fixed in buffered 10% formalin for 24 h and included in paraffin. Sections 4 µm thick were stained with hematoxylin-eosin. For scanning electron microscopy (SEM), free spores were placed on a slide coated with poly-L-lysine then fixed in glutaraldehyde, and washed with 1 M sodium cacodylate buffer before dehydration in an alcohol series. After critical

⁺Corresponding author. Fax: +55-19-3289.3124. E-mail: b_barassa@hotmail.com
Received 24 January 2003
Accepted 25 June 2003

point drying, the samples were coated with gold and examined with a JEOL JMS-5900LV electron microscope operated at 15 kV.

The chemical and physical properties of the lake water (pH, conductivity, dissolved solids, and oxygen) were determined monthly using a Corning Check Mate Model 90 meter.

Pearson's correlation coefficient was used to determine whether there was a correlation between the prevalence of the parasite and the properties of the water. A chi-square test was used to compare the seasonal prevalence of the parasite.

RESULTS

Of the 120 (117 adult and 3 juvenile) specimens of *A. altiparanae* examined, 106 (88.3%) had gills parasitized by myxosporeans. Of the fish parasitized, 97.2% were adult, and 2.8% were juveniles. The overall prevalence of the parasite in males and females was 77.8%, and 90.2%, respectively. The prevalence of the parasites ranged from 80% in the spring and fall, 93% in the summer, and 100% in the winter. This difference was not significant ($\chi^2 = 1.01$; $p = 0.05$). In the spring, the prevalence of infected adult and juveniles was 79.3% (23/29) and 100% (1/1) respectively, whereas in the summer, the corresponding values were 92.8% (26/28) and 100% (2/2). In the fall and winter, the prevalence of infected adult was 80% (24/30) and 100% (30/30) respectively. No juveniles were collected in these two seasons. There was no significant correlation between the prevalence of parasites and the chemical and physical properties of the water, including pH ($r = 0.25$; $p = 0.42$), conductivity ($r = 0.39$; $p = 0.19$), dissolved oxygen ($r = -0.11$; $p = 0.73$), dissolved solids ($r = 0.29$; $p = 0.34$) and temperature ($r = -0.35$; $p = 0.26$). Based on the shape and dimensions of the spores, the myxosporean studied was identified as a new species of *Henneguya*.

Henneguya chydadea sp. n.

Figs 1-3

Description

Vegetative stage - White, oval-shaped and polysporic cysts measuring 40-64 μm x 64-80 μm were encountered in the gill lamellae of *A. altiparanae*. When opened, spores in all stages of development were observed (Fig. 1A).

Spores ($n = 20$) - Mature spores elongated (total length 17.6-20 μm ; spore length 8.8-11.2 μm ; spore width 3.2-5.6 μm ; thickness 3.6-4 μm ; caudal appendix length 8-9.6 μm). Sporoplasma binucleate. Two polar capsules elongated and of equal size (length 3.2-4.4 μm , width 1.2- 1.6 μm). Polar filament with 9-10 coils, arranged perpendicular to the axis of the capsule. Spore wall smooth consisting of two symmetrical valves with a visible line of suture (Figs 2, 3). Scanning electron microscopy revealed two pores for the discharge of polar filaments situated at the anterior extremity of the spore on one side of the line of suture (Fig. 2B). Mucous envelope or iodophilous vacuole not seen.

Type host - *Astyanax altiparanae* Garutti & Britski, 2000 (Characidae: Tetragonopterinae)

Site of infection - Gill lamella epithelium

Prevalence - 88.3% (106/120)

Locality - Rio das Pedras farm, municipality of Campinas, state of São Paulo, Brazil.

Type material - slides with stained spores of *H. chydadea* sp. n. (Syntipe) were deposited in the collection of the Museum of Natural History in the Institute of Biology, State University of Campinas (Unicamp) (accession numbers ZUEC 10 and 11).

Etymology - the specific name of the parasite is derived of the Latin word *chydaeus* (= common).

Histopathology - Histological analysis of the gills of *A. altiparanae* revealed that the *H. chydadea* cysts were of the intralamellar-type located in the gill lamella epithelium. The initial development of the cysts occurred in several regions (basal, median and distal) of the gill lamella without compromising the gill structure (Fig. 1B, C). In more advanced stages, the cysts occupied the entire lamella and caused its deformation. As a result, the epithelial cells were compressed and their nucleus were situated to the free surface. Compression of the capillaries and retraction of the neighboring lamellae were also observed (Fig. 1D). No inflammatory reaction or hyperplasia was observed during development of the cysts.

DISCUSSION

The shape and dimensions of the cysts and spores of *H. chydadea* were compared with those of other species of *Henneguya* reported for freshwater fish of South America and other parts of the world. Of the species described, only *H. wenyoni* Pinto, 1928, which parasitizes the gills of *Tetragonopterus* sp. (Pinto 1928), and *H. santae* Guimarães & Bergamini, 1934, which parasitizes the gills of *Tetragonopterus santae* (Guimarães & Bergamini 1934), shared some features with *H. chydadea* (Table). The spores of *H. wenyoni* resembled those of *H. chydadea* in body length and in the length and width of the polar capsules. However, the spores of *H. wenyoni* had a longer tail process and the body was wider. The morphology and body width of the spores of *H. santae* were similar to those of *H. chydadea*, but the tail process of *H. santae* was longer and the body and polar capsule lengths were shorter than in *H. chydadea*. In addition, the spores of *H. wenyoni* and *H. santae* had an iodophilous vacuole and the polar capsules were of variable size, whereas in *H. chydadea* the iodophilous vacuole was absent and the polar capsule dimensions were constant. The dimensions of the cysts in *H. wenyoni* (2 mm x 1 mm) and *H. santae* (1 mm x 0.70 mm) were greater than those of *H. chydadea* cysts (40-64 μm x 64-80 μm). Based on the morphometric differences, the parasite observed in *A. altiparanae* was considered to be a new species of *Henneguya*, and the first to be recorded in *A. altiparanae*.

No significant seasonal differences were found, therefore the number of mature *H. chydadea* cysts and spores in the gills of *A. altiparanae* was greatest during the winter, and gradually decreased thereafter, probably through rupture. These observations suggest that *H. chydadea* could have a seasonal cycle of development in *A. altiparanae*, although further studies are needed to confirm this. The properties of the lake water had no effect on the prevalence of the parasite throughout the year.

A seasonal reproductive cycle has also been reported for other species of *Henneguya*. Molnár (1998) observed seasonality and synchronicity in the development of the cysts and spores of *H. creplini*, a parasite of the gills of *Stizostedion lucioperca*. The young cysts of *H. creplini* appeared in the gills of *S. lucioperca* in April and gradually grew to form spores in the winter. Rupture of the cysts to

release the spores occurred in March of the following year. Cone (1994) reported that for *H. doori*, a parasite of *Perca flavescens*, cyst development and spore release occurred between September of one year and March of the following year. This author also observed that rupture of the cysts and the release of spores occurred following an increase in temperature.

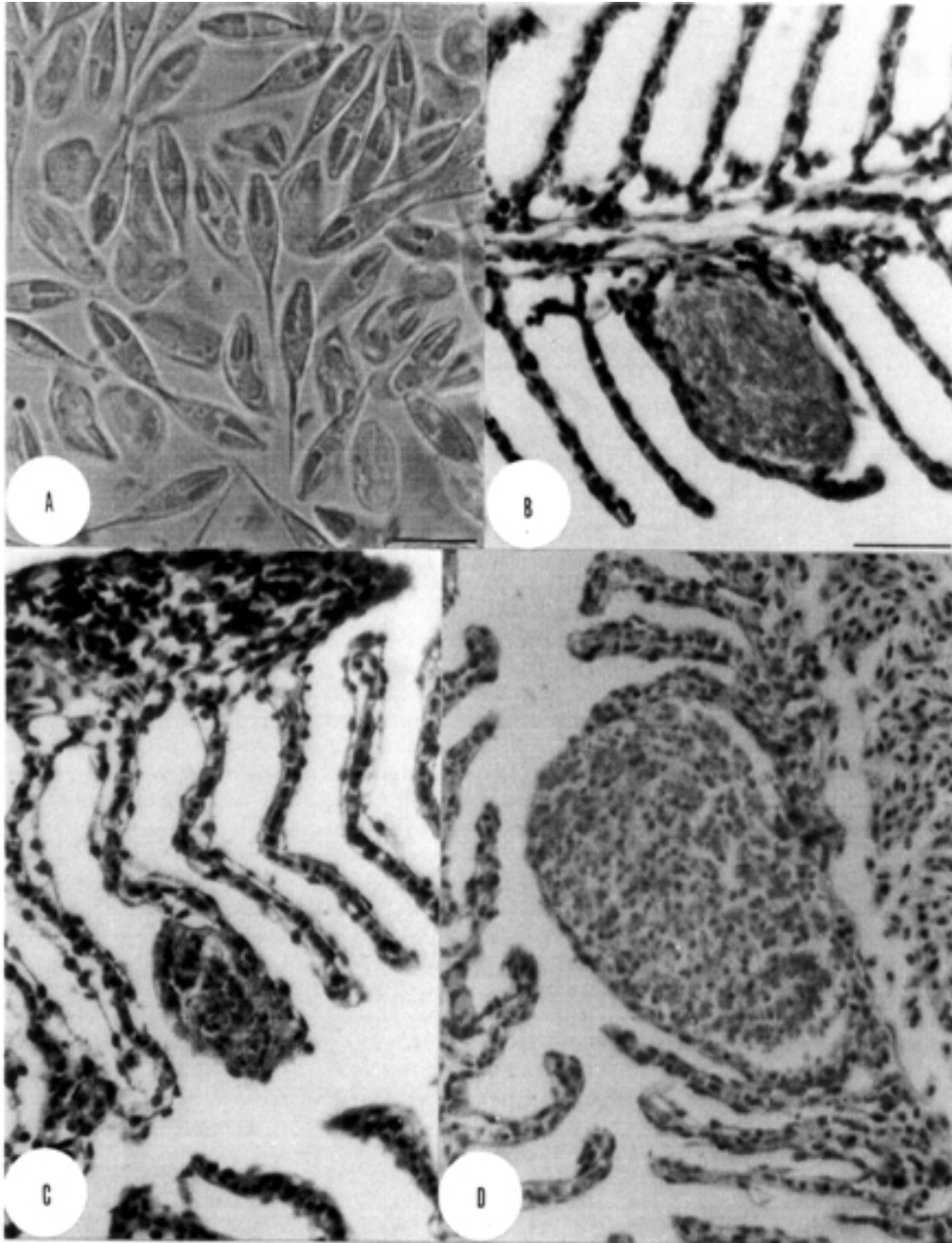


Fig. 1: *Henneguya chydadea* sp. n. from *Astyanax altiparanae*. A: spores in a fresh preparation. Bar = 5 μ m; B-D: histological sections of a gill. B: immature cyst located in the basal and median regions of a gill lamella. Bar = 30 μ m; C: immature cyst in the distal region of a gill lamella. Bar = 30 μ m; D: mature cyst occupying the entire length of the lamella: note the presence of epithelial cells with their nucleus close to the free surface (black arrow), as well as compression of the neighboring lamellae with a discrete reduction in the interlamellar space (white arrow) Bar = 30 μ m

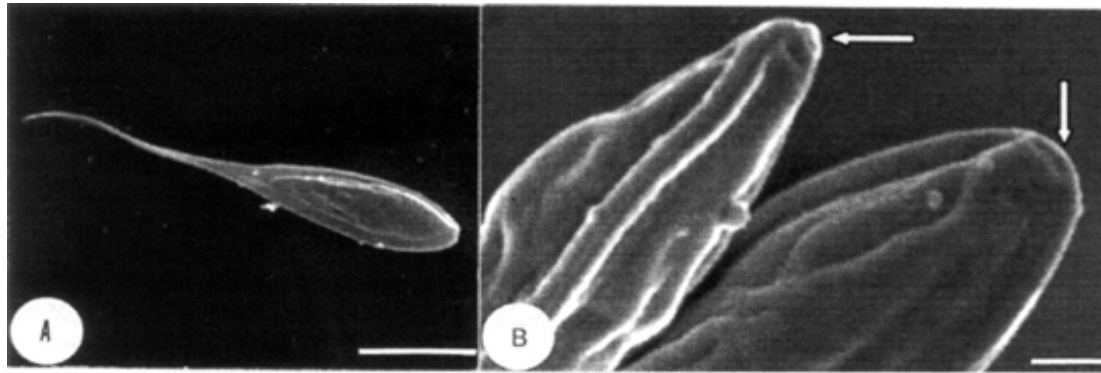


Fig. 2: scanning electron micrograph of *Henneguya chydadea* sp. n. from *Astyanax altiparanae*. A: frontal view. Bar = 5 μ m; B: lateral view: note the presence of two pores for the discharge of polar filaments situated at the anterior extremity of the spore on one side of the line of suture. Bar = 1 μ m

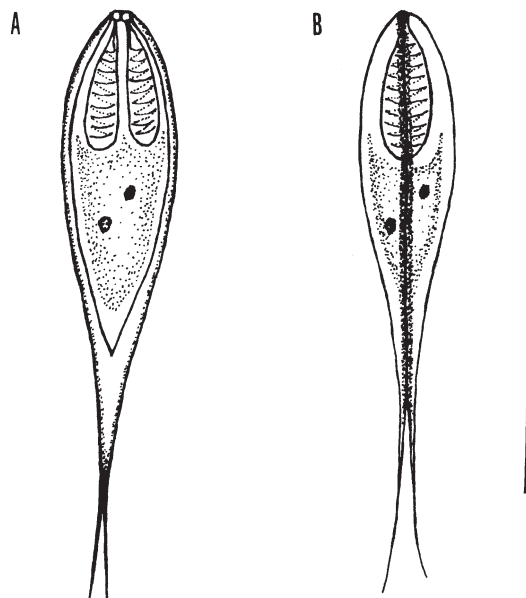


Fig. 3: schematic representation of mature spores of *Henneguya chydadea* sp. n. A: frontal view; B: lateral view. Bar = 10 μ m

The development of *H. chydadea* cysts in the epithelium of the gill lamellae of *A. altiparanae* resulted in deformation of the lamellae and compression of the capillaries. In more advanced stages, when the cysts occupied the entire length of a lamella, retraction of the neighboring lamellae was observed, with a reduction in

the surface available for gas exchange. In the initial stages, cysts development occurred on one side of the gill lamella, with marked dilatation of the side infected. According to Molnár (2002), such cysts are classified as asymmetric.

In a similar histopathological study of the gills of *S. lucioperca* parasitized by *H. creplini*, which produce the same kind of cysts, as those described here, Molnár (1998) also reported hyperplasia and the formation of a thick layer of granular tissue.

In other works, Kalavati and Narasimhamurti (1985), who studied *Channa punctatus* infected by *H. waltirensis*, Martins and Souza (1997), who studied the gills of *Piaractus mesopotamicus* parasitized by *Henneguya* sp., and Martins et al. (1999b), who studied the gills of *Leporinus macrocephalus* infected by *H. leporinocola*, hemorrhage and/or inflammatory foci were observed, neither of which was seen here.

Although massive infection by *H. chydadea* was not observed, the histopathological alterations (deformation of the structures, compression of the capillaries and retraction of the neighboring lamellae) indicated that this parasite is potentially pathogenic, and that a high parasite load could compromise gill functions.

ACKNOWLEDGEMENTS

To the Laboratório de Microscopia Eletrônica, Laboratório Nacional de Luz Síncrotron, Campinas, Brazil, for use of the electron microscope. To Nilson Branco for help in the field work and Dr Stephen Hyslop for editing the English.

REFERENCES

Barbieri G, Marins MA 1995. Estudo da dinâmica da reprodução de fêmeas de *Astyanax bimaculatus* (Linnaeus, 1758) da

TABLE

Comparison of the measurements (μ m) of spores from *Henneguya chydadea* n. sp. with these of other species of *Henneguya*

Species	TL	BL	BW	TaL	PCL	PCW	FC	TSB
<i>H. chydadea</i> n. sp.	17.6-20.0	8.8-11.2	3.2-5.6	8.0-9.6	3.2-4.4	1.2-1.6	9-10	3.6-4.0
<i>H. santae</i>	19.3-22.0	8.5-10.6	4.9-5.7	8.7-12.7	2.5-3.5	-	-	-
<i>H. wenyoni</i>	19-24	11-12	4.5-6.0	8.0-12.0	3.4-5.0	1.5	-	-

TL: total length; BL: body length; BW: body width; TaL: tail length; PCL: polar capsule length; PCW: polar capsule width; FC: number of polar filament coils; TSB: thickness of the spore body; -: unknown

- Represa do Lobo, Estado de São Paulo (Osteichthyes, Characidae). *Arq Biol Tecnol* 38: 1191-1197.
- Cone DK 1994. Annual cycle of *Henneguya doori* (Myxosporea) parasiting yellow perch (*Perca flavescens*). *J Parasitol* 80: 900-904.
- Cordeiro NS, Artigas PT, Gióia I, Lima RS 1983/84. *Henneguya pisciforme* n. sp., myxosporídio parasito de brânquias do lambari *Hyphessobrycon anisitsi* (Pisces, Characidae). *Mem Inst Butantan* 47/48: 61-69.
- Dyková I, Lom J 1978. Histopathological changes in fish gills infected with myxosporidian parasites of the genus *Henneguya*. *J Fish Biol* 12: 197-202.
- Esteves KE 1996. Feeding ecology of three *Astyanax* species (Characidae, Tetragonopterinae) from a floodplain lake of Mogi-Guaçu river, Paraná river basin, Brazil. *Environ Biol Fish* 46: 83-101.
- Garutti V, Britski HA 1997. Descrição de uma nova espécie de *Astyanax* (Teleostei, Characidae), com mancha umeral horizontalmente ovalada, da bacia do rio Guaporé, Amazônia. *Papéis Avul Zool São Paulo* 40: 217-229.
- Guimarães JRA, Bergamini F 1934. *Henneguya santae* sp. n. um novo mixosporídio parasito de *Tetragopterus* sp. *Rev Indústria Animal* 12: 110-113.
- Gióia I, Cordeiro NS 1987. Myxosporea da ictiofauna brasileira: *Henneguya artigasi* n. sp. (Myxosporea: Myxobolidae). XIV Cong Bras Zoologia, Juiz de Fora, p. 186.
- Gióia I, Cordeiro NS, Artigas PT 1986. *Henneguya intracornea* n. sp. (Myxozoa: Myxosporea) parasito de olho de lambari, *Astyanax scabripinnis* (Jenyns, 1842) (Osteichthyes, Characidae). *Mem Inst Oswaldo Cruz* 81: 401-407.
- Kalavati C, Narasimhamurti CC 1985. Histopathological changes in the gills of *Channa punctatus* BL. infected with *Henneguya waltirensis*. *Arch Protistenk* 129: 199-202.
- Kent ML, Andree KB, Bartholomew JL, El-Matbouli M, Desser SS, Delvin RH, Feist SW, Hedrick RP, Hoffmann RW, Khattra J, Hallett SL, Lester RJG, Longshaw M, Palenzeula O, Siddall ME, Xiao CX 2001. Recent advances in our knowledge of the Myxozoa. *J Euk Microbiol* 48: 395-413.
- Lom J, Arthur JR 1989. A guideline for the preparation of species descriptions in Myxosporea. *J Fish Dis* 12: 151-156.
- Lom J, Dyková L 1995. Myxosporea (Phylum Myxozoa). In PTK Woo, *Fish Diseases and Disorders - Protozoan and Metazoan Infections*, Vol. 1, Cab International, p. 87-147.
- Lom J, Vávra J 1963. Mucous envelopes of spores of the subphylum Cnidospora (Doflein, 1901). *Vestn Cesk Spol Zool* 27: 4-6.
- Martins ML, Souza VN 1997. *Henneguya piaractus* n. sp. (Myxozoa: Myxobolidae), a gill parasite of *Piaractus mesopotamicus* Holmberg, 1887 (Osteichthyes: Characidae), in Brazil. *Rev Bras Biol* 57: 239-245.
- Martins ML, Souza VN, Moraes JRE, Moraes FR, Costa AJ 1999a. Comparative evaluation of the susceptibility of cultivated fishes to the natural infection with myxosporean parasites and tissue changes in the host. *Rev Bras Biol* 59: 263-269.
- Martins ML, Souza VN, Moraes JRE, Moraes FR 1999b. Gill infection of *Leporinus macrocephalus* Garavello & Bristski, 1988 (Osteichthyes: Anostomidae) by *Henneguya leporinocola* n. sp (Myxozoa: Myxobolidae) description, histopathology and treatment. *Rev Bras Biol* 59: 527-534.
- Molnár K 1998. Taxonomic problems, seasonality and histopathology of *Henneguya creplini* (Myxosporea) infection of the pikeperch *Stizostedion lucioperca* in Lake Balaton. *Folia Parasitol* 45: 261-269.
- Molnár K 2002. Site preference of fish myxosporeans in the gill. *Dis Aquat Org* 48: 197-207.
- Pinto C 1928. *Henneguya wenyoni* n. sp. myxosporidie parasite des branchies des poissons d'eau douce du Brésil. *Comptes Rendus Soc Biol Paris* 98: 1580.
- Schaefer SA 1998. Conflict and resolution: impact of new taxa on phylogenetic studies of the neotropical cascudinhos (Siluroidea: Loricariidae). In LR Malabarba, RE Reis, RP Vari, ZMS Lucena, CAS Lucena (eds), *Phylogeny and Classification of Neotropical Fishes*, EDIPUCRS, Porto Alegre, p. 375-400.