






Impact of the SARS-Cov2 Pandemic on Orthodontic Therapies: An Italian Experience of Teleorthodontics

Alessandra Putrino¹, Martina Caputo¹, Denise Giovannoni¹, Ersilia Barbato¹, Gabriella Galluccio¹

¹Department of Oral and Maxillofacial Sciences, Sapienza University of Rome, Italy.

Author to whom correspondence should be addressed: Alessandra Putrino, Department of Oral and Maxillofacial Sciences, Unit of Orthodontics, Sapienza University of Rome, Italy. Phone: +00393205321465. E-mail: alessandra.putrino@gmail.com.

Academic Editor: Alessandro Leite Cavalcanti

Received: 18 May 2020 / Accepted: 29 June 2020 / Published: 18 July 2020

How to cite this article: Putrino A, Caputo M, Giovannoni D, Barbato E, Galluccio G. Impact of the SARS-Cov2 pandemic on orthodontic therapies: an Italian experience of teleorthodontics. *Pesqui Bras Odontopediatria Clín Integr*. 2020; 20:e0100. <https://doi.org/10.1590/pboci.2020.140>

Abstract

Objective: To assess the possibility of controlling patients at a distance according to principles of teleorthodontics to understand its possible usefulness in the future routine activity and the impact pandemic may have had on different types of orthodontic treatments. **Material and Methods:** One hundred orthodontic patients (57 F, 43 M, age 7-46) during quarantine were checked through videocalls and photos sent by patients following proper instructions. Three groups have been distinguished based on the type of therapy: A-fixed appliances; B-removable appliances; C-clear aligners. Relevant events about dental and gingival health, integrity of appliances, orthodontic therapies related symptoms and overall progress of treatments were recorded. **Results:** A and B groups reported higher percentages of gingival inflammation (27 and 22%), dental plaque (16 and 13%), deciduous tooth loss (8 and 16%). Bracket and attachment detachment were the most frequent events in A and C groups (22 and 23%). Pain and discomfort were reported in A and B groups (35 and 32%). Therapies continued to progress better in C (51% improved dental alignment) and B (31% improved malocclusions) groups. **Conclusion:** Orthodontics is safe and allows during emergencies to postpone checks. Everyday mobile-technology is useful in managing orthodontic patients unable to carry out in-person control. When their effectiveness equals other systems, treatments with clear aligners without attachments should be preferred in patients unavailable for regular checks.

Keywords: Telemedicine; Orthodontics; Coronavirus Infections; SARS Virus.

Introduction

Telemedicine is the complex of technologies and tools that cover medical services, ranging from the formation of opinion during consultation to diagnosis, prescriptions, treatment and monitoring of the patient, all carried out remotely via an Internet connection. Telemedicine allows to break down the distances that exist between doctor and patient also in pediatric age [1,2]. This is also a very important aspect in dentistry. Teledentistry is, in fact, a specialistic extension of telemedicine that has been developed first at the military level and subsequently has found application mainly in the management of visits to patients living in rural areas in countries where dental practices can be many kilometers away or in the case of the management of patients whose movements want to be limited to the necessary for reasons of greater fragility, for example in the case of cancer patients [3].

In the context of teledentistry, its application to orthodontics, called teleorthodontics, can be considered a very useful tool to assess the patient remotely when he wants to report a problem related to a fixed or removable device before periodic check-in person or when he has doubts about how to use the removable orthodontic devices or some components of the fixed one (e.g., elastics) [4].

The SARS-CoV-2 pandemic required dentists to limit their performance to those so-called 'non-deferable' emergencies to avoid the possible spread of the infection given the high risk of infection in healthcare environments where procedures involve aerosol production [5].

Orthodontists like all dentists, who did not have guidelines in the first few months, had to suspend their visits and regular checks on their patients and also the management of orthodontic emergencies that would normally lead to an early visit of the patient (among the most common: oral cavity lesions, detachment of brackets and bands, breakage of orthodontic arch, breakage of a removable device, detachment of attachments from aligners and breakage of them). The lack of professional platforms developed specifically for teledentistry and therefore also teleorthodontics has meant that in order to make up for the impossible in-person control, orthodontists have mainly used mobile messaging services, video calls and applications to carry out this new activity [6].

This study aims to assess the reliability of virtual orthodontic remote controls according to principles of teleorthodontics to understand its possible usefulness in the future routine activity and to evaluate the impact that the pandemic may have had on different types of orthodontic treatments.

Material and Methods

Sample

One hundred patients (57 females and 43 males, age 7 to 46) under orthodontic therapy in our dental offices carried out orthodontic monthly checks (after an average period of 40 days since the last check-up in the dental office) using the WhatsApp mobile phone application's video call service (Facebook Inc., Menlo Park-USA) from their mobile phone or their parents' (and in their presence) if under the age of 18.

Clinical Instructions

Patients were given the following instructions to make orthodontic control easier and explanatory guide photos (made on himself by one of the authors) were sent before the virtual check (Figures 1 to 5):

- 1) Sit in a well-lit place in the house by placing frontally the phone or computer (using the Whatsapp service via the web) so that the front camera of the phone (selfie mode) or pc could well frame the mouth of the patient (Figure 6). Help from a parent in case of children or other family members in the case of adult subjects is recommended.

- 2) If the current therapy is with removable orthodontic appliances, make them a series of photographs and send them to the orthodontist before starting the video call.
- 3) Keep mobile devices or auxiliary tools of fixed orthodontic therapy (e.g., rubber bands) near the phone during the video call.
- 4) At the beginning of the video call report, any type of disturbance related to the teeth or oral mucous appeared in the previous days or weeks and any problems related to the appliance as in the traditional appointment.
- 5) During the video call, when asked from the orthodontist, pull the lips or use the fingers of both hands to retract as much as possible the cheeks, as well as the professional cheek distractors that patients know because of the orthodontic photos, to show the teeth.
- 6) Bite down so back teeth touch. Directly facing the camera, smile wide, trying to get as many teeth as possible. Pull lips and cheeks away from teeth with index and middle fingers to show more teeth. Keeping to bite down so that back teeth touch, smile and retract the cheek and lips with the fingers on the right side of the mouth to expose more of teeth. The slight head rotation from the opposite side to that of the retracted cheek helps expose more teeth (Figures 1 to 3).
- 7) For an occlusal view of the upper arch hyperextend head backwards lifting the chin as high as possible and open the mouth wide. Hold the camera so that it's perpendicular to the biting surfaces of the upper teeth (Figure 4).
- 8) For the occlusal view of the lower arch, open the mouth wide and tilt the chin downwards toward the chest. Hold the camera so it's perpendicular to the biting surfaces of the lower teeth. Lift the tongue to facilitate the sight of the dental elements and allow optimal vision of the oral floor and the tongue frenulum (Figure 5).
- 9) Use the index finger and thumb of both hands at the same time to pull the upper lips first and then lower and allow a view of the frontal frenulum.

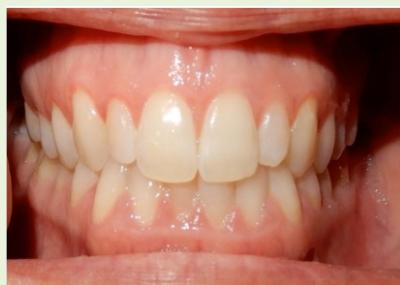

Figure 1. Frontal view in the tutorial photo.

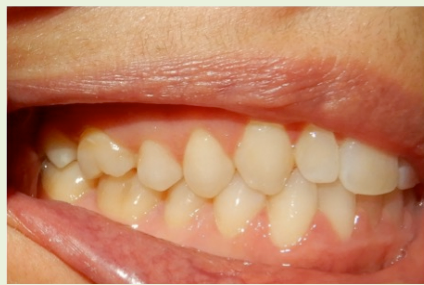

Figure 2. Right lateral view in the tutorial photo.

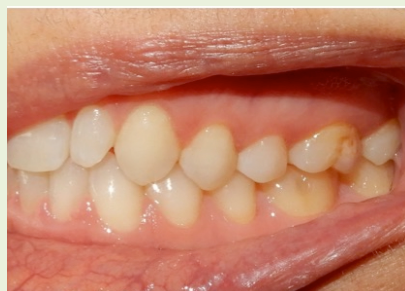

Figure 3. Left lateral view in the tutorial photo.

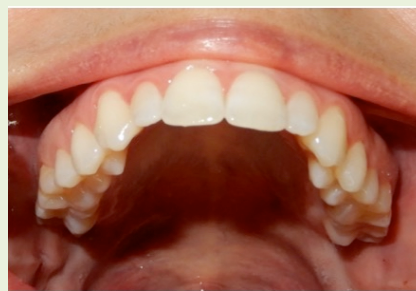

Figure 4. Occlusal view of the upper dental arch in the tutorial photo

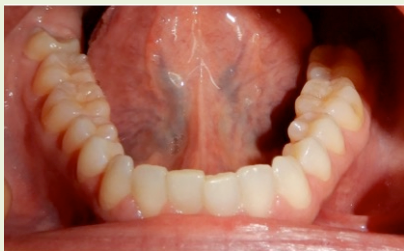

Figure 5. Occlusal view of the lower dental arch in the tutorial photo.



Figure 6. A 10 years old patient wearing a Bionator appliance and her mother during her orthodontic check via video call.

Subjects with removable (including aligners) appliances should also repeat these steps of the orthodontic check wearing their appliances to check the consistency and absence of any problems. Patients with fixed multibrackets or on metal bands therapies should check with their fingertips that all brackets and bands have not detached. Patients with invisible aligners should check all attachments also occur.

Patients were distinguished into three main groups: those with fixed appliances - multibrackets, palatal expanders, distal jets - (Group A); those with removable appliances - Fraenkel Functional Regulator, Twinblock, Bionator, Schwartz appliance, Tongue cage - (Group B); those with invisible aligners - Invisalign® (Align Technology Inc., Redwood City, CA, USA), Smiletech® (Ortodontica Italia, Roma, Italy), F22® (Sweden & Martina SPA, Due Carrare, Italy), Sorriddi® (Allineatori Sorriddi, Latina, Italy) - (Group C) (Tables 1 to 3). In the group C all patients with the Sorriddi® system and four of those under therapy with Invisalign® system continued the therapy thanks to the sending by post courier of the successive aligners. For the other patients with Invisalign system and with Smiletech® and F22® systems it was not possible to do the same way as the patients would have had to perform stripping and in some cases the removal of the attachments.

The problems and issues related to each group found during this service of virtually assisted orthodontic checks are collected in the results with a descriptive statistical analysis.

Based on the observations detected during the virtual orthodontic checks, the following categories and subcategories indicated in parentheses were grouped according to the three groups of patients referred to:

- The health status of the teeth and gums (visible gum inflammation, dental plaque and suspected carious lesions, tooth fracture, tooth permutation -if applicable-);
- The integrity of the appliance (breaking one or more parts, decementing of attacks, bands, attachments);
- Symptoms related to orthodontic therapy (pain in the pressure mucous of the appliances, inflammations from orthodontic arch or metallic ligatures that sting, dental pain, joint and functional pain);
- Overall progress of orthodontic therapy (compared to the previous orthodontic controls more aligned teeth and/or reduced malocclusion, replacement of invisible aligners occurred without problems).

Ethical Considerations

Patients (or their parents) expressed informed consent to share therapy data (including images and videos) for this study knowing that they would be treated and disclosed anonymously. The current Regulation of the Ethics Committee of the Higher Institute of Health (Istituto Superiore di Sanità) established the ethical aspects that need evaluation, approval and monitoring of trial protocols relate to epidemiological, evaluation and medical-social projects when personal data are not anonymised. In accordance with this regulation, in this study the personal data of patients was anonymized.

Results

The group of patients with fixed orthodontic appliances (Group A) comprised 37 subjects of which 29 with fixed multibrackets therapies (17 of which were in intermediate phase of treatment, 7 at the beginning of therapy, 5 at the end of treatment), 6 with palatal expanders (all had already completed the planned activation cycle and were to be reassessed at each check), 2 with distal-jet (intermediate stage of treatment). The results of the observations for this group have been presented in the Table 1.

The group of patients with removable appliances (Group B) comprised 32 subjects of which 11 with Fraenkel Functional Regulator, 8 with Twin Block, 2 with Bionator, 7 with Schwartz appliance, 4 with Tongue cage. Seven patients were at the early stage of treatment (2 with Twin Block, 2 with Fraenkel, 2 with Schwartz, 1 with Tongue Cage). The others patients of this group were already in an intermediate stage of therapy. The most frequently found situations and events observed in Group B have been collected in Table 2.

The group of patients under treatment with clear aligners (Group C) included 35 patients of which 9 with Invisalign aligners (3 at the beginning of treatment, 5 in intermediate stage of therapy, 1 at the finishing stage of therapy), 7 with F22 aligners (1 at the beginning of therapy, 1 at the intermediate stage, 3 at the end of treatment, 2 at the finishing phase), 8 with Smiletech aligners (2 at the beginning of therapy, 5 at intermediate stage of therapy, 1 at the finishing phase), 11 with Sorrirdi aligners (1 at the beginning of treatment, 10 at intermediate stage of therapy). Results for this group of patients have been reported in Table 3. For the number of subcategories that correspond to the data of the three groups, the descriptive statistics method was applied to these results (Figures 7 to 10).

Patients who overall had a better health condition of teeth and gums were those in Group C (81%). The cases of gum inflammation were greater in A (27%) and B (22%) groups than in C (13%). In A and B groups, mixed teething patients were reported in cases of tooth loss (in A 8%, in B 16%). The dental plaque incidence were higher in A and B groups (16% and 13% versus 6% in C group) (Figure 7). The most frequent events that lead to a loss of integrity are bracket and attachment detachment (22 and 23%), loss of ligatures (14%) and hook breakage (9%) (Figure 8). Patients in the C group did not report any discomfort or pain associated with ongoing orthodontic therapy, while in the other groups cases of pain and discomfort were highlighted (in A 35%, in B 32%) (Figure 9). Group C was the one where the dental situation improved better (51% versus 27% in A), group B was the one where there was a better improvement in malocclusions (31%) compared to the A group (5%) and also where there was no worsening in dental alignment (observed in 8% of A group and 9% of B group) (Figure 10). Figures 11 to 13 show the remote checking of patients.

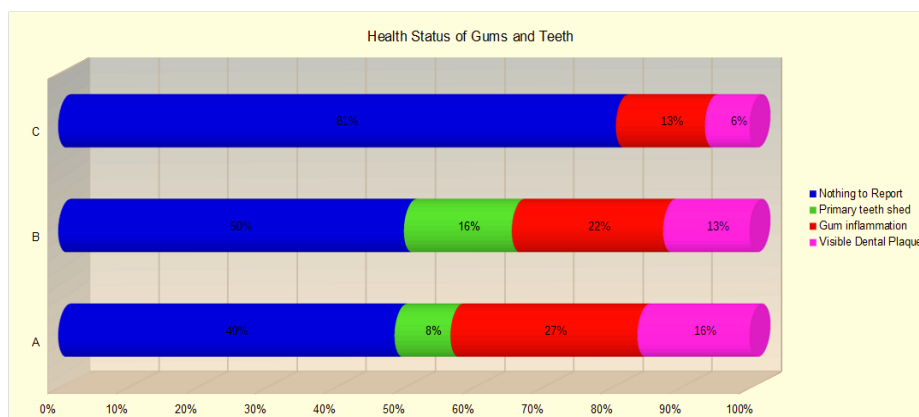


Figure 7. Health status of gums and teeth in the groups sampled.

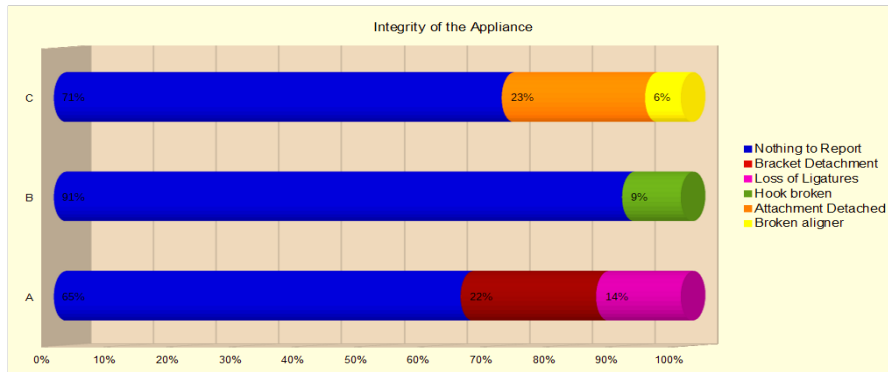


Figure 8. Integrity of the orthodontic appliance in the groups sampled.

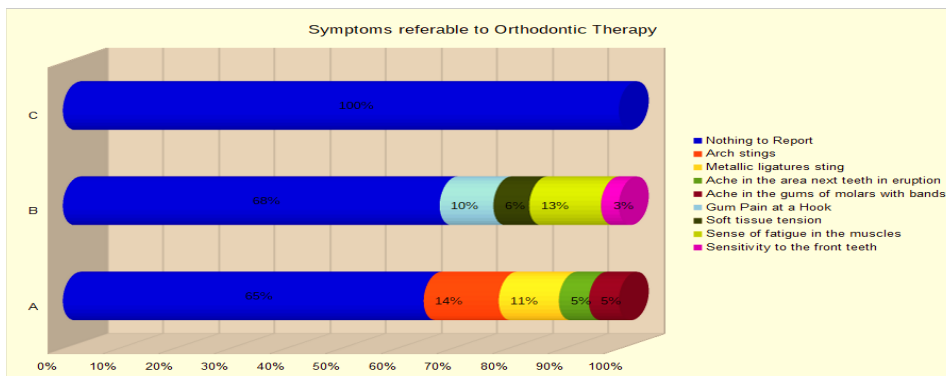


Figure 9. Symptoms referable to orthodontic therapy in the groups sampled.

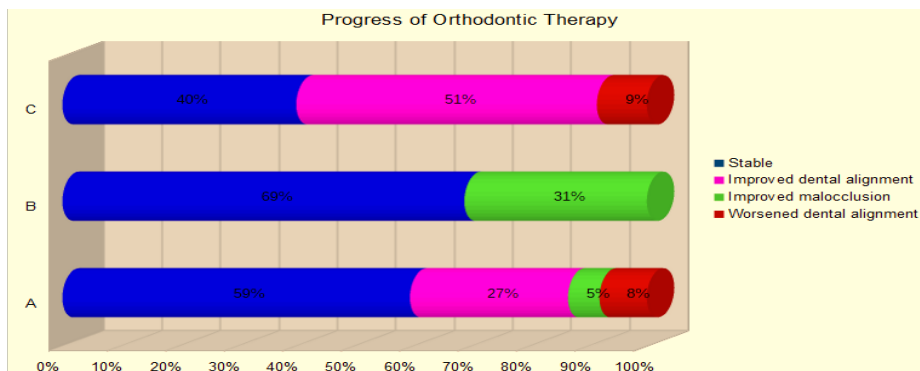


Figure 10. Progress of orthodontic therapy in the groups sampled.

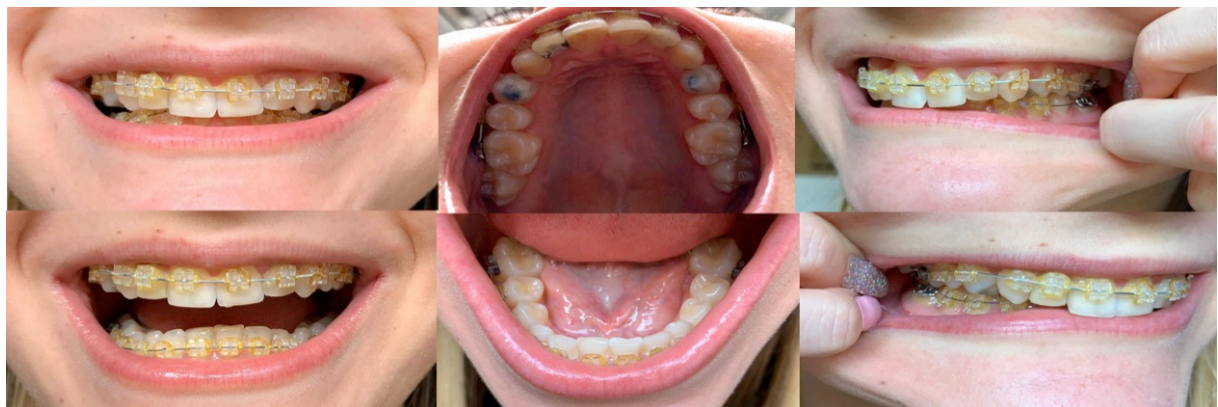


Figure 11. A collection of photographs made with the personal phone and sent to the orthodontist by a patient with a fixed multibrackets appliance before the video call consult.

Table 1. A group data.

Sex	Age	Type of Fixed Appliance	Stage of Treatment	Health Status of Gums and Teeth	Integrity of the Appliance	Symptoms Related to Orthodontic Therapy	Progress of Orthodontic Therapy
F	17	Multibrackets	Intermediate	Nothing to Report	Bracket Detachment	Nothing to Report	Stable
F	38	Multibrackets	Intermediate	Nothing to Report	Nothing to Report	Nothing to Report	Improved Dental Alignment
F	23	Multibrackets	End	Visible Dental Plaque	Nothing to Report	Nothing to Report	Stable
M	24	Multibrackets	Beginning	Gum Inflammation	Loss of Ligatures	Arch Stings	Stable
M	16	Multibrackets	Intermediate	Visible Dental Plaque	Nothing to Report	Nothing to Report	Stable
M	13	Multibrackets	Intermediate	Nothing to Report	Bracket Detachment	Metallic Ligatures Sting	Worsened Dental Alignment
M	15	Multibrackets	Intermediate	Nothing to Report	Nothing to Report	Nothing to Report	Improved Dental Alignment
F	13	Multibrackets	Beginning	Gum Inflammation	Nothing to Report	Nothing to Report	Improved Dental Alignment
F	25	Multibrackets	Intermediate	Visible Dental Plaque	Loss of Ligatures	Nothing to Report	Stable
M	17	Multibrackets	End	Nothing to Report	Nothing to Report	Arch Stings	Stable
F	7	Palatal Expander	End of Activations	Primary Teeth Shed	Nothing to Report	Ache in the Area Next Teeth in Eruption	Improved Malocclusion
M	8	Palatal Expander	End of Activations	Nothing to Report	Nothing to Report	Nothing to Report	Stable
M	8	Palatal Expander	End of Activations	Visible Dental Plaque	Nothing to Report	Nothing to Report	Stable
F	18	Multibrackets	Beginning	Nothing to Report	Loss of Ligatures	Nothing to Report	Stable
M	9	Palatal Expander	End of Activations	Visible Dental Plaque	Nothing to Report	Nothing to Report	Improved Malocclusion
F	12	Distal-jet	Intermediate	Nothing to Report	Nothing to Report	Nothing to Report	Stable
F	10	Palatal Expander	End of activations	Primary Teeth Shed	Nothing to Report	Ache in the Gums of Molars with Bands	Stable
M	13	Distal-jet	Intermediate	Visible Dental Plaque	Nothing to Report	Nothing to Report	Stable
F	15	Multibrackets	Intermediate	Gum Inflammation	Bracket Detachment	Metallic Ligatures Sting	Stable
F	16	Multibrackets	Intermediate	Nothing to Report	Bracket Detachment	Nothing to Report	Stable
M	13	Multibrackets	Beginning	Nothing to Report	Bracket Detachment	Arch Stings	Stable
F	20	Multibrackets	Intermediate	Nothing to Report	Bracket Detachment	Nothing to Report	Worsened Dental Alignment
M	10	Palatal Expander	End of Activations	Primary Teeth Shed	Nothing to Report	Ache in the Gums of Molars with Bands	Stable
M	13	Multibrackets	Intermediate	Gum Inflammation	Bracket Detachment	Nothing to Report	Worsened Dental Alignment
F	12	Multibrackets	Intermediate	Gum Inflammation	Bracket Detachment	Nothing to Report	Stable
M	16	Multibrackets	Beginning	Nothing to Report	Loss of Ligatures	Metallic ligatures sting	Stable
F	14	Multibrackets	Beginning	Nothing to Report	Loss of Ligatures	Arch stings	Stable
F	17	Multibrackets	Intermediate	Nothing to Report	Nothing to Report	Nothing to Report	Improved Dental Alignment

M	12	Multibrackets	Intermediate	Gum Inflammation	Nothing to Report	Metallic Ligatures Sting	Improved Dental Alignment
F	18	Multibrackets	End	Gum Inflammation	Nothing to Report	Nothing to Report	Stable
M	14	Multibrackets	Intermediate	Nothing to Report	Nothing to Report	Nothing to Report	Improved Dental Alignment
M	17	Multibrackets	Intermediate	Gum Inflammation	Nothing to Report	Arch Stings	Stable
F	16	Multibrackets	End	Nothing to Report	Nothing to Report	Nothing to Report	Improved Dental Alignment
F	11	Multibrackets	Beginning	Gum Inflammation	Nothing to Report	Ache in the Area Next Reeth in Eruption	Improved Dental Alignment
F	18	Multibrackets	End	Nothing to Report	Nothing to Report	Nothing to Report	Stable
M	12	Multibrackets	Intermediate	Gum Inflammation	Nothing to Report	Metallic Ligatures Sting	Improved Dental Alignment
M	12	Multibrackets	Intermediate	Nothing to Report	Nothing to Report	Nothing to Report	Improved Dental Alignment

Table 2. B group data.

Sex	Age	Type of Removable Appliance	Stage of Treatment	Health Status of Gums and Teeth	Integrity of the Appliance	Symptoms Related to Orthodontic Therapy	Progress of Orthodontic Therapy
F	7	Tongue Cage	Beginning	Primary Teeth Shed	Nothing to Report	Nothing to Report	Stable
M	10	Twin Block	Intermediate	Visible Dental Plaque	Nothing to Report	Nothing to Report	Stable
M	8	Fraenkel	Intermediate	Nothing to Report	Nothing to Report	Nothing to Report	Stable
M	9	Fraenkel	Intermediate	Visible Dental Plaque	Nothing to Report	Soft Tissue Tension	Stable
F	10	Bionator	Intermediate	Nothing to Report	Nothing to Report	Nothing to Report	Stable
F	10	Schwartz	Intermediate	Nothing to Report	Broken Hook	Nothing to Report	Improved Malocclusion
M	9	Schwartz	Intermediate	Visible Dental Plaque	Nothing to Report	Gum Pain at a Hook	Stable
M	9	Twin Block	Beginning	Nothing to Report	Nothing to Report	Sense of Fatigue in the Muscles	Improved Malocclusion
M	11	Twin Block	Intermediate	Visible Dental Plaque	Nothing to Report	Nothing to Report	Stable
F	12	Twin Block	Intermediate	Nothing to Report	Nothing to Report	Sensitivity to the Front Teeth	Improved Malocclusion
F	10	Fraenkel	Intermediate	Nothing to Report	Nothing to Report	Nothing to Report	Stable
F	10	Schwartz	Intermediate	Nothing to Report	Nothing to Report	Nothing to Report	Stable
F	8	Bionator	Intermediate	Primary Teeth Shed	Nothing to Report	Nothing to Report	Stable
M	9	Fraenkel	Intermediate	Nothing to Report	Nothing to Report	Nothing to Report	Improved Malocclusion
F	10	Fraenkel	Intermediate	Primary Teeth Shed	Nothing to Report	Nothing to Report	Stable
F	10	Fraenkel	Beginning	Gum Inflammation	Nothing to Report	Nothing to Report	Stable

M	8	Tongue cage	Intermediate	Nothing to Report	Nothing to Report	Gum Pain at a Hook	Stable
F	11	Twin Block	Intermediate	Gum Inflammation	Nothing to Report	Nothing to Report	Stable
M	9	Tongue Cage	Intermediate	Nothing to Report	Nothing to Report	Nothing to Report	Stable
F	12	Fraenkel	Beginning	Gum Inflammation	Nothing to Report	Sense of Fatigue in the Muscles	Stable
F	10	Fraenkel	Intermediate	Nothing to Report	Nothing to Report	Nothing to Report	Improved Malocclusion
F	9	Fraenkel	Intermediate	Nothing to Report	Nothing to Report	Soft tissue tension	Improved Malocclusion
M	7	Tongue Cage	Intermediate	Primary Teeth Shed	Nothing to Report	Nothing to Report	Improved Malocclusion
M	11	Twin Block	Intermediate	Nothing to Report	Broken Hook	Nothing to Report	Stable
F	10	Twin Block	Beginning	Nothing to Report	Nothing to Report	Nothing to Report	Stable
F	10	Fraenkel	Intermediate	Gum Inflammation	Nothing to Report	Sense of Fatigue in the Muscles	Improved Malocclusion
M	9	Schwartz	Intermediate	Gum Inflammation	Nothing to Report	Gum Pain at a Hook	Stable
M	12	Schwartz	Beginning	Primary Teeth Shed	Nothing to Report	Nothing to Report	Stable
M	10	Twin Block	Intermediate	Nothing to Report	Nothing to Report	Nothing to Report	Improved Malocclusion
F	13	Schwartz	Intermediate	Gum Inflammation	Broken Hook	Nothing to Report	Stable
F	13	Schwartz	Beginning	Nothing to Report	Nothing to Report	Nothing to Report	Stable
M	10	Fraenkel	Intermediate	Nothing to Report	Nothing to Report	Sense of Fatigue in the Muscles	Improved Malocclusion

Table 3. C group data.

Sex	Age	Type of Clear Aligners	Stage of Treatment	Health Status of Gums and Teeth	Integrity of the appliance	Symptoms Related to Orthodontic Therapy	Progress of Orthodontic Therapy
F	45	Sorridi	Intermediate	Nothing to Report	Nothing to Report	Nothing to Report	Improved Dental Alignment
F	43	Smiletech	Intermediate	Nothing to Report	Attachment Detached	Nothing to Report	Stable
F	38	F22	Finishing	Nothing to Report	Nothing to Report	Nothing to Report	Stable
F	27	F22	End	Gum Inflammation	Attachment detached	Nothing to Report	Worsened Dental Alignment
F	19	F22	End	Nothing to Report	Attachment detached	Nothing to Report	Stable
M	25	Invisalign	Beginning	Gum Inflammation	Nothing to Report	Nothing to Report	Stable
F	31	Sorridi	Beginning	Nothing to Report	Nothing to Report	Nothing to Report	Improved Dental Alignment
M	46	Invisalign	Intermediate	Nothing to Report	Attachment Detached	Nothing to Report	Worsened Dental Alignment
F	21	Smiletech	Intermediate	Nothing to Report	Attachment Detached	Nothing to Report	Stable

M	32	Sorridi	Intermediate	Nothing to Report	Nothing to Report	Nothing to Report	Improved Dental Alignment
F	30	Sorridi	Intermediate	Nothing to Report	Nothing to Report	Nothing to Report	Improved Dental Alignment
M	25	Sorridi	Intermediate	Nothing to Report	Nothing to Report	Nothing to Report	Stable
F	19	Sorridi	Intermediate	Gum Inflammation	Nothing to Report	Nothing to Report	Improved Dental Alignment
F	23	Invisalign	Intermediate	Nothing to Report	Nothing to Report	Nothing to Report	Improved Dental Alignment
M	20	Sorridi	Intermediate	Nothing to Report	Nothing to Report	Nothing to Report	Improved Dental Alignment
M	30	Invisalign	Beginning	Nothing to Report	Nothing to Report	Nothing to Report	Improved Dental Alignment
F	23	Invisalign	Intermediate	Gum Inflammation	Broken Aligner	Nothing to Report	Stable
F	32	Smiletech	Intermediate	Nothing to Report	Nothing to Report	Nothing to Report	Improved Dental Alignment
M	29	Smiletech	Intermediate	Visible Dental Plaque	Nothing to Report	Nothing to Report	Improved Dental Alignment
M	18	F22	Finishing	Nothing to Report	Nothing to Report	Nothing to Report	Stable
M	22	Invisalign	Finishing	Nothing to Report	Nothing to Report	Nothing to Report	Improved Dental Alignment
F	25	Invisalign	Intermediate	Nothing to Report	Nothing to Report	Nothing to Report	Improved Dental Alignment
M	30	F22	Beginning	Nothing to Report	Attachment Detached	Nothing to Report	Stable
F	19	Smiletech	Intermediate	Nothing to Report	Nothing to Report	Nothing to Report	Stable
F	27	Sorridi	Intermediate	Nothing to Report	Nothing to Report	Nothing to Report	Improved Dental Alignment
F	18	Smiletech	Beginning	Nothing to Report	Nothing to Report	Nothing to Report	Improved Dental Alignment
M	33	Invisalign	Beginning	Visible Dental Plaque	Broken Aligner	Nothing to Report	Worsened Dental Alignment
F	25	Invisalign	Intermediate	Nothing to Report	Nothing to Report	Nothing to Report	Stable
F	23	F22	End	Gum Inflammation	Nothing to Report	Nothing to Report	Stable
M	20	F22	Intermediate	Nothing to Report	Attachment detached	Nothing to Report	Stable
M	27	Smiletech	Beginning	Nothing to Report	Nothing to Report	Nothing to Report	Improved Dental Alignment
F	19	Smiletech	Finishing	Nothing to Report	Attachment detached	Nothing to Report	Stable
M	20	Sorridi	Intermediate	Nothing to Report	Nothing to Report	Nothing to Report	Improved Dental Alignment
F	18	Sorridi	Intermediate	Nothing to Report	Nothing to Report	Nothing to Report	Improved Dental Alignment
F	18	Sorridi	Intermediate	Nothing to Report	Nothing to Report	Nothing to Report	Improved Dental Alignment

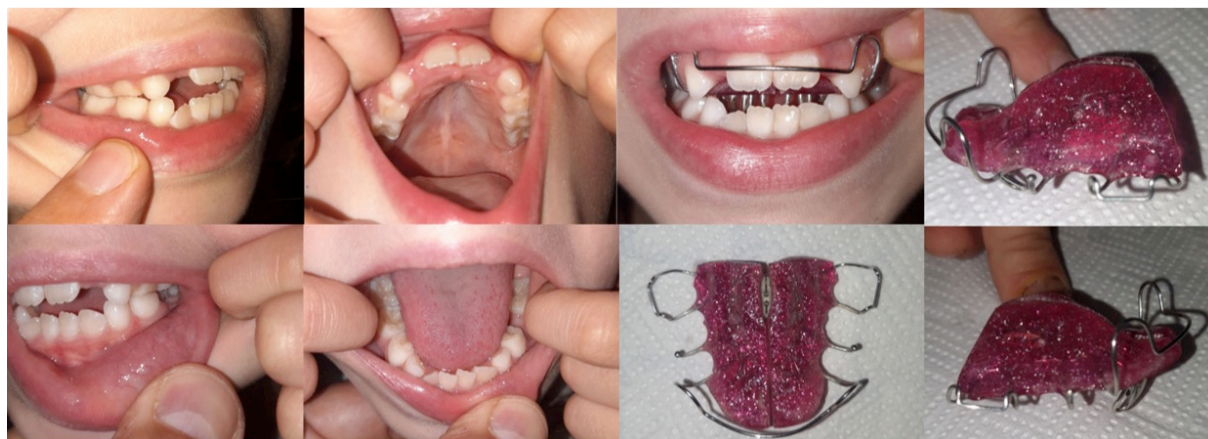

Figure 12. A collection of photographs the parent's of a patient with a removable appliance (Schwartz appliance with tongue thrust) made and sent with the personal phone to the orthodontist before the video call consult.

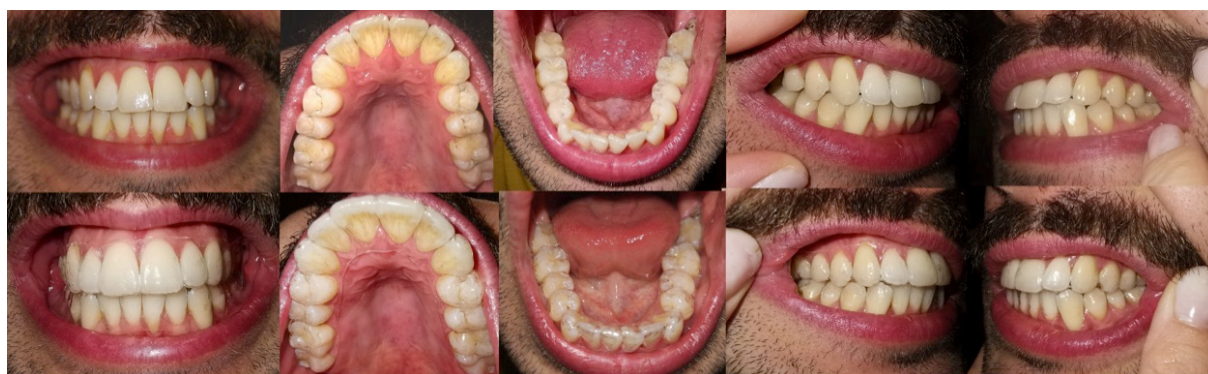

Figure 13. A collection of photographs made with the personal phone and sent to the orthodontist before the orthodontic consult by a patient with and without his clear aligners (Allineatori Sorridi®).

Discussion

The advent of the Coronavirus pandemic shocked the entire world community, which had to rapidly change its daily lives while the scientific community and the medical class were facing the emergency from a health point of view [7-10]. Dentists, even if aware of the characteristics of the virus and the prevention measures necessary to contain the infection and avoid the risk of infection, in the absence of adequate individual protective devices and guidelines capable of ensuring safety for themselves, for their coworkers and for the patients themselves had to close their dental offices remaining available only for non-differible emergencies [11,12]. The orthodontics then fell within the non-urgent dental branches and monthly checks on patients were cancelled [13,14]. Telemedicine from which teledentistry originates, and by definition teleorthodontics, although it is not a particularly widespread diagnosis and control strategy and is reserved only for certain categories of patients and situations, in this situation can be a winning tool to not lose sight of the patient under orthodontic therapy [15].

Patients enthusiastically adhered to the possibility of being remotely checked and although the quality of their photos (Figures 11 to 13), despite repeated attempts, has not always been excellent the time when they were checked by video call were very useful to check their oral health condition, schedule the future interventions to be done, reassure the patient that no major harm had occurred and motivated him to continue orthodontic therapy.

One of the most frequently encountered situations during orthodontic treatment is the gingival inflammation linked to an increase in plaque retention for inadequate oral hygiene [16]. The latest scientific literature results show that invisible aligners are better tolerated from a periodontal point of view. Thus, their use should be recommended in patients with recurrent gingivitis [17]. In this study, the presence of dental plaque and gum inflammation was recorded in several cases, but most of the subjects in all three groups showed acceptable oral conditions and none apparently had visible unknown carious lesions. Group A showed higher percentages of gum inflammation (27%) and dental plaque (16%) compared to the other two groups. This study confirms the better response of gingival tissues to clear aligners that show lower percentages of gum inflammation (13%) and dental plaque (6%). Information on oral hygiene techniques needed for proper oral health maintenance [18] was reiterated during the video check and critical areas for some patients were highlighted.

Orthodontic therapies using fixed devices are inevitably subject to inconveniences related to the breakage of their components that cause a discontinuity in therapy often and discomfort in the patient [19]. Cases with fixed therapies (Group A) have been quite stable (65%), there has not been a great advance in therapy (59% of patients remained stable), but not a major deterioration, although the detachment of brackets (22%) and loss of ligatures (14%) have contributed to the onset of some discomfort and pain. Detachment of brackets and loss of ligatures is a very frequent occurrence in orthodontic practice and is a factor that makes orthodontic therapy unstable and slows its progress by lengthening overall duration of treatment [20].

Orthodontic therapies based on removable devices are also not exempt from accidents and complications related to the breakage of the device itself [21]. Removable devices (Group B) are certainly very safe for children given the non-significant presence of accidents that have compromised their use and the type of discomfort reported by patients. Some removable devices are accepted with difficulty by younger patients, especially at the beginning of therapy, so checks with the orthodontist and parents' motivational support are very important [22]. The pain sometimes accompanies the initial stages of orthodontic treatment with removable appliances that creates doubts and anxiety [23]. Pain can be the manifestation of oral injuries caused by the rubbing of the orthodontic device or its pressure on oral mucous [24] but also be the manifestation of more complex symptomatic situations that emerge with orthodontic treatment and that would require a diagnostic deepening [25]. Assessing these aspects with remote controls is complicated. Pain during orthodontic treatment that arises at specific stages of device activation, somehow predictable in advance, can be treated pharmacologically safely and effectively [26].

In our study, some patients from Groups A and B reported a succession of symptoms related to orthodontic therapy that were very common but with overall low rates: 35% in Group A and 32% in Group B. In accordance with what other authors have already said [27,28], in our study, orthodontic therapies with invisible aligners (Group C) are much more comfortable than those with other mobile or fixed devices, as there are no reports of discomfort or pain.

Current literature guidelines [29,30] in the comparison between invisible aligners and traditional orthodontic devices propose a less enthusiastic view of clear aligners because although their effectiveness even in moderate complex cases is recognized, they would not be superior in terms of long-term stability of the result and would be more inefficient in correcting antero-posterior and vertical malocclusions [31]. In our study, in accordance with what is stated in the literature [32], treatments with clear aligners progress faster. Altogether, the progress of orthodontic therapy is better (51% of improved dental alignment compared to 27% of improved dental alignment in Group A) as it was possible, in cases without intermediate stripping or

addition/removal of attachments, to send the aligners to patients who have replaced themselves the old aligners with new ones.

Cases where a system without attachments and with divot (Sorriddi Aligners) were used allowed progress with therapy regularly without even the risk of detachment of attachments. This event occurred, in a not insignificant percentage (23%), in those cases with systematic aligners that use bonded attachments. From our experience in this research, we agree that the presence of attachments poses many problems in fitting the invisible aligner to the teeth [33] and given the evolution of the systematics with invisible aligners without attachments their presence, decided during the set-up, should be limited to the necessary as other solutions, such as divots, show great effectiveness in guiding the orthodontic movement and make the treatment easier and smooth [34]. This study's data allow us to define orthodontics as a safe specialist branch that, despite a period of almost two months without a check done in person, did not report serious consequences for the patient with any type of orthodontic therapy in progress.


Patients who reported problems such as ligature loss, detachment of brackets and other incidents during this period were told that they would be treated for these emergencies as soon as we could resume orthodontic activity. Patients who reported ailments such as pain or discomfort were asked to suspend therapy for a few days if the device was removable or provided with orthodontic wax in fixed therapy cases.





It is difficult to replace teleorthodontic checks with the evaluations carried out with live objective clinical examinations. Furthermore, remotely viewing radiographs such as an orthopantomics, lateral teleradiographies or more accurate examinations such as TC DentaScan or CBCT (cone beam computer tomography) make difficult initial assessments on the need for complex treatments such as extractions or evaluations on the importance of certain radiographic elements [35,36]. Even if teleorthodontics definitely applies best to patients who have already started therapy as long as it is limited to a reasonable amount of time, overcome this global emergency, the creation of teleorthodontic systems organized would be a precious clinical advance. The standardization of protocols for its use would make this method very useful in the control of patients unable to make regular checks (disabled, sick, frequent travelers, residing in rural areas distant from the dental office).

Conclusion

The Coronavirus pandemic has brought to life the importance of having technologies to carry out visits and checks to orthodontic patients at a distance and low impact emergency therapies. The possibility to dialogue with the patient and to view his intra-oral situation through mobile technology is a strategy that can be adopted safely and effectively in emergency situations and routine when they want to do intermediate checks to the one in the studio or when the patient is forced for various reasons to skip a monthly appointment. Even if the orthodontist cannot be replaced by do-it-yourself orthodontic therapy, in cases where the clinical case allows it and the situation requires it, treatments with invisible aligners with few or nothing checks in dental chair (no attachments, divot mechanics), associated with remote teleorthodontic control, can be considered the future evolution of post-pandemic orthodontics: zero-emission aerosol, reduced social contact, risk of null contagion, agendas with fewer appointments.

Authors' Contributions

AP  0000-0001-5278-145X Conceptualization, Methodology, Investigation, Formal Analysis and Writing – Original Draft Preparation.

MC  0000-0001-8305-2241 Methodology and Writing – Review and Editing.
DG  0000-0003-3509-9955 Methodology and Writing – Review and Editing.
EB  0000-0002-5328-3580 Methodology and Writing – Review and Editing.
GG  0000-0002-6876-8839 Investigation and Writing – Review and Editing.

All authors declare that they contributed to critical review of intellectual content and approval of the final version to be published.

Financial Support

None.

Conflict of Interest

The authors declare no conflicts of interest.

References

- [1] Waller M, Stotler C. Telemedicine: a primer. *Curr Allergy Asthma Rep* 2018; 18(10):54. <https://doi.org/10.1007/s11882-018-0808-4>
- [2] Burke BL Jr, Hall RW. Telemedicine: pediatric applications. *Pediatrics* 2015; 136(1):e293-308. <https://doi.org/10.1542/peds.2015-1517>
- [3] Estai M, Kanagasigam Y, Tennant M, Bunt S. A systematic review of the research evidence for the benefits of teledentistry. *J Telemed Telecare* 2018; 24(3):147-56. <https://doi.org/10.1177/1357633X16689433>
- [4] Kotantoula G, Haisraeli-Shalish M, Jerrold L. Teleorthodontics. *Am J Orthod Dentofacial Orthop* 2017; 151(1):219-21. <https://doi.org/10.1016/j.ajodo.2016.10.012>
- [5] Putrino, A., Raso, M., Magazzino, C., Galluccio G. Coronavirus (COVID-19) in Italy: knowledge, management of patients and clinical experience of Italian dentists during the spread of contagion. *BMC Oral Health* 2020; 20:200. <https://doi.org/10.1186/s12903-020-01187-3>
- [6] Caprioglio A, Pizzetti GB, Zecca PA, Fastuca R, Maino G, Nanda R. Management of orthodontic emergencies during 2019-NCOV. *Prog Orthod* 2020; 21(1):10. <https://doi.org/10.1186/s40510-020-00310-y>
- [7] Steffens I. A hundred days into the coronavirus disease (COVID-19) pandemic. *Euro Surveill* 2020; 25(14):2000550. <https://doi.org/10.2807/1560-7917.ES.2020.25.14.2000550>
- [8] Chatterjee P, Nagi N, Agarwal A, Das B, Banerjee S, Sarkar S, et al. The 2019 novel coronavirus disease (COVID-19) pandemic: a review of the current evidence. *Indian J Med Res* 2020; 151(2&3):147-59. https://doi.org/10.4103/ijmr.IJMR_519_20
- [9] Sjödin H, Wilder-Smith A, Osman S, Farooq Z, Rocklöv J. Only strict quarantine measures can curb the coronavirus disease (COVID-19) outbreak in Italy, 2020. *Euro Surveill* 2020; 25(13):2000280. <https://doi.org/10.2807/1560-7917.ES.2020.25.13.2000280>
- [10] Sifuentes-Rodríguez E, Palacios-Reyes D. COVID-19: The outbreak caused by a new coronavirus. *Bol Med Hosp Infant Mex* 2020; 77(2):47-53. <https://doi.org/10.24875/BMHIM.20000039>
- [11] Peng X, Xu X, Li Y, Cheng L, Zhou X, Ren B. Transmission routes of 2019-nCoV and controls in dental practice. *Int J Oral Sci* 2020; 12(1):9. <https://doi.org/10.1038/s41368-020-0075-9>
- [12] Coulthard P. Dentistry and coronavirus (COVID-19) - moral decision-making. *Br Dent J* 2020; 228(7):503-5. <https://doi.org/10.1038/s41415-020-1482-1>
- [13] Lindauer SJ. COVID-19 affecting our world. *Angle Orthod*; 90(3):467. <https://doi.org/10.2319/0003-3219-90.3.467>
- [14] Suri S, Vandersluis YR, Kochhar AS, Bhasin R, Abdallah MN. Clinical orthodontic management during the COVID-19 pandemic. *Angle Orthod* 2020. <https://doi.org/10.2319/033120-236.1>
- [15] Dunbar AC, Bearn D, McIntyre G. The influence of using digital diagnostic information on orthodontic treatment planning - a pilot study. *J Healthc Eng* 2014; 5(4):411-27. <https://doi.org/10.1260/2040-2295.5.4.411>
- [16] Verrusio C, Iorio-Siciliano V, Blasi A, Leuci S, Adamo D, Nicolò M. The effect of orthodontic treatment on periodontal tissue inflammation: a systematic review. *Quintessence Int* 2018; 49(1):69-77. <https://doi.org/10.3290/j.qi.a39225>
- [17] Jiang Q, Li J, Mei L, Du J, Levrini L, Abbate GM, et al. Periodontal health during orthodontic treatment with clear aligners and fixed appliances: a meta-analysis. *J Am Dent Assoc* 2018; 149(8):712-720.e12. <https://doi.org/10.1016/j.adaj.2018.04.010>
- [18] Nammi K, Starke EM, Ou SS, et al. The effects of use of a powered and a manual home oral hygiene regimen on plaque and gum health in an orthodontic population. *J Clin Dent* 2019; 30(Spec No A):A1-A8.
- [19] Sachan A, Chaturvedi TP. Emergency orthodontic care. *Int J Orthod Milwaukee* 2011; 22(4):21-5.

- [20] Dowsing P, Murray A, Sandler J. Emergencies in orthodontics. Part 1: Management of general orthodontic problems as well as common problems with fixed appliances. *Dent Update* 2015; 42(2):131-40. <https://doi.org/10.12968/denu.2015.42.2.131>
- [21] Dowsing P, Murray A, Sandler J. Emergencies in orthodontics. Part 2: Management of removable appliances, functional appliances and other adjuncts to orthodontic treatment. *Dent Update* 2015; 42(3):221-8. <https://doi.org/10.12968/denu.2015.42.3.221>
- [22] Arreghini A, Trigila S, Lombardo L, Siciliani G. Objective assessment of compliance with intra- and extraoral removable appliances. *Angle Orthod* 2017; 87(1):88-95. <https://doi.org/10.2319/020616-104.1>
- [23] Banerjee S, Banerjee R, Shenoy U, Agarkar S, Bhattacharya S. Effect of orthodontic pain on quality of life of patients undergoing orthodontic treatment. *Indian J Dent Res* 2018; 29(1):4-9. https://doi.org/10.4103/ijdr.IJDR_113_16
- [24] Baricevic M, Mravak-Stipetic M, Majstorovic M, Baranovic M, Baricevic D, Loncar B. Oral mucosal lesions during orthodontic treatment. *Int J Paediatr Dent* 2011; 21(2):96-102. <https://doi.org/10.1111/j.1365-263X.2010.01078.x>
- [25] Racich MJ. Occlusion, temporomandibular disorders, and orofacial pain: an evidence-based overview and update with recommendations. *J Prosthet Dent* 2018; 120(5):678-685. <https://doi.org/10.1016/j.prosdent.2018.01.033>
- [26] Monk AB, Harrison JE, Worthington HV, Teague A. Pharmacological interventions for pain relief during orthodontic treatment. *Cochrane Database Syst Rev* 2017; 11(11):CD003976. <https://doi.org/10.1002/14651858.CD003976.pub2>
- [27] Allereau B, Sabouni W. Perception of pain in orthodontic treatment with thermoformed aligners. *Orthod Fr* 2017; 88(4):383-9. <https://doi.org/10.1051/orthodfr/2017028>
- [28] Shen H, Shao S, Zhang J, et al. Fixed orthodontic appliances cause pain and disturbance in somatosensory function. *Eur J Oral Sci* 2016; 124(1):26-32. <https://doi.org/10.1111/eos.12234>
- [29] Tamer İ, Öztaş E, Marşan G. Orthodontic treatment with clear aligners and the scientific reality behind their marketing: a literature review. *Turk J Orthod* 2019; 32(4):241-6. <https://doi.org/10.5152/TurkJOrthod.2019.18083>
- [30] Ke Y, Zhu Y, Zhu M. A comparison of treatment effectiveness between clear aligner and fixed appliance therapies. *BMC Oral Health* 2019; 19(1):24. <https://doi.org/10.1186/s12903-018-0695-z>
- [31] Kassam SK, Stoops FR. Are clear aligners as effective as conventional fixed appliances?. *Evid Based Dent* 2020; 21(1):30-1. <https://doi.org/10.1038/s41432-020-0079-5>
- [32] Pithon MM, Baião FCS, Sant Anna LIDA, Paranhos LR, Cople Maia L. Assessment of the effectiveness of invisible aligners compared with conventional appliance in aesthetic and functional orthodontic treatment: a systematic review. *J Investig Clin Dent* 2019; 10(4):e12455. <https://doi.org/10.1111/jicd.12455>
- [33] Mantovani E, Castroflorio E, Rossini G, Garino F, Cugliari G, Deregibus A, et al. Scanning electron microscopy analysis of aligner fitting on anchorage attachments. *J Orofac Orthop* 2019; 80(2):79-87. <https://doi.org/10.1007/s00056-018-00167-1>
- [34] Hennessy J, Al-Awadhi EA. Clear aligners generations and orthodontic tooth movement. *J Orthod* 2016; 43(1):68-76. <https://doi.org/10.1179/1465313315Y.0000000004>
- [35] Putrino A, Impellizzeri A, Pavese L, Barbato E, Galluccio G. Orthodontic treatment and third molars development: longitudinal study on radiographs. *Dental Cadmos* 2019; 87:558-70.
- [36] Putrino A, Leonardi RM, Barbato E, Galluccio G. The association between ponticulus posticus and dental agenesis: a retrospective study. *Open Dent J* 2018; 12:510-9. <https://doi.org/10.2174/1874210601812010510>