




## Clinical and Radiographic Sequelae in Primary Teeth due to Dental Trauma

Thaynara de Souza Lopes<sup>1</sup>, Gabriela Cristina Santin<sup>2</sup>, Laís Albuquerque Marengoni<sup>3</sup>, Jessica Behrens Crispim<sup>4</sup>, Larissa Colepicolo Ceron<sup>5</sup>, Marina de Lourdes Calvo Fracasso<sup>6</sup>


<sup>1</sup>Post-Graduation Program, School of Dentistry, State University of Maringá, Maringá, PR, Brazil.  0000-0002-5113-571X

<sup>2</sup>Department of Pediatric Dentistry, School of Dentistry, State University of Maringá, Maringá, PR, Brazil.  0000-0003-0216-0502

<sup>3</sup>Private Practice, Maringá, PR, Brazil.  0000-0002-4577-3045

<sup>4</sup>Post-Graduation Program, School of Dentistry, State University of Maringá, Maringá, PR, Brazil.  0000-0001-8246-6303

<sup>5</sup>Private Practice, Maringá, PR, Brazil.  0000-0003-1173-706X

<sup>6</sup>Department of Pediatric Dentistry, School of Dentistry, State University of Maringá, Maringá, PR, Brazil.  0000-0003-1112-3156

Author to whom correspondence should be addressed: Thaynara de Souza Lopes, Programa de Pós-Graduação em Odontologia, Universidade Estadual de Maringá, Av. Mandacarú, 1550, Maringá, PR, Brazil. 87080-000. Phone: +55 43 99908-5599. E-mail: [thaynaralopes9@gmail.com](mailto:thaynaralopes9@gmail.com).

Academic Editors: Alessandro Leite Cavalcanti and Wilton Wilney Nascimento Padilha

Received: 20 December 2018 / Accepted: 08 May 2019 / Published: 17 May 2019

### Abstract

**Objective:** To evaluate the presence of clinical and radiographic sequelae in primary teeth affected by dental trauma and its association with age at the time of trauma in children attended at a Public Higher Education Institution. **Material and Methods:** This is a longitudinal clinical study, in which 229 patients with history of dental trauma in primary teeth were examined, totaling 390 traumatized teeth. Relative frequency analysis was used, and for associations, the Chi-square test was used to verify the relationship of age at the time of trauma with variables such as type of trauma. **Results:** The most prevalent age group was over 24 months, and fall from own height as the main etiological factor; 71.0% of traumas had involvement of 2 teeth, 9.5% had history of anterior trauma and 66.6% of traumas involved supporting tissues. Regarding the type of injury to dental tissue, the most prevalent was enamel fracture (58.3%) and to periodontium, lateral dislocation (30.8%). Children older than two years had less trauma related to dental tissue ( $p < 0.01$ ), higher number of injuries to the periodontium ( $p = 0.03$ ); and most of them did not present extra-oral changes associated with trauma ( $p = 0.01$ ). During the 12-month period, 325 teeth were examined, and the most frequent clinical sequelae observed was crown discoloration. In the radiographic evaluation, inflammatory root resorption was the most prevalent. **Conclusion:** Children older than two years presented more injuries to the periodontium. After 12 months, the main clinical sequelae observed was enamel discoloration and the main radiographic sequelae was inflammatory root resorption.

**Keywords:** Dental Care for Children; Tooth, Deciduous; Tooth Injuries; Tooth Fractures.

## Introduction

Trauma to primary teeth is an aesthetic-functional and psychological problem and can be considered an emergency situation, not only due to dental problems and their future repercussions, but also due to the emotional involvement of the child and his / her families [1-6]. Currently, they are considered a public health problem, not only due to their frequency, which can range from 4% to 33% [3], but also by the negative impact it generates on the quality of life of individuals [7-9].

The number of studies available in literature is quite significant in relation to trauma in permanent dentition [1,2,5]; however, there is lack of longitudinal follow-ups on traumas in primary teeth, especially with a focus on injuries to supporting tissues, type of trauma, and possible sequelae resulting from such trauma.

Scientific researches have pointed to some risk factors for dental trauma in children, including age at the moment of trauma, concluding that this risk increases by up to two times when the child starts walking, between one year and a half and three years of age due to the motor coordination immaturity, leading to falls [10,11].

Among the types of trauma in primary teeth, dislocations occur more frequently, since the bone tissue in the child has larger medullary spaces, resulting in greater plasticity, which favors tooth dislocation when compared to fractures [9,12,13]. As for the most affected teeth, the highest prevalence is for the upper incisors, especially central incisors [11,14,15].

One of the major challenges reported in scientific studies is the adherence of family members to the treatment and clinical and radiographic follow-up of patients involved in dental trauma, since the demand for dental care for children suffering from dental trauma is still neglected, especially for minor injuries. In relation to severe trauma involving soft tissues and teeth, care is often restricted to immediate treatment, with little involvement of parents in follow-up visits [11].

Thus, the aim of the present study was to evaluate the appearance of clinical and radiographic sequelae in primary teeth affected by dental trauma and its association with age at the moment of trauma.

## Material and Methods

### Study Design

This is a longitudinal clinical study, in which the first clinical and radiographic evaluation after traumatic injury was carried out, followed by re-evaluations of traumatized primary teeth, also through clinical and radiographic evaluation.

### Sample

The sample was composed of 299 children attended at the Dental Clinic of the State University of Maringá, Paraná, Brazil, with history of trauma involving primary teeth in the period from 2012 to 2017, totaling 390 traumatized teeth. Children with mean age of  $3.4 \pm 1.1$  years who sought the Dental Clinic for dental trauma in primary teeth were included. Patients who did not return the follow-up visits were excluded from the study.

## Data Collection

At the first visit, variables related to gender, age, trauma etiology (falling from own height, collisions, accidents and others); involved teeth, number of teeth affected, previous presence of dental trauma, presence of pain (spontaneous, chewing or thermal changes), injuries to soft tissues (intra- and extra-oral), type of traumatic injury (dental or supporting tissue injury) and time elapsed to first care were collected. Then, through a single dentist with extensive clinical experience and previously calibrated, traumatic injuries of primary teeth were evaluated through clinical and radiographic examination, and if one tooth had an injury in dental and supporting tissue, both were collected for analysis, and immediate treatment was performed [16].

In a second moment, patients were rescheduled and 325 traumatized teeth were evaluated again by the same dentist who performed the initial evaluation through clinical and radiographic examination so that possible trauma sequelae were diagnosed and, if necessary, treated in a timely manner. Re-assessment visits were scheduled one week after trauma, 3-4 weeks, 6-8 weeks, 6 months, 1 year and, during each subsequent year until tooth eruption [17].

Clinical and radiographic sequelae of primary teeth were duly analyzed following the guide of dental trauma published in 2012 [16] considering the following aspects: Clinical signs: absence of clinical signs; enamel discoloration, abscess, fistula and mobility. Radiographic signs: absence of radiographic alteration, periapical lesion, inflammatory root resorption, pulpal calcification, ankylosis. A single dental element could present more than one postoperative sequela.

## Data Analysis

Quantitative data were analyzed through the IBM SPSS Statistics Software, version 23 (IBM Corp., Armonk, NY, USA), obtaining the relative frequency of the previously cited variables and the association of age at the time of trauma ( $\leq 2$  years or  $> 2$  years) with gender, history of trauma, number of affected teeth, spontaneous pain, chewing pain, reaction to thermal change, intra- or extra-oral changes and dental and supportive tissue injuries using the Chi-square test ( $p < 0.05$ ). In the re-evaluation, relative frequency analysis was performed for clinical and radiographic sequelae caused by trauma in supporting tissues.

## Ethical Aspects

This research was approved by the Ethics Committee for Research Involving Human Beings of the State University of Maringá (Protocol No. 1,144,717). All parents / guardians were informed of the study objectives and signed the Free and Informed Consent Form.

## Results

The male gender was the most affected with 60.3%, and the most prevalent age at the time of trauma was 24-35 months (35.1%), with fall from own height being the main etiological factor (77.9%).

The upper dental arch was the most affected by dental traumas (96.2%) and the upper central incisors the most traumatized teeth (82.8%). Most patients (71.0%) had at least 2 teeth affected by the traumatic injury, and about 9.5% had previously dental trauma. When assessing pain after trauma, 27.2% had spontaneous pain, 42.6% had chewing pain and 9.7% had reaction to thermal change. Regarding soft tissue evaluation, 20.8% of patients had some type of extra-oral alteration and 39.2% had some intra-oral alteration, with lip cut being the most frequent (42.4%) followed by upper lip laceration (15.9%).

Figures 1 to 3 show the prevalence of trauma in children included in the study, as well as the treatment offered at the time of trauma. It was found that 66.6% of traumas involved supporting tissue and 33.8% dental tissues. Regarding the type of tooth injury, the most prevalent was enamel fracture (58.3%) and lateral dislocation (30.8%). In most traumatized teeth (74.1%), only clinical and radiographic follow-up was indicated as immediate treatment, followed by tooth extraction (7.9%) and restoration (7.4%).

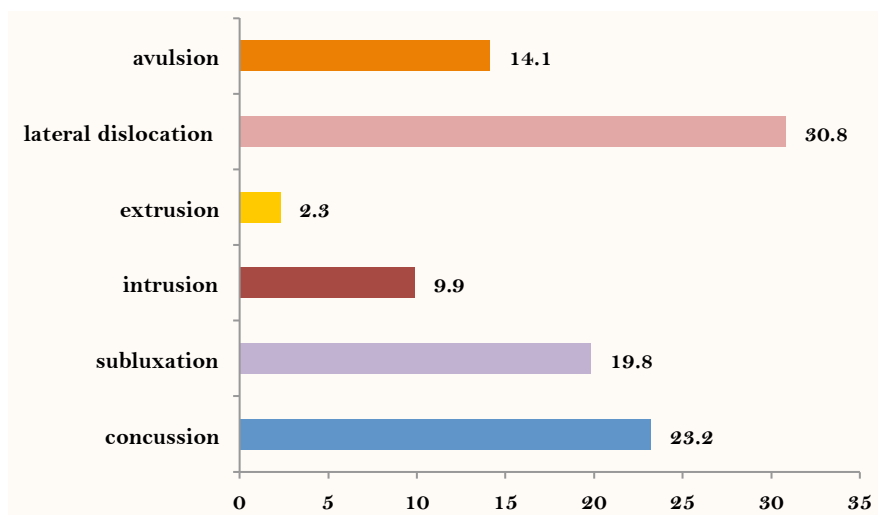


Figure 1. Distribution of injuries to supporting tissues.

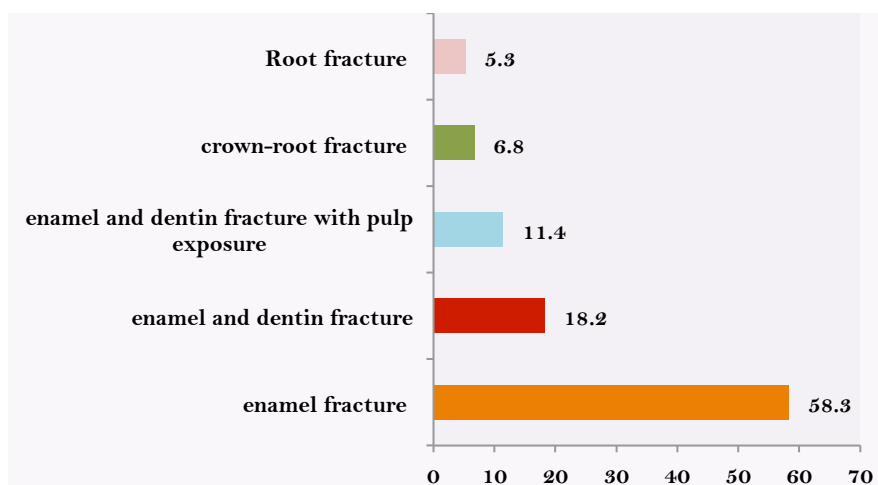


Figure 2. Distribution of injuries to dental tissues.

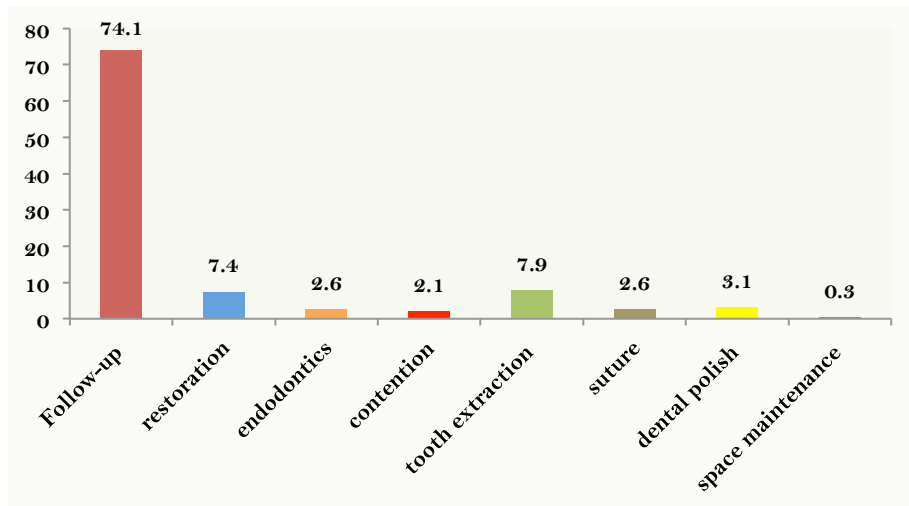


Figure 3. Immediate treatment performed.

There was association between extra-oral alteration ( $p=0.01$ ), prevalence of dental injuries ( $p<0.01$ ) and supporting tissue ( $p=0.03$ ) in relation to age at the time of trauma (Table 1).

Table 1. Characteristics related to trauma according to two age groups of occurrence.

| Variables                    | ≤2 Years | >2 Years | p-value |
|------------------------------|----------|----------|---------|
| Gender                       |          |          |         |
| Female                       | 50       | 105      | 0.304   |
| Male                         | 83       | 152      |         |
| Previous History of Trauma   |          |          |         |
| Yes                          | 14       | 23       | 0.369   |
| No                           | 119      | 234      |         |
| More Than One Tooth Affected |          |          |         |
| Yes                          | 94       | 183      | 0.501   |
| No                           | 39       | 74       |         |
| Spontaneous Pain             |          |          |         |
| Yes                          | 31       | 75       | 0.132   |
| No                           | 102      | 182      |         |
| Chewing Pain                 |          |          |         |
| Yes                          | 62       | 104      | 0.145   |
| No                           | 71       | 153      |         |
| Reaction to Thermal Changes  |          |          |         |
| Yes                          | 16       | 22       | 0.179   |
| No                           | 117      | 235      |         |
| Extra Oral Alteration        |          |          |         |
| Yes                          | 19       | 62       | 0.015   |
| No                           | 114      | 195      |         |
| Intra Oral Alteration        |          |          |         |
| Yes                          | 50       | 103      | 0.358   |
| No                           | 83       | 154      |         |
| Dental Injury                |          |          |         |
| Yes                          | 58       | 74       | 0.003   |
| No                           | 75       | 183      |         |
| Injury to Supporting Tissues |          |          |         |
| Yes                          | 81       | 182      | 0.032   |
| No                           | 52       | 75       |         |

In the preservation of traumatized teeth, 325 teeth were evaluated, which represented 83.3% of total teeth, most of them (67.1%) underwent re-evaluation within a period of up to 12 months after traumatic injury. Of evaluated teeth, 75.4% were still present in the dental arch, and 66.6% did not present any clinical signs indicative of sequelae due to dental trauma. However, 144 teeth presented clinical sequelae, as seen in Table 2.

**Table 2. Characteristics related to trauma of primary teeth according to clinical sequelae.**

| Type of Trauma      | Absence of Clinical Signs<br>N (%) | Crown Discoloration<br>N (%) | Abscess<br>N (%) | Fistula<br>N (%) | Mobility<br>N (%) |
|---------------------|------------------------------------|------------------------------|------------------|------------------|-------------------|
| Concussion          | 33 (71.7)                          | 11 (23.9)                    | 0 (0.0)          | 2 (4.3)          | 0 (0.0)           |
| Subluxation         | 26 (76.5)                          | 7 (20.6)                     | 1 (2.9)          | 0 (0.0)          | 0 (0.0)           |
| Intrusion           | 8 (61.5)                           | 2 (15.4)                     | 0 (0.0)          | 1 (7.7)          | 2 (15.4)          |
| Extrusion           | 0 (0.0)                            | 0 (0.0)                      | 0 (0.0)          | 0 (0.0)          | 0 (0.0)           |
| Lateral Dislocation | 28 (57.1)                          | 15 (30.6)                    | 0 (0.0)          | 1 (2.0)          | 5 (10.2)          |
| Avulsion            | 2 (100.0)                          | 0 (0.0)                      | 0 (0.0)          | 0 (0.0)          | 0 (0.0)           |
| Total               | 97 (67.4)                          | 35 (24.3)                    | 1 (0.7)          | 4 (2.8)          | 7 (4.8)           |

At radiographic examination, 79.4% did not have any type of pathological alteration; however, in 145 traumatized teeth, some alterations were diagnosed (Table 3).

**Table 3. Characteristics related to trauma of primary teeth according to radiographic sequelae.**

| Type of Trauma      | Absence of Radiographic<br>N (%) | Periapical Injury<br>N (%) | Pulp Calcification<br>N (%) | Inflammatory Root Resorption<br>N (%) | Ankylosis<br>N (%) |
|---------------------|----------------------------------|----------------------------|-----------------------------|---------------------------------------|--------------------|
| Concussion          | 40 (87.0)                        | 2 (4.3)                    | 1 (2.2)                     | 3 (6.5)                               | 0 (0.0)            |
| Subluxation         | 27 (79.4)                        | 1 (2.9)                    | 1 (2.9)                     | 3 (8.8)                               | 2 (5.9)            |
| Intrusion           | 8 (61.5)                         | 1 (7.7)                    | 0 (0.0)                     | 4 (30.8)                              | 0 (0.0)            |
| Extrusion           | 0 (0.0)                          | 0 (0.0)                    | 0 (0.0)                     | 0 (0.0)                               | 0 (0.0)            |
| Lateral Dislocation | 36 (73.5)                        | 4 (8.2)                    | 2 (4.1)                     | 7 (14.3)                              | 0 (0.0)            |
| Avulsion            | 2 (100.0)                        | 0 (0.0)                    | 0 (0.0)                     | 0 (0.0)                               | 1 (0.0)            |
| Total               | 113 (77.9)                       | 8 (5.5)                    | 4 (2.8)                     | 17 (11.7)                             | 3 (2.1)            |

Still in the second moment, 80.9% of evaluated teeth remained in clinical and radiographic follow-up, and 17.6% needed some type of intervention, among them: restoration, endodontics, extraction, among others and in 1.8%, the permanent successor had already erupted.

## Discussion

In literature, there are differences in results regarding the prevalence of traumatic injuries in relation to gender. Some reports have found no statistical difference between them [18-20], and other authors, like those of the present study, have shown that males suffer a greater number of traumatic injuries, probably due to the greater involvement of boys in physical activities [8,12]. In relation to age at the time of trauma, this study showed higher frequency in the age group of 24-35 months, an age coincident with the stage in which motor coordination begins to develop, as well as lack of protection instinct, leading to falls [3,10,11], especially those from own height, as demonstrated in scientific literature [11,12,18,21] and in the present study.

Studies have shown significant relationship between age and the appearance of sequelae in primary teeth due to the stage of development of deciduous roots at the moment of trauma, since the approximate closing time of deciduous incisor roots occurs close to the age of 2 years, while resorption begins at approximately 5 years [12,19]. In both cases mentioned above, apices are open with larger vascular-nervous bundles entering the apical foramen of the root; therefore, the highest incidence of sequelae problems is observed in the age group of 2-3-years, where apices are more mature [12,19].

The teeth most affected by traumatic injuries are the central incisors (82.8%), especially the upper teeth, according to literature [11,14,15,22]. It is noteworthy that during anamnesis, 9.5% of patients reported that they had suffered previous trauma and 71% of patients had at least 2 teeth affected by traumatic injury. A study conducted with Brazilian children also showed that 16.9% of the sample had history of dental trauma [12], as confirmed by the systematic review published in 2019, which concluded that patients with previous dental trauma are at greater risk of new trauma [23], indicating greater need for clinical and radiographic follow-up, because clinical practice shows that the appearance of sequelae is higher in teeth with recurrent trauma.

In this study, injuries involving a greater number of children were, in relation to the tooth, enamel and supporting tissue fractures and lateral dislocation. The fact of identifying a greater number of injuries to supporting tissues is attributed by many authors to the fact that the bone tissue in children presents greater plasticity, with larger medullary spaces, propitiating lateral dislocation when compared to fractures [9,12,24]. It was observed in this study that children older than two years had fewer lesions compromising the crown structure and greater number of injuries to supporting tissues, corroborating literature results.

A significant and quite positive finding of this study was that 74.1% of traumatized anterior primary teeth did not present any significant injury at the moment of trauma, requiring only clinical and radiographic follow-up and after the 12-month follow-up, 80.9% tooth and periodontium maintained complete integrity.

The scientific literature points out that many trauma complications, both in primary and permanent teeth are due to the lack of immediate care and control of possible complications, performed in the dental office by the professional. A study carried out in 2014, associating level of root maturity with types of trauma, concluded that time greater than 180 days is necessary for sequelae to be diagnosed in primary teeth involved in trauma, so maintaining a follow-up protocol for traumatized teeth is of paramount importance; however, post - trauma sequelae can be diagnosed even after more than 4 years of follow-up [25].

In the present study, in the clinical and radiographic follow-up of traumatized teeth of up to 12 months, it was observed that the main clinical sequelae found in primary teeth was crown discoloration (24.3%), data similar to other reports in literature [25,26], which also observed discoloration as the most frequent sequela, and often trauma is only noticed by parents due to the aesthetic change of tooth color. However, there are controversies regarding the appropriate

treatment for primary teeth that have changed crown color, since the traumatized primary tooth can become rosy, yellowish or grayish [24,26-28].

Some changes are physiological responses to injuries, while others may indicate a pathological process that requires treatment [24,26,27]. Rosy tooth indicates internal reabsorption and usually needs to be extracted; the yellowish tooth usually indicates pulpal calcification, rarely developing pulp necrosis, requiring no treatment, and its exfoliation occurs normally [24,26,27]. Grayish discolorations are the most controversial in relation to treatment, and may be related to slight pulp changes, that is, evidence of periapical inflammation in 1 to 2 months after trauma, and coloration may disappear in a few weeks; however, if the grayish color remains, and the normality of the periodontal structures is verified, follow-up and further examinations must be performed at 6 and 12 months [24,26-28].

In the present study, the main traumatic injury that led to color change of traumatized teeth was lateral dislocation followed by concussion. According to previous report, dental lesion that causes crown fracture may have better prognosis than a tooth that receives a strong impact without crown fracture, since part of the impact energy dissipates when the crown is fractured, unlike what occurs when there is absorption of all energy by the tooth and supporting tissues [29]. Thus, the periodontium and the pulp of the traumatized tooth bear less impact if crown fracture occurs and therefore improves the prognosis for long-term tooth retention and pulp vitality maintenance [30,31].

The results of this study also indicated that the most frequent radiographic sequelae during prosthodontics was inflammatory root resorption (8.6%), also confirmed in another study [3]. Injuries that led to the greatest number of inflammatory root resorption were lateral and intrusive dislocations, because the rupture of the gingival insertion facilitates the infiltration of bacteria in periodontal tissues, which stimulates osteoclasts to induce inflammatory root resorption [29]. A literature review pointed out that for the treatment of dislocations, especially lateral dislocations, tooth repositioning increases the risk of pulpal necrosis, since the periodontal ligament may already be traumatized and edematous, increasing the already existing pressure on the vascular-nervous bundle of the tooth, increasing the chance of ischemia and necrosis [30].

Considering the above, knowing the risks of clinical and radiographic sequelae in traumatized primary teeth remains the objective of research in future longitudinal studies, and one of the challenges will be to increase the sample size and commitment of family members in posttraumatic control visits, since the consequences of trauma are often unpredictable, requiring periodic clinical and radiographic monitoring, and such consequences will depend on the degree of root apical dislocation, degree of alveolar injury, and stage of permanent tooth formation [21,31,32].

This study had some limitations such as the small sample size, short post-traumatic time, and difficulty in prosthodontics, since some patients did not attend the scheduled appointment, compromising the more precise analysis of statistical data and the association among variables under study. Therefore, every traumatic tooth should be monitored according to specific protocol, based on



scientific evidence, since the risks of clinical and radiographic sequelae are large and can generate several changes to primary teeth.

## Conclusion

Children older than two years had less trauma related to dental tissue, more injuries to the periodontium; and the majority did not present extra-oral alteration associated with trauma. At 12 months, the main clinical sequela observed was crown discoloration and the main radiographic sequela inflammatory root resorption.

**Authors' Contributions:** All authors contributed individually and significantly to the development of this article. TSL wrote and reviewed the manuscript, contributed to the intellectual conceptualization of the study and the entire research project. JBC reviewed the manuscript. LAM performed measurements for the assessments and outcome assessment analysis. LCC contributed to the intellectual conceptualization of the study and reviewed the manuscript. GCS performed the statistical analysis and reviewed the manuscript. MLCF performed measurements for the assessments, wrote and reviewed the manuscript.

**Financial Support:** This study was financed in part by the Coordenação de Aperfeiçoamento de Pessoal de Nível Superior - Brasil (CAPES) - Finance Code 001.

**Conflict of Interest:** The authors declare no conflicts of interest.

## References

- [1] Andreasen JO, Andreasen FM. Treatment of traumatic dental injuries. Shift in strategy. *Int J Technol Assess Health Care* 1990; 6(4):588-602.
- [2] Glendor U. Epidemiology of traumatic dental injuries – A 12 year review of the literature. *Dent Traumatol* 2008; 24(6):603-11. <https://doi.org/10.1111/j.1600-9657.2008.00696.x>
- [3] Mendoza-Mendoza A, Iglesias-Linares A, Yañez-Vico RM, Abalos-Labruzzi C. Prevalence and complications of trauma to the primary dentition in a subpopulation on Spanish children in southern Europe. *Dent Traumatol* 2015; 31(2):144-9. <https://doi.org/10.1111/edt.12147>
- [4] Jung CP, Tsai AI, Chen CM. A 2-year retrospective study of pediatric dental emergency visits at a hospital emergency center in Taiwan. *Biomed J* 2016; 39(3):207-13. <https://doi.org/10.1016/j.bj.2016.06.004>
- [5] Guedes-Pinto AC. *Odontopediatria*. 8<sup>th</sup> ed. São Paulo: Santos, 2010. [In Portuguese]
- [6] ElKarmi RF, Hamdan MA, Rajab LD, Abu-Ghazaleh SB, Sonbol HN. Prevalence of traumatic dental injuries and associated factors among preschool children in Amman, Jordan. *Dent Traumatol* 2015; 31(6):487-92. <https://doi.org/10.1111/edt.12183>
- [7] Jorge KO, Moysés SJ, Ferreira e Ferreira E, Ramos-Jorge ML, de Araújo Zarzar PM. Prevalence and factors associated to dental trauma in infants 1-3 years of age. *Dent Traumatol* 2009; 25(2):185-9. <https://doi.org/10.1111/j.1600-9657.2008.00730.x>
- [8] Robson F, Jorge MLR, Bendo CB, Vale MP, Paiva SM, Pordeus IA. Prevalence and determining factors of traumatic injuries to primary teeth in preschool children. *Dent Traumatol* 2009; 25(1):118-22. <https://doi.org/10.1111/j.1600-9657.2008.00725.x>
- [9] Zhang Y, Zhu Y, Su W, Zhou Z, Jin Y, Wang X. A retrospective study of pediatric traumatic dental injuries in Xi'an, China. *Dent Traumatol* 2014; 30(3):211-5. <https://doi.org/10.1111/edt.12075>
- [10] Flores MT. Traumatic injuries in the primary dentition. *Dent Tramamol* 2002; 18(6):287-98. <https://doi.org/10.1034/j.1600-9657.2002.00153.x>
- [11] Atabek D, Alaçam A, Aydıntug I, Konakoglu G. A retrospective study of traumatic dental injuries. *Dent Traumatol* 2014; 30(2):154-61. <https://doi.org/10.1111/edt.12057>
- [12] Amorim LFG, Costa LRRS, Estrela C. Retrospective study of traumatic dental injuries in primary teeth in a Brazilian specialized pediatric practice. *Dent Traumatol* 2011; 27(5):368-73. <https://doi.org/10.1111/j.1600-9657.2011.01011.x>
- [13] Lauridsen E, Blanche P, Yousaf N, Andreasen JO. The risk of healing complications in primary teeth with extrusive or lateral luxation - A retrospective cohort study. *Dent Traumatol* 2017; 33(4):307-16. <https://doi.org/10.1111/edt.12340>

- [14] Avsar A, Topaloglu B. Traumatic tooth injuries to primary teeth of children aged 0-3 years. *Dent Traumatol* 2009; 25(3):323-7. <https://doi.org/10.1111/j.1600-9657.2008.00695.x>
- [15] Ritwik P, Massey C, Hagan J. Epidemiology and outcomes of dental trauma cases from an urban pediatric emergency department. *Dent Traumatol* 2015; 31(2):97-102. <https://doi.org/10.1111/edt.12148>
- [16] Andreasen JO, Lauridsen E, Gerds TA, Ahrensburg SS. Dental trauma guide: A source of evidence-based treatment guidelines for dental trauma. *Dent Traumatol* 2012; 28(5):345-50. [https://doi.org/10.1111/j.1600-9657.2011.01059\\_1.x](https://doi.org/10.1111/j.1600-9657.2011.01059_1.x)
- [17] Andreasen JO, Flores MT, Robertson A, DiAngelis AJ, Andersson L, et al. International Association of Dental Traumatology guidelines for the management of traumatic dental injuries: 3. Injuries in the primary dentition. *Dent Traumatol* 2012; 28(3):174-82. <https://doi.org/10.1111/j.1600-9657.2012.01146.x>
- [18] Kramer PF, Zembruški C, Ferreira SH, Feldens CA. Traumatic dental injuries in Brazilian preschool children. *Dent Traumatol* 2003; 19(6):299-303. <https://doi.org/10.1046/j.1600-9657.2003.00203.x>
- [19] Rocha VG, Jacomo D, Campos V, Moliterno FM. Frequency of injuries in the primary dentition: A longitudinal descriptive study. *Arq Bras Odontol* 2008; 4(1):3-10.
- [20] Odersjo ML, Robertson A, Koch G. Incidence of dental traumatic injuries in children 0-4 years of age: A prospective study based on parental reporting. *Eur Arch Paediatr Dent* 2018; 19(2):107-111. <https://doi.org/10.1007/s40368-018-0334-z>
- [21] Rodrigues I, Da Silva BS, Ceron LC, Lopes TS, Venante HS, Santin GC, et al. Treatment of side luxation in decided teeth - Importance of preservation. *Braz J Surg Clin Res* 2017; 19(1):90-5.
- [22] Andersson L, Andreasen JO, Day P, Heithersay G, Trope M, DiAngelis AJ, et al. International Association of Dental Traumatology guidelines for the management of traumatic dental injuries: 2. Avulsion of permanent teeth. *Dent Traumatol* 2012; 28(2):88-96. <https://doi.org/10.1111/j.1600-9657.2012.01125.x>
- [23] Magno MB, Neves AB, Ferreira DM, Pithon MM, Maia LC. The relationship of previous dental trauma with new cases of dental trauma. A systematic review and meta-analysis. *Dent Traumatol* 2019; 35(1):3-14. <https://doi.org/10.1111/edt.12449>
- [24] Qassem A, Martins NM, Costa VPP, Torriani DD, Pappen FG. Long-term clinical and radiographic follow up of subluxated and intruded maxillary primary anterior teeth. *Dent Traumatol* 2015; 31(1):57-61. <https://doi.org/10.1111/edt.12135>
- [25] Qassem A, Goettens M, Torriani DD, Pappen FG. Radicular maturity level of primary teeth and its association with trauma sequelae. *Dent Traumatol* 2014; 30(3):227-31. <https://doi.org/10.1111/edt.12072>
- [26] Holan G. Development of clinical and radiographic signs associated with dark discolored primary incisors following traumatic injuries: a prospective controlled study. *Dent Traumatol* 2004; 20(5):276-87. <https://doi.org/10.1111/j.1600-9657.2004.00285.x>
- [27] Lauridsen E, Blanche P, Amaloo C, Andreasen JO. The risk of healing complications in primary teeth with concussion and subluxation injury - A retrospective cohort study. *Dent Traumatol* 2017; 33(5):337-44. <https://doi.org/10.1111/edt.12342>
- [28] Mocellini BS, de Alencar NA, Bolan M, Magno MB, Maia LC, Cardoso M. Pulp necrosis and crown discoloration: A systematic review and meta-analysis. *Int J Paediatr Dent* 2018; 28(5):432-42. <https://doi.org/10.1111/ipd.12372>
- [29] McDonald RE, Avery DR. *Odontopediatria*. 7<sup>th</sup> ed. Rio de Janeiro: Guanabara Koogan; 2001. [In Portuguese]
- [30] Holan G, Needleman HL. Premature loss of primary anterior teeth due to trauma - potential short - and long-term sequelae. *Dent Traumatol* 2014; 30(2):100-6. <https://doi.org/10.1111/edt.12081>
- [31] Losso EM, Tavares MCR, Bertoli FMP, Baratto-Filho F. Dentoalveolar trauma in the primary dentition. *RSBO* 2011; 8(1):1-20.
- [32] Fracasso MLC, Santin GC, Terra GMO, Martioli G, Provenzano MGA, Camillo A, et al. Dental injuries in deciduous teeth: A longitudinal study. *Saúde Pesq* 2016; 9(3):461-71. <https://doi.org/10.17765/1983-1870.2016v9n3p461-471>