


# A 12-month Follow-Up Study of Pulp Oxygen Saturation in Deciduous Molars After Selective and Nonselective Carious-Tissue Removal: A Randomized Pilot Trial

Pierre Adriano Moreno Neves<sup>1</sup>, Soraia de Fátima Carvalho Souza<sup>2</sup>, Luciano Casagrande<sup>3</sup>,  
Fernando Borba de Araujo<sup>3</sup>, Cayara Mattos Costa<sup>2</sup>, Cecilia Claudia Costa Ribeiro<sup>2</sup>

<sup>1</sup>Department of Dentistry, Federal University of Maranhão, São Luís, MA, Brazil.

<sup>2</sup>Postgraduate Program of Dentistry, Federal University of Maranhão, São Luís, MA, Brazil.

<sup>3</sup>Department of Dentistry, School of Dentistry, Federal University of Rio Grande do Sul, Porto Alegre, RS, Brazil.

**Correspondence:** Cecília Claudia Costa Ribeiro, Federal University of Maranhão, Center of Biological Sciences and Health, Department of Dentistry II, Campus Bacanga, São Luís, MA, Brazil. 65085-580. **E-mail:** [cecilia\\_ribeiro@hotmail.com](mailto:cecilia_ribeiro@hotmail.com)

**Academic Editor:** Alessandro Leite Cavalcanti

**Received:** 18 October 2021 / **Review:** 02 May 2022 / **Accepted:** 17 June 2022

**How to cite:** Neves PAM, Souza SFC, Casagrande L, Araujo FB, Costa CM, Ribeiro CCC. A 12-month follow-up study of pulp oxygen saturation in deciduous molars after selective and nonselective carious-tissue removal: a randomized pilot trial. *Pesqui Bras Odontopediatria Clín Integr.* 2023; 23:e210196. <https://doi.org/10.1590/pboci.2023.028>

## ABSTRACT

**Objective:** To compare the pulp vitality of deciduous molars before and after selective caries removal (SCR) or nonselective caries removal to hard dentin (NSCR) over one year, using oxygen saturation percentage (%SaO<sub>2</sub>). **Material and Methods:** Deciduous molars with deep occlusal/proximal-occlusal caries lesions were randomized to SCR (n=22) or NSCR groups (n=22). After the caries removal, the teeth were protected with calcium hydroxide cement and restored with composite resin (Filtek Z250). The pulp condition diagnosis was evaluated at baseline, immediately after caries removal, and follow-up (7 days, 1-, 6- and 12-months) by %SaO<sub>2</sub>. Pulp exposure and pulp necrosis were primary outcomes, and %SaO<sub>2</sub> was secondary. **Results:** Intraoperative pulp exposure occurred in four teeth of the NSCR group (18.2%) and one tooth of the SCR group (4.5%) (p>0.05). Two cases of pulp necrosis occurred in the NSCR group (10%). No difference in %SaO<sub>2</sub> pulp was observed in the inter- and intragroup comparison over time (p>0.05). **Conclusion:** Advantageously, the %SaO<sub>2</sub> minimizes preoperative pulp vitality diagnosis subjectivity before SCR/ NSCR treatments. Furthermore, the pilot study results suggest the pulp response of deciduous molars, when evaluated by clinical, radiographic, and pulp %SaO<sub>2</sub> seems not to differ between teeth treated with SCR or NSCR.

**Keywords:** Dental Caries; Dental Cavity Preparation; Tooth, Deciduous; Oximetry; Dental Pulp Necrosis.

## Introduction

Selective caries removal (SCR) is a conservative treatment for deep caries lesions [1,2]. SCR treatment maintains the innermost portion of the cavity preparation, the affected dentin - a vital tissue [3,4]- with an intact collagen structure that remineralizes a few months after the restorative treatment [5-7].

Clinical studies have shown a significant decline in the number of microorganisms and hardening of the affected dentin in teeth submitted to SCR after the cavity sealing period and no carious lesion progression [2,4]. Systematic reviews with meta-analysis of randomized clinical trials have shown that SCR in deciduous and permanent teeth resulted in reduced risk of pulp exposure [7-9] and postoperative pain [9] than nonselective caries removal to hard dentine (NSCR) treatment.

In selecting teeth for conservative treatment as SCR, clinical criteria for pulp vitality should be rigorously evaluated, excluding teeth with a history of spontaneous pain, radiographic evidence of periapical involvement, or clinical signs indicative of irreversible pulp inflammation or pulp necrosis [10-12]. Thus, it is essential to establish the correct diagnosis of the pulp condition since the technique's success depends on a favorable response of the dental pulp [3,13]. Furthermore, deciduous teeth frequently undergo caries lesions to pulpal necrosis without any clinical symptoms reported by the child [14]. Thus, clinical subjective data can lead professionals to misdiagnose and, consequently, perform an inadequate treatment in deep carious lesions in deciduous teeth.

In deciduous teeth, thermal tests do not accurately diagnose the pulp condition [12,15]. Due to children's fear and pain, these patients often lead false positive or negative results, leading the practitioner to misinterpret the pulp response to the applied stimulus [16]. Additionally, the thermal and electrical tests have limitations in observing the pulp sensitivity. These subjective tests evaluate pulp vitality based on the sensory response, not through evaluation of the pulp vascularisation [15-17]. The pulp nerve fibers are more resistant to degeneration than the vascular tissue [18]. Thus, thermal tests may result in a false-positive response for reversible pulp inflammation, even when the vascularisation of the pulp tissue is already compromised [16,19].

An alternative to complement the evaluation of the pulp condition in deciduous teeth affected by caries could be the use of the pulse oximeter adapted for dentistry [20]. The pulse oximeter is a sensitive, painless, and accurate method to evaluate the peripheral arterial oxygen saturation percentage (%SaO<sub>2</sub>) of pulp tissue [19,21]. %SaO<sub>2</sub> has been validated to determine pulpal blood flow in healthy and damaged deciduous and permanent teeth [15-17].

Pulse oximetry reduces subjectivity in diagnosing the pulp condition before carious tissue removal and provides a complementary objective evaluation of the pulp response of deciduous teeth over time. Thus, this clinical pilot study compares the pulp vitality of deciduous molars before and after SCR or NSCR over 12 months, using intraoperative pulp exposure and pulp necrosis as primary outcomes and the pulp peripheral arterial oxygen saturation percentage (%SaO<sub>2</sub>) as a secondary outcome.

## Material and Methods

### Study Design and Ethical Clearance

This study is a pilot clinical trial, approved by the Research Ethics Committee of the Federal University of Maranhão (UFMA), Brazil, protocol no. 698.684, and registered in the Brazilian Clinical Trials Registry, Rebec Registry (ID # RBR-49MQHS). Parents or legal guardians received detailed information about the study and signed an informed consent form allowing the children to participate. All children received complete dental treatment at the Paediatric Dentistry Clinic of UFMA.

The Research Project registered at REBEC included the selection of deciduous and young permanent molars, with the age range of the participants between 8 and 15 years. However, due to the difficulty in selecting the sample of young permanent molars, the clinical trial was conducted only with deciduous molars. Therefore, the sample size was reduced, and the age range changed to 5 to 8 years.

The tooth was the experimental unit. The interventions were selective and nonselective carious-tissue removal. The primary outcomes were intraoperative pulpal exposure and pulp necrosis, and the secondary one was pulp %SaO<sub>2</sub>.

### Sample Selection

We did not find studies that evaluated pulp %SaO<sub>2</sub> and selective removal of carious tissue; thus, the sample size was based on previous SCR clinical trials in deciduous teeth (n=40) [3,4]. The sample was adjusted to 44 teeth (22 teeth per group), taking into account the possible loss. The sample included children aged 5 to 8 years of both genders who sought care at the Paediatric Dentistry Clinic of UFMA between August 2014 and June 2016.

After a clinical examination of 65 children, 27 children, corresponding to 54 teeth, were considered eligible for radiographic examination to select the teeth to be included in the study. The sample unit was the tooth, and 44 teeth that met the following inclusion criteria were included [3,4]: deciduous molar tooth with pulp vitality, without previous restoration and with active occlusal or proximal-occlusal carious lesions (inner half of dentine confirmed radiographically).

Teeth with deep caries lesion without pulp involvement and score 3 in the Nyvad system (Enamel/dentin cavity easily visible with the naked eye; cavity surface feels soft or leathery on gentle probing) [22] were eligible. As inclusion criteria, no clinical and radiographic signs indicate irreversibly pulp inflammation in teeth, such as a history of spontaneous pain, and no radiographic signs suggestive of pulp and periapical abnormality [3,4]. In addition, a mean of 74.6% of pulp %SaO<sub>2</sub> was used as the cut-off value for diagnosing necrotic pulp [23]. The %SaO<sub>2</sub> was measured in triplicate, and the median value of the measurements was considered representative of the tooth [24].

The teeth selected for the experiment were randomized using a sequence of random numbers generated in a spreadsheet by a person who did not belong to the research group; 22 teeth were included in the NSCR group, and 22 teeth were included in the SCR group. This information was provided to the operator only at the time of treatment.

### Measurement of Finger and Pulpal %SaO<sub>2</sub>

Initially, the %SaO<sub>2</sub> was measured on the right index finger thumb of each participant using an MD300A pulse oximeter (IMFtec Tecnologia para Saúde LTDA, São Paulo, SP, Brazil) adapted for dentistry [24] (Figure 1A), with an attached "Y"-type sensor (Figure 1B). Then, the sensors and their cables were covered with PVC film to avoid direct contact with oral tissues. The light-emitting sensor was positioned on the vestibular surface of the tooth, and the light-receiving sensor was positioned on the palatal or lingual surface, with the two diodes in parallel. The patients were instructed not to move their heads during the test. The light reflector dental equipment was turned off so as not to interfere with the signal of the oximeter [24].

For the pulp condition diagnosis before the restorative procedure (%SaO<sub>2</sub> baseline), the teeth were not anesthetized but were submitted to prophylaxis, relative isolation with cotton rolls, and air-dried.



**Figure 1. Pulse oximeter device adapted for Dentistry: (a) MD300A pulse oximeter model with "Y"-type sensor. (b) Diode sensors, one emitter of infrared light and the other receiver to measure pulp %SaO<sub>2</sub> (before PVC film protection).**

#### Removal of Carious Tissue

The teeth were anesthetized and absolute isolation with a rubber dam was performed, and the patients were submitted to the caries removal technique previously defined by the randomization process.

In the NSCR group, the cavity was accessed with a high-speed round diamond bur (No. 1013), and the carious tissue was completely removed with a low-speed smooth round bur. A caries detector dye (Evicárie, Biodinâmica Química e Farmacêutica LTDA, Ibiporã, PR, Brazil) was applied to the dentine for 10 sec, followed by washing of the cavity to remove excess dye to reduce the subjectivity of the examiner. This procedure was repeated until the dentine was no longer stained; this point was considered to be the complete removal of the carious dentine [4].

In the SCR group, after accessing the lesion, the cavity preparation was limited to the total removal of carious tissue from the lateral walls. Removal of necrotic dentine from the surface of the pulpal wall was performed with smooth round burs while keeping the deepest dentine (affected dentin) [4].

Calibration of the operator for selective removal of carious tissue was performed in 20 deciduous molars evaluated after this procedure, comparing the operator to a senior one with expertise in SCR, who supervised all clinical attendance (Kappa inter-examiner = 0.85).

Next, in both groups, the pulpal wall was protected with calcium hydroxide cement (Hydro C, Dentsply, Petrópolis, RJ, Brazil). The enamel and dentine of the surrounding walls were treated with 37% phosphoric acid. Finally, the teeth were restored with composite resin (Filtek Z250, 3M ESPE, Sumaré, SP, Brazil) after the application of an adhesive system (Adper™ Single Bond Plus Adhesive, 3M ESPE, Sumaré, SP, Brazil) according to the manufacturer's instructions.

The cases of minor pulp exposure after preparation of the cavity in both groups were recorded regarding their occurrence for subsequent statistical analysis. Immediately after the restorative procedure and removal of the rubber dam, another measurement of the pulp %SaO<sub>2</sub> was performed. All %SaO<sub>2</sub> measurements were performed by a blinded operator regarding the carious-tissue removal technique.

#### Follow-up

The pulp necrosis outcome was evaluated in the follow-up appointments (7 days, 1-, 6- and 12 months), whereas the pulp peripheral arterial oxygen saturation percentage outcome was evaluated before and after the restorative procedure and at all follow-ups. The outcome of pulp exposure was assessed during the transoperative.

Follow-up evaluations concerning pulp vitality were performed with teeth without being anesthetized and with relative isolation. The outcome pulp vitality was analyzed in the follow-up, observing no symptoms

indicative of irreversible pulpitis and no radiographic signs suggestive of pulpal and periapical abnormality [3,4]. In addition, the secondary outcome pulp %SaO<sub>2</sub> was performed by the same operator and in the same manner described for the baseline session.

### Statistical Analysis

The tooth was considered the experimental unit of analysis of the study. The normality of the data was evaluated using the Shapiro-Wilk test. Variables were normally distributed, and the values of the pulpal %SaO<sub>2</sub> within each evaluation group (NSCR or SCR) over time were compared using the ANOVA. In addition, the pulp %SaO<sub>2</sub> levels were compared between the NSCR and SCR groups using the Student's t-test for dependent samples (baseline, immediately after restoration, after 7 days, after 1-, 6-, and 12 months of follow-up).

The intraoperative pulp exposure and pulp necrosis were compared between the NSCR and SCR groups using Fisher's exact test. Furthermore, the %SaO<sub>2</sub> levels measured in the children's fingers were compared to the saturation of the pulp levels measured in the teeth through Spearman correlation analysis. All analyses were performed using BioEstat 5.3 software (Instituto Mamirauá, Brazil). A 5% significance level was adopted.

### Results

Five cases of intraoperative pulp exposure were recorded in our study during the removal of carious tissue, with four cases in the NSCR group (18.18%), of which three cases involved major pulp exposure, for which pulpotomy and exclusion from the study were indicated. Minor pulp exposure occurred in the other tooth of the NSCR group, and direct pulp capping was performed using calcium hydroxide paste and cement. Little pulp exposure also appeared in one tooth of the SCR group (4.5%), and direct pulp capping was also performed. The two teeth in which direct pulp capping was performed were included in the sample, and the occurrence of such procedures was recorded.

Although a lower percentage of intraoperative pulp exposure was observed in the SCR group, no significant difference was observed between the groups ( $p > 0.05$ ) (Table 1). In the two teeth with little pulp exposure accompanied (SCR - 1/NSCR - 1), no reduction in %SaO<sub>2</sub> levels over time was observed compared to baseline values (Table 2).

At follow-up, none of the teeth showed clinical and radiographic evidence of loss of pulp vitality; however, after these appointments, two cases of pulp necrosis with facial edema were recorded in the NSCR group (10%), but with no difference from the SCR group ( $p > 0.05$ ) (Table 1). In the first case, the %SaO<sub>2</sub> was 93% at the time of diagnosis and decreased to 84% at the 1-month evaluation, and the edema appeared 15 days after this last measurement (45 days after baseline). In the second case, the %SaO<sub>2</sub> at the time of diagnosis was 93% and decreased to 82% in the 6-month evaluation, and the child returned with facial edema 30 days (210 days after baseline) after this last visit (Table 2).

**Table 1. Comparison of the outcomes pulp exposure and pulp necrosis between the SCR and NSCR groups.**

Outcomes	Events	Selective Caries Removal	Nonselective Caries Removal	p-value*
		N (%)	N (%)	
Pulp Exposure (n = 44)	Present	1 (4.5)	4 (18.2)	0.3449
	Absent	21 (95.5)	18 (81.8)	
Pulp Necrosis (n = 40)	Present	0 (0.0)	2 (10.5)	0.2192
	Absent	21 (100.0)	17 (89.5)	

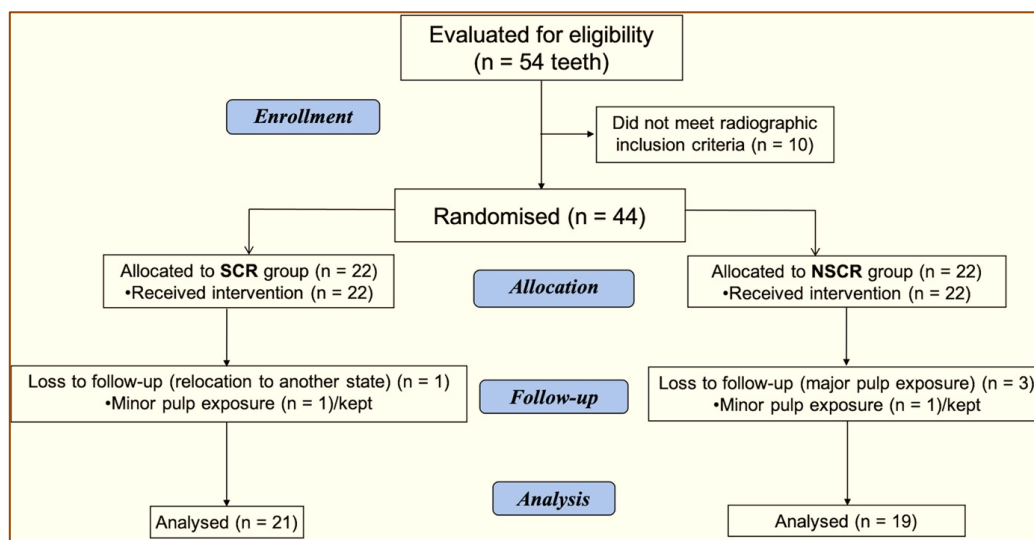
\*Fisher's exact test.

**Table 2. Medians of %SaO<sub>2</sub> of the cases of pulp exposure and pulp necrosis in the NSCR and SCR groups.**

Outcomes	Groups	Baseline		Follow-up		
		Before	After	7 Days	1 Month	6 Months
Pulp Exposure	SCR	93%	90%	84%	95%	84%
	NSCR	81%	90%	87%	91%	92%
Pulp Necrosis	NSCR (1 <sup>st</sup> case)	93%	91%	88%	84%	(-)
	NSCR (2 <sup>nd</sup> case)	93%	88%	94%	85%	82%

Baseline - (before and after the surgical procedure); SCR: Selective Caries Removal; NSCR: Nonselective Caries Removal; (-) - no reading available.

In the SCR group, one tooth was lost because the child moved to another state. Thus, the final sample consisted of 21 teeth in the SCR group and 19 teeth in the NSCR group (Figure 2). We tested the sample power to the primary outcomes (exposure and pulp necrosis) and the secondary outcome (%SaO<sub>2</sub> pulp). The power for the pulp exposure was 33.4%, pulp necrosis was 29.5%, and the %SaO<sub>2</sub> was 40%. These results indicate that studies need a larger sample to observe differences between SCR and NSCR, 60 teeth per group (%SaO<sub>2</sub>), 65 (pulp exposure), and 69 (pulp necrosis).



**Figure 2. Flowchart of the study design.**

In our study, the pulse oximeter was able to detect the %SaO<sub>2</sub> pulp in all evaluated teeth. In the analysis of the %SaO<sub>2</sub> pulp values, the mean saturation in the teeth during the evaluation period for the SCR group was 88.28%, and that for the NSCR group was 89.35%. No difference was observed in oxygen saturation levels between groups and within the same group over time ( $p > 0.05$ ) (Table 3).

**Table 3. Comparison of %SaO<sub>2</sub> (mean% ± SD) data between treatment groups over time.**

Group	Baseline		Follow-up				p-value <sup>†</sup>
	Before	After	7 Days	1 Month	6 Months	12 Months	
SCR (n=21)	87.66 ± 3.48	88.44 ± 3.34	88.44 ± 3.08	89.00 ± 3.96	90.00 ± 2.23	88.33 ± 3.78	0.5290**
NSCR (n=19)	89.44 ± 4.10	88.94 ± 2.62	89.16 ± 3.27	89.56 ± 3.24	89.36 ± 4.00	88.00 ± 1.00	0.7585**
p-value	0.1631*	0.63.66*	0.3942*	0.6850*	0.7119*	0.8899*	

Baseline: before and after the surgical procedure; SD: Standard Deviation; †Friedman's test; \*Student's *t*-test; \*\*Friedman's test; SCR: Selective Caries Removal; NSCR: Nonselective Caries Removal.

During the follow-up appointments, spontaneous or provoked pain was not reported by children or their parents. No statistical correlation was found between the %SaO<sub>2</sub> levels measured in the fingers and teeth for the NSCR or SCR groups ( $p > 0.05$ ) (data not shown).

## Discussion

This randomized pilot trial shows that the pulp vitality of deciduous molars submitted to SCR did not differ from that of teeth submitted to NSCR regarding pulp exposure, necrosis, and peripheral arterial pulp oxygen saturation percentage (%SaO<sub>2</sub>) outcomes during 12-month follow-up.

In the follow-up, two pulp necrosis (10.5%) occurred in teeth with no clinical and radiographic abnormal pulp vitality signal at baseline in the NSCR group. No necrosis case happened in the SCR group. However, the necrosis outcome did not significantly differ between the groups, probably due to the small sample of this trial (Table 1). About this finding, the meta-analyses evaluating the risk of pulp disease after SCR showed a risk ratio of 0.27 [0.05-1.60] with a p-value of 0.15 [7] or an odds ratio of 0.58 [0.31-1.10], however with a p-value of 0.10 [9], with insufficient evidence that the SCR had a superior effect to NSCR for pulp disease outcome. The development of pulp disease is an infrequent event after carious tissue removal; the sample size may also be why studies have not been able to show a significant difference in the outcome of pulp necrosis when comparing the SCR and NSCR groups.

The pulp %SaO<sub>2</sub> of the two teeth which developed pulp necrosis was > 90% at baseline and decreased in the follow-up to values ranging from 84% to 82% values identified at the previous follow-up before the clinical observation of pulp necrosis (Table 2). The decrease in %SaO<sub>2</sub> levels in the follow-up period alerted us to transition from reversible pulpitis to pulp necrosis, but no pain was reported by the patients. Dental abscesses occurred in the subsequent follow-up of these teeth, for which oximeter readings were not recorded. Thus, we confirmed necrosis and opened the teeth for pulpectomy. It is noteworthy that the restorations of these two teeth were clinically satisfactory.

This observation confirms the Brazilian Academy of Pediatric Dentistry guidelines, which alerts to the possibility of the dental pulp of deciduous teeth passing from the hyperemia to the necrosis phase without manifesting pain. The absence of pain is not considered a reliable parameter for diagnosing pulpal health. Thus, clinical subjective data on deciduous deep caries lesions may lead professionals to misdiagnose and perform an inadequate treatment [14].

Our results show that necrosis development after carious tissue removal occurred in two cases of the NSCR group where the baseline values of pulp %SaO<sub>2</sub> were > 90%, minimizing the possibility of an error in the diagnosis of the pulp condition at the time of randomization.

This is the first study evaluating the pulp response over time in decayed deciduous molars, using an objective tool to analyze pulp vitality in deciduous teeth before and after SCR / NSCR. A possible explanation for the absence of studies using a test to assess pulp vitality at baseline and follow-up would be the inaccuracy of the pulp response to the thermal and electrical tests in primary dentition [12].

The cut-off values for pulp health determination by pulse oximetry are not yet a consensus. A clinical trial with deciduous teeth showed an average pulp oxygen saturation of 87%, 77%, and 75% for vital and non-vital teeth, respectively [20]. A previous study indicates cut-off values of 93% for deciduous teeth vitality [16]. A systematic review established 87% as the median %SaO<sub>2</sub> for healthy pulp in central and lateral incisors and permanent canines [25]. Another study that included pre-molar teeth suggested this value may vary between 75% and 85% [18].

We observed five teeth (12.5%) that showed baseline %SaO<sub>2</sub> values between 81% and 83%, and during the follow-up period, these values progressively increased to levels > 90%. This observation suggests that for decayed deciduous molars, the cut-off baseline median may be lower than the cut-off values described in previous

studies for healthy deciduous teeth [15,16]. However, it should be noted that these values were consistently higher than 74.6%, which is considered the cut-off point of %SaO<sub>2</sub> for the diagnosis of pulp necrosis [23].

The mean values of pulp %SaO<sub>2</sub> (88.81 ± 0.77) were lower than the %SaO<sub>2</sub> values measured in patients' fingers (94.64 ± 0.73), with no correlation between these measurements, which is consistent with the literature for deciduous [15,16] and permanent teeth [25]. The lower %SaO<sub>2</sub> values in the teeth compared to the finger may be explained by the location of the pulp, which is surrounded by hard tissue, creating an obstacle to the detection of vascularisation [26]. Thus, infrared light diffraction through the enamel prisms and dentinal tubules [27] and the dispersion of light through the periodontium [16].

This 12-month follow-up pilot study suggests that the pulp response of deciduous molars, when evaluated by clinical, radiographic, and pulp %SaO<sub>2</sub>, did not differ between teeth treated with SCR or NSCR. We observed a tendency for pulp exposure and necrosis cases in the NSCR intervention. These infrequent outcomes may require many observations to see the difference between SCR and NSCR. The sample size did not have the power to identify a significant difference comparing the treatments evaluated. Systematic reviews grouping data from primary studies concluded that pulp exposure and pain are more frequent in the NSCR than in the SCR [7-9]. However, the meta-analyses had not shown evidence that the SCR had a superior effect to NSCR on necrosis outcome, possibly due to the small sample size, even though they grouped primary data [7,9].







This study has strengths that should be emphasized: (1) it serves as a reference for calculating the sample size on pulp exposure, necrosis, and %SaO<sub>2</sub> outcomes in Selective Caries Removal studies, and (2) it meets all the requirements of a randomized clinical trial; thus, our data can be included in meta-analyses in future.

Pulp %SaO<sub>2</sub> decreased overtime in two teeth that developed pulp necrosis. Thus, the reduction in %SaO<sub>2</sub> values in the follow-up is an alert to irreversible pulp inflammation and the need for a short time for subsequent teeth examination. Furthermore, a pulse oximeter adapted for dentistry may be a helpful tool to diagnose pulp conditions in deciduous teeth, minimize the subjectivity in treatment decision moment, and monitor pulp vitality longitudinally. The pulp %SaO<sub>2</sub> can support the clinician's decision-making when the professional is uncertain about the clinical/radiographic signs of irreversible pulp inflammation.

## Conclusion

Advantageously, the %SaO<sub>2</sub> minimizes preoperative pulp vitality diagnosis subjectivity before SCR/NSCR treatments. Furthermore, the pilot study results suggest the pulp response of deciduous molars, when evaluated by clinical, radiographic, and pulp %SaO<sub>2</sub> seems not to differ between teeth treated with SCR or NSCR.

## Authors' Contributions

PAMN 	<a href="https://orcid.org/0000-0002-6056-1382">https://orcid.org/0000-0002-6056-1382</a>	Conceptualization, Methodology, Data Curation, Writing - Original Draft, Writing - Review and Editing, Supervision.
SFCS 	<a href="https://orcid.org/0000-0002-8730-8600">https://orcid.org/0000-0002-8730-8600</a>	Methodology, Writing - Original Draft, Writing - Review and Editing, Supervision.
LC 	<a href="https://orcid.org/0000-0001-9515-6048">https://orcid.org/0000-0001-9515-6048</a>	Formal Analysis, Writing - Original Draft, Writing - Review and Editing.
FBA 	<a href="https://orcid.org/0000-0003-2892-3256">https://orcid.org/0000-0003-2892-3256</a>	Supervision, Writing - Original Draft, Writing - Review and Editing.
CMC 	<a href="https://orcid.org/0000-0002-4491-9700">https://orcid.org/0000-0002-4491-9700</a>	Data Curation, Writing - Original Draft, Writing - Review and Editing.
CCCR 	<a href="https://orcid.org/0000-0003-0041-7618">https://orcid.org/0000-0003-0041-7618</a>	Conceptualization, Data Curation, Formal Analysis, Writing - Original Draft, Writing - Review and Editing, Supervision.

All authors declare that they contributed to critical review of intellectual content and approval of the final version to be published.

## Financial Support

This study was funded by FAPEMA (Maranhão State Foundation for Research and Scientific and Technological Development), CNPq (National Council for Scientific and Technological Development) PQ- 315360/2021-6; and CAPES (Coordination for the Improvement of Higher Education Personnel): Finance Code 001, PROCAD- Amazônia 8881.200487/2018-01 and Amazônia Legal 0810/2020/8881.510244/2020-01.



## Conflict of Interest

The authors declare no conflicts of interest.

## Data Availability

The data used to support the findings of this study can be made available upon request to the corresponding author.

## Acknowledgments

We thank the children and their parents for their voluntary participation in this study. The authors are grateful to Cyrene Piazero Silva Costa for providing the photographs of the pulse oximeter device adapted for Dentistry. This study was partially supported by FAPEMA for financial support, and CAPES for granting a fellowship. The funders had no role in study design, data collection and analysis, decision to publish, or preparation of the manuscript.

## References

- [1] Giacaman RA, Muñoz-Sandoval C, Neuhaus KW, Fontana M, Chatas R. Evidence-based strategies for the minimally invasive treatment of carious lesions: review of the literature. *Adv Clin Exp Med* 2018; 27(7):1009-16. <https://doi.org/10.17219/acem/77022>
- [2] Lula EC, Almeida LJ, Alves CM, Monteiro-Neto V, Ribeiro CC. Partial caries removal in primary teeth: association of clinical parameters with microbiological status. *Caries Res* 2011; 45(3):275-80. <https://doi.org/10.1159/000325854>
- [3] Ribeiro CCC, Baratieri LN, Perdigão J, Baratieri NMM, Ritter AV. A clinical, radiographic and scanning electron microscopic evaluation of adhesive restorations on carious dentin in primary teeth. *Quint Int* 1999; 30:591-9.
- [4] Lula EC, Monteiro-Neto V, Alves CM, Ribeiro CC. Microbiological analysis after complete or partial removal of carious dentin in primary teeth: A randomized clinical trial. *Caries Res* 2009; 43(5):354-8. <https://doi.org/10.1159/000231572>
- [5] Fusayama T, Okuse K, Hosoda H. Relationship between hardness, discoloration, and microbial invasion in carious dentin. *J Dent Res* 1966; 45(4):1033-46. <https://doi.org/10.1177/00220345660450040401>
- [6] Deyhle H, Bunk O, Müller B. Nanostructure of healthy and caries-affected human teeth. *Nanomedicine* 2011; 7(6):694-701. <https://doi.org/10.1016/j.nano.2011.09.005>
- [7] Ricketts D, Lamont T, Innes NP, Kidd E, Clarkson JE. Operative caries management in adults and children. *Cochrane Database Syst Rev* 2013; (3):CD003808. <https://doi.org/10.1002/14651858.CD003808.pub3>
- [8] Li T, Zhai X, Song F, Zhu H. Selective versus non-selective removal for dental caries: a systematic review and meta-analysis. *Acta Odontol Scand* 2018; 76(2):135-40. <https://doi.org/10.1080/00016357.2017.1392602>
- [9] Schwendicke F, Dörfer CE, Paris S. Incomplete caries removal: a systematic review and meta-analysis. *J Dent Res* 2013; 92(4):306-14. <https://doi.org/10.1177/0022034513477425>
- [10] Kindelan SA, Day P, Nichol R, Willmott N, Fayle SA; British Society of Paediatric Dentistry. UK national clinical guidelines in paediatric dentistry: stainless steel performed crowns for primary molars. *Int J Paediatr Dent* 2008; 18(Suppl 1):20-8. <https://doi.org/10.1111/j.1365-263X.2008.00935.x>
- [11] Wambier DS, Santos FA, Guedes-Pinto AC, Jaeger RG, Simionato MR. Ultrastructural and microbiological analysis of the dentin layers affected by caries lesions in primary molars treated by minimal intervention. *Pediatr Dent* 2007; 29(3):228-34.
- [12] American Academy of Pediatric Dentistry. Pulp therapy for primary and immature permanent teeth. *The Reference Manual of Pediatric Dentistry*. Chicago, III.: American Academy of Pediatric Dentistry 2021; 399-407.
- [13] Hori A, Poureslami HR, Pariookh M, Mirzazadeh A, Abbot P. The ability of pulp sensibility tests to evaluate the pulp status. *Int J Paediatr Dent* 2011; 21(6):441-5. <https://doi.org/10.1111/j.1365-263X.2011.01147.x>
- [14] Pintor AVB, Mello-Moura ACV, Primo LG, Bedran LR, Nelson-Filho P. Pulp Therapy in Primary Teeth. In: *Brazilian Academy of Pediatric Dentistry. Guidelines for Clinical Procedures in Pediatric Dentistry*. 3rd. ed. São Paulo: Santos; 2021. [In Portuguese].
- [15] Pozzobon MH, Vieira RS, Alves AMH, Reyes-Carmona J, Teixeira CS, Souza BDM, et al. Assessment of pulp blood flow in primary and permanent teeth using pulse oximetry. *Dent Traumatol* 2011; 27(3):184-8. <https://doi.org/10.1111/j.1600-9657.2011.00976.x>
- [16] Goho C. Pulse oximetry evaluation of vitality in primary and immature permanent teeth. *Pediatr Dent* 1999; 21(2):125-7.
- [17] Gopikrishna V, Tinagupta K, Kandaswamy D. Comparison of electrical, thermal and pulse oximetry methods for assessing pulp vitality in recently traumatised teeth. *J Endod* 2007; 33(5):531-5. <https://doi.org/10.1016/j.joen.2007.01.014>
- [18] Gopikrishna V, Tinagupta K, Kandaswamy D. Evaluation of efficacy of a new custom-made pulse oximeter dental probe in comparison with the electrical and thermal tests for assessing pulp vitality. *J Endod* 2007; 33(4):411-4. <https://doi.org/10.1016/j.joen.2006.12.003>
- [19] Munshi AK, Hedge AM, Radhakrishnan S. Pulse oximetry: a diagnostic instrument in pulp vitality testing. *J Clin Pediatr Dent* 2002; 26(2):141-5. <https://doi.org/10.17796/jcpd.26.2.2j25008jg6u86236>

- [20] Sharma D, Mirsha S, Bannda NR, Vaswani S. In vivo evaluation of customized pulse oximeter and sensitivity pulp tests for assessment of pulp vitality. *J Clin Pediatr Dent* 2019; 43(1):11-5. <https://doi.org/10.17796/1053-4625-43.1.3>
- [21] Samuel SS, Thomas AM, Namita S. A comparative study of pulse oximetry with the conventional pulp testing methods to assess vitality in immature and mature permanent maxillary incisors. *CHRISMED J Health Res* 2014; 1(4):235-40. <https://doi.org/10.4103/2348-3334.142985>
- [22] Nyvad B, Machiulskiene V, Baelum V. Reliability of a new caries diagnostic system differentiating between active and inactive caries lesions. *Caries Res* 1999; 33(4):252-60. <https://doi.org/10.1159/000016526>
- [23] Setzer F, Kataoka SHH, Natrielli F, Gondim-Junior E, Caldeira CL. Clinical diagnosis of pulp inflammation based on pulp oxygenation rates measured by pulse oximetry. *J Endod* 2012; 38(7):880-3. <https://doi.org/10.1016/j.joen.2012.03.027>
- [24] Costa CPS, Thomaz EBAF, Souza SFC. Association between sickle cell anemia and pulp necrosis. *J Endod* 2013; 39(2):177-81. <https://doi.org/10.1016/j.joen.2012.10.024>
- [25] Bruno KF, Barletta FB, Felipe WT, Silva JA, Alencar AHG, Estrela C. Oxygen saturation in the dental pulp of permanent teeth: a critical review. *J Endod* 2014; 40(8):1054-7. <https://doi.org/10.1016/j.joen.2014.04.011>
- [26] Fuss Z, Trowbridge H, Bender IB, Rickoff B, Sorin S. Assessment of reliability of electrical and thermal pulp testing agents. *J Endod* 1986; 12(7):301-305. [https://doi.org/10.1016/S0099-2399\(86\)80112-1](https://doi.org/10.1016/S0099-2399(86)80112-1)
- [27] Radhakrishnan S, Munshi AK, Hedge AM. Pulse oximetry: a diagnostic instrument in pulp vitality testing. *J Clin Pediatr Dent* 2002; 26(2):141-5. <https://doi.org/10.17796/jcpd.26.2.2j25008jg6u86236>