


Evaluation of Bone Repair in the Mandible of Rabbits Using Biphasic Calcium Phosphate Micro-Macroporous Hydroxyapatite Bioceramics and Beta-Tricalcium Phosphate


Francisco Franceschini Neto¹, Rudyard dos Santos Oliveira², Ana Paula Altheman Lopes³, Carlos Eduardo Xavier dos Santos Ribeiro da Silva⁴

¹Implant Dentistry Specialization Course, Brazilian Dental Association, Paraíba Section, João Pessoa, PB, Brazil.

 0000-0002-5581-682X

²Department of Imaging and Oral Radiology, São Leopoldo Mandic College, Campinas, SP, Brazil.  0000-0001-9690-8563

³Private Practice, São Paulo, SP, Brazil.  0000-0002-5765-705X

⁴School of Dentistry, Santo Amaro University, São Paulo, SP, Brazil.  0000-0001-5048-8700

Author to whom correspondence should be addressed: Rudyard dos Santos Oliveira, Rua Domício M. Dourado, 605, Asa Sul, Irecê, BA, Brazil. 44900-000. Phone: +55 74 3641-2689. E-mail: dr.rudyardoliveira@gmail.com.

Academic Editors: Alessandro Leite Cavalcanti and Wilton Wilney Nascimento Padilha

Received: 14 June 2018 / Accepted: 21 January 2019 / Published: 31 January 2019

Abstract

Objective: To perform a clinical and histological evaluation, characterizing and proving the feasibility of the use of beta tricalcium phosphate (HA/ β TCP) bioceramics as a bone defect repair material, comparing it with autogenous bone and blood clot in terms of osteoinductive, conductive, and genic capacities. **Material and Methods:** The experiment was based on 3 critical defects in the mandible of 11 New Zealand rabbits. The defects were filled with HA/ β TCP bioceramics and autogenous bone, respectively, collected and ground during the development of defects and blood clots. The animals were euthanized after the 90-day experiment and samples were collected for histomorphological examination. To evaluate differences between the groups, a one-way analysis of variance (ANOVA) was performed with Tukey's post hoc test. An α value lower than 0.05 was considered statistically significant. **Results:** Microscopy revealed the presence of osteoblasts, osteoclasts, and osteocytes associated or not associated with the presence of mature or immature bone. All the studied materials presented bone neoformation in all cases, with the presence of mature and immature bone. Regarding the presence of HA/ β TCP bioceramic residual material, the same was found in 7 of 11 slides. **Conclusion:** HA/ β TCP bioceramics were shown to be a biocompatible bone substitute, with osteoinductive and osteoconductive characteristics, accelerating the process of new bone formation when compared with autogenous and blood clotted bone, thereby showing promise for bone defect repair with safety and efficacy.

Keywords: Dental Implants; Bone and Bones; Hydroxyapatites; Ceramics.

Introduction

Recently, much effort has been made to find solutions to correct bone defects for placing osteointegration implants. Biomaterials are remarkable in this regard, as they eliminate the need to remove autogenous bone. One of the referred biomaterials, highlighted in the present study, is beta tricalcium phosphate (β TCP) bioceramics associated with hydroxyapatite.

It has been demonstrated that β TCP bioceramics is a material with properties that can promote osteoinduction, i.e., the capacity to store proteins and cells that are viable, specific, and particular to the individual receiving the implant; thus, allowing natural bone neo-formation and biocompatibility, with problems restricted to its accelerated absorption [1,2].

Synthetic hydroxyapatites (HA), despite having a different composition and morphology, resemble natural bone the most, and are, therefore, an option for cases in which it is necessary to recover lost bone structure and fill in defects, because of its high osteogenic potential and structural maintenance with slow resorption [2,3].

To analyze alveolar repair using biomaterials, a study filled in the alveoli using an average 0.78 g of β TCP bioceramics without membranes. One first subjective visual clinical analysis rated it as very good to good for 87% of the cases post grafting. Radiographic analysis after 12 months revealed the presence of β TCP bioceramics granules in 30% of the cases, as well as reabsorption in height and width in 10% of the cases. The effectiveness of the treatment was rated as good and very good in 89% of the cases. For 100% of the cases there was no reactions or complications regarding the material. Clinically, it was observed that cases that used membranes were superior. It was concluded that the technique using membranes and β TCP bioceramics is recommended for the maximum preservation of alveoli for further implant prosthetic rehabilitation [4].

Another study performed a histological and histomorphometric analysis of autogenous bone versus β TCP bioceramics alone in 20 cases of bilateral sinus lift. On one side, β TCP bioceramics alone were placed, and on the other autogenous bone, in each patient. It was found no significant difference in the histologic and histomorphometric analyses in the experimental and control groups after 6 months; thus, being considered a good material for this type of treatment [5].

Studies have demonstrated mandibular reconstructions with β TCP bioceramics associated with autogenous bone in a proportion of 30% to 50% depending on the case. A total of 152 patients with various defects such as: bone repair after cystic exeresis, alveolar reconstruction, maxillary sinus lift, fractures of alveolar fractures, periodontal regeneration, reconstruction after removal of tumors and apicectomies, all defects being > 2 cm, were analyzed. The β TCP bioceramics in particles of 500-2,000 μ m and post-operative control of 4, 12, and 52 weeks were used. The authors reported easy application of the material; in 9.2% of the cases there was local irritation with granule loss; in 2% of the cases there was total loss of the material; and in 88.8% of the cases there was complete reabsorption of the material with simultaneous bone replacement, observed radiographically and histomorphometrically. It was also reported that the insertion of dental implants in the grafted region could be performed 5-6 months after the graft [6,7].

Another study reported the use of composites of HA + carbon and HA + carbon + sodium bicarbonate, in bone defects in rabbit ulnas. The evidence of early bone regeneration, absence of infection, rejection, efficiency, and high reliability of the materials could be seen [8].

Researchers have reported studies of maxillary sinus lift with β TCP. For this purpose, 17 bilateral edentulous patients had β TCP bioceramics grafted on one side and autogenous bone was used on the other. After 6 months, 68 implants were placed, and bone removed from the site was histomorphometrically analyzed. The bone density showed no significant difference between the sides, but the biodegradation was significantly slower on the β TCP bioceramic side, whereas the bone trabeculation pattern on the β -TCCP side was lower than that of the autogenous bone, but without significant differences. It was concluded that after 6 months, implants could be anchored without major problems in grafting with β TCP bioceramics [9,10].

The performance of the resorbable bioceramics was evaluated using tricalcium phosphate silicon as a stabilizer in the repair of extensive defects in the long bones of sheep. The evaluation was performed through sequential radiographs, tomography, histology, immunohistology, and microradiography to analyze the density and percentage of bone growth. They concluded that there was excellent integration and significant bone regeneration besides evident osteoclastic biomaterial reabsorption. At the end of the first year the remainder of the biomaterial was 10-20% and after the second year it was completely reabsorbed, with the defect completely filled by new, highly mineralized, lamellar bone [11].

In an animal study carried out with 8 rabbits, β TCP bioceramic blocks and β TCP bioceramic blocks treated with PRP for onlay growth were compared. It was concluded after 3 months that there was no inflammatory process in any of the blocks, and the association with PRP did not result in any significant improvement in bone growth [12,13].

Therefore, animal studies are of paramount importance for the timely and safe comparison of biomaterials of varied characteristics, with control groups, such as autogenous bone and blood clot, and for treatments, if they were tested in human patients, avoiding, in this way, suffering and damage to humans [14].

The objective of this study was to perform a clinical and histological evaluation, characterizing and proving the feasibility of the use of HA/ β TCP bioceramics as a bone defect repair material, comparing it with autogenous bone and blood clot in terms of osteoinductive, conductive, and genic capacities.

Material and Methods

The rabbits used in this study were obtained from the Santo Amaro University (UNISA) Animal Facility, and were monitored and medicated by the veterinarian team of the facility. All surgical procedures were performed at the UNISA Multidisciplinary Laboratory of Veterinary Surgery Techniques, and the rabbits had undergone 12 hours absolute fasting as per veterinary instruction and supervision.

Eleven female New Zealand rabbits were selected for the experimental surgical procedures, with ages ranging between 4 and 6 months, and weights between 3.0 and 3.5 kg. The animals were weighed and on the day of the procedure the selected animals received pre-anesthetic medication (intramuscular), consisting of 0.2 ml Acepran 1%. In every procedure, the animals were anesthetized using an association (intramuscular) of Cetamin (40 mg/kg), Xylazin (5 mg/kg), and Meperidine (10 mg/kg), and were monitored by the responsible veterinary team, receiving further half-dose applications according to their need during the procedure [11].

The area was shaved and antisepsis was performed with povidone-iodine followed by infiltrative local anesthesia with Mepivacaine 2% without vasoconstrictor. Two separate bilateral rectilinear incisions were made in the antero-posterior mandible of the rabbits, according to the anatomy verified through palpation, using scalpel number 15. A patch was then removed to expose the bone tissue of the mandible, using periosteum lifters. In every procedure, a veterinarian of the same team monitored the heart rate, respiration, and palpebral reflexes of the animals.

Next, three inlay bony defects were made mechanically on the mandible of the rabbits, using a straight surgical instrument, electric motor, and trephines, under constant irrigation using physiological saline (0.9%). The defects were 7 mm in diameter and 3 mm deep; two were made on the left side of the mandible and one on the right (Figure 1).

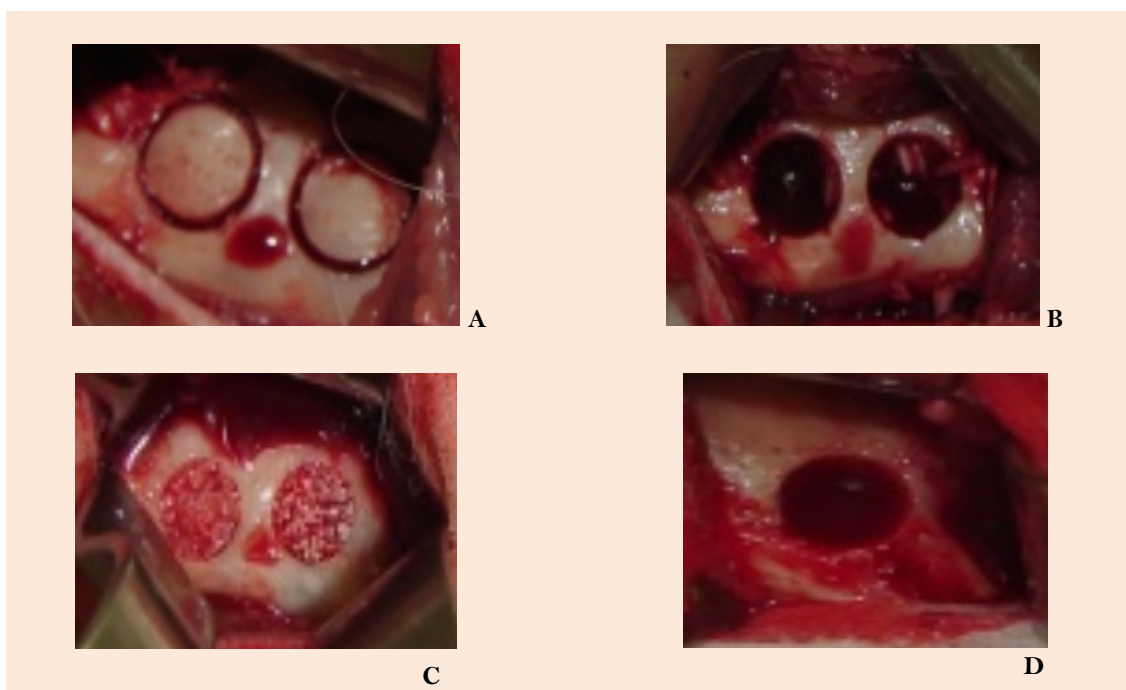


Figure 1. A: Defects; B: Defects empty; C: Autogenous bone/ β TCP blood; D: Blood clot.

To facilitate posterior identification and standardization of the defects, the animal's teeth were used as reference. On the left side, the anterior defect was made in the direction of the second posterior tooth, and the posterior defect was made after the last posterior tooth. On the right side, the defect was made in the direction between the third and fourth posterior teeth. All defects were

made 4 mm above the mandibular ridge. After making the defects, we carefully marked the external cortical of the mandible in the region of the defects and stored this cortical bone with physiological saline at 0.9% for further use [12].

The defects were filled in as follows: the first, on the right mandible side with a blood clot (control group); the second, on the anterior left side with autogenous bone removed when the defects were trephined and crushed using a bone grinder; and the third, on the left posterior side with HA/ β TCP bioceramics, always respecting a distance of at least 3 mm between the 2 defects. After filling in the defects, the full patch was repositioned and the tissues were sutured with simple stitches by using nylon 3.0.

The rabbits were kept for 7 days in individual cages, which were cleaned daily, and then moved to cells that housed three animals, thus allowing minor motility and reducing stress during the observation period. The environment was maintained under controlled temperature and luminosity, and the animals were fed 3 times a day with Nutriara® ration (Nutriara Alimentos Ltd., Cuiabá, MT, Brazil) and had water ad libitum. The animals received subcutaneous postoperative medication for 7 days: Enrofloxacin (5 mg/kg) and Flunixin Meglumine (1.1 mg/kg) [11].

The rabbits were sacrificed after 12 weeks, by using a technique recommended by Brazilian College of Animal Experimentation, consisting of an overdose of general anesthetic (Thiopentax®) associated with an intravenous injection of potassium chloride (19.1%). The assessment time was standardized as 3 months, as this period corresponded to approximately 9 months in humans. This time interval used for the assessment was justified by previous studies that showed the bone metabolism in rabbits is approximately 3 times faster than that in humans, and could be used as the foundation for research with an allometric scale [11,13,14].

Next, material was removed from the respective location with 7-mm diameter trephines. A clinical analysis was performed and any changes in the defects were registered. The specimens were stored in formaldehyde at 10%, stained with hematoxylin and eosin (HE) by histology technicians, and forwarded to the pathologic anatomy laboratory to prepare the histologic blades.

The blades were photographed and digitalized (micrography) and then analyzed (Plínio S Anatomia Patológica S/C Ltda, São Paulo, SPB, Brazil) for the presence of cells suitable for bone maturation, such as osteoblasts, osteoclasts, osteocytes, and evidence of material waste.

Data Analysis

Mean values and standard deviations were obtained. Data were analyzed using IBM SPSS Statistics for Windows Software, version 18 (IBM Corp., Armonk, NY, USA). To evaluate differences between the sample and control, a one-way analysis of variance (ANOVA) was performed with Tukey's post hoc test. An α value lower than 0.05 was considered statistically significant.

Ethical Aspects

The research was approved by the Research Ethics Committee of Santo Amaro University (Protocol No. 011/2008). It was carried out in accordance with the ethical principles of animal experimentation elaborated by the Brazilian College of Animal Experimentation (COBEA), affiliated to the International Council of Laboratory Animal Science (ICLAS).

Results

The results were analyzed considering the clinical evolution of the animals, as well as the healing process of the bone neo-formation of the defects made on the animal's mandibles. Regarding the immediate postoperative clinical aspects, after post-anesthetic recovery, all animals were healthy and all local masticatory and sensorial functions were preserved (Table 1).

Table 1. Representation of the presence (+) or absence (-) in the mature bone in the experiment.

Bone Maturation (%)	Autogenous Bone		Blood Clot		HA/ β TCP	
	Mature Bone (100%)	Immature Bone (55%)	Mature Bone (100%)	Immature Bone (9%)	Mature Bone (100%)	Immature Bone (18%)
Rabbit 1	+	-	+	-	+	-
Rabbit 2	+	+	+	+	+	+
Rabbit 3	+	+	+	-	+	+
Rabbit 4	+	-	+	-	+	+
Rabbit 5	+	+	+	-	+	+
Rabbit 6	+	-	+	-	+	+
Rabbit 7	+	-	+	-	+	+
Rabbit 8	+	-	+	-	+	+
Rabbit 9	+	+	+	-	+	-
Rabbit 10	+	+	+	-	+	+
Rabbit 11	+	+	+	-	+	+

The animals were followed and monitored daily, and no adverse events were observed from the postoperative period until the moment of euthanasia. Furthermore, it should be noted that animals went back to their normal habits and motor functions shortly after they had recovered from the effects of anesthesia; thus, the result was considered positive from a clinical perspective. When the surgical sites were accessed to collect the material, there were no tissue infiltrations in the regions where bone filling was performed with autogenous bone, in any of the animals.

Similarly, in regions where fillings were performed with HA/ β TCP, no tissue infiltrations were found in any of the animals; thus evincing mechanical strength, gradual bone substitution, and the biphasic feature of the material. However, regions filled using blood clots revealed tissue infiltrations that caused small bone structural defects in all animals (Figure 2).

Through microscopic analysis it was observed that all HA/ β TCP bioceramics blades had cells considered feasible for bone neo-formation. Osteoblasts were found in 9 of the 11 HA/ β TCP bioceramics blades, whereas osteoclasts were observed in 6 blades, both of which showed evidence of bone growth and metabolism. Only 1 of the HA/ β TCP blades presented a greater number of osteoblasts and osteoclasts than those of the others. Furthermore, these cells were not observed in 2 of the 11 blades, which suggests that each animal had a different response to the same material in the same period of time (Figure 3).

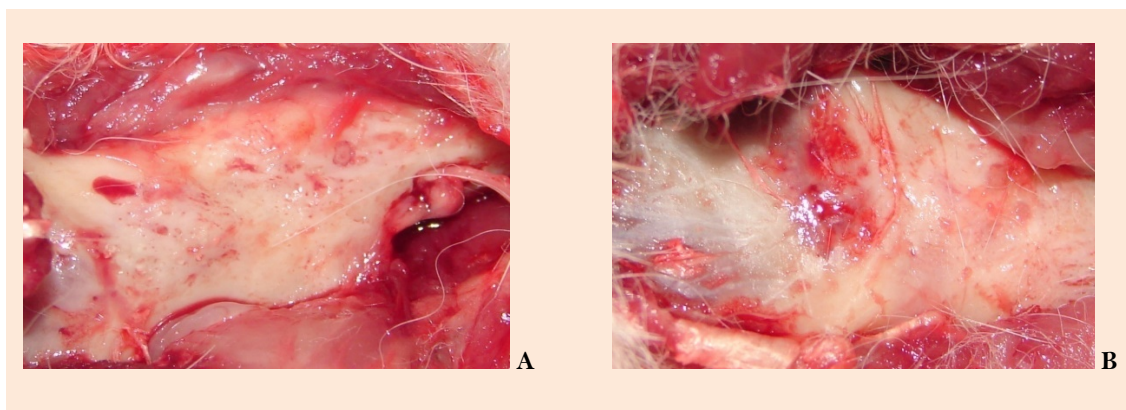


Figure 2. A: Autogenous bone HA/βTCP blood; B: Blood clot.

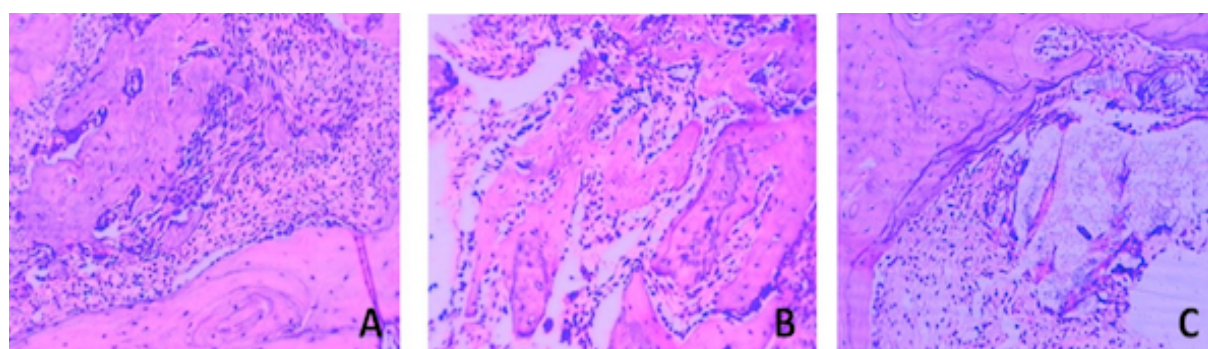


Figure 3. A: Presence of mature bone with osteocytes and bone metabolism, in the presence of osteoclasts and osteoblasts. B: Presence of increased amount of mature bone and bone in the maturation process, with minimal presence of osteoclasts and large numbers of osteoblasts. C: Presence of bone with a high metabolism rate and presence of osteoblasts and osteoclasts, in close contact with HA/βTCP bioceramics and mature bone with osteocytes.

It was observed that there were a greater number of osteoblasts and osteoclasts in addition to a greater presence of immature bone on the autogenous bone blades than that of the the HA/βTCP bioceramics blades. This shows an acceleration of the bone maturation process when HA/βTCP bioceramics were present (Table 2).

Table 2. Representation of the presence (+) or absence (-) of autogenous bone in the experiment.

Autogenous Bone	Osteoblasts	Osteoclasts	Mature Bone	Immature Bone
Rabbit 1	++	+	+	-
Rabbit 2	+++	+	+	+
Rabbit 3	++	+	+	+
Rabbit 4	+	+	+	-
Rabbit 5	++	+	+	+
Rabbit 6	+	+	+	-
Rabbit 7	+	++	+	-
Rabbit 8	+	+	+	-
Rabbit 9	+++	+	+	+
Rabbit 10	+++	+	+	-
Rabbit 11	++	++	+	+

However, when compared with that of the blood clot, the presence of osteoblasts and osteoclasts was greater in the HA/ β TCP bioceramics blades, with a smaller presence of mature bone, thus evincing faster bone neoformation in the defects filled in with blood clots, with a clinical loss of the filling structure (Table 3).

Table 3. Representation of the presence (+) or absence (-) of blood clot in the control group.

Blood Clot	Osteoblasts	Osteoclasts	Mature Bone	Immature Bone
Rabbit 1	+	+	+	-
Rabbit 2	++	+	+	+
Rabbit 3	+	+	+	-
Rabbit 4	-	-	-	-
Rabbit 5	+	+	+	-
Rabbit 6	+	+	+	-
Rabbit 7	-	-	+	-
Rabbit 8	+	+	+	-
Rabbit 9	+	-	+	-
Rabbit 10	+	-	+	-
Rabbit 11	-	-	+	-

The presence of mature bone and osteocytes were observed in every HA/ β TCP bioceramics blade; however, immature bone was observed with great significance only in one blade, which also had a greater number of osteoblasts and osteoclasts (Table 4).

Table 4. Representation of the presence (+) or absence (-) of HA/ β TCP bioceramics in the experiment.

Bioceramics of HA/ β TCP	Osteoblasts	Osteoclasts	Mature Bone	Immature Bone	Residual Material
Rabbit 1	+++	++	+	+	+
Rabbit 2	+	+	+	-	-
Rabbit 3	+	+	+	-	-
Rabbit 4	+	-	+	-	-
Rabbit 5	+	+	+	-	+
Rabbit 6	+	+	+	-	+
Rabbit 7	-	-	+	-	+
Rabbit 8	+	-	+	-	+
Rabbit 9	+	-	+	+	+
Rabbit 10	+	+	+	-	+
Rabbit 11	-	-	+	-	-

It was also observed that in all HA/ β TCP biomaterial blades, there was a greater presence of mature bone when the material was directly in contact with the defect walls. Residual HA/ β TCP material was observed in 7 of the 11 blades, but at low amounts and always located more towards the center of the defect, which showed that growth is centripetal, starting by the walls directly in contact with the material gradually towards the center of the defect. The presence of residual material on these blades also shows individual factors in relation to absorption and the metabolism time in animals also evincing the biphasic feature of the material (Figure 4).

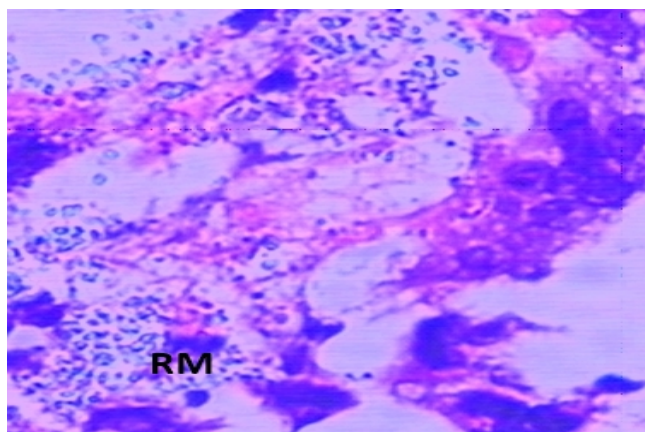


Figure 4. RM: Residual material: centripetal growth.

Discussion

In agreement with previous observations, it was found that bone regeneration was best and fastest when there was close contact of the HA/ β TCP bioceramics with the neighboring bone, because of the direct interface resulting from the integration of the cortical and medullar bone with the material [15,16].

Evidence was given for the osteoconductive and osteoinduction of the HA/ β TCP bioceramics material, which facilitates regeneration and guiding new bone trabecular [1,6,17,18]. Furthermore, complete filling of the defects, without tissue infiltration, which remained stable during bone substitution was clinically evinced in all the HA/ β TCP bioceramics blades, taking into consideration the delays in the bone formation, observed histologically, because of the individual reaction to the material. Furthermore, when the process was accelerated, it also affected degradation of both the most and least soluble parts [1,5,8,9,19-23].

Another factor that should be considered is that, clinically, when the surgery was performed to collect the material for analysis, we noticed that the appearance of the neoformed bone, despite not using membranes, was normal and without any tissue infiltration in the region. Thus, we believed that it is not necessary to use membranes to achieve good results with the material, as its mechanical resistance and biphasic features maintain the desired structural support until bone substitution has been completed [24-26].

In addition, the material was very effective in filling inlay bone defects; however, further studies are needed to show the osteogenic capacity of the material [2,6,16,26]. It was shown that the material guided the neoformation of bone trabeculae, and induced neoformation when in contact with the bone, and can thus be classified as osteoconductive and osteoinductive [22,26].

Clinically, the material appeared to be more resistant to perforation, showing higher hardness than that of the other fillings. The difficult decalcification evinced this when preparing the histologic blades, in which bone calcification required twice the time during the process [27]. However, studies in consecutive years have reported that the bone density of the grafted region

when perforated for implant placement did not present clinical differences than that of contiguous natural bone sites, requiring more specific analysis for these conclusions [8,12,27].

The association between the bioceramics HA/ β TCP and other materials has been studied; the use of platelet rich plasma (PRP), phosphate silicone, fibrin glue, or even autogenous bone favor increased repair speed and improvement in neoformed bone structure [6,9,10,17,18,28,29]. In another study, no changes were observed to the morphology and number of viable cells present in the site with new bone formation in any of the HA/ β TCP bioceramics blades, nor in the blood clot and autogenous bone blades [30].

Based on the type of material and size of its particles, there is a greater or lesser use of that material during bone matrix formation. Hence, it is possible that particle size affects the formation of the bone trabeculae, improving or worsening its absorption, since bone deposition occurs simultaneously. In the present study, the size of the HA/ β TCP bioceramics particles was 100–200 μ m, which facilitated its absorption and liberation of calcium ions, favoring the osteoblast mitosis process, promoting osteoinduction [22,25].

While conducting this study, we considered the concept of critical defects in the mandible of rabbits [17]; however, the size of the defect should be considered since it could need the association of HA/ β TCP bioceramics with autogenous or other osteogenic materials to promote better and faster bone repair in larger defects; thus, making it feasible to create a new cellular bone matrix in that region [6,12,26]. Nevertheless, in 2016, the material was considered as ideal for using in long bones as a substitute to autogenous bone even if used alone [17]. Another positive factor of the material that should be reported its easy application, as it is known that several products are difficult to apply, and its form of application and presentation would make it easy to use in daily practice [6]. Locally, there was acceleration in the process of bone neoformation in defects filled with HA/ β TCP bioceramics, compared with those filled with blood clot. However, when compared to autogenous bone, bone neoformation was similar [16,22,23,26].

Conclusion

The bioceramic HA/ β TCP was shown to be a biocompatible bone substitute, with osteoinductive and osteoconductive characteristics that accelerated the process of bone neoformation relative to autogenous bone and blood clot. Thus, it is effective for the repair of bone defects.

Financial Support: None.

Conflict of Interest: The authors declare no conflicts of interest.

References

- [1] Ishack S, Mediero A, Wilder T, Ricci JL, Cronstein BN. Bone regeneration in critical bone defects using three-dimensionally printed β -tricalcium phosphate/hydroxyapatite scaffolds is enhanced by coating scaffolds with either dipyridamole or BMP-2. *J Biomed Mater Res B Appl Biomater* 2017; 105(2):366-75. <https://doi.org/10.1002/jbm.b.33561>

- [2] Shavandi A, Bekhit AD, Ali MA, Sun Z, Gould M. Development and characterization of hydroxyapatite/ β -TCP/chitosan composites for tissue engineering applications. *Mater Sci Eng C Mater Biol Appl* 2015; 56:481-93. <https://doi.org/10.1016/j.msec.2015.07.004>
- [3] Wen B, Kuhn L, Charles L, Pendry D, Shafer D, Freilich M. Comparison of bone morphogenetic protein-2 delivery systems to induce supracrestal bone guided by titanium implants in the rabbit mandible. *Clin Oral Implants Res* 2016; 27(6):676-85. <https://doi.org/10.1111/clr.12645>
- [4] Shavandi A, Bekhit AD, Sun Z, Ali A, Gould M. A novel squid pen chitosan/hydroxyapatite/ β -tricalcium phosphate composite for bone tissue engineering. *Mater Sci Eng C Mater Biol Appl* 2015; 55:373-83. <https://doi.org/10.1016/j.msec.2015.05.029>
- [5] Brogginini N, Bosshardt DD, Jensen SS, Bornstein MM, Wang CC, Buser D. Bone healing around nanocrystalline hydroxyapatite, deproteinized bovine bone mineral, biphasic calcium phosphate, and autogenous bone in mandibular bone defects. *J Biomed Mater Res B Appl Biomater* 2015; 103(7):1478-87. <https://doi.org/10.1002/jbm.b.33319>
- [6] Nguyen TBL, Lee BT. A combination of biphasic calcium phosphate scaffold with hyaluronic acid-gelatin hydrogel as a new tool for bone regeneration. *Tissue Eng Part A* 2014; 20(13-14):1993-2004. <https://doi.org/10.1089/ten.TEA.2013.0352>
- [7] Chang YL, Lo YJ, Feng SW, Huang YC, Tsai HY, Lin CT, et al. Bone healing improvements using hyaluronic acid and hydroxyapatite/beta-tricalcium phosphate in combination: An animal study. *Biomed Res Int* 2016; 2016:8301624. <https://doi.org/10.1155/2016/8301624>
- [8] Corbella S, Taschieri S, Francetti L, Weinstein R, Del Fabbro M. Histomorphometric results after postextraction socket healing with different biomaterials: A systematic review of the literature and meta-analysis. *Int J Oral Maxillofac Implants* 2017; 32(5):1001-17. <https://doi.org/10.11607/jomi.5263>
- [9] Pereira RS, Gorla LF, Boos FB, Okamoto R, Garcia Júnior IR, Hochuli-Vieira E. Use of autogenous bone and beta-tricalcium phosphate in maxillary sinus lifting: histomorphometric study and immunohistochemical assessment of RUNX2 and VEGF. *Int J Oral Maxillofac Surg* 2017; 46(4):503-10. <https://doi.org/10.1016/j.ijom.2017.01.002>
- [10] Tamura K, Sato S, Kishida M, Asano S, Murai M, Ito K. The use of porous β -tricalcium phosphate blocks with platelet-rich plasma as an onlay bone graft biomaterial. *J Periodontol* 2007; 78(2):315-21. <https://doi.org/10.1902/jop.2007.060228>
- [11] Gad SC. *Animal Models in Toxicology*. 3rd ed. CRC Press, 2015. 1152p.
- [12] Yip I, Ma L, Mattheos N, Dard M, Lang NP. Defect healing with various bone substitutes. *Clin Oral Implants Res* 2015; 26(5):606-14. <https://doi.org/10.1111/clr.12395>
- [13] Yang C, Unursaikhan O, Lee JS, Jung UW, Kim CS, Choi SH. Osteoconductivity and biodegradation of synthetic bone substitutes with different tricalcium phosphate contents in rabbits. *J Biomed Mater Res B Appl Biomater* 2014; 102(1):80-8. <https://doi.org/10.1002/jbm.b.32984>
- [14] Peres MF, Ribeiro ED, Casarin RC, Ruiz KG, Junior FH, Sallum EA, et al. Hydroxyapatite/ β -tricalcium phosphate and enamel matrix derivative for treatment of proximal class II furcation defects: a randomized clinical trial. *J Clin Periodontol* 2013; 40(3):252-9. <https://doi.org/10.1111/jcpe.12054>
- [15] Lambert F, Leonard A, Lecloux G, Sourice S, Pilet P, Rompen E. A comparison of three calcium phosphate-based space fillers in sinus elevation: A study in rabbits. *Int J Oral Maxillofac Implants* 2013; 28(2):393-402. <https://doi.org/10.11607/jomi.2332>
- [16] Weinand C, Nabili A, Khumar M, Dunn JR, Ramella-Roman J, Jeng JC, et al. Factors of osteogenesis influencing various human stem cells on third-generation gelatin/ β -tricalcium phosphate scaffold material. *Rejuvenation Res* 2011; 14(2):185-94. <https://doi.org/10.1089/rej.2010.1105>
- [17] Suruagy AA, Alves AT, Sartoretto SC, Calasans-Maia JA, Granjeiro JM, Calasans-Maia MD. Physicochemical and histomorphometric evaluation of zinc-containing hydroxyapatite in rabbits calvaria. *Braz Dent J* 2016; 27(6):717-26. <https://doi.org/10.1590/0103-6440201601028>
- [18] Daculsi G1, Goyenvalle E, Cognet R, Aguado E, Suokas EO. Osteoconductive properties of poly(96L/4D-lactide)/beta-tricalcium phosphate in long term animal model. *Biomaterials* 2011; 32(12):3166-77. <https://doi.org/10.1016/j.biomaterials.2011.01.033>
- [19] Bagher Z, Rajaei F, Shokrgozar M. Comparative study of bone repair using porous hydroxyapatite/ β -tricalcium phosphate and xenograft scaffold in rabbits with tibia defect. *Iran Biomed J* 2012; 16(1):18-24.

- [20] Jeong BC, Choi H, Hur SW, Kim JW, Oh SH, Kim HS et al. Repair of cranial bone defects using rhBMP2 and submicron particle of biphasic calcium phosphate ceramics with through-hole. *J T Biomed Res Int* 2015; 2015:926291. <https://doi.org/10.1155/2015/926291>
- [21] Ebrahimi M, Pripatnanont P, Monmaturapoj N, Suttapreyasri S. Fabrication and characterization of novel nano hydroxyapatite/ β -tricalcium phosphate scaffolds in three different composition ratios. *J Biomed Mater Res A* 2012; 100(9):2260-8. <https://doi.org/10.1002/jbm.a.34160>
- [22] Zhou TH, Su M, Shang BC, Ma T, Xu GL, Li HL, et al. Nano-hydroxyapatite/ β -tricalcium phosphate ceramics scaffolds loaded with cationic liposomal ceftazidime: preparation, release characteristics in vitro and inhibition to *Staphylococcus aureus* biofilms. *Drug Dev Ind Pharm* 2012; 38(11):1298-304. <https://doi.org/10.3109/03639045.2011.648196>
- [23] Kiliç SC, Güngörmüş M. Cone beam computed tomography assessment of maxillary sinus floor augmentation using beta-tricalcium phosphate alone or in combination with platelet-rich plasma: A randomized clinical trial. *Int J Oral Maxillofac Implants* 2016; 31(6):1367-75. <https://doi.org/10.11607/jomi.5205>
- [24] Roohani-Esfahani SI, Nouri-Khorasani S, Lu Z, Appleyard R, Zreiqat H. The influence hydroxyapatite nanoparticle shape and size on the properties of biphasic calcium phosphate scaffolds coated with hydroxyapatite-PCL composites. *Biomaterials* 2010; 31(21):5498-509. <https://doi.org/10.1016/j.biomaterials.2010.03.058>
- [25] Ogawa K, Miyaji H, Kato A, Kosen Y, Momose T, Yoshida T, et al. Periodontal tissue engineering by nano beta-tricalcium phosphate scaffold and fibroblast growth factor-2 in one-wall infrabony defects of dogs. *J Periodontal Res* 2016; 51(6):758-67. <https://doi.org/10.1111/jre.12352>
- [26] Zabeu, JLA, Mercadante MT. Bone graft substitutes compared to autologous bone graft in orthopedic surgery: systematic literature review. *Rev Bras Ortop* 2008; 43(3):59-68. <https://doi.org/10.1590/S0102-36162008000200002>
- [27] Bizenjima T, Takeuchi T, Seshima F, Saito A. Effect of poly (lactide-co-glycolide) (PLGA)-coated beta-tricalcium phosphate on the healing of rat calvarial bone defects: A comparative study with pure-phase beta-tricalcium phosphate. *Clin Oral Implants Res* 2016; 27(11):1360-7. <https://doi.org/10.1111/clr.12744>
- [28] McCullen SD, Zhu Y, Bernacki SH, Narayan RJ, Pourdeyhimi B, Gorga RE, et al. Electrospun composite poly (L-lactic acid)/tricalcium phosphate scaffolds induce proliferation and osteogenic differentiation of human adipose-derived stem cells. *Biomed Mater* 2009; 4(3):035002. <https://doi.org/10.1088/1748-6041/4/3/035002>
- [29] Uchida M, Agata H, Sagara H, Shinohara Y, Kagami H, Asahina I. Mixing conditions for cell scaffolds affect the bone formation induced by bone engineering with human bone marrow stromal cells, beta-tricalcium phosphate granules, and rhBMP-2. *J Biomed Mater Res* 2009; 91(1):84-91. <https://doi.org/10.1002/jbm.a.32200>
- [30] Cheng L, Ye F, Yang R, Lu X, Shi Y, Li L, et al. Osteoinduction of hydroxyapatite/beta-tricalcium phosphate bioceramics in mice with a fractured fibula. *Acta Biomater* 2010; 6(4):1569-74. <https://doi.org/10.1016/j.actbio.2009.10.050>