


Correlation Between Palatal Depth and Duration of Upper Airway Obstruction Since Diagnosis in Children

Astri Kusumaningrum¹, Sarworini Bagio Budiardjo², Darmawan Budi Setyanto³

¹Department of Pediatric Dentistry, Faculty of Dentistry, Universitas Indonesia, Jakarta, Indonesia.  0000-0001-7360-1083

²Department of Pediatric Dentistry, Faculty of Dentistry, Universitas Indonesia Jakarta, Indonesia.  0000-0002-2506-6191

³Department of Pediatric, Faculty of Medicine, Universitas Indonesia, Jakarta, Indonesia.  0000-0003-1307-356X

Author to whom correspondence should be addressed: Sarworini B. Budiardjo, Department of Pediatric Dentistry, Faculty of Dentistry, Universitas Indonesia, Jl. Salemba Raya No.4, Jakarta, Indonesia. Phone: +62 21 31930270. E-mail: sarworinibagio@yahoo.com.

Academic Editors: Alessandro Leite Cavalcanti and Wilton Wilney Nascimento Padilha

Received: 20 February 2019 / Accepted: 10 July 2019 / Published: 30 July 2019

Abstract

Objective: To analyze the correlation between palatal depth and duration of the upper airway obstruction since diagnosis among children with habitual mouth breathing. **Material and Methods:** This cross-sectional analytical study was conducted using the consecutive sampling method on boys and girls who were habitual mouth breathers and presented with allergic rhinitis, adenoid hypertrophy, obstructive sleep apnea, rhinosinusitis, and nasal polyp. Information about the duration of upper airway obstruction was obtained from the medical records of the patients. The patients divided into two groups: those diagnosed with upper airway obstruction for < 4 years, and those diagnosed with upper airway obstruction for > 4 years. Hard palate measurements were obtained from upper arch study models using a caliper with a precision of $\pm 0,1$ mm. **Results:** A strong positive correlation was noted between the duration of the upper airway obstruction since diagnosis and palatal depth in children ($r=0.623$; $p<0.05$). Furthermore, the depth of the palates was found to be greater than 40 mm when the duration of upper airway obstruction since diagnosis was more than four years. **Conclusion:** The finding of this study indicates that upper airway obstruction can result in high palates in children with habitual mouth breathing.

Keywords: Mouth Breathing; Airway Obstruction; Rhinitis, Allergic; Sleep Apnea Syndromes.

Introduction

Craniofacial growth and development can be influenced by the breathing process. Nasal breathing allows for the proper growth of the dentofacial complex. According to the functional matrix theory by Melvin Moss, facial growth occurs as a response to functional needs such as breathing, sucking, chewing, and swallowing. Additionally, nose breathing can stimulate lateral growth of the maxilla and lower the palatal vault [1,2].

Upper airway obstruction refers to a blockage in nasopharynx or oropharynx areas. In children, the causes of upper airway obstruction are adenoid hypertrophy, allergic rhinitis, obstructive sleep apnea, nasal polyp, and rhinosinusitis, resulting in habitual mouth breathing [2,3]. The effects of this breathing habit on maxillary growth are a long and narrow face, short upper lip, prominent maxillary incisors, narrow V-shaped upper arch with high palatal vault, and class II occlusal relationship [3,4].

A few studies have reported the relationship between respiratory problems and maxillary growth. A previous study showed a narrowing of the palate in the posterior region as a result of mouth-breathing [5]. Similar results were reported in another study along with the presence of significantly deeper palate in children with allergic rhinitis [6]. However, to the best of our knowledge, there were no studies on the effect of the duration of upper airway obstruction and palatal depth.

The aim of this study was to determine the correlation between palatal depth and the duration of upper airway obstruction in children.

Material and Methods

Study Design and Sample

In this cross-sectional and analytic study, a consecutive sampling method was used on boys and girls with allergic rhinitis, adenoid hypertrophy, obstructive sleep apnea, rhinosinusitis, and nasal polyp.

The inclusion criteria were: boys or girls with mouth-breathing habit due to allergic rhinitis, adenoid hypertrophy, obstructive sleep apnea, rhinosinusitis, and nasal polyp. The diagnosis of allergic rhinitis, adenoid hypertrophy, obstructive sleep apnea, nasal polyp, and rhinosinusitis was based on the clinical history and clinical examination by an experienced pediatrician at the outpatient clinic.

Data Collection

Information about the duration of upper airway obstruction was obtained from the medical records of the patients. The patients divided into two groups: those diagnosed with upper airway obstruction for < 4 years, and those diagnosed with upper airway obstruction for > 4 years. Hard palate measurements were obtained from upper arch study models using a caliper with a precision of

$\pm 0,1$ mm. The measurements of the depth of the palate were used to calculate the palatal height index using the following formula [7]:
$$\text{Index Palatine Height} = \frac{\text{Palatine Height} \times 100}{\text{Palatine Width}}$$

Data Analysis

Data and analyzed using Statistical Package for the Social Sciences (SPSS) version 20 (IBM Corp., Armonk, NY, USA). Descriptive statistics were used to calculate the absolute and relative frequencies. Descriptive statistics and Spearman Correlation were used.

Ethical Aspects

This study was approved by the Ethics in Research Committee of the Faculty of Dentistry, University of Indonesia number 603/UN2.F1/ETIK/VIII/2016. Written informed consent was obtained from the parents of children who agreed to take part in this study.

Results

A strong positive correlation between palatal depth and duration of upper airway obstruction since diagnosis was noted ($r=0.623$; $p<0.05$). As shown in Figure 1, the depth of the palate was greater than 40 mm when the duration of upper airway obstruction since diagnosis was more than four years.

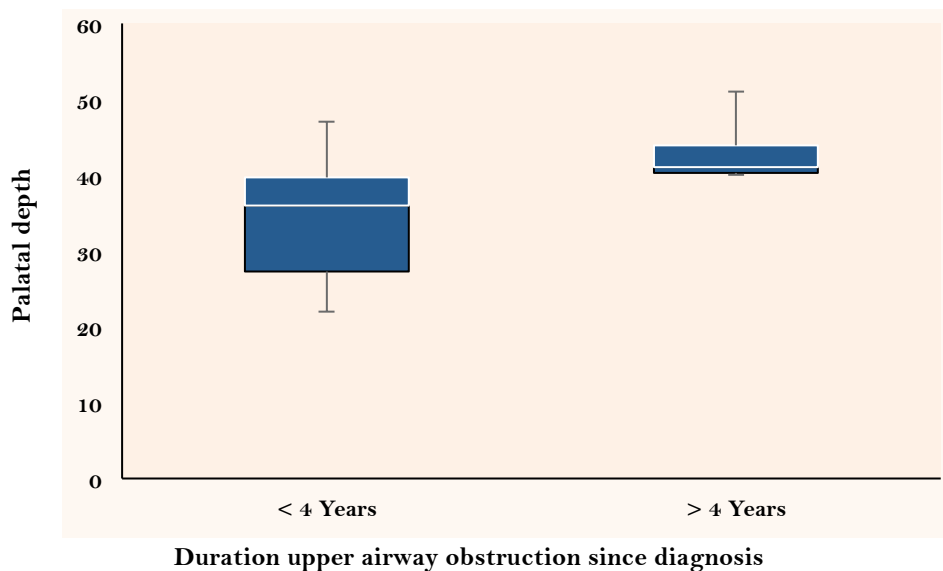


Figure 1. Box plot showing palatal depths in children diagnosed with upper airway obstruction for <4 and >4 years. The depth of the palate was greater than 40 mm diagnosed with upper airway obstruction for more than four years.

Discussion

Upper airway obstruction is a common problem in children and refers to a blockage in the nasopharynx or oropharynx areas. The causes of upper airway obstruction are allergic rhinitis

adenoid hypertrophy, rhinosinusitis, obstructive sleep apnea, and nasal polyp [8,9]. The obstruction of the upper airway promotes the habit of mouth breathing in children leading to muscular and postural changes that may result in dento-skeletal changes [3,4].

In the present study, a strong and positive correlation was noted between the palatal depth and duration of upper airway obstruction since diagnosis. The previous study has demonstrated a relationship between upper airway obstruction and palatal depth statistically significant differences between obstructive sleep apnea and control subjects [10].

Nasal breathing stimulates the lateral growth of the maxilla and lowers palatal vault. Additionally, it influences the development of craniofacial structure, favoring the harmonious growth and development along with the function of swallowing and mastication [11]. During the growth and development of the nasomaxillary complex, the growth of maxilla can be influenced by the growth of the cartilaginous of the nasal septum. Palatal growth occurs by the deposition on the palatal roof and apposition on the nasal floor [12].

Mouth breathing induces the development of a high palatal vault because the absence of negative pressure in the nasal cavity prevents the lowering of the palate. Moreover, the low position of the tongue in the oral cavity creates an unbalance between lateral buccal and lingual muscular forces, resulting in a narrow and V-shaped palatal vault [13,14]. In view of manifestation in the craniofacial complex as a result of habitual mouth breathing, multidisciplinary teamwork is required. Furthermore, orthodontic treatment is needed for occlusal adjustment. Limitation of this present study is lack of mouth breathers subjects, further investigation of palatal depth in mouth breathers caused by airway obstruction is required with more number of subjects.

Conclusion

Nasal breathing facilitates the normal growth and development of the craniofacial complex. Any obstruction in the upper airway passages may result in dentofacial and skeletal alterations. In the present study, children with habitual mouth breathing due to upper airway obstruction presented with narrow and V-shaped palates. A strong positive correlation between palatal depth and duration upper airway obstruction since diagnosis was noted. Moreover, children who had upper airway obstruction for more than four years since diagnosis presented with deeper palates.

Authors' Contributions: AK designed the study, performed the data collection, data analysis and interpretation, and wrote the manuscript. SBD and DBS designed the study, performed the data collection, data analysis and interpretation, wrote the manuscript and reviewed the manuscript. All authors declare that they contributed to critical review of intellectual content and approval of the final version to be published.

Financial Support: None.

Conflict of Interest: The authors declare no conflicts of interest.

References

- [1] Lione R, Franchi L, Huanca Ghislazoni LT, Primozić J, Buongiorno M, Cozza P. Palatal surface and volume in mouth-breathing subjects evaluated with three-dimensional analysis of digital dental casts - A controlled study. *Eur J Orthod* 2014; 37(1):101-4. <https://doi.org/10.1093/ejo/cju018>
- [2] Gungor AY, Turkkahraman H. Effects of airway problems on maxillary growth: A review. *Eur J Dent* 2009; 3(3):250-4.
- [3] Basheer B, Hegde KS, Bhat SS, Umar D, Baroudi K. Influence of mouth breathing on the dentofacial growth of children: A cephalometric study. *J Int Oral Health* 2014; 6(6):50-5.
- [4] Lessa FC, Enoki C, Feres MF, Valera FC, Lima WT, Matsumoto MAN. Breathing mode influence in craniofacial development. *Braz J Otorhinolaryngol* 2005; 71(2):156-60. [https://doi.org/10.1016/S1808-8694\(15\)31304-5](https://doi.org/10.1016/S1808-8694(15)31304-5)
- [5] Berwig LC, Montenegro MM, Ritzel RA, Silva AMT, Corrêa ECR, Mezzomo CL. Influence of the respiratory mode and nonnutritive sucking habits in the palate dimensions. *Braz J Oral Sci* 2011; 10(1):42-9. <https://doi.org/10.20396/bjos.v10i1.8641695>
- [6] Ghasempour M, Mohammadzadeh I, Garakani S. Palatal arch diameters of patients with allergic rhinitis. *Iran J Allergy Asthma Immunol* 2009; 8(1):63-4.
- [7] Maria CM, Silva AMT, Busanello-Stella AR, Bolzan GP, Berwig LC. Evaluation of hard palate depth: Correlation between quantitative and qualitative method. *Rev CEFAC* 2013; 15(5):1292-9. <https://doi.org/10.1590/S1516-18462013005000029>
- [8] Darras KE, Roston AT, Yewchuk LK. Imaging acute airway obstruction in infants and children. *Radiographics* 2015; 35(7):2064-79. <https://doi.org/10.1148/rg.2015150096>
- [9] Mandal A, Kabra SK, Lodha R. Upper airway obstruction in children. *Indian J Pediatr* 2015; 82(8):737-44. <https://doi.org/10.1007/s12098-015-1811-6>
- [10] Gungor AY, Turkkahraman H. Effects of airway problems on maxillary growth: A review. *Eur J Dent* 2009; 3(3):250-4.
- [11] Harari D, Redlich M, Miri S, Hamud T, Gross M. The effect of mouth breathing versus nasal breathing on dentofacial and craniofacial development in orthodontic patients. *Laryngoscope* 2010; 120(10):2089-93. <https://doi.org/10.1002/lary.20991>
- [12] Premkumar S. *Textbook of Craniofacial Growth*. New Delhi: Jaype Brothers Medical Publisher; 2011.
- [13] Peltomäki T. The effect of mode of breathing on craniofacial growth - revisited. *Eur J Orthod* 2007; 29(5):426-9. <https://doi.org/10.1093/ejo/cjm055>
- [14] Jain A, Bhaskar DJ, Gupta D, Yadav P, Dalai DR, Jhingala V, et al. Mouth breathing: A menace to developing dentition. *J Contemp Dent* 2014; 4(3):145-51. <https://doi.org/10.5005/jp-journals-10031-1085>