





# Donor Site Morbidity of Nonvascularized Bone Graft: A Systematic Review

Lilies Dwi Sulistyani<sup>1</sup>, Vera Julia<sup>1</sup>, Teuku Zulfahmi Rizki<sup>1</sup>, Dwi Kasta Dharmawan<sup>1</sup>

<sup>1</sup>Department of Oral and Maxillofacial Surgery, Faculty of Dentistry, Universitas Indonesia, Indonesia.

**Correspondence:** Lilies Dwi Sulistyani, Department of Oral and Maxillofacial Surgery, Faculty of Dentistry, Universitas Indonesia. Jalan Salemba Raya No. 4, Jakarta Pusat, Indonesia 10430, Indonesia. **E-mail:** [liliesdwi\\_s@yahoo.co.id](mailto:liliesdwi_s@yahoo.co.id)

**Academic Editor:** Catarina Ribeiro Barros de Alencar

**Received:** 09 February 2022 / **Review:** 20 June 2022 / **Accepted:** 17 July 2022

**How to cite:** Sulistyani LD, Julia V, Rizki TZ, Dharmawan DK. Donor site morbidity of nonvascularized bone graft: a systematic review. *Pesqui Bras Odontopediatria Clín Integr.* 2023; 23:e220029. <https://doi.org/10.1590/pboci.2023.033>

## ABSTRACT

**Objective:** To evaluate the donor site morbidity of iliac and fibular nonvascularized bone graft after mandibular resection. **Material and Methods:** This study was guided by the Preferred Reporting Items for Systematic Reviews and Meta-Analyses (PRISMA) in PubMed, Proquest, Science Direct, and Ebsco. A total of 12 studies met the criteria of studies in humans using iliac and fibular nonvascularized bone grafts in mandibular reconstruction after mandibular resection. **Results:** A greater proportion of patients received iliac nonvascularized bone graft (88.9%) than fibular nonvascularized bone graft (11.1%). Of the 385 cases of iliac bone graft, 153 cases (40%) experienced complications at the iliac donor site, whereas in 48 cases of fibular bone graft, two (4%) experienced complications at the donor site. Hemorrhage, bone fracture, infection requiring debridement, and hematoma were the major complications. **Conclusion:** The morbidity rate of the nonvascularized bone graft donor site of the fibula (4%) tended to be lower than that of the ilium (40%). Patient age and defect size were not significantly correlated with the occurrence of morbidity donor sites in either the ilium or fibula.

**Keywords:** Mandibular Reconstruction; Morbidity; Bone Transplantation; Ilium; Fibula.

## Introduction

Most tumors of the jaw are benign [1]. For the complete removal of tumors, radical therapy is required for benign tumors with a high recurrence rate or for large-sized tumors. Resection for tumor removal within a free margin of 1 cm decreases the recurrence rate of benign tumors of the jaw [2,3]. Ideally, reconstruction should be performed to restore facial function and esthetics by preserving the facial contour. Moreover, reconstruction after mandible resection should be performed to restore oral function and preserve the occlusal plane, floor of the mouth, and anatomical position of the tongue [2-4].

Both vascularized, and nonvascularized techniques are used for jaw reconstruction. The choice of method depends on the surgeon's experience, the contour and size of the defect, and the soft tissue. In defects of >6 cm, hard- and soft-tissue reconstruction is required using a vascularized bone graft. However, in defects of <6 cm without soft-tissue reconstruction, a nonvascularized bone graft can be performed [3,4]. Donor sites for nonvascularized bone grafts include the ilium, tibia, calvarium, fibula, scapula, radius, and costochondral bones [4-6].

Nonvascularized bone grafts have advantages and disadvantages. The ilium and fibula are often used as nonvascularized bone grafts [7,8]. Osborn et al. revealed that iliac bone graft (IBG) could be considered the first choice for defects of <9 cm because of its high success rate [4], easy access, and adequate availability of cortical and cancellous bone [7]. Reconstruction using a fibular bone graft (FBG) is a simple, rapid procedure with low donor site morbidity. The fibula recipient site can regenerate rapidly, especially in relatively young patients. Generally, if there is soft tissue and good blood supply, iliac and fibular nonvascularized bone grafts can be alternatives to vascularized bone grafts [8].

Existing studies have investigated and evaluated the use of vascularized bone grafts by comparing donor sites, healing after bone graft reconstruction, and success rates [9-13]. Additionally, three articles have assessed the morbidity of vascularized bone graft [14-16]. However, until now, there have been only a few studies discussing donor site morbidity of iliac and fibular nonvascularized bone grafts. This systematic review aimed to evaluate the donor site morbidity of iliac and fibular nonvascularized bone grafts after mandibular resection.

## Material and Methods

### Literature Search

The study was guided by the Preferred Reporting Items for Systematic Reviews and Meta-Analysis (PRISMA). The study search was conducted in four databases: PubMed, Proquest, Science Direct, and Ebsco. The search strategy used the following keywords: "reconstruction" AND "mandible" AND "non-vascularized" AND ("bone graft" OR "bone transplants") AND ("iliac" OR "fibula") AND "morbidity" AND "donor site." The search was conducted on research published from January 2011 to January 2021, reported in English and in the form of full text. We excluded duplicate studies. Endnote X9 was used as the reference manager.

### Inclusion Criteria

For the initial selection, two independent reviewers assessed the titles and abstracts on the basis of the following inclusion criteria: studies on iliac and fibular nonvascularized bone grafts in mandibular reconstruction after mandibular resection in human, retrospective or prospective cohort studies, randomized controlled trials, or case series were included in this systematic review. Studies in which subjects received chemotherapy or radiation treatment and had systemic disease were excluded. After the initial selection, the reviewers read the full text to determine whether the study should be included or excluded (Figure 1).

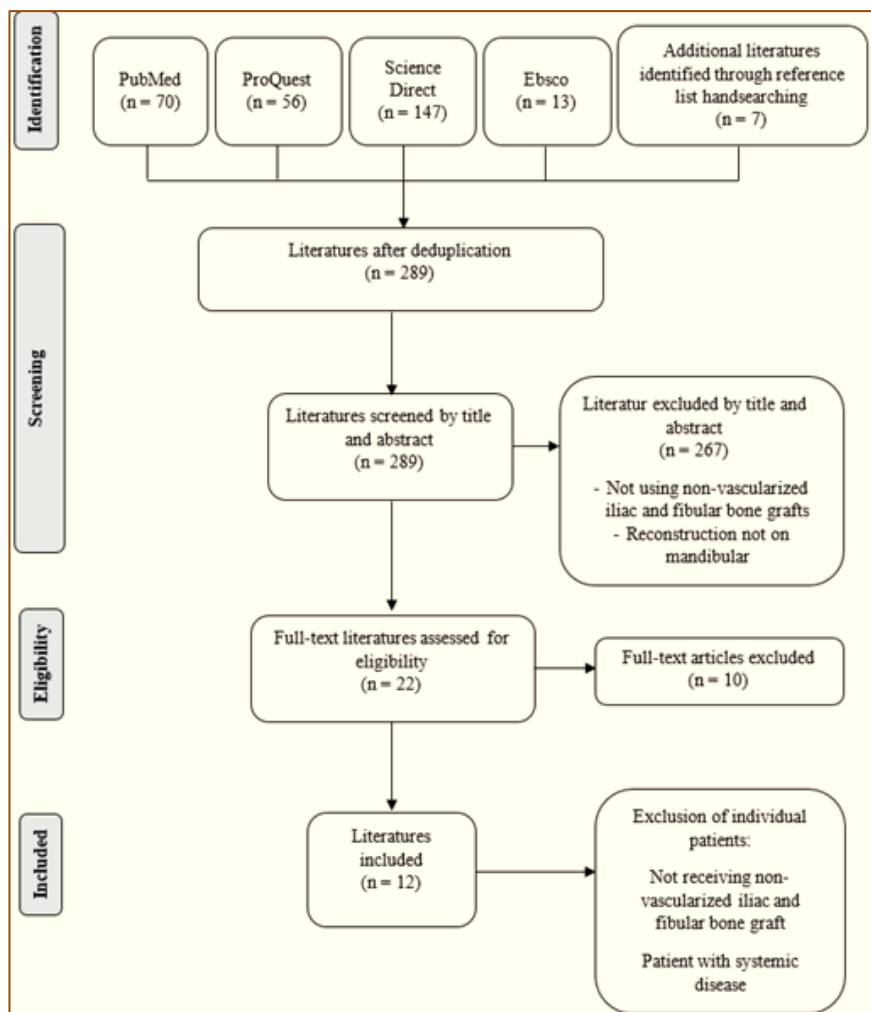


Figure 1. The PRISMA statement criteria.

#### Data Collection

Data collected from each study included the following: subject characteristics (age, gender), diagnosis, defect size, and donor site (graft used and complications).

#### Quality Assessment

The evaluation of study quality was conducted using the PRISMA statement criteria [17]. Table 1 lists the criteria used to classify the potential risk of bias. Studies meeting all the criteria were categorized as having a low risk of bias, and those that did not meet two or more criteria were categorized as having a high risk of bias.

#### Results

The search results yielded 286 studies. After removing duplicates, 282 studies were assessed for titles and abstracts, and 267 studies were excluded because they were irrelevant to the study topic or did not meet the inclusion criteria. Of the remaining studies, 15 met the inclusion criteria. Seven studies were included after screening the reference lists from other studies. Twenty-two studies were assessed using the full text, and 12 studies were found that met the inclusion criteria for final writing (Figure 1) shows the flowchart of the selection process [17].

**Table 1. Assessment of the article quality.**

Year	Author	Random Selection in Population	Defined Inclusion/Exclusion Criteria	Report of Loss to Follow-Up	Validated Measurements	Statistical Analysis	Potential Risk of Bias
2011	Gadre et al. [18]	Yes	Yes	Yes	Yes	No	Moderate
2011	Rana et al. [9]	Yes	Yes	Yes	Yes	Yes	Low
2012	Obimakinde et al. [19]	Yes	Yes	No	Yes	Yes	Moderate
2013	Bai et al. [20]	Yes	Yes	Yes	Yes	No	Moderate
2013	Magesh et al. [21]	Yes	Yes	No	Yes	Yes	Moderate
2013	Scheerlink et al. [22]	Yes	Yes	Yes	No	Yes	Moderate
2014	Akbay and Andogan [23]	Yes	No	No	Yes	No	High
2014	Ndukwe et al. [24]	Yes	No	Yes	Yes	Yes	Moderate
2015	Akinbami and Akadiri [25]	Yes	Yes	No	Yes	No	High
2018	Osborn et al. [4]	Yes	Yes	Yes	Yes	Yes	Low
2019	Marechek et al. [26]	Yes	Yes	Yes	Yes	Yes	Low
2020	Sharma et al. [27]	Yes	Yes	Yes	Yes	Yes	Low

Among the 12 suitable studies (Table 2), nine were retrospective, two were prospective, and one was a case series. The studies included a total of 592 patients. However, 159 patients were excluded because they did not receive a nonvascularized bone graft from the ilium and fibula or had diabetes mellitus, leaving 433 patients divided into two groups. A total of 385 patients (88.9%) received a nonvascularized IBG, and 49 patients (11.1%) received a fibular nonvascularized bone graft. The size of the defect from all studies ranged from 0.8 to 22 cm. The causes of the defects were categorized into benign lesions (39.5%), malignant lesions (16.3%), infection (8.3%), trauma (14%), and other causes (21.9%). Ameloblastoma was the main cause of defect, comprising as much as 26% of all cases for iliac and fibular nonvascularized bone grafts.

Several authors assessed donor site morbidity from postoperative complications [4,9,22,23]. Other authors assessed complications intraoperatively, postoperatively while the patient was still hospitalized, and postoperatively when the patient was discharged from the hospital [22,24,25]. Other authors categorized the major and minor complications, whereby major complications consisted of conditions requiring an intervention such as a blood transfusion, surgical revision, referral to another specialist, persistent postoperative pain, or esthetic problems. Other complications were categorized as minor, such as infection, seroma, hematoma, wound dehiscence, fracture, and plate removal [22,26].

**Table 2. Descriptive analysis of included studies.**

Author	Type of Study	Patient Characteristics		Diagnosis	Defect Size (cm)	Donor Site	
		N / Sex	Age (Years)			Graft Performed	Complications
Gadre et al. [18]	Cohort Retrospective	N = 87 Male: 59 Female: 28	13–85 Mean: 40.24	BENIGN LESION: 55 Ameloblastoma (34) Odontogenic keratocyst (16)	Not reported	Iliac: 68 Fibular: 16 Others: 3	ILIAC BONE GRAFT: Infection (1)

				Aneurysmal bone cyst (2) Central giant cell granuloma (1) Chondrosarcoma (1) Ossifying fibroma (1) Peripheral neuroectodermal tumor (1) MALIGNANT LESION: 31 Squamous cell carcinoma (31)			Temporary gait disturbances (2)
Rana et al. [9]	Cohort Retrospective	N = 178 Male: 131 Female: 47	13–85 Mean Male: 55.1 Female: 55.4	BENIGN LESION: 23 Ameloblastoma (9) Keratocystic odontogenic tumor (5) Dentigerous cyst (2) Central giant cell granuloma (3) Adenomatoid odontogenic tumor (1) Pindborg tumor (1) Odontogenic myxoma (2) OTHERS: 35 Post-temporomandibular joint ankylosis defects (35) INFECTIONS: 26 Osteomyelitis of the mandible (24) Osteosarcoma of the mandible (2) TRAUMA: 44 Post-traumatic defects (44) MALIGNANT LESION: 50 Squamous cell carcinoma (50)	4–9 Mean: 6	Iliac: 80 Fibular: 31 Others: 67	ILIAC BONE GRAFT: Pain (80) Infection (2) Paresthesia (3) Postoperative limp (5) FIBULAR BONE GRAFT: Infection (2)
Obimakinde et al. [19]	Cohort Retrospective	N = 47 Male: 26 Female: 21	12–45 Mean: 24.6	BENIGN LESION: 41 Ameloblastoma (36) Primordial cyst (1) Dentigerous cyst (2) Ossifying fibroma (2) MALIGNANT LESION: 4 Fibromyxoma (1) Ameloblastic carcinoma (2) Osteosarcoma (1) TRAUMA: 2 Gunshot (1) Mandibular fracture (1)	Not reported	Iliac: 47	ILIAC BONE GRAFT: Infection (3) Paresthesia (2) Initial gait disturbance (2) Wound dehiscence (3)
Bai et al. [20]	Cohort Retrospective	N = 7 Male: 3	20–47 Mean: 31.8	BENIGN LESION: 7 Ameloblastoma (6)	6–12 Mean: 9.15	Iliac: 7	NO COMPLICATIONS

Author	Study Design	Female: 4		Odontogenic calcifying epithelioma (1)			
Magesh et al. [21]	Cohort Retrospective	N = 13 Male: 7 Female: 6	19–48 Mean: 29	BENIGN LESION: 13 Ameloblastoma (9) Odontogenic keratocyst (4)	4–6 Mean: Not reported	Iliac: 13	NOT MENTIONED
Scheerlinck et al. [22]	Cohort Retrospective	N = 99 TREATED WITH ILIAC CREST N = 55 Male: 21 / Female: 34 TREATED WITH CALVARIUM N = 26 Male: 10 / Female: 16 TREATED WITH MANDIBULAR RAMUS N = 18 Male: 8 / Female: 10	16–65 Mean: 42	TRAUMA: 24 Posttraumatic defect (21) Resection defect (3) OTHERS: 75 Mandibular or maxillary atrophy (38) Oligodontia (30) Pseudoarthrosis (3) Orbital/zygomatic defect (3) Graves' orbipathy (1)	Not reported	Iliac: 55 Others: 44	ILIAC BONE GRAFT: Pain (20) Infection (1) Paresthesia (3) Hemorrhage (1) Fracture (2) Accidental bicortical harvesting (1) Hematoma (7)
Ndukwe et al. [24]	Cohort Retrospective	N = 25 Male: 12 Female: 13	13–73 Mean Male: 32.7, Female: 35.0	BENIGN LESION: 22 Ameloblastoma (17) Central giant cell granuloma (1) Cementifying fibroma (3) Odontogenic myxoma (1) OTHERS: 2 Hemifacial hypoplasia (1) Fibrous dysplasia (1) TRAUMA: 1 Gunshot (1)	Not reported	Iliac: 8 Others: 17	NO COMPLICATIONS
Akbay & Aydogan [23]	Case Series	N = 11 Male: 10 Female: 1	10–56 Mean: 32.27	BENIGN LESION: 2 Ameloblastoma (1) Giant cell granuloma (1) TRAUMA: Firearm injury (9)	3–14 Mean: 5.3	Iliac: 9 Fibular: 1 Others: 1	NO COMPLICATIONS
Akinbami & Akadiri [25]	Cohort Prospective	N = 20 Male: 10 Female: 10	10–54 Mean: 24.3	BENIGN LESION: 19 Ameloblastoma (16) Odontogenic keratocyst (2) Ossifying fibroma (1) MALIGNANT LESION: 1 Central basal adenoma (1)	4–8 Mean: not reported	Iliac: 20	ILIAC BONE GRAFT: Pain (week 1: 20; week 2: 15; week 4: 5) Restriction of limb movement (2) Altered gait (1)

Osborn et al. [4]	Cohort Retrospective	N = 60 Male: 37 Female: 23	13–67 Mean: not reported	BENIGN LESION: 30 MALIGNANT LESION: 1 TRAUMA: 2 INFECTIONS: 9 OTHERS: 18	<6–>9 Mean: not reported	Iliac: 60	ILIAC BONE GRAFT: Pain (3) Wound dehiscence (1)
Marechek et al. [26]	Cohort Retrospective	N = 29 Male: 17 Female: 12	17–81 Mean: 55 y	BENIGN LESION: 13 Ameloblastoma (6) Odontogenic keratocyst (4) Myxoma (1) Ossifying fibroma (2) MALIGNANT LESION: 2 Squamous cell carcinoma (1) Osteosarcoma (1) INFECTIONS: 11 Osteomyelitis/osteonecrosis (11) OTHERS: 3 Fibrous dysplasia (1) Nonunion (1) Pathological fracture (1)	2–22 Mean: 4.1 cm (for defect ≤6 cm) Mean: 11.5 cm (for defect >6 cm)	Iliac: 28 Others: 1	ILIAC BONE GRAFT: Infection (1) Wound dehiscence (1) Fracture (1)
Sharma et al. [27]	Cohort Retrospective	N = 16 Male: 10 Female: 6	17–81 Mean: 42 y	BENIGN LESION: 9 Ameloblastoma (4) Odontogenic keratocyst (2) Ossifying fibroma (2) Myxoma (1) INFECTIONS: 3 Osteomyelitis (3) OTHERS: 4 Pathological fracture (4)	3–22 Mean: Not reported	Others: 16	ILIAC BONE GRAFT: Infection Wound dehiscence Fracture

## Discussion

Reconstruction after mandibular resection needs to be performed to restore function and esthetics. Reconstruction can be performed using vascularized and nonvascularized bone grafts. The selection of a bone donor site depends on several factors, one of which is donor site morbidity. This systematic review aimed to evaluate the level of donor site morbidity using nonvascularized bone grafts. This systematic review had some limitations. First, from a total of 433 patients, 385 (88.9%) received nonvascularized IBGs and 48 (11%) received nonvascularized FBGs; thus, the imbalance between the iliac and fibular counts affected the final analysis in terms of donor site morbidity among both bone graft types. Second, one study used only a reconstructed iliac donor site, and the evaluation was therefore limited to the iliac donor site. Third, the criteria might not have fully included all the studies discussing the morbidity rates of nonvascularized iliac and FBG donor sites.

The evaluation of the donor site was conducted through periodic postoperative evaluations for up to 12 months [9,18-21,24,25]. Two other studies evaluated donor sites over a period of 6 months [27] and 18 months [26], respectively. In the other three studies, the time of the evaluation was not reported [4,22,23]. From the 385 cases of IBG, 153 cases (40%) were found to have complications at the iliac donor site, whereas in 48 cases of FBG, two (4%) experienced complications at the fibular donor site (Table 2). The greater use of the ilium as a donor site in all of the included studies might be because the ilium has better contours and fewer complications [24]. Additionally, the ilium provides an advantage for soft-tissue reconstruction and large postresection defects [28].

Several other studies also evaluated complications at the donor sites and categorized them into two groups on the basis of complication management [4,18,22,26,27]. Major complications included complications requiring intensive treatment in the hospital, such as blood transfusion, debridement, and drainage management in the operating room, persistent postoperative pain, and esthetic disturbances. Minor complications included complications requiring only outpatient treatment with medication or minor treatment in the dental unit. Minor complications included pain, temporary numbness, wound dehiscence, temporary limitation of limb movement, and infection [4,18,22,26,27]. In addition to these two groupings, Scheerlinck et al. [22] further categorized donor site complications on the basis of the time of occurrence, namely, intraoperative, early postoperative when the patient is still hospitalized, and late postoperative when the patient is discharged from the hospital.

The most common complications in the iliac donor site are minor complications. Rana et al. [9] and Akinbami and Akadiri [25] stated that all subjects in their studies experienced postoperative pain at the donor site. Scheerlinck et al. [22] reported 20 (36%) events of pain at the donor site in 55 patients who received IBG [22], and Osborn et al. [4] reported that three of 56 patients (5.3%) receiving IBG experienced pain. Several studies reported that infections, temporary gait disturbances, and wound dehiscence were the most common minor complications after pain, as listed in Table 2. Numbness was also found in studies conducted by Rana et al. [9] and Scheerlinck et al. [22]. Several studies reported major complications such as hemorrhage, bone fracture, infection requiring debridement, and hematoma [26,27].

Akinbami and Akadiri [25] reported donor site morbidity of iliac nonvascularized bone graft, which included pain and limitations in limb movement that improved more than 2 weeks postoperatively as well as a change in gait that improved within 3–6 weeks postoperatively. Pain at the donor site was assessed using the visual analog scale (VAS), with a score of 6–9 at 1 week postoperatively and then reducing to 3–6 and subsiding in most patients at week 4 [25].

Only three of the 12 studies used both iliac and fibular donor sites in their study and evaluated the morbidity of each donor site [9,18,23]. Of the 48 cases of FBG, only one study [9] reported two cases of minor complications in the form of infection leading to wound dehiscence and graft loss. Meanwhile, no complications were found at the donor site of the fibula in two other studies [18,23].

Based on all of the included studies, the morbidity at the fibular donor site tended to be minor compared with at the iliac donor site. However, major complications could also be found at the fibular donor site. This was reported by Kerrari et al. [29] and Fodor et al. [30], who found the presence of acute compartment syndrome (ACS) after a reconstruction procedure using FBG, resulting in the patient experiencing gait disturbances and disturbances in daily activities. Kerrari et al. [29] also confirmed that the incidence of ACS increased in obese patients and young adults. Additionally, Fodor et al. [30] found major complications at the donor site in the form of nerve injury fibula, ankle instability, and fractures.







Age and size of the defect are known risk factors for morbidity at the donor site. These clinical parameters were also analyzed by several studies. Scheerlinck et al. [22] stated that age did not correlate with the occurrence of complications at the donor site [25]. This finding was also supported by studies conducted by Brudnicki et al. [31] and Katz et al. [32], who compared the morbidity of the iliac donor site among different age groups. Brudnicki et al. [31] evaluated the morbidity of the iliac donor site among patients aged 1–40 years, whereas Katz evaluated patients aged 7–85 years. The research results by Brudnicki et al. [31] showed no statistically significant correlation between complaints at the donor site and age or gender. However, they found a tendency for women to experience pain at the donor site associated with older age. A limitation of the study was that the application of the VAS could not be performed in patients in the younger age groups [31]. Katz et al. [32], supporting the Brudnicki et al. [31] study, found no significant difference between gait disturbances, hernias, fractures, hyperesthesia, or wound problems in the younger group of patients (<60 years) and the older group of patients (≥60 years).

Because of their avascular nature, nonvascularized grafts are prone to infection and failure in larger defects [24]. Marechek et al. [26] found that three of 22 cases with large defects (<6 cm) had minor complications at the donor site. This was also explained by Allsopp et al. [28] in their study regarding the size of the defect and the use of nonvascularized bone grafts, where adequate research evidence was not provided to support the 6 cm defect rule for nonvascularized bone grafts because of the different evaluation mechanisms of each study [33]. Several strategies have been reported to reduce the morbidity at the donor site, such as well-prepared preoperative planning to reduce surgery time and pain and infection control at the donor site by prescribing analgesics and antibiotics [22].

## Conclusion

The morbidity rate of nonvascularized bone grafts of fibular donor sites (4%) tended to be lower than that of iliac donor sites (40%). Patient age and defect size were not significantly correlated with the occurrence of morbidity of the donor site in either the ilium or fibula. We suggest reducing the morbidity of iliac and fibular donor sites to increase the postoperative success of future reconstructive procedures.

## Authors' Contributions

LDS	 <a href="https://orcid.org/0000-0001-5542-6787">https://orcid.org/0000-0001-5542-6787</a>	Conceptualization, Methodology, Validation, Formal Analysis, Investigation, Resources, Data Curation, Writing - Original Draft and Writing - Review and Editing.
VJ	 <a href="https://orcid.org/0000-0001-6182-5688">https://orcid.org/0000-0001-6182-5688</a>	Conceptualization, Methodology, Validation, Formal Analysis, Investigation, Resources, Data Curation, Writing - Original Draft and Writing - Review and Editing.
TZR	 <a href="https://orcid.org/0000-0001-9839-6733">https://orcid.org/0000-0001-9839-6733</a>	Conceptualization, Methodology, Formal Analysis, Investigation, Data Curation, Writing - Original Draft, Writing - Review and Editing, Visualization and Project Administration.
DKD	 <a href="https://orcid.org/0000-0002-0772-2220">https://orcid.org/0000-0002-0772-2220</a>	Methodology, Formal Analysis, Investigation, Data Curation, Writing - Original Draft, Writing - Review and Editing, Visualization and Project Administration.

All authors declare that they contributed to critical review of intellectual content and approval of the final version to be published.

## Financial Support

None.

## Conflict of Interest

The authors declare no conflicts of interest.

## Data Availability

The data used to support the findings of this study can be made available upon request to the corresponding author.

## References

- [1] Silva L, Macedo R, Serpa M, Sobral A, Souza L. Global frequency of benign and malignant odontogenic tumors according to the 2005 WHO classification. *J Oral Diag* 2017; 2:1-8. <https://doi.org/10.5935/2525-5711.20170044>
- [2] Pogrel M, Kahnberg K, Andersson L. *Essentials of Oral and Maxillofacial Surgery*. Chichester, United Kingdom: John Wiley & Sons; 2014.
- [3] Bonanthaya K, Panneerselvam E, Manuel S, Kumar V, Rai A. *Oral and Maxillofacial Surgery for the Clinician*. Singapore: Springer; 2021.
- [4] Osborn TM, Helal D, Mehra P. Iliac crest bone grafting for mandibular reconstruction: 10-year experience outcomes. *J Oral Biol Craniofac Res* 2018; 8(1):25-9. <https://doi.org/10.1016/j.jobcr.2017.12.001>
- [5] Anand M, Panwar S. Commonly Utilized Non Vascularised Bone Grafts in Maxillofacial Reconstruction. In: Sun H. *Surgical Management of Head and Neck Pathologies [Internet]*. London: IntechOpen; 2021. <https://doi.org/10.5772/intechopen.96983>
- [6] Ahmed W, Adil Asim M, Ehsan A, Abbas Q. Non-vascularized autogenous bone grafts for reconstruction of maxillofacial osseous defects. *J Coll Phys Surg Pak* 2018; 28(1):17-21. <https://doi.org/10.29271/jcpsp.2018.01.17>
- [7] Oryan A, Alidadi S, Moshiri A, Maffulli N. Bone regenerative medicine: classic options, novel strategies, and future directions. *J Orthop Surg Res* 2014; 9(1):18. <https://doi.org/10.1186/1749-799X-9-18>
- [8] Agrawal A, Mehrotra D, Mohammad S, Singh RK, Kumar S, Pal US. Randomized control trial of non-vascularized fibular and iliac crest graft for mandibular reconstruction. *J Oral Biol Craniofac Res* 2012; 2(2):90-6. <https://doi.org/10.1016/j.jobcr.2012.05.002>
- [9] Rana M, Warrach R, Kokemüller H, Lemound J, Essig H, Tavassol F, et al. Reconstruction of mandibular defects—clinical retrospective research over a 10-year period -. *Head Neck Oncol* 2011; 3(1):23. <https://doi.org/10.1186/1758-3284-3-23>
- [10] Puricelli E, Chem RC. Thirty-eight-year follow-up of the first patient of mandibular reconstruction with free vascularized fibula flap. *Head Face Med* 2021; 17(1):46. <https://doi.org/10.1186/s13005-021-00293-z>
- [11] Sarukawa S, Noguchi T, Oh-Iwa I, Sunaga A, Uda H, Kusama M, et al. Bare bone graft with vascularised iliac crest for mandibular reconstruction. *J Craniomaxillofac Surg* 2012; 40(1):61-6. <https://doi.org/10.1016/j.jcms.2011.01.017>
- [12] Pang KM, Choi SW, Byun SH, Lee JY, Jung HJ, Lim KY, et al. Mandibular condylar-ramal reconstruction using vascularised costochondral graft based on the serratus anterior composite flap. *J Craniomaxillofac Surg* 2015; 43(7):1184-93. <https://doi.org/10.1016/j.jcms.2015.04.014>
- [13] Caldrony S, Ghazali N, Dyalram D, Lubek JE. Surgical resection and vascularized bone reconstruction in advanced stage medication-related osteonecrosis of the jaw. *Int J Oral Maxillofac Surg* 2017; 46(7):871-6. <https://doi.org/10.1016/j.ijom.2017.01.023>
- [14] Feuvrier D, Sagawa Y, Béliard S, Pauchot J, Decavel P. Long-term donor-site morbidity after vascularized free fibula flap harvesting: clinical and gait analysis. *J Plast Reconstr Aesthet Surg* 2016; 69(2):262-9. <https://doi.org/10.1016/j.bjps.2015.10.007>
- [15] Hadouiri N, Feuvrier D, Pauchot J, Decavel P, Sagawa Y. Donor site morbidity after vascularized fibula free flap: gait analysis during prolonged walk conditions. *Int J Oral Maxillofac Surg* 2018; 47(3):309-15. <https://doi.org/10.1016/j.ijom.2017.10.006>
- [16] Rendenbach C, Kohlmeier C, Suling A, Assaf AT, Catala-Lehnen P, Amling M, et al. Prospective biomechanical analysis of donor-site morbidity after fibula free flap. *J Craniomaxillofac Surg* 2016 ;44(2):155-9. <https://doi.org/10.1016/j.jcms.2015.10.027>
- [17] Hutton B, Salanti G, Caldwell DM, Chaimani A, Schmid CH, Cameron C, et al. The PRISMA extension statement for reporting of systematic reviews incorporating network meta-analyses of health care interventions: checklist and explanations. *Ann Intern Med* 2015; 162(11):777-84. <https://doi.org/10.7326/M14-2385>
- [18] Gadre PK, Ramanojam S, Patankar A, Gadre KS. Nonvascularized bone grafting for mandibular reconstruction: myth or reality? *J Craniofac Surg* 2011; 22(5):1727-35. <https://doi.org/10.1097/SCS.0b013e31822e633b>
- [19] ObimakindOkoje VN, Obimakinde OS, Arotiba JT, Fasola AO, Ogunlade SO, Obiechina AE. Mandibular defect reconstruction with nonvascularized iliac crest bone graft. *Niger J Clin Pract* 2012; 15(2):224-7. <https://doi.org/10.4103/1119-3077.97334>
- [20] Bai XF, Wushou A, Zheng J, Li G. An alternative approach for mandible reconstruction. *J Craniofac Surg* 2013; 24(2):e195-e198. <https://doi.org/10.1097/SCS.0b013e3182802269>
- [21] Magesh DP, Kumaravelu C, Maheshwari GU. Efficacy of PRP in the reconstruction of mandibular segmental defects using iliac bone grafts. *J Maxillofac Oral Surg* 2013; 12(2):160-7. <https://doi.org/10.1007/s12663-012-0418-y>
- [22] Scheerlinck LM, Muradin MS, van der Bilt A, Meijer GJ, Koole R, Van Cann EM. Donor site complications in bone grafting: comparison of iliac crest, calvarial, and mandibular ramus bone. *Int J Oral Maxillofac Implants* 2013; 28(1):222-7. <https://doi.org/10.11607/jomi.2603>
- [23] Akbay E, Aydogan F. Reconstruction of isolated mandibular bone defects with non-vascularized corticocancellous bone autograft and graft viability. *Auris Nasus Larynx* 2014; 41(1):56-62. <https://doi.org/10.1016/j.anl.2013.07.002>

- [24] Ndukwe KC, Aregbesola SB, Ikem IC, Ugboko VI, Adebisi KE, Fatusi OA, et al. Reconstruction of mandibular defects using nonvascularized autogenous bone graft in Nigerians. *Niger J Surg* 2014; 20(2):87-91. <https://doi.org/10.4103/1117-6806.137309>
- [25] Akinbami BO, Akadiri OA. Reconstruction of the mandible following benign tumor ablations: an audit of 20 cases. *J Oral Maxillofac Surg Med Pathol* 2015; 27(5):650-5. <https://doi.org/10.1016/j.ajoms.2015.01.009>
- [26] Marechek A, AlShare A, Pack S, Demko C, Queresby FA, Baur D. Nonvascularized bone grafts for reconstruction of segmental mandibular defects: is length of graft a factor of success? *J Oral Maxillofac Surg* 2019; 77(12):2557-66. <https://doi.org/10.1016/j.joms.2019.05.008>
- [27] Sharma S, Hotkar S, Matne A, Vallabhaneni S, Ravipati A, Khandelwal A. Reconstruction of continuity defects of the mandible with non-vascularized bone grafts- Original study. *Adv Med Dent Sci Research* 2020; 8(11):23-6. <https://doi.org/10.21276/jamdsr>
- [28] Allsopp BJ, Hunter-Smith DJ, Rozen WM. Vascularized versus nonvascularized Bone Grafts: what is the Evidence? *Clin Orthop Relat Res* 2016; 474(5):1319-27. <https://doi.org/10.1007/s11999-016-4769-4>
- [29] Kerrary S, Schouman T, Cox A, Bertolus C, Febrer G, Bertrand JC. Acute compartment syndrome following fibula flap harvest for mandibular reconstruction. *J Craniomaxillofac Surg* 2011; 39(3):206-8. <https://doi.org/10.1016/j.jcms.2010.03.012>
- [30] Fodor L, Dinu C, Fodor M, Ciuce C. Severe compartment syndrome following fibula harvesting for mandible reconstruction. *Int J Oral Maxillofac Surg* 2011; 40(4):443-5. <https://doi.org/10.1016/j.ijom.2010.10.021>
- [31] Brudnicki A, Rachwalski M, Wiepszowski Ł, Sawicka E. Secondary alveolar bone grafting in cleft lip and palate: a comparative analysis of donor site morbidity in different age groups. *J Craniomaxillofac Surg* 2019; 47(1):165-9. <https://doi.org/10.1016/j.jcms.2018.11.006>
- [32] Katz MS, Ooms M, Heitzer M, Peters F, Winnand P, Kniha K, et al. Postoperative morbidity and complications in elderly patients after harvesting of iliac crest bone grafts. *Medicina* 2021; 57(8):759. <https://doi.org/10.3390/medicina57080759>
- [33] Lonie S, Herle P, Paddle A, Pradhan N, Birch T, Shayan R. Mandibular reconstruction: meta-analysis of iliac- versus fibula-free flaps. *ANZ J Surg* 2016; 86(5):337-42. <https://doi.org/10.1111/ans.13274>