

# Clinical and Radiographic Success Rates of Pulpotomies in Primary Molars Treated with Formocresol, Biodentine™, and Endo Repair: A Randomized Clinical Trial

Elham Farokh Gisour<sup>1</sup>, Farzaneh Jalali<sup>2</sup>, Fatemeh Jahanimoghadam<sup>3</sup>, Tania Dehesh<sup>4</sup>

<sup>1</sup>Endodontology Research Center, Kerman University of Medical Sciences, Kerman, Iran.

<sup>2</sup>School of Dentistry, Kerman University of Medical Sciences, Kerman, Iran.

<sup>3</sup>Social Determinants on Oral Health Research Center, Kerman University of Medical Sciences, Kerman, Iran.

<sup>4</sup>Department of Biostatistics and Epidemiology, School of Public Health, Kerman University of Medical Sciences, Kerman, Iran.

**Correspondence:** Fatemeh Jahanimoghadam, Social Determinants on Oral Health Research Center, Kerman University of Medical Sciences, Kerman, Iran. **E-mail:** [fatemehjahani4@gmail.com](mailto:fatemehjahani4@gmail.com)

**Academic Editor:** Burak Buldur

**Received:** 09 January 2022 / **Review:** 17 April 2022 / **Accepted:** 09 June 2022

**How to cite:** Gisour EF, Jalali F, Jahanimoghadam F, Dehesh T. Clinical and radiographic success rates of pulpotomies in primary molars treated with formocresol, Biodentine™, and Endo Repair: a randomized clinical trial. *Pesqui Bras Odontopediatria Clín Integr.* 2023; 23:e220005. <https://doi.org/10.1590/pboci.2023.037>

## ABSTRACT

**Objective:** To compare the clinical and radiographic success rates of formocresol, Biodentine™, and Endo Repair agents in primary molars after 12 months. **Material and Methods:** This randomized double-blind clinical trial was conducted on healthy children referred to the Department of Pediatric Dentistry, Kerman, Iran, in 2018. One hundred twenty children (human primary molar teeth) aged 3–9 years were selected and randomly divided into three interventions (with pulpotomy medicament agents), including formocresol, Biodentine™, and Endo Repair. All pulpotomized teeth were restored using stainless steel crowns and evaluated clinically and radiographically during a 12-month follow-up. Fisher exact test was used to determine the association of categorical variables and the data were analysed with SPSS 25. **Results:** All the available teeth in formocresol and Biodentine™ groups obtained clinical success, whereas 62.5% of the Endo Repair group was successful in this regard. Radiographic success rates of the formocresol, Biodentine™, and Endo Repair groups were 94.7%, 70%, and 28.1% after a 12-month follow-up, respectively. Moreover, pulp canal obliteration was observed in 26.3%, 25%, and 12.5% of the formocresol, Biodentine™, and Endo Repair groups. **Conclusion:** This study reported a high rate of clinical success using both Biodentine™ and formocresol pulpotomy techniques. However, the radiographic success rate of formocresol was higher than that of Biodentine™, and Endo Repair was not considered a suitable pulpotomy medicament agent.

**Keywords:** Regenerative Endodontics; Formocresols; Tooth, Deciduous; Pulpotomy.

## Introduction

One of the most common oral diseases is dental caries, which remains a public health problem [1]. Pulp therapy is a controversial issue in pediatric dentistry treatment [2]. In this regard, the most important concern of pediatric dentists is to maintain the shape and function of a child's teeth until they exfoliate naturally [3]. A pulpotomy is the standard care for the treatment of carious asymptomatic vital primary teeth [4,5]. The main goal of the procedure is to preserve the vitality and function of the radicular pulp by coronal pulp amputation and keep the vital radicular tissue surface [6].

Regarding the significance of pulp vitality preservation, it is of utmost importance to select the proper strategy in pulp therapy. The success rate of pulpotomy depends on the degree of inflammation of the pulp [7,8]. Although there are many reports on the use of different types of materials in a pulpotomy, there is still no general agreement on this issue. Formocresol is one of the main successful medicament agents for use in a pulpotomy, and the utilization of this agent is common due to its excellent clinical success and ease of use [9].

However, there is some evidence of the carcinogenicity characteristic of formocresol [10,11]. Additionally, other concerns about the use of formocresol include cytotoxicity, allergenicity, mutagenicity, chromosomal damage to the dental pulp cells in tissue culture [12], chromosomal breaks, aberrations in peripheral lymphocytes [13], and mutagenesis of stem cells [14]. Therefore, it is critical to find alternative pulpotomy medicament agents.

In this regard, a new tricalcium-silicate cement (Biodentine™) is introduced by Septodont. The bioactivity and outstanding performance of Biodentine™ in vital pulp treatment were assessed in vitro and in vivo, which showed positive effects on the application of the materials in primary teeth pulpotomy [6,15-19]. Furthermore, this material has been noticed due to its great sealing ability, biocompatibility, stability, long-term impenetrability, low solvability, short setting time, and ability to induce hard tissue regeneration. Moreover, the necessity of a restorative material to fill the pulp chamber can be removed using Biodentine™ [20-22].

Endo Repair (Hoffman's Endo repair) is a new commercial material that has been available in powder and liquid form since 2017. The powder contains particles of calcium phosphate and hydroxyapatite. It can be used in direct and indirect pulp coverage, iatrogenic injury of the dental pulp, and root perforations. Another important use of this substance is in the treatment of primary teeth after the amputation of the vital pulp tissue. Some animal studies were performed on the applicability of calcium phosphate in pulp treatments [23,24]. However, despite the success of animal studies, there is a lack of human studies on using calcium phosphate and hydroxyapatite in pulpotomy.

Given the limited number of studies assessing the clinical and radiographic success in primary teeth pulpotomy, it seems that future clinical research should be performed to assess the new tricalcium-silicate cement, such as Biodentine™ (as substitute materials) compared to older medicament agents, including formocresol and mineral trioxide aggregate (MTA) in this regard. With this background in mind, this study aimed to compare the clinical and radiographic success rates of three agents (i.e., formocresol, Biodentine™, and Endo Repair) used in pulpotomy.

## Material and Methods

### Study Design and Ethical Clearance

The protocol of this randomized, double-blind, controlled clinical trial was approved by the Ethics Committee of Kerman University of Medical Sciences, Kerman, Iran and it was in accordance with the Helsinki

Declaration of Human Rights. The ethical code of the present study was IR.KMU.REC.1397.324 and its confirmation code was IRCT20180521039763N2.

In addition, the clinical procedure, logic of the treatment, and possible risks were explained completely before treatment, and informed consent was obtained from all parents. This study was conducted on healthy children referred to the Department of Pediatric Dentistry, Kerman, Iran, in 2018.

#### Inclusion and Exclusion Criteria

The inclusion criteria were: 1) age range within 3-9 years, 2) proper physical and mental development, 3) presence of at least one second primary molar tooth requiring pulpotomy treatment, and 4) possibility to refer for follow-up visits. Moreover, the dental selection clinical criteria for pulpotomy included: 1) pulp dental opening due to decay, 2) lack of pathological tooth mobility, 3) no pain in percussion or palpation, 4) no history of nocturnal or spontaneous pain, 5) no fistula, abscess or swelling, 6) possibility of restored of the teeth by a coat, and 7) controllability of the pulp bleeding after amputating two mm of it.

Furthermore, the radiographic criteria for tooth selection were: 1) pulp opening due to decay, 2) lack of internal or external pathological root resorption, 3) lack of radiolucency at the furcation or apex, and 4) lack of periodontal ligament (PDL) space widening.

On the other hand, the patients with any systemic diseases (i.e., leukemia preventing pulpotomy) and any radiographic findings, including internal and external root resorption, and PDL widening, as well as those with the presence of radiolucency around the apex or furcation, and pulp canal obliteration were excluded from the study. Moreover, if more than two-thirds of the root length underwent physiological resorption, the subjects were removed from the study.

#### Study Design

This study was conducted on healthy children referred to the Department of Pediatric Dentistry, Kerman, Iran, in 2018. The Cochran formula was used for sample size evaluation. Two hundred children were eligible for participation. After considering the inclusion and exclusion criteria, the (120 human primary molar teeth) aged 3-9 years, were selected and randomly through the table of random numbers divided into three groups (with pulpotomy medicament agents) of formocresol, Biodentine™, and Endo Repair (n=40). The groups were similar in age and gender and the initial condition of the tooth was determined based on clinical and radiographic criteria. Pulpotomy was performed by a postgraduate student of pediatric dentistry who could not be blinded to the materials and methods used, but the parents and patients were blinded to them.

In the first session, the demographic characteristics of medical records, including personal characteristics such as age, gender and medical and dental history, were completed for each participant. Moreover, the treatment steps were explained in detail to the assistant (the standard method of pulpotomy). After local anesthesia with lidocaine 2% and epinephrine 180,000 (Persocaine, Daroopaksh Company, Tehran, Iran) was administered using an anesthesia method (posterior superior alveolar block in the upper jaw and the inferior alveolar nerve block in the lower jaw) and rubber dam isolation according to the group in which the tooth was included.

Initially, a high-speed diamond fissure bur (Tizkavan, Tehran, Iran) was used to remove the carious enamel, and the carious dentin was excavated by a low-speed round carbide bur (Tizkavan, Tehran, Iran). Subsequently, the pulp chamber roof was exposed with a diamond fissure bur using a high-speed handpiece.

Following that, the pulp tissue was cut by a sharp spoon excavator, and after rinsing with normal saline, a sterile cotton pellet soaked in the normal saline was placed in the canals for 5 min to stop the bleeding. In case of prolonged bleeding, the teeth were excluded from the study and underwent pulpectomy.

In the first group, after controlling the bleeding, a sterile cotton pellet soaked in one to five dilutions of Buckley's formocresol (Sultan Healthcare, York, PA, USA) was placed onto the orifices of the canals for 5 min. After removing the cotton pellet, and when the canal entrance was brown or dark red, the tooth was temporarily restored with a zinc oxide eugenol cement (Zonalin-Kemdent, Associated Dental Products Ltd., Swindon, UK).

In the second group, Biodentine™ (Septodont, Saint-Maur-des-Fosses, France) based on the manufacturer's instructions, 5 drops of liquid were added to the powder-containing capsule, and the capsule was placed in an amalgamator for 30 seconds. After controlling the bleeding, the prepared mixture was placed on the exposure site, using a plastic spatula (Septodont, Saint-Maur-des-Fosses, France) and packed with a sterile cotton pellet moistened with normal saline.

Regarding the third group, after achieving hemostasis, according to the manufacturer's directions, at a two-to-three ratio of Endo Repair powder (Endo Repair, Hoffmann Dental Manufaktur, Berlin, Germany) and liquid mixed with a creamy consistency. Next, it was placed on the exposure site as a pulp dressing material.

Eventually, all pulpotomized teeth were restored with stainless steel crowns (SSC) (3M Unitek, St. Paul, MN, USA) and cemented using glass ionomer cement (Fuji I, GC Corp., Tokyo, Japan). In the next stage, all patients underwent clinical radiography evaluation for 12 months. After calibration, two blinded researchers performed the research process. Lack of pain, abscess or swelling, sensitivity to percussion and pathologic mobility, absence of a fistula, or unexplained sinus tract were the criteria for clinical success. Furthermore, the criteria for radiographic success were no internal resorption, external root pathological resorption furcal radiolucency, periradicular radiolucency, and PDL widening.

Follow-up evaluations were performed radiographically and clinically 12 months late. After calibration, two researchers who were not aware of the type of treatment commented on the radiographic criteria. In case of disagreement, a single conclusion was reached by discussing the disputed samples. If there was a disagreement between the two observers, a consensus was reached after discussion and re-evaluation of the case.

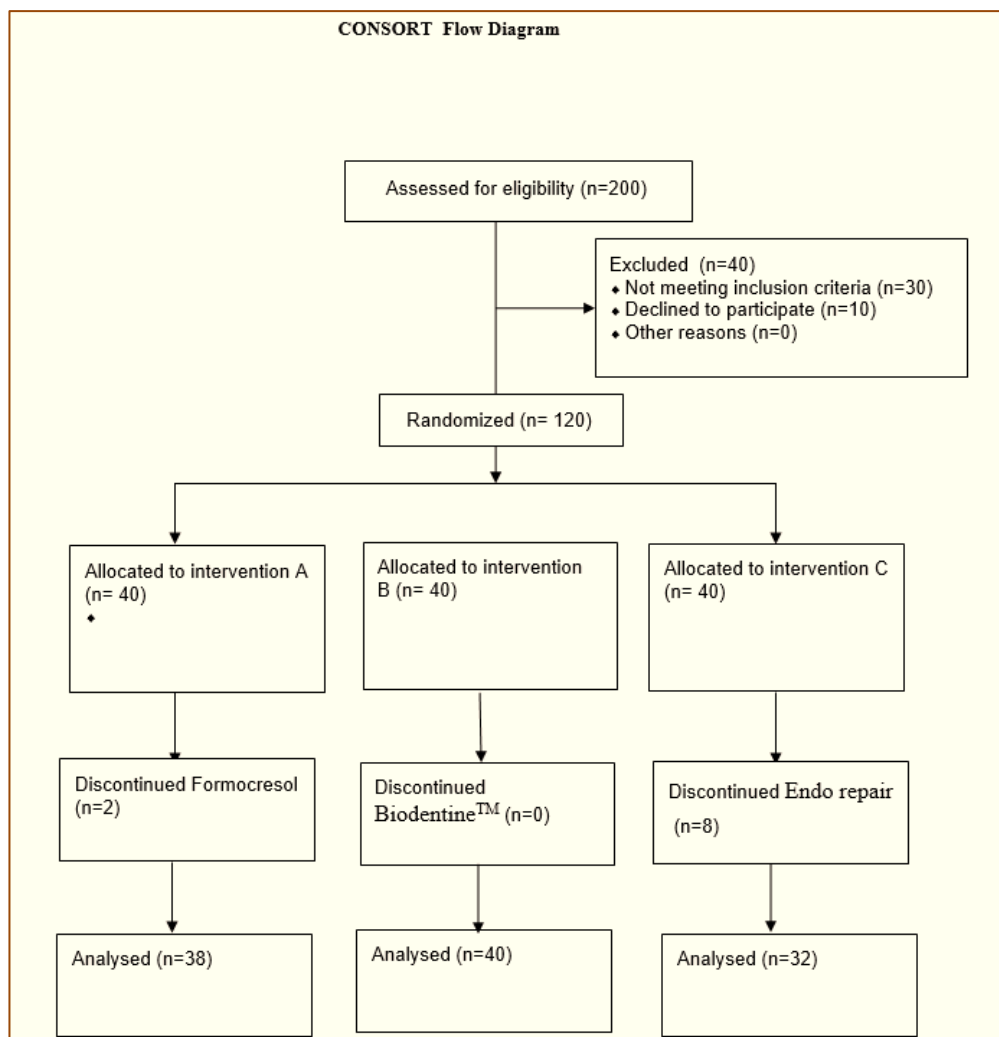
Pulp canal obliteration (PCO) was not observed as a failure. Periapical radiographs were used by the parallel technique with a Rinn XCP (Dentsply Sirona, York, PA, USA) to increase reproducibility. Furthermore, it should be noted that lead aprons and thyroid collars were used to reduce the patient's exposure to radiation in the follow-up visits. The information obtained in each group was recorded in separate files.

### Statistical Analysis

Data were analyzed in SPSS 20.0 software for Windows version 20. The frequency and percent of categorical variables were calculated. Fisher's exact test was used to determine the association of categorical variables (groups). A p-value less than 0.05 was considered statistically significant.

### Results

Out of 120 pulpotomized teeth (40 teeth in each group), 2 and 8 patients in the formocresol and the Endo Repair groups did not continue the 12-month follow-up, respectively. Accordingly, 110 teeth were followed up at the end of 12 months. Most patients were female ( $n=54$ , 51.4%) (Figure 1).



**Figure 1. Flow chart of the included and excluded patients.**

Table 1 shows the relationship between radiographic and clinical criteria in terms of pulpotomy failure using three agents. Based on the obtained results, the pain severity, abscess, or swelling of the teeth were higher in the Endo Repair group compared to other groups. Moreover, no significant difference was reported among the three groups regarding sensitivity to percussion and mobility. In addition, the three groups showed no significant difference regarding the internal resorption; however, the Endo Repair group obtained higher levels of external root pathological resorption, furcal radiolucency, and periradicular radiolucency compared to the other groups.

Furthermore, the comparison of the three groups showed no significant difference among the groups in terms of clinical criteria for pulpotomy failure. Moreover, PDL widening was higher in Endo Repair and Biodentine™ groups compared to the formocresol group. In the same line, the radiographic criteria of pulpotomy failure were higher in the Endo Repair group than in the Biodentine™ and formocresol groups.

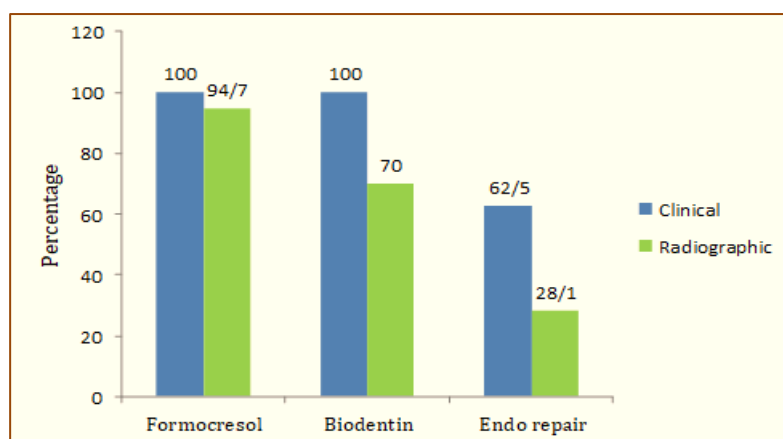
**Table 1. Relationship among the three groups in terms of radiographic and clinical criteria of pulpotomy failure.**

	Variables	Formocresol		Biodentine™		Endo Repair		p-value <sup>1</sup>
		N	%	N	%	N	%	
Clinical Criteria	Pain	0	0	0	0	5	15.8	0.002
	Swelling	0	0	0	0	5	15.8	0.002
	Mobility	0	0	0	0	2	6.3	0.080

	Sensitivity to percussion	0	0	0	0	0	0	0.990
	Fistula	0	0	0	0	3	9.4	0.020
	p-value	0.99		0.99		0.17		
Radiographic Criteria	Internal resorption	0	0	4	10	2	6.3	0.001
	External root pathological resorption	1	2.6	2	5	9	28.1	<0.001
	Furcal radiolucency	2	5.3	1.	2.5	19	59.4	<0.001
	Periradicular radiolucency	0	0	0	0	11	34.4	0.006
	PDL widening	0	0	7	17.5	8	25	0.006
	p-value	0.12		0.51		<0.001		

<sup>1</sup>Fisher exact test.

Figure 2 illustrates the comparison results of the three groups regarding clinical and radiographic success rates of pulpotomy after 12 months. Accordingly, the results of the clinical success of three agents (i.e., Endo Repair, Biodentine™, and formocresol) after 12 months showed a significant difference among them. As a result, the success rate of the Biodentine™ and formocresol was significantly higher than that of the Endo Repair group ( $p < 0.05$ ). Moreover, there was no significant difference between the Biodentine™ and formocresol groups regarding clinical success after 12 months ( $p > 0.05$ ).



**Figure 2. Comparison of three groups regarding clinical and radiographic success rates of pulpotomy after a 12-month follow-up.**

Similarly, the evaluation of the radiographic success of three substances after 12 months showed a significant difference among the groups, and the radiographic success rate of formocresol group was significantly higher than that of the Biodentine™ and Endo Repair groups ( $p < 0.05$ ).

The relationship of pulpotomy success rates with gender is shown in Table 2, which reveals no difference among these variables ( $p > 0.05$ ). In general, the success rate by clinical and radiographical approaches was 89% and 66.3%, respectively. It should be noted that pulp canal obliteration (PCO) was observed in 26.3%, 25%, and 12.5% of the formocresol, Biodentine™, and Endo Repair groups, respectively ( $p = 0.31$ ).

**Table 2. The relationship between gender with success rates of pulpotomy.**

Variables	Gender				p-value <sup>1</sup>	
	Male		Female			
	N	%	N	%		
Clinical	Success	60	88.2	38	90.5	0.76
	Failure	8	11.8	4	9.5	
Radiographical	Success	45	66.2	28	66.7	0.95
	Failure	23	33.8	14	33.3	

<sup>1</sup>Fisher exact test.



## Discussion

The failure of pulpotomy in primary molars may be observed in the furcation or periapical areas. Therefore, preoperative periapical radiographs are applied to monitor the prognosis of primary molars pulpotomy [25]. In general, the findings in this study showed that the pulpotomy failure was higher in the Endo Repair group compared to the Biodentine™ and formocresol groups. Moreover, the radiographic success rate of Formocresol was higher than that of Biodentine™ and Endo Repair groups. Regarding the clinical success rate, the Biodentine™ and formocresol groups obtained higher rates than the Endo Repair group. However, no difference was observed among the three groups in terms of PCO. Furthermore, no evidence was found about the relationship between the success rate and gender.

Although there is evidence of the success rate of pulpotomy for the treatment of extensive carious lesions approximating the pulp in primary teeth, the use of this approach remains a challenging issue due to insufficient clinical data [26]. Formocresol is a selective successful medicament agent for vital pulpotomy of the primary molars. Despite adverse reactions of formocresol, this mixture is a long-term successful medicament agent [27,28]. The performance of MTA, as a biological dressing, is similar to that of formocresol. However, prolonged setting time, difficult handling characteristics, and high material cost are the main problems in the utilization of MTA. Recently, Biodentine™ has been suggested to deal with the complications induced by formocresol and MTA [8,29,30]. Accordingly, it seems that this material can help preserve the vitality of the pulp in subjects who are candidates for pulpotomy procedures [31].

In this regard, some studies were performed to compare the materials with older medicament agents regarding vital pulpotomy of the primary molars [8,29,30]. Moreover, there is evidence of the excellent features of Biodentine™ compared to formocresol and MTA [25]. El Meligy et al. [25] conducted a randomized, split-mouth clinical study to determine the radiographic and clinical success rate of Biodentine™ pulpotomy technique compared to formocresol in pulpotomy of primary molars in children. They found favorable clinical and radiographic outcomes in both pulpotomy techniques at 3- and 6-month follow up [25].

Similar to our study, the results of a randomized clinical trial performed by Rubanenko et al. [32] revealed a similar clinical success rate of Biodentine™ (100%) and formocresol (100%) in pulpotomy of primary teeth, as it was observed in a study carried out by El Meligy et al. [25] using a longer follow-up. Radiographic success rates of formocresol and Biodentine™ were determined at 100% in a study carried out by Rubanenko et al. [32]. In another study, radiographic success rates of formocresol and Biodentine™ have been estimated at 95.24% and 94.4%, respectively [33]. Although equal clinical success rates of formocresol and Biodentine™ were found in this study, it was not confirmed in the case of radiographic success.

According to a systematic review, the total success rate at a 2-year follow-up period for formocresol regarding the vital pulpotomy of the primary teeth was obtained at 87.1% [34]. In the same way, multiple studies reported a high success rate of formocresol and Biodentine™ [2,5,17,29,30,35,36]. However, it is not in line with the obtained results of previously conducted studies, which can be attributed to the smaller sample size [37,38].

The clinical and radiographic success rates of three different pulpotomy agents of Biodentine™, MTA, and formocresol were assessed in another study carried out by Juneja and Kulkarni [6]. The obtained results of an 18-month follow-up showed a 100% clinical success rate of MTA and Biodentine™; however, the corresponding value was 73.3% for formocresol. Furthermore, the radiographic success rates were 73.3%, 100%, and 86.6% for MTA, Biodentine™, and formocresol, respectively [6]. The better clinical and radiographic

success rate of Biodentine™, compared to formocresol and MTA, was confirmed by other similar studies [37,39,40].

Although the radiographic success rate of formocresol was higher than that of Biodentine™ in this study, the radiographic success of Biodentine™ in primary molars pulpotomy was acceptable. Biodentine™ is suggested as an excellent replacement for formocresol due to its regenerative properties in primary molars pulpotomy [32]. Moreover, the high radiographic success rates of Biodentine™ could be related to its excellent sealing and regeneration abilities. Biocompatibility and alkalinity of the material are also higher compared to other medicament agents, which helps to increase its success chance. However, the evidence shows that formocresol is still more effective in terms of radiographic success rate compared to Biodentine™. The antiseptic (germicidal) and fixative properties of formocresol are the main factors in the increased success rate of this mixture.

A limited number of studies have been performed on Endo Repair containing hydroxyapatite and calcium phosphate particles. Our findings showed that the clinical and radiographic success rates of Endo Repair were lower than those of Biodentine™ and formocresol. In the Endo Repair group, several failures were identified in a short period, which could be due to the presence of undetected subclinical inflammation during treatment. Notably, severe postoperative pain was reported in two cases.

Gandolfi et al. suggested calcium silicate/calcium phosphate for the treatment of the vital pulp of human deciduous teeth [41]. In another study [42], clinical and radiographic success rates of hydroxyapatite in the primary molars pulpotomy were obtained at 100% and 80.33%, respectively. Similarly, Shayegan et al. [43] found no difference between hydroxyapatite and formocresol in terms of radiographic success. In another study, calcium phosphate cement was compared with formocresol, which showed no significant difference between them in this regard [44]. The low success rate of Endo Repair in our study can be attributed to the combination of hydroxyapatite and calcium phosphate, which is not an ideal material for pulp tissue. Moreover, fewer clinical and radiographic success rates in Endo Repair may also be due to the different time periods of tooth evaluation, improper selection of teeth for pulpotomy treatment, and leakage of microorganisms around the margins of the SSC.

The PCO is a radiographic finding in a pulpotomy, which results from vigorous odontoblastic activity and pulpotomy materials, such as formocresol, ferric sulfate, or Biodentine™ [2,30,36]. The PCO range was reported within 0-52% among the teeth treated with formocresol pulpotomy [29,30,37,45]. In our study, the PCO was observed in 26.3% and 25% of the formocresol and Biodentine™ groups, respectively; however, it was 12.5% in the Endo Repair group. In a study conducted by Holan et al. [37], the PCO rates were 58% and 52% in the MTA and formocresol groups, respectively, which was remarkably higher than that obtained in the current study.

According to a study by El Meligy et al. [25], the PCO occurred in 15.2% of the teeth treated with Biodentine™ and formocresol at a 6- and 12-month follow-up. Moreover, PCO was observed in 17.8% and 12.5% of the molars treated with Biodentine™ and formocresol, respectively [25]. It is worth mentioning that no significant difference was reported between Biodentine™ and formocresol groups in the mentioned study, which was consistent with our findings [25].

On the other hand, the frequency of PCO in the Biodentine™ technique was higher in the present study compared to a study carried out by El Meligy et al. [25]. Since our study is similar to the aforementioned study regarding the sample size, this inconsistency may be due to other unknown confounding variables [25].



In the present study, the most common cause of radiographic failure in the Biodentine™ group was PDL widening. However, in another study, the majority of the Biodentine™ radiographic failure was related to bone destruction around the root [39]. Moreover, in a study by Holan et al. [37], the majority of the radiographic failure in the formocresol group was due to furcal radiolucency and internal resorption, whereas no internal resorption was reported in our study.





Several studies have also suggested that teeth be repaired with SSC after pulpotomy since in addition to its long-term survival rate, it is reliable. In this study, the SSC was used to repair the teeth to homogenize all samples [31]. Moreover, treatment failure can manifest itself after a short time if the case selection is not correct. Failures may occur shortly after treatment; however, since clinical and radiographic examinations were performed after 12 months, some failures may have occurred much earlier. This emphasizes the importance of follow-ups in shorter periods. It should also be noted that the failure might be due to the leakage of microorganisms around the margins of the SSC.

A limited number of randomized clinical trials have recently compared formocresol, Biodentine™, and Endo Repair in primary molars pulpotomy. The adequate sample size is another advantage of the current study. However, the limited time for follow-up was the main limitation of our study. Moreover, blinding the assistant was not possible due to the different types of applied materials. On the other hand, the present study highlights the necessity of conducting further studies with longer follow-ups.

## Conclusion

The high clinical success rate of Biodentine™ and formocresol pulpotomy techniques was reported in this study. However, the radiographic success rate of the formocresol was higher than that of the Biodentine™. Therefore, although Biodentine™ was suggested as a promising material with a high success rate without any adverse effects in some studies, it seems that formocresol is still an ideal medicament agent in pulpotomy.

## Authors' Contributions

EFG		<a href="https://orcid.org/0000-0002-5907-2119">https://orcid.org/0000-0002-5907-2119</a>	Conceptualization, Resources.
FJ		<a href="https://orcid.org/0000-0002-4868-1285">https://orcid.org/0000-0002-4868-1285</a>	Writing - Original Draft, Writing - Review and Editing.
FJ		<a href="https://orcid.org/0000-0003-0990-5386">https://orcid.org/0000-0003-0990-5386</a>	Methodology, Validation, Formal Analysis, Data Curation.
TD		<a href="https://orcid.org/0000-0003-0083-0672">https://orcid.org/0000-0003-0083-0672</a>	Visualization, Supervision, Project Administration.

All authors declare that they contributed to critical review of intellectual content and approval of the final version to be published.

## Financial Support

None.

## Conflict of Interest

The authors declare no conflicts of interest.

## Data Availability

The data used to support the findings of this study can be made available upon request to the corresponding author.

## Acknowledgements

We thank all the participants for their patience and cooperation during this research.

## References

- [1] Kemoli A. Global disparity in childhood dental caries: Is there a remedy? *East Afr Med J* 2013; 90(4):130-6.
- [2] Erdem AP, Guven Y, Balli B, Ilhan B, Sepet E, Ulukapi I, et al. Success rates of mineral trioxide aggregate, ferric sulfate, and Formocresol pulpotomies: a 24-month study. *Pediatr Dent* 2011; 33(2):165-70.

- [3] Fuks AB. Vital pulp therapy with new materials for primary teeth: new directions and treatment perspectives. *Pediatr Dent* 2008; 30(3):211-9. <https://doi.org/10.1016/j.joen.2008.02.031>
- [4] Mythraiyee R, Rao V, Babu MM, Satyam M. Evaluation of the clinical and radiological outcomes of pulpotomized primary molars treated with three different materials: mineral trioxide aggregate, biodentine, and pulpotec. An in-vivo study. *Cureus* 2019; 11(6):e4803. <https://doi.org/10.7759/cureus.4803>
- [5] El Meligy OA, Allazzam S, Alamoudi NM. Comparison between biodentine and formocresol for pulpotomy of primary teeth: A randomized clinical trial. *Quintessence Int* 2016; 47(7):571-80. <https://doi.org/10.3290/j.qi.a36095>
- [6] Juneja P, Kulkarni S. Clinical and radiographic comparison of biodentine, mineral trioxide aggregate and formocresol as pulpotomy agents in primary molars. *Eur Arch Paediatr Dent* 2017; 18(4):271-8. <https://doi.org/10.1007/s40368-017-0299-3>
- [7] B, Rakesh K, Richa K. Clinical and radiographical evaluation of mineral trioxide aggregate, biodentine and propolis as pulpotomy medicaments in primary teeth. *Restor Dent Endod* 2015; 40(4):276-85. <https://doi.org/10.5395/rde.2015.40.4.276>
- [8] Sushynski JM, Zealand CM, Botero TM, Boynton JR, Majewski RF, Shelburne CE, et al. Comparison of gray mineral trioxide aggregate and diluted Formocresol in pulpotomized primary molars: a 6-to 24-month observation. *Pediatr Dent* 2012; 34(5):120-8.
- [9] Srinivasan V, Patchett C, Waterhouse P. Is there life after Buckley's Formocresol? Part I-a narrative review of alternative interventions and materials. *Int J Paediatr Dent* 2006; 16(2):117-27. <https://doi.org/10.1111/j.1365-263X.2006.00688.x>
- [10] Goldstein BD. Hematological and toxicological evaluation of formaldehyde as a potential cause of human leukemia. *Hum Exp Toxicol* 2011; 30(7):725-35. <https://doi.org/10.1177/0960327110381682>
- [11] Lewis BB, Chestner SB. Formaldehyde in dentistry: a review of mutagenic and carcinogenic potential. *J Am Dent Assoc* 1981; 103(3):429-34. <https://doi.org/10.14219/jada.archive.1981.0341>
- [12] Nishimura H, Higo Y, Ohno M, Tsutsui TW, Tsutsui T. Ability of root canal antiseptics used in dental practice to induce chromosome aberrations in human dental pulp cells. *Mutat Res* 2008; 649(1-2):45-53. <https://doi.org/10.1016/j.mrgentox.2007.07.007>
- [13] Zarzar P, Rosenblatt A, Takahashi C, Takeuchi P, Júnior LC. Formocresol mutagenicity following primary tooth pulp therapy: an in vivo study. *J Dent* 2003; 31(7):479-85. [https://doi.org/10.1016/S0300-5712\(03\)00087-3](https://doi.org/10.1016/S0300-5712(03)00087-3)
- [14] Zhang L, Steinmaus C, Eastmond DA, Xin XK, Smith MT. Formaldehyde exposure and leukemia: a new meta-analysis and potential mechanisms. *Mutat Res* 2009; 681(2-3):150-68. <https://doi.org/10.1016/j.mrrev.2008.07.002>
- [15] Han L, Okiji T. Bioactivity evaluation of three calcium silicate-based endodontic materials. *Int Endod J* 2013; 46(9):808-14. <https://doi.org/10.1111/iej.12062>
- [16] Nowicka A, Lipski M, Parafiniuk M, Sporniak-Tutak K, Lichota D, Kosierkiewicz A, et al. Response of human dental pulp capped with biodentine and mineral trioxide aggregate. *J Endod* 2013; 39(6):743-7. <https://doi.org/10.1016/j.joen.2013.01.005>
- [17] Bani M, Aktaş N, Çınar Ç, Odabaş ME. The clinical and radiographic success of primary molar pulpotomy using Biodentine™ and mineral trioxide aggregate: a 24-month randomized clinical trial. *Pediatr Dent* 2017; 39(4):284-8.
- [18] Niranjani K, Prasad MG, Vasa AAK, Divya G, Thakur MS, Saujanya K. Clinical evaluation of success of primary teeth pulpotomy using mineral trioxide aggregate®, laser and Biodentine™ - an in vivo study. *J Clin Diagn Res* 2015; 9(4):ZC35-7. <https://doi.org/10.7860/JCDR/2015/13153.5823>
- [19] Cuadros-Fernández C, Rodríguez AL, Sáez-Martínez S, García-Binimelis J, Mercadé M. Short-term treatment outcome of pulpotomies in primary molars using mineral trioxide aggregate and Biodentine: a randomized clinical trial. *Clin Oral Investig* 2016; 20(7):1639-45. <https://doi.org/10.1007/s00784-015-1656-4>
- [20] Bani M, Sungurtekin-Ekçi E, Odabaş ME. Efficacy of Biodentine as an apical plug in nonvital permanent teeth with open apices: an in vitro study. *Biomed Res Int* 2015; 2015:359275. <https://doi.org/10.1155/2015/359275>
- [21] Yoldaş SE, Bani M, Atabek D, Bodur H. Comparison of the potential discoloration effect of bioaggregate, biodentine, and white mineral trioxide aggregate on bovine teeth: in vitro research. *J Endod* 2016; 42(12):1815-8. <https://doi.org/10.1016/j.joen.2016.08.020>
- [22] Bhavya B, Sadique M, Simon EP, Ravi S, Lal S. Spectrophotometric analysis of coronal discoloration induced by white mineral trioxide aggregate and Biodentine: An in vitro study. *J Conserv Dent* 2017; 20(4):237. <https://doi.org/10.4103/0972-0707.219203>
- [23] Yoshimine Y, Maeda K. Histologic evaluation of tetracalcium phosphate-based cement as a direct pulp-capping agent. *Oral Surg Oral Med Oral Pathol Oral Radiol Endod* 1995; 79(3):351-8. [https://doi.org/10.1016/S1079-2104\(05\)80229-X](https://doi.org/10.1016/S1079-2104(05)80229-X)
- [24] Sena M, Yamashita Y, Nakano Y, Ohgaki M, Nakamura S, Yamashita K, et al. Octacalcium phosphate-based cement as a pulp-capping agent in rats. *Oral Surg Oral Med Oral Pathol Oral Radiol Endod* 2004; 97(6):749-55. <https://doi.org/10.1016/j.tripleo.2003.10.029>
- [25] El Meligy OAES, Alamoudi NM, Allazzam SM, El-Housseiny AAM. Biodentine™ versus formocresol pulpotomy technique in primary molars: a 12-month randomized controlled clinical trial. *BMC Oral Health* 2019; 19(1):1-8. <https://doi.org/10.1186/s12903-018-0702-4>

- [26] Smaïl-Faugeron V, Porot A, Muller-Bolla M, Courson F. Indirect pulp capping versus pulpotomy for treating deep carious lesions approaching the pulp in primary teeth: a systematic review. *Eur J Paediatr Dent* 2016; 17(2):107-12.
- [27] Winters J, Cameron AC, Widmer RP. Pulp therapy for primary and immature permanent teeth. *Handbook of Pediatric Dentistry*: Elsevier; 2013. p. 103-22. <https://doi.org/10.1016/B978-0-7234-3695-9.00007-9>
- [28] Chandrashekhar S, Shashidhar J. Formocresol, still a controversial material for pulpotomy: a critical literature review. *Restorative Dent* 2014; 2(3):114. <https://doi.org/10.4103/2321-4619.143594>
- [29] Agamy HA, Bakry NS, Mounir MM, Avery DR. Comparison of mineral trioxide aggregate and formocresol as pulp-capping agents in pulpotomized primary teeth. *Pediatr Dent* 2004; 26(4):302-9.
- [30] Farsi N, Alamoudi N, Balto K, Mushayt A. Success of mineral trioxide aggregate in pulpotomized primary molars. *Int J Clin Pediatr Dent* 2005; 29(4):307-11. <https://doi.org/10.17796/jcpd.29.4.n80t77w625118k73>
- [31] Zanini M, Sautier JM, Bernal A, Simon S. Biodentine induces immortalized murine pulp cell differentiation into odontoblast-like cells and stimulates biomineralization. *J Endod* 2012; 38(9):1220-6. <https://doi.org/10.1016/j.joen.2012.04.018>
- [32] Rubanenko M, Moskovitz M, Petel R, Fuks A, editors. Effectiveness of Biodentine versus formocresol as dressing agents in pulpotomized primary molars: preliminary results. Sopot, Poland: 12th congress of EAPD; 2014.
- [33] Rajasekharan S, Martens L, Vandenbulcke J, Jacquet W, Bottenberg P, Cauwels R. Efficacy of three different pulpotomy agents in primary molars: a randomized control trial. *International J Endod* 2017; 50(3):215-28. <https://doi.org/10.1111/iej.12619>
- [34] Coll JA, Seale NS, Vargas K, Marghalani AA, Al Shamali S, Graham L. Primary tooth vital pulp therapy: a systematic review and meta-analysis. *Pediatr Dent* 2017; 39(1):16-123.
- [35] Sonmez D, Sari S, Çetinbaş T. A comparison of four pulpotomy techniques in primary molars: a long-term follow-up. *J Endod* 2008; 34(8):950-5. <https://doi.org/10.1016/j.joen.2008.05.009>
- [36] Awawdeh L, Al-Qudah A, Hamouri H, Chakra RJ. Outcomes of vital pulp therapy using mineral trioxide aggregate or biodentine: a prospective randomized clinical trial. *J Endod* 2018; 44(11):1603-9. <https://doi.org/10.1016/j.joen.2018.08.004>
- [37] Holan G, Eidelman E, Fuks AB. Long-term evaluation of pulpotomy in primary molars using mineral trioxide aggregate or formocresol. *Pediatr Dent* 2005; 27(2):129-36.
- [38] Jabbarifar SE, Khademi AA, Ghasemi D. Success rate of formocresol pulpotomy versus mineral trioxide aggregate in human primary molar tooth. *J Res Med Sci* 2004; 9(6):55-8.
- [39] Carti O, Oznurhan F. Evaluation and comparison of mineral trioxide aggregate and biodentine in primary tooth pulpotomy: Clinical and radiographic study. *Niger J Clin Pract*. 2017; 20(12):1604-9. <https://doi.org/10.4103/1119-3077.196074>
- [40] Aeinehchi M, Dadvand S, Fayazi S, Bayat-Movahed S. Randomized controlled trial of mineral trioxide aggregate and formocresol for pulpotomy in primary molar teeth. *Int Endod J* 2007; 40(4):261-7. <https://doi.org/10.1111/j.1365-2591.2007.01209.x>
- [41] Gandolfi M, Spagnuolo G, Siboni F, Procino A, Riviaccio V, Pelliccioni G, et al. Calcium silicate/calcium phosphate biphasic cements for vital pulp therapy: chemical-physical properties and human pulp cells response. *Clin Oral Investig* 2015; 19(8):2075-89. <https://doi.org/10.1007/s00784-015-1443-2>
- [42] Adlakha VK, Chandna P, Joshi J, Thomas A, Singh N. A comparative evaluation of hydroxyapatite crystals and glutaraldehyde as agents for pulpotomy in deciduous molars. *Int J Clin Pediatr Dent* 2009; 2(1):13. <https://doi.org/10.5005/jp-journals-10005-1035>
- [43] Shayegan A, Atash R, Petein M, Abbee AV. Nanohydroxyapatite used as a pulpotomy and direct pulp capping agent in primary pig teeth. *J Dent Child* 2010; 77(2):77-83.
- [44] Jose B, Ratnakumari N, Mohanty M, Varma H, Komath M. Calcium phosphate cement as an alternative for formocresol in primary teeth pulpotomies. *Indian J Dent Res* 2013; 24(4):522. <https://doi.org/10.4103/0970-9290.118370>