



One-step laparoscopic abomasopexy versus abomasopexy via right paralumbar fossa to treat left abomasal displacement in dairy cows¹

João H. Perotta^{2*}, Hugo R. Dyck², Rüdiger D. Ollhoff³, Júlio A.N. Lisbôa⁴,
Nilton Vieira⁵ and Ivan R. Barros Filho²

ABSTRACT.- Perotta J.H., Dyck H.R., Ollhoff R.D., Lisbôa J.A.N., Vieira N. & Barros Filho I.R. 2018. **One-step laparoscopic abomasopexy versus abomasopexy via right paralumbar fossa to treat left abomasal displacement in dairy cows.** *Pesquisa Veterinária Brasileira* 38(6):1068-1076. Departamento de Medicina Veterinária, Universidade Federal do Paraná, Rua dos Funcionários 1540, Juvevê, Curitiba, PR 80035-050, Brazil. E-mail: perotta@ufpr.br

This study aimed to compare the clinical and metabolic results obtained by use of one-step laparoscopic abomasopexy and right paralumbar fossa abomasopexy for the treatment of left displaced abomasum in dairy cows. Thirty Holstein-Friesian dairy cows were randomly placed in two groups: G1, with 15 animals treated by one-step laparoscopic abomasopexy; and G2, with 15 animals treated by right paralumbar fossa ventral abomasopexy. Concentrations of sodium, potassium, chloride, bicarbonate, base excess (BE), pH, partial pressure of carbon dioxide (pCO₂), strong ion difference (SID), anion gap (AG), glucose, β-hydroxybutyrate (BHBA) and non-esterified fatty acids (NEFA) were measured before (M0) and 24 (M1), 48 (M2) and 72 (M3) hours following surgery. Laparotomy was statistically faster than laparoscopy. Hypochloremia was observed only in G2 at M0. Hypokalemia and hypocalcemia were observed in both groups at M0, increasing after surgery. Metabolic alkalosis in both groups before surgery was characterized by high bicarbonate, pCO₂, and BE, which decreased in subsequent time points, as well as blood pH. Glucose was statistically increased and NEFA and BHBA were statistically decreased in G2 compared to G1. In G1, NEFA and BHBA decreased significantly following surgery. Both surgical techniques restored abomasal flow and feed intake in both groups. Based in acid-base status, one-step laparoscopy showed no additional advantage in comparison with abomasopexy via right paralumbar fossa.

INDEX TERMS: Laparoscopic abomasopexy, abomasopexy, abomasal displacement, dairy cows, abomasum, acid-base status, cattle, bovine, minimally invasive, surgery.

RESUMO.- [Abomasopexia por laparoscopia em um passo em comparação à abomasopexia via laparotomia pelo flanco direito no tratamento do deslocamento de abomaso à esquerda em vacas leiteiras.] Este estudo objetivou

comparar as técnicas de abomasopexia por laparoscopia em um passo e abomasopexia por laparotomia pelo flanco direito, no tratamento do deslocamento de abomaso à esquerda (DAE) em vacas leiteiras quanto a recuperação clínica no pós-operatório, utilizando parâmetros clínicos, metabólicos e eletrolíticos. Trinta vacas Holandesas preto e brancas foram distribuídas de forma aleatória em dois grupos: G1 com 15 animais tratados pela técnica de abomasopexia em um passo; e G2, com 15 animais tratados pela abomasopexia por laparotomia pelo flanco direito. Foram mensuradas as concentrações séricas de sódio, potássio, cloro, bicarbonato, excesso de base (BE), pH sanguíneo, pressão parcial de gás carbônico (pCO₂), diferença de íons fortes (SID), ânion gap (AG), glicose, β-hidroxibutirato (BHBA) e ácidos graxos não esterificados (NEFA). As variáveis foram mensuradas antes da operação e 24, 48 e 72 horas após operação. A laparotomia foi estatisticamente mais rápida do que a laparoscopia no tratamento do DAE.

¹ Received on April 13, 2017.

Accepted for publication on May 12, 2017.

² Departamento de Medicina Veterinária, Universidade Federal do Paraná (UFPR), Rua dos Funcionários 1540 Juvevê, Curitiba, PR 80035-050, Brazil. E-mails: ivanbarf@ufpr.br, hugodyck@gmail.com; *Corresponding author: perotta@ufpr.br

³ Universidade Católica do Paraná, Rua Imaculada Conceição 115, Prado Velho, Curitiba, PR 80215-901, Brazil. E-mail: ollhoff@gmail.com

⁴ Departamento de Clínicas Veterinárias, Universidade Estadual de Londrina (UEL), Campus Universitário, Cx. Postal 10.011, Londrina, PR 86057-970, Brazil. E-mail: janlisboa@uel.br

⁵ Médico Veterinário Autônomo, Rua José Nunes de Souza 537, Arapoti, PR 84990-000, Brazil. E-mail: nilvie@brturbo.com.br

Hipocloremia foi observada somente nas vacas do G2 antes da cirurgia. Alcalose metabólica em ambos os grupos antes da operação foi caracterizada pelo aumento do bicarbonato, pCO_2 e BE, os quais diminuíram significativamente nos momentos subsequentes, assim como o pH sanguíneo. A concentração de glicose apresentou aumento significativo no G2 em comparação ao G1, enquanto o BHBA e o NEFA estavam estatisticamente diminuídos. Ambas as técnicas restauraram o fluxo abomasal e o consumo de alimentos em ambos os grupos. Baseado no equilíbrio ácido-base, a técnica de laparoscopia não demonstrou vantagens sobre a técnica cirúrgica tradicional.

TERMOS DE INDEXAÇÃO: Abomasopexia, laparoscopia, abomasopexia, laparotomia, abomaso, vacas leiteiras, bovinos, cirurgia, equilíbrio ácido-base, minimamente invasiva.

INTRODUCTION

Since first reports of left abomasal displacement (LAD) in the second half of the past century (Begg 1950, Ford 1950), this disease has increased in prevalence and importance worldwide (Van Winden & Kuiper 2003). This disorder more often affects dairy cattle, such as Holstein-Friesian, Guernsey and Jersey (Van Winden & Kuiper 2003), one month after calving, and increases in older cows (Constable et al. 1992). However, a recent study showed higher incidence in younger cows (Sexton et al. 2007).

Numerous surgical methods have been used to treat LAD, each one with advantages and disadvantages (Seeger et al. 2006). The approaches can be classified as invasive and minimally invasive techniques. Invasive methods include abomasopexy via right paralumbar (Straiton & McIntee 1959) or left paralumbar fossa laparotomy (Ames 1968), left paralumbar (Lagerweij & Numans 1962, 1968) or right paralumbar fossa omentopexy (Dirksen 1961, 1967) and right paralumbar fossa pyloro-omentopexy (Bartlett et al. 1995, Baird & Harrison 2001, Câmara et al. 2010). Left and right paralumbar fossa omentopexy are the most accepted surgical methods due to a low rate of relapse (Bückner 1995). Blind stich (Hull 1972) and toggle-pin suture (Grymer & Sterner 1982) are minimally invasive procedures that were developed as low cost alternatives to more invasive surgical techniques (Hull 1972, Grymer & Sterner 1982), indicated for debilitated or less valuable animals (Bartlett et al. 1995).

Janowitz (1998) described a minimally invasive technique using laparoscopy. However, this procedure is performed in two steps and the cow is placed in dorsal recumbency, which is more physically straining for the cow, owner and veterinarian, besides the risk of aspiration pneumonia, and trauma (van Leeuwen et al. 2009).

One-step laparoscopic abomasopexy was described in the last decade and can be performed in dorsal recumbency (Newman et al. 2005, Babkine et al. 2006) or in standing position (Barisani 2004, Christiansen 2004). The approaches of Christiansen (2004) and Barisani (2004) have been extensively used to treat LAD (Van Leeuwen et al. 2009, Freick et al. 2013), and right abomasal displacement (Freick et al. 2013). However, no randomized controlled trial has been conducted comparing one-step laparoscopic abomasopexy and abomasopexy or omentopexy via right paralumbar fossa.

The objective of this study was to compare the efficacy, clinical outcomes and characteristics achieved of one-step

laparoscopic abomasopexy and abomasopexy via right paralumbar fossa laparotomy for the treatment of LAD in dairy cows, based on clinical assessments, acid-base balance and metabolic profile.

MATERIALS AND METHODS

The Animal Care and Use Committee of Universidade Federal do Paraná approved this study (protocol number 056/2013). Thirty Holstein-Friesian cows naturally affected by LAD were used in this experiment. The animals were from nine high-yielding dairy farms (higher than 8500 kg/milk/305 days/per cow) from the municipality of Arapoti (24°09'28"S 49°49'37"O), Paraná state, Brazil.

The cows were randomly distributed in two groups:

- Group 1 (G1), with 15 cows, which were submitted to one-step laparoscopic abomasopexy, according to Christiansen (2004). Mean \pm SD weight, age and number of lactation of the cows were 639.47 \pm 125.87kg, 4.09 \pm 1.33 years old and 2.20 \pm 1.08 lactations respectively.
- Group 2 (G2, control group), with 15 cows, which were submitted to right paralumbar fossa laparotomy and ventral abomasopexy, according to Baker (1976) as modified by Vieira. Mean \pm SD weight, age and number of lactations of the cows were 618.73 \pm 88.55kg, 4.25 \pm 1.83 years old and 2.27 \pm 1.39 lactations respectively.

The animals were selected from dairy farms with occurrence of LAD. However, cows with mild or severe lameness in one limb (phlegmon, deep sole ulcer and fractures), severe endometritis or severe mastitis with fever, and acute or chronic diarrhea were excluded from the experiment.

Altogether 34 cows were operated, but four animals were excluded due complications during postoperative period. All surgical procedures were undertaken from February to April 2015 under field conditions, between 08:00 a.m. and 11:00 p.m. The laparoscopies were performed by one surgeon (JHP) with assistance of two other surgeons (HRD and IRBF). Right flank abomasopexy was performed by one experienced surgeon (NV) with assistance of two others (JHP and HRD).

The diagnosis of LAD was made based in physical examination (heart and respiratory rates, rectal temperature and number of rumen contractions per five minutes), historical of drop in milk production and auscultation with percussion and succussion of left paralumbar fossa (Dirksen 1961).

Blood samples were taken from the jugular vein before surgery (M0) and 24 (M1), 48 (M2), and 72 hours (M3) after surgery. Blood was analyzed for partial pressure of carbon dioxide (pCO_2), pH, base excess (BE), bicarbonate, ionized calcium, glucose and packed cell volume (PCV) with a CG8+ cartridge (i-STAT® Point of Care, Abbott Laboratories, Illinois, USA).

Blood samples were centrifuged and serum was separated and stored at -21°C until further laboratory analysis. Beta-hydroxybutyrate (BHBA) and non-esterified fatty acids (NEFA) were measured using a commercial test kit (Randox Laboratories Ltd., County Antrim, UK) and an automatic analyzer (BS-200 Chemistry Analyzer, Mindray, Shenzhen, China). Sodium, potassium and chloride ions were measured using an ion-selective electrode (Dimension, Siemens Healthcare GmbH, Munich, Germany).

Strong ion difference and anion gap were calculated using the formulas: $SID = (Na^+ + K^+) - Cl^-$ (Constable et al. 2005) and $Anion\ Gap = (Na^+ + K^+) - (Cl^- + HCO_3^-)$ (Dibartola 2012).

Results of physical and laboratory exams before surgery (M0) and on three consecutive days after surgery (M1, M2 and M3) were included in the study.

One-step laparoscopy abomasopexy was performed according to Christiansen (2004), using surgical instruments developed for this approach (Dr. Fritz GmbH, Tuttlingen-Möhringen, Germany). The cows were restrained in headgates and the area 15cm ventral of transverse process and 5cm caudal to the last rib was clipped and desensitized using 10mL of 2% lidocaine without vasoconstrictor. An 8.0mm trocar was introduced dorsocaudally after skin incision, perforating abdominal muscles and peritoneum to introduce the 7.0mm optic probe. An air pump was connected to this device to create a pneumoperitoneum. In another area over the 11th left intercostal space, after clipping and local anesthesia, a 12mm working channel was introduced under laparoscopic guidance. The abomasum was located and perforated next to the great omentum at the great abomasal curvature by a 5.0mm cannula. The toggle bar suture was introduced into the abomasum using a rod, and then the viscera were deflated. The spieker was introduced into the abdomen and the ventral abdominal wall was perforated. A nylon thread was tied at the ventral extremity of the big needle, which was removed from the abdomen. At this moment, one end of the nylon thread was in the ventral paramedian region and the other in the left body wall. The toggle bar suture was tied with nylon thread and the ventral extremity was pulled, exteriorizing the toggle bar suture, which was tied using a gauze roll.

The Christiansen (2004) technique was modified in large-framed cows with weight ≥ 700 kg, because of the impossibility of tying the abomasum at the right paramedian side. To accomplish this, a third access, over the 11th intercostal space, 15cm ventrally of the second access was used to introduce the working channel and the spieker. To conduce the toggle bar suture ventrally, first the thread had to be recovered through the third access, using a hook, since the thread was in the second portal. Afterwards, the surgery was completed as described by Christiansen (2004).

Right paralumbar fossa abomasopexy was performed according to Baker (1976) as modified by Vieira. The right flank was clipped and anesthetized with 40mL of 2% lidocaine without vasoconstrictor at the surgery site. The skin, muscles and peritoneum were incised and the abomasum was located in the left abdomen. The viscus was

deflated using a needle attached to a rubber tube. The abomasum was pulled to the right ventral abdomen and an abomasal fold was created using the left hand fingers. An "S" shaped needle with cotton thread was introduced using the right hand from the outside to the inside of the abdomen, passing through the abomasal fold and returning to the outside, again passing through the abomasum. The thread was tied using gauze roll. In both groups, the threads were removed after one week.

All cows from G2 were treated by intra-abdominal administration of 5,000,000 IU of benzylpenicillin procaine immediately before suturing the laparotomy site. Antibiosis continued by intramuscular administration of 5,000,000 IU of benzylpenicillin procaine immediately after surgery and until the end of the study in both groups.

Repeated measure ANOVA with two factors (time and treatment) was used to compare the results. When F was statistically significant, the Bonferroni test was applied to compare the means. Test results were considered significant for values of $P \leq 0.05$. Differences between surgery duration were evaluated by the *t* test. The SigmaStat for Windows 3.1 program (Systat Software Inc., California, USA) was used for all statistical analyses.

RESULTS

During the study period, 34 cows were operated: 19 by one-step laparoscopic abomasopexy and 15 by abomasopexy via right paralumbar fossa. The surgical procedure was successfully completed in 18 of 19 cows of G1 (94.73%) and in all cows (100%) of G2. In the one animal in which we were not able to complete the surgical procedure, one extremity of the toggle thread remained in the abdominal cavity, preventing abomasal replacement. In this specific animal, the Barisani (2004) method was used. Three cows from G1 were excluded, one due to pylorus obstruction diagnosed 48 h following surgery and two died 72 h and 120 h after surgery, due to uterine infection and hemorrhage following abomasal perforation.

Cardiac and respiratory rate, body temperature (data not shown), packed cell volume and ruminal motility (Fig.1) did not differ statistically between groups. No statistical differences in ruminal motility were observed in G2, and in both groups regarding heart and respiratory rate and body temperature. Higher ruminal motility was observed at M3

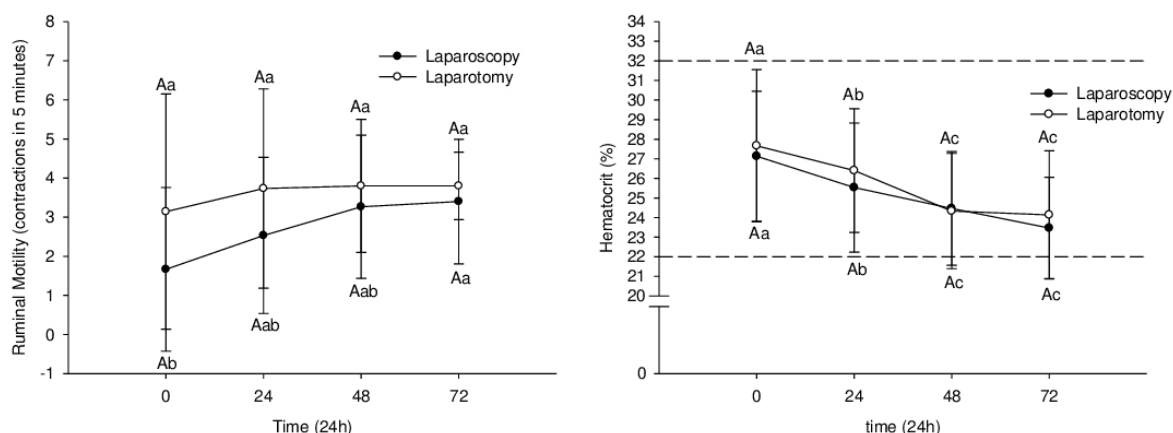


Fig.1. Mean \pm standard deviation of packed cell volume and ruminal motility from 30 Holstein cows with left abomasal displacement treated by one-step laparoscopy (laparoscopy, black circle; $n=15$) or abomasopexy via right paralumbar fossa (laparotomy; white circle; $n=15$) before (0) and during the first three days after surgery. Different capital letters differ between groups ($p \leq 0.05$). Different small letters differ between time points inside groups ($p \leq 0.05$). Dashed lines represent the upper and lower reference values.

($p=0.039$) compared to M0 in G1. The cows were slightly dehydrated before surgery, with packed cell volume decreasing significantly in both groups at M1 ($p<0.008$ and $p<0.007$ for G1 and G2 respectively), at M2 ($p<0.001$ for both groups), and at M3 ($p<0.001$ for both groups).

Hypochloremia was not observed before surgery in G1, but mild hypochloremia was observed in G2, and hypokalemia was noted in both groups (Fig.2). Despite increasing to reference values following surgery, no statistical differences between groups and time points inside the groups were observed for chloremia. Cows from G2 were still hypokalemic at M1, although potassium increased significantly in both groups following surgery at M1 ($p<0.001$) in G1 and at M2 ($p<0.001$ and $p=0.004$ for G1 and G2, respectively) and M3 ($p<0.001$ and $p=0.002$ for G1 and G2, respectively). However, no statistical difference was observed between G1 and G2 for potassium and sodium ions. Sodium concentration remained in the reference range, but decreased significantly at M1 in G1 ($p=0.033$) and increased significantly at M2 in G2 ($p=0.011$) (Fig.2). Ionized calcium did not differ statistically between groups (Fig.2). The cows from both groups were

hypocalcemic at M0 and M1, increasing at M2 and M3, which differed significantly from M0 in both groups ($p<0.001$ in G1 for both M2 and M3; $p=0.002$ and $p<0.001$ in G2 for M2 and M3, respectively). However, at all time points ionized calcium concentration remained below reference values.

Bicarbonate and BE were higher in both groups at M0 (Fig.3), indicating metabolic alkalosis, despite normal pH values. In both groups, bicarbonate concentration ($p=0.03$, $p=0.045$, $p=0.045$ for M1, M2 and M3 from G1; $p=0.05$, $p=0.045$, $p=0.045$ for M1, M2 and M3 from G2) and BE ($p=0.02$, $p=0.09$, $p=0.05$ for M1, M2 and M3 from G1; $p=0.03$, $p=0.09$, $p=0.045$ for M1, M2 and M3 from G2) decreased significantly following surgery, but only in G1 bicarbonate showed physiological values. No statistical difference was found comparing groups in bicarbonate, blood pH, pCO_2 and BE (Fig.3). Partial pressure of carbon dioxide did not differ significantly between time points in both groups. Data on pH showed statistically significant decrease in G2 following surgery at all time points ($p=0.02$, $p=0.07$ and $p=0.044$ for M1, M2, and M3 respectively) and at M1 ($p=0.07$) and M2

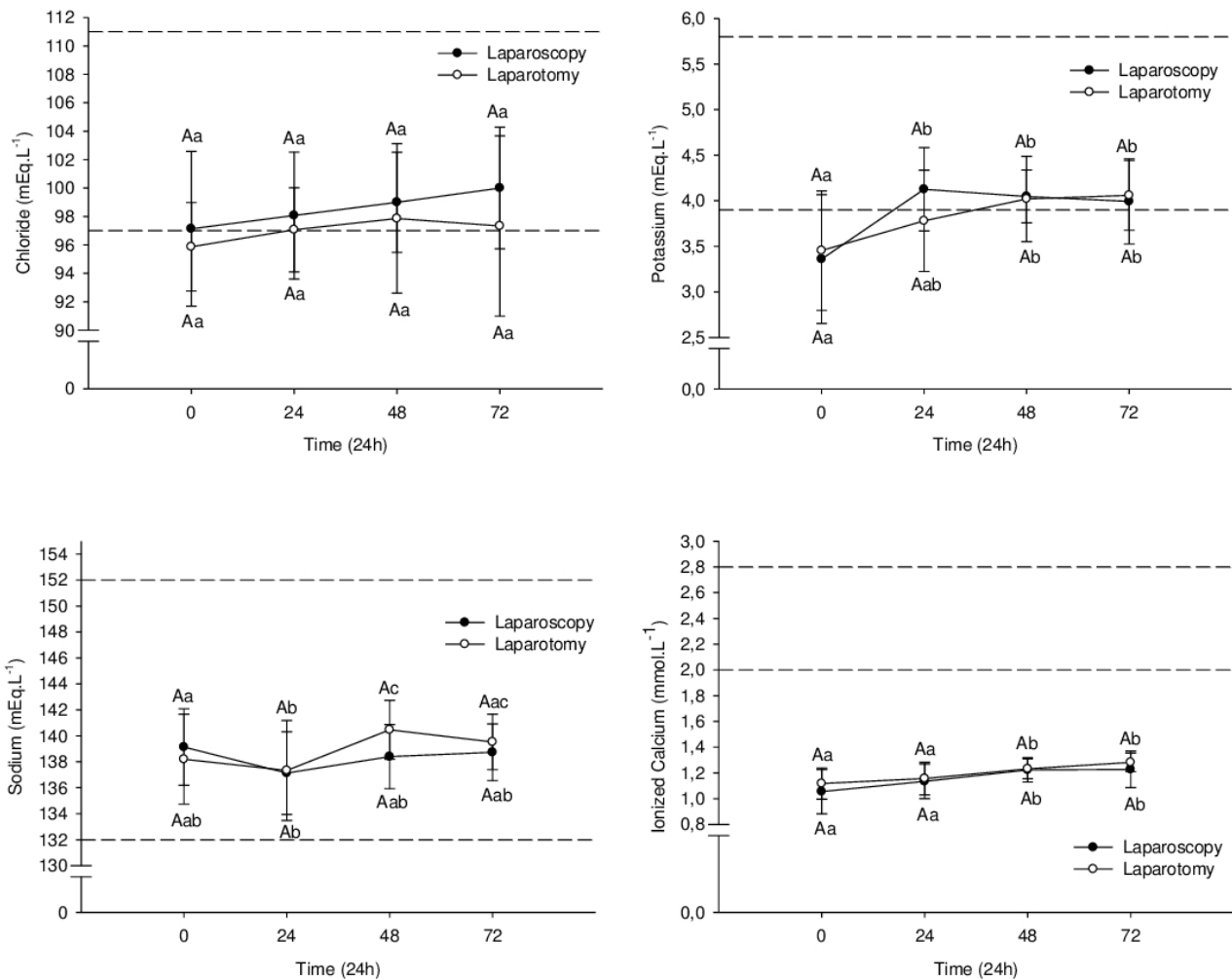


Fig.2. Mean \pm standard deviation of chloride, potassium, sodium, and ionized calcium blood concentrations from 30 Holstein cows with left abomasal displacement treated by one-step laparoscopy (laparoscopy, black circle; $n=15$) or abomasopexy via right paralumbar fossa (laparotomy; white circle; $n=15$) before (0) and during the first three days after surgery. Different capital letters differ between groups ($p\leq 0.05$). Different small letters differ between time points inside groups ($p\leq 0.05$). Dashed lines represent the upper and lower reference values.

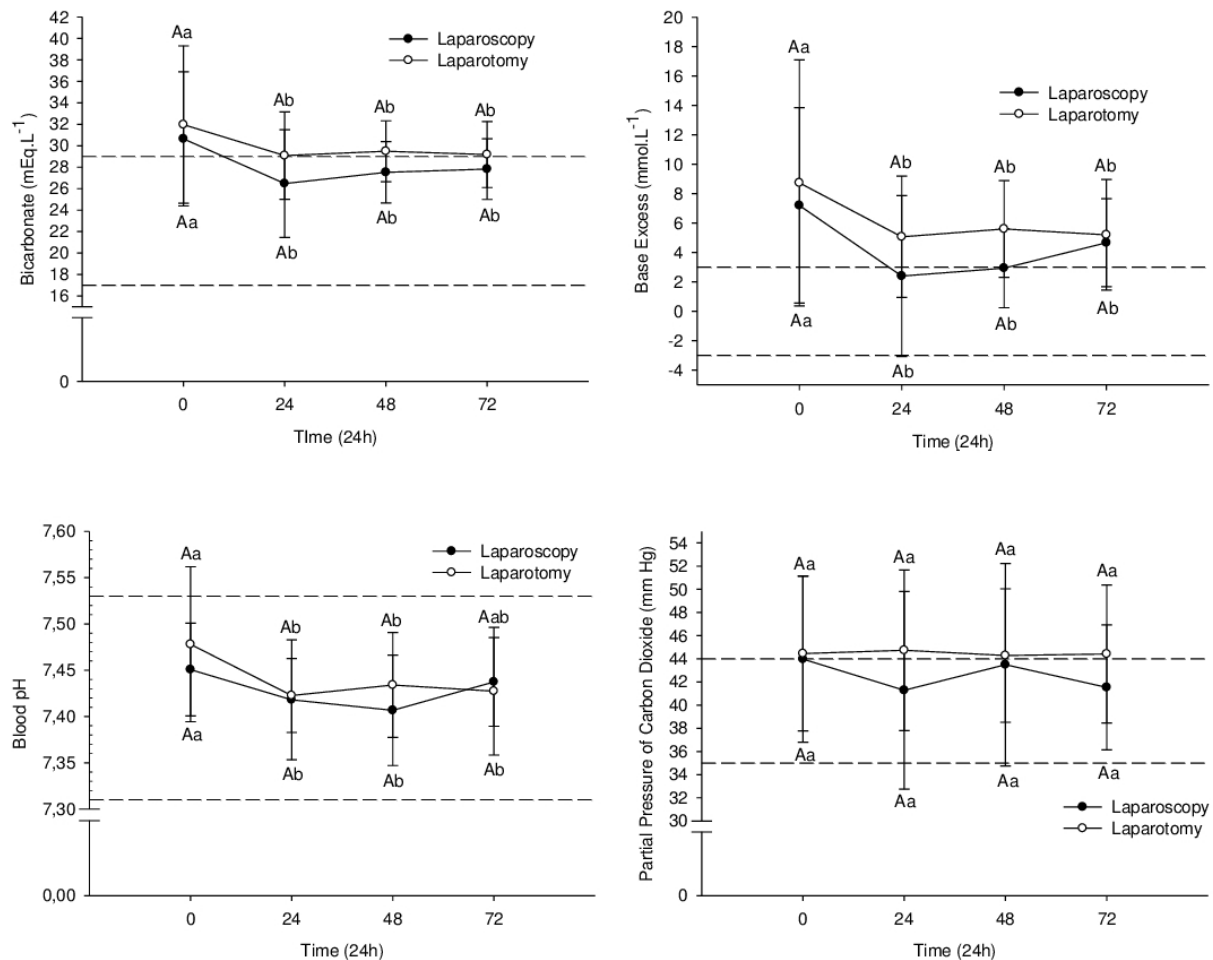


Fig.3. Mean \pm standard deviation of bicarbonate blood concentration, base excess, blood pH, and partial pressure of carbon dioxide from 30 Holstein cows with left abomasal displacement treated by one-step laparoscopy (laparoscopy; black circle; $n=15$) or abomasopexy via right paralumbar fossa (laparotomy, white circle; $n=15$) before (0) and during the first three days after surgery. Different capital letters differ between groups ($p \leq 0.05$). Different small letters differ between time points inside groups ($p \leq 0.05$). Dashed lines represent the upper and lower reference values.

($p=0.07$) in G1 (Fig.3). Mild hypercapnia was observed in all time points in G2 and at M0 in G1.

Anion gap was slightly lower than physiological values at M1 in G2. Strong ion difference increased at M1 and M2 in G2, and was higher in G2 compared to G1 at M3 ($p=0.033$). Anion gap and SID did not differ significantly between time points in both groups and AG did not differ significantly comparing groups (Fig.4).

Glucose was statistically higher in G2 (Fig.5) at all time points ($p=0.08$, $p=0.02$, $p=0.08$, $p=0.04$ for M0, M1, M2 and M3, respectively). Inside groups, only at M1 did glucose differ statistically, in both groups ($p=0.04$ and $p=0.039$ for G1 and G2, respectively), being greater than the reference value in G2.

Beta-hydroxybutyrate (BHBA) was statistically higher in G1 compared with G2 at M0 ($p<0.001$), M1 ($p=0.003$) and M2 ($p=0.024$), and NEFA was statistically greater in G1 compared with G2 at all time points ($p=0.03$, $p=0.015$, $p=0.05$, $p=0.014$ for M0, M1, M2 and M3 respectively) (Fig.5). Both BHBA and NEFA were increased at M0, and decreased significantly following surgery (for BHBA: $p=0.019$, $p<0.001$, $p<0.001$ for M1, M2

and M3, respectively; for NEFA: $p=0.02$, $p<0.001$, $p<0.001$ for M1, M2 and M3 respectively), until reach physiological values at M2 and M3 for NEFA and BHBA, respectively (Fig.5). Data from NEFA in G2 decreased significantly following surgery ($p=0.07$, $p<0.001$ for M1, M2 and M3 respectively).

Mean duration of the surgical procedure (from skin incision to the end of surgery) was 35.04 ± 11.40 minutes (20 to 60 minutes) for G1 and 24.67 ± 2.1 minutes (24 to 28 minutes) for G2. Laparotomy was statistically faster than laparoscopy ($p=0.006$).

Eleven cows from G1 had concurrent diseases, five (33.34%) had mild endometritis and six (40%) had mild lameness in one limb. In this group, one cow (6.67%) was pregnant (seven months) and two calved twins. In G2, seven cows (46.67%) had concurrent diseases, five (33.34%) suffered from mild lameness in one limb and two (13.34%) had mild endometritis. Seven cows (46.67%) were pregnant during LAD, four with five and two with seven months. One cow calved twins.

One cow from G1 relapsed one month after surgery. The animal was operated by right paralumbar fossa laparotomy, but the abomasum could not be replaced due to adhesions

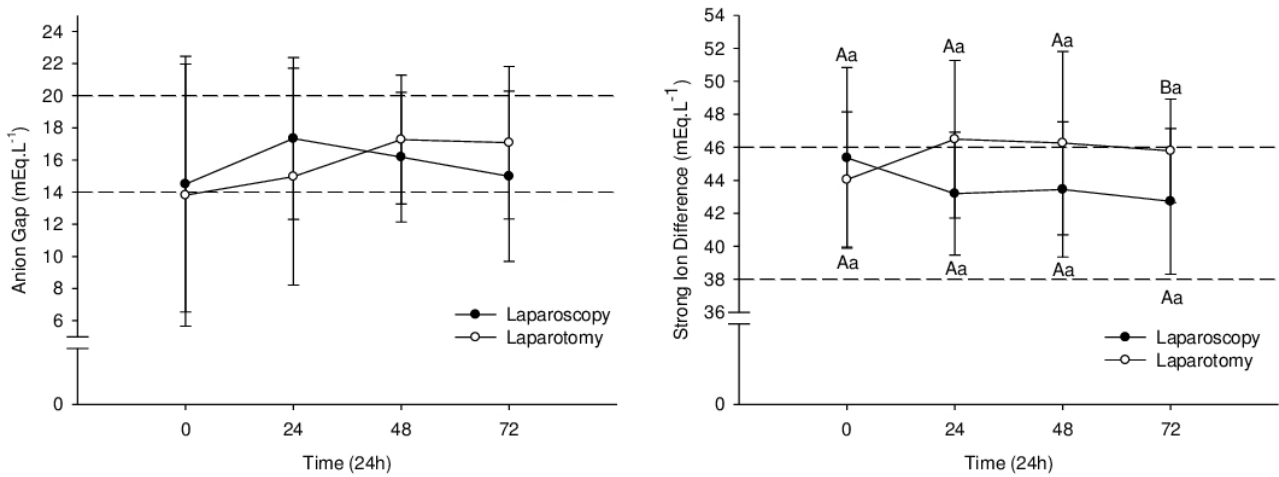


Fig.4. Mean ± standard deviation of anion gap, and Strong Ion Difference from 30 Holstein cows with left abomasal displacement treated by one-step laparoscopy (laparoscopy, black circle; n=15) or abomasopexy via right paralumbar fossa (laparotomy; white circle; n=15) before (0) and during the first three days after surgery. Different capital letters differ between groups ($p \leq 0.05$). Different small letters differ between time points inside groups ($p \leq 0.05$). Dashed lines represent the upper and lower reference values.

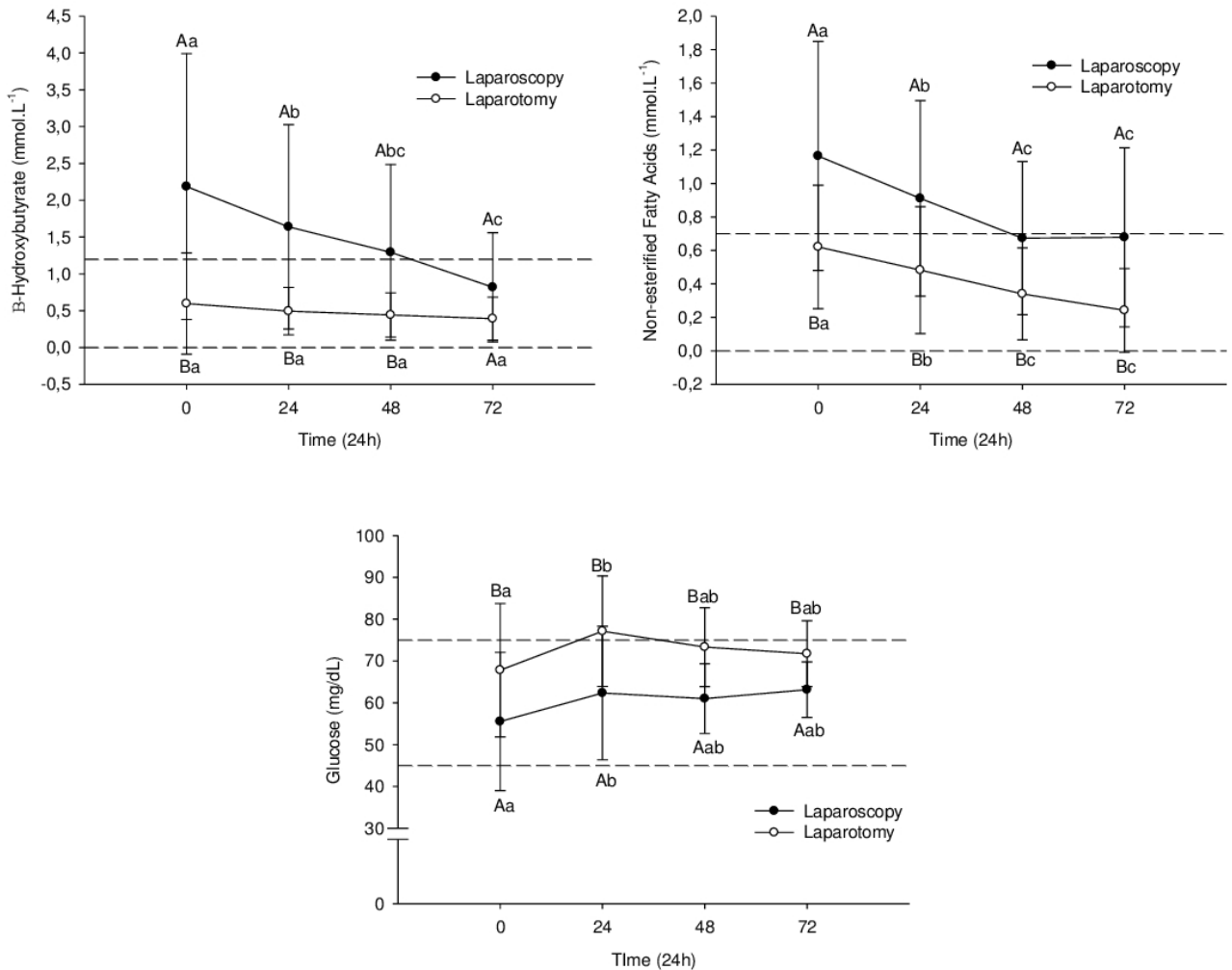


Fig.5. Mean ± standard deviation of glucose, non-esterified fat acid, and β-hydroxybutyrate blood concentration from 30 Holstein cows with left abomasal displacement treated by one-step laparoscopy (laparoscopy, black circle; n=15) or abomasopexy via right paralumbar fossa (laparotomy; white circle; n=15) before (0) and during the first three days after surgery. Different capital letters differ between groups ($p \leq 0.05$). Different small letters differ between time points inside groups ($p \leq 0.05$). Dashed lines represent the upper and lower reference values.

and the cow was slaughtered. Third access was performed successfully in seven (46.67%) cows due to large frame (weight ≥ 700 kg).

DISCUSSION

The one-step laparoscopic abomasopexy has been used effectively to treat LAD in farm settings (Barisani 2004, Christiansen 2004, Gnemmi 2006, Freick et al. 2013), however all articles describing procedures following Barisani (2004) and Christiansen (2004) are case studies with no controls (Van Leeuwen et al. 2009). To our knowledge, this is the first randomized research report comparing this technique with another and the first study evaluating the efficacy of abomasopexy via laparotomy in the right paralumbar fossa.

Obstruction of pylorus was suspected in one cow 48 hours following surgery, which is the most favorable moment for diagnosis (Kelton & Fubini 1989). The animal showed hypokalemia (3.5; 3.4; 2.9; 2.6 mmol.L⁻¹ for M0, M1, M2 and M3 respectively), BE (9; 18; 25; 26 mmol.L⁻¹ for M0, M1, M2 and M3 respectively), increased bicarbonate (31.4; 39.3; 48.7; 48 mmol.L⁻¹ for M0, M1, M2 and M3 respectively) and dehydration (PCV of 24; 21; 24; 29% for M0, M1, M2 and M3 respectively), associated with lack of appetite and absent feces. These clinical signs are common in pyloric obstruction (Braun et al. 1990, Van Leeuwen et al. 2009) and early removal of the toggle suture corrected the obstruction, as reported previously (Kelton & Fubini 1989, Van Leeuwen et al. 2009).

The approach of Barisani (2004) was attempted in one cow, but the sharp point of spieker cut off one extremity of toggle suture, and the abomasum was not replaced. In our experience, the approach of Barisani showed similar complications during exteriorization of toggle thread in right ventral paramedian wall, as described in literature (Van Leeuwen et al. 2009), reason why the approach of Christiansen (2004) was chosen for correction of displaced abomasum.

The rupture of abomasum and consequently bleeding was suspected to be a fall, since the owner reported a previous episode of slip in free-stall.

Peritonitis was not observed in this study, probably because all animals were treated with antibiotics, associated with preoperative antisepsis. Although not necessary (Van Leeuwen et al. 2009), field conditions and owner requirements influenced the choice for antibiotic therapy.

The duration of the one-step laparoscopic abomasopexy is shorter, taking around 15-20 minutes, but some skill is needed (Christiansen 2004, Van Leeuwen et al. 2009). Abomasopexy via right paralumbar fossa was significantly faster than one-step laparoscopic abomasopexy. The difference in operating time was influenced by the lack of experience of the surgeon who performed laparoscopy and the lengthy experience (30 years) of the surgeon who performed laparotomy. The high number of third access (46.67%) probably further increased surgery time.

The decision to use the third access was based on the difficulty of reaching the right side of ventral abdomen in large-framed cows, even though abomasopexy on the left side demonstrated good results (Van Leeuwen et al. 2009). This extra approach allowed the abomasopexy in the correct position.

Cows with LAD developed metabolic alkalosis with hypochloremia, hypokalemia and increased BE, due to partial obstruction of the abomasal passage, keeping bicarbonate in

plasma and chloride ions in the gastrointestinal tract, with reflux of chloride into the rumen, decreasing absorption. Concomitantly, a compensatory increase in pCO₂ occurs in blood plasma (Braun et al. 1988). Hypokalemia occurred because H⁺ ions leave the distal tubule cells to titrate bicarbonate, exchanged by K⁺ ions that enter the cell, resulting in potassium excretion (DiBartola & Autran De Morais 2012). Sodium ions are reabsorbed with Cl⁻ in normochloremic state. But in hypochloremic states, Na⁺ is reabsorbed with bicarbonate, maintaining metabolic alkalosis (Monnig 2013).

The usual clinical presentation of cows with LAD was observed in both groups before surgery, with metabolic alkalosis (increased bicarbonate and BE), hypokalemia, hypochloremia, and hypercapnia. All animals improved regarding acid-base and electrolyte status following surgery, but the treatment approach did not influence the recovery.

Anion gap (AG) is the difference of unmeasured cations (UC) and anions (UA), but the discussion about AG is normally restricted to UA (Constable 2014). This variable is employed to distinguish between hyperchloremic metabolic acidosis (normal AG) and normochloremic metabolic acidosis (increased AG), where protein, ketones bodies and lactate contribute to increase AG (Monnig 2013). Metabolic alkalosis is associated with slight increases in AG due to lactic acid production (Huckabee 1958), but the reviewed literature has meager information about cows with LAD, and variations in AG in cows with displaced abomasum are associated with increased AG (Delgado-Lecaroz et al. 2000) and a marked increase is associated with death (Garry et al. 1988).

Except for a slight decrease at M0 in G2, AG remained within physiological values. Despite increased ketone bodies in cows from G1, AG did not increase above the reference range. The absence of high values for AG could be explained by rapid diagnosis and treatment, up to 12 h after displacement, avoiding high production of organic acids, phosphates and sulfates. But, as for plasmatic proteins, these variables were not measured.

Cows with LAD show increased SID due to hypochloremia (Barros Filho 2002), which is accompanied by increased bicarbonate and BE (Barros Filho 2002, De Morais & Constable 2012). In this study, increased SID was not observed, since mild hypochloremia was observed only in G2, despite increased BE and bicarbonate. Increased SID following surgery in G2 suggests hypoalbuminemia due to acute phase response to inflammation (de Morais & Constable 2012), since acute phase protein increases following laparotomy (Wittek et al. 2012).

Ketosis is a risk factor for abomasal displacement in cows (Rohrbach et al. 1999) and increased BHBA and NEFA have been reported in cows with displaced abomasum, due to negative energy balance (Rehage et al. 1996). The cows from G1 showed ketosis because they were mostly in the postpartum period, with high body score (fatty cows), which explains the increased BHBA and NEFA. The surgical intervention decreased BHBA and NEFA near to reference values, as described in the literature (Rehage et al. 1996), showing returning food intake.

However, almost half of the cows from G2 were pregnant (46.67%). These animals had not been in negative energy balance and consequently in ketosis, as shown by BHBA and NEFA values. NEFA concentration increases a few days before parturition (Bertics et al. 1992). High infiltration of NEFA in

the liver, associated with low carbohydrate concentration, increases ketone body production (Baird 1982). The animals from G2 were not in negative energy balance, which may explain the low NEFA concentration. Glucose concentration was higher in G2 than in G1, and associated with low NEFA concentration may explain the low concentration of BHBA. Nevertheless, NEFA declined significantly following surgery. Probably abomasal displacement induced a temporary and weak fat mobilization, insufficient to increase BHBA, and reposition of LAD permitted food intake and decrease of NEFA.

Hypocalcemia increases risk of LAD due to impairment of abomasal motility and consequently gas accumulation (Massey et al. 1993, Shaver 1997). In this study, hypocalcemia was observed in both groups before and 24 h following surgery reinforcing previous findings (Curtis et al. 1983, Massey et al. 1993). Although ionized calcium was below reference values, data for ionized calcium from healthy cows obtained using the portable analyzer have had excellent correlation with reference analyzer data (Peiró et al. 2010). The data from this study 48 h after surgery corroborate the findings of Peiró et al. (2010).

A portable analyzer was used to measure different variables with good correlation to the gold standard methods (Peiró et al. 2010, Yildirim et al. 2015). In this study, a portable device was essential to measure the acid-basis status, since the experiment was carried out in field settings, without access to another blood gas analyzer. Thus, this device can be an auxiliary tool in diagnosis and treatment of displaced abomasum.

Dehydration is frequent in cows with LAD due to abomasal atony and consequently accumulation of liquid in the abomasum. Animals with great accumulation of fluid have the most evident increase in PCV (Poulsen 1974). In the present experiment, the short period of time between diagnosis and treatment could explain the mild dehydration found in animals with LAD. Fluid therapy was not performed in these animals. Nevertheless, the cows showed rehydration, since PCV decreased significantly following surgery.

Rehydration, associated with other parameters like bicarbonate, potassium, chloride and BE, confirm that both techniques of abomasopexy reestablished gastrointestinal flow. On the other hand, when these parameters are not normalized, pylorus obstruction should be considered for differential diagnosis.

Cows submitted to two-step laparoscopic abomasopexy typically return to normal milk yield and daily energy intake faster than cows submitted to omentopexy (Seeger et al. 2006), but there is no information about the influence of one-step laparoscopic abomasopexy on these variables. Initially, we aimed to determine milk yield and daily energy intake, but the cows remained in free stalls and some dairy farms did not record individual milk yield during the post-operative period, so this information could not be recorded.

CONCLUSIONS

The one-step laparoscopic abomasopexy proved to be a suitable and safe option to treat cows with LAD under field settings, mostly in cows with general disorders, since dorsal recumbency is not necessary.

Both techniques reestablished abomasal flow, enabling recovery of food intake and negative energy balance status.

This experiment showed no additional advantage of one-step laparoscopy in comparison to the abomasopexy via right paralumbar fossa, because both techniques showed similar postsurgical recovery rates. Further studies are needed to establish whether one-step laparoscopic influences milk yield and daily energy intake during the post-operative period.

Conflict of interest statement. - The authors have no competing interests.

Acknowledgements. - The authors would like to thank Prof. Dr. Karina Keller Marques da Costa Flaiban (DMVP/UEL) and Prof. Dr. Priscila Fajardo Valente Pereira (DCV/UEL) for their generous help with the electrolyte measurements.

REFERENCES

- Ames 2nd S. 1968. Repositioning displaced abomasum in the cow. *J. Am. Vet. Med. Assoc.* 153(11):1470-1471. PMID:5693920.
- Babkine M., Desrochers A., Boure L. & Hélie P. 2006. Ventral laparoscopic abomasopexy on adult cows. *Can. Vet. J.* 47(4):343-348. PMID:16642872.
- Baird G.D. 1982. Primary ketosis in the high-producing dairy cow: clinical and subclinical disorders, treatment, prevention, and outlook. *J. Dairy Sci.* 65(1):1-10. [http://dx.doi.org/10.3168/jds.S0022-0302\(82\)82146-2](http://dx.doi.org/10.3168/jds.S0022-0302(82)82146-2). PMID:7042782.
- Baird A.N. & Harrison S. 2001. Surgical treatment of left displaced abomasum. *Compendium* 23:107-114.
- Baker J.S. 1976. Right displacement of the abomasum in the bovine: a modified procedure for treatment. *Bovine Practice* 11:58-60.
- Barisani C. 2004. Evoluzione della tecnica di Janowitz per la risoluzione della dislocazione abomasale sinistra secondo Barisani. *Summa* 5:35-39.
- Barros Filho I.R. 2002. Perioperative Veränderungen im Säure-Basen- und Elektrolythaushalt von abomasopexierten oder omentopexierten Kühen mit linksseitiger Labmagenverlagerung. Dissertation, Tierärztliche Hochschule Hannover, Hannover, Germany. 123p.
- Bartlett P.C., Kopcha M., Coe P.H., Ames N.H., Ruegg P.L. & Erskine R.J. 1995. Economic comparison of the pyloro-omentopexy vs the roll-and-toggle procedure for treatment of left displacement of the abomasum in dairy cattle. *J. Am. Vet. Med. Assoc.* 206(8):1156-1162. PMID:7768736.
- Begg H. 1950. Diseases of the stomach of the adult ruminant. *Vet. Rec.* 62(51):797-808. <http://dx.doi.org/10.1136/vr.62.51.797>. PMID:14788586.
- Bertics S.J., Grummer R.R., Cadorniga-Valino C. & Stoddard E.E. 1992. Effect of prepartum dry matter intake on livre triglyceride concentration and early lactation. *J. Dairy Sci.* 75(7):1914-1922. [http://dx.doi.org/10.3168/jds.S0022-0302\(92\)77951-X](http://dx.doi.org/10.3168/jds.S0022-0302(92)77951-X). PMID:1500587.
- Braun U., Eicher R. & Bracher V. 1988. Inneres Erbrechen beim Rind: Untersuchungen über das abomasale Refluxsyndrom bei verschiedenen Erkrankungen des Verdauungsapparates. *Schweiz. Arch. Tierheilkunde* 130:225-236.
- Braun U., Steiner A. & Kaegi B. 1990. Clinical, haematological and biochemical findings and the results of treatment in cattle with acute functional pyloric stenosis. *Vet. Rec.* 126(5):107-110. PMID:2309403.
- Bückner R. 1995. Surgical correction of left displaced abomasum in cattle. *Vet. Rec.* 136(11):265-267. <http://dx.doi.org/10.1136/vr.136.11.265>. PMID:7793021.
- Câmara A.C.L., Afonso J.A.B., Costa N.A., Mendonça C.L., Souza M.I. & Borges J.R.J. 2010. Fatores de risco, achados clínicos, laboratoriais e avaliação terapêutica em 36 bovinos com deslocamento de abomaso. *Pesq. Vet. Bras.* 30(5):453-464. <http://dx.doi.org/10.1590/S0100-736X2010000500014>.
- Christiansen K. 2004. Laparoskopisch kontrollierte Operation des nach links verlagerten Labmagens (Janowitz-Operation) ohne Ablegen des Patienten. *Tierärztl. Praxis* 32:118-121.

- Constable P.D. 2014. Acid-Base assessment: when and how to apply the Henderson-Hasselbalch equation and Strong Ion Difference theory. *Vet. Clin. N. Am., Food Anim. Pract.* 30(2):295-316, v. <http://dx.doi.org/10.1016/j.cvfa.2014.03.001>. PMID:24980723.
- Constable P.D., Miller G.Y., Hoffsis G.F., Hull B.L. & Rings D.M. 1992. Risk factors for abomasal volvulus and left abomasal displacement in cattle. *Am. J. Vet. Res.* 53(7):1184-1192. PMID:1497190.
- Constable P.D., Stämpfli H.R., Navetat H., Berchtold J. & Schelcher F. 2005. Use of quantitative strong ion approach to determine the mechanism for acid-base abnormalities in sick calves with or without diarrhea. *J. Vet. Intern. Med.* 19(4):581-589. PMID:16095178.
- Curtis C.R., Erb H.N., Sniffen C.J., Smith R.D., Powers P.A., Smith M.C., White M.E., Hillman R.B. & Pearson E.J. 1983. Association of parturient hypocalcemia with eight periparturient disorders in Holstein cows. *J. Am. Vet. Med. Assoc.* 183(5):559-561. PMID:6618988.
- De Morais H.A. & Constable P.D. 2012. Strong ion approach to acid-base disorders, p.316-329. In: Dibartola S.P. (Ed.), *Fluid, Electrolyte and Acid-Base Disorders in Small Animal Practice*. 4th ed. Saunders Elsevier, St Louis, Missouri. <http://dx.doi.org/10.1016/B978-1-4377-0654-3.00020-2>.
- Delgado-Lecaroz R., Warnick L.D., Guard C.L., Smith M.C. & Barry D.A. 2000. Cross sectional study of the association of abomasal displacement or volvulus with serum electrolyte and mineral concentration in dairy cows. *Can. Vet. J.* 41(4):301-305. PMID:10769767.
- DiBartola S.P. 2012. Metabolic acid-base disorders, p.253-286. In: Dibartola S.P. (Ed.), *Fluid, Electrolyte and Acid-Base Disorders in Small Animal Practice*. 4th ed. Saunders Elsevier, St Louis, Missouri. <http://dx.doi.org/10.1016/B978-1-4377-0654-3.00017-2>.
- DiBartola S.P. & Autran De Morais H. 2012. Disorders of potassium: hypokalemia and hyperkalemia, p.92-119. In: Dibartola S.P. (Ed.), *Fluid, Electrolyte and Acid-base Disorders in Small Animal Practice*. 4th ed. Saunders Elsevier, St Louis, Missouri. <http://dx.doi.org/10.1016/B978-1-4377-0654-3.00012-3>.
- Dirksen G. 1961. Die Erweiterung, Verlagerung und Drehung des Labmagens beim Rind. *Zbl. Vet. Med.* 8:934-1015.
- Dirksen G. 1967. Gegenwärtiger Stand der Diagnostik, Therapie und Prophylaxe der Dislocatio abomasi sinistra des Rindes. *Dtsch. Tierärztl. Wschr.* 74:626-633.
- Ford E.J.H. 1950. A case of displacement of the bovine abomasum. *Vet. Rec.* 62(49):763-766. <http://dx.doi.org/10.1136/vr.62.49.763>. PMID:14788578.
- Freick M., Sieber I., Endtmann A., Passarge U. & Passarge O. 2013. Endoskopische Labmagenreposition am stehenden Tier in einem sächsischen Milchviehbetrieb. *Tierärztl. Umschau* 68:311-321.
- Garry F.B., Hull B.L., Rings D.M., Kersting K. & Hoffsis G.F. 1988. Prognostic value of anion gap calculation in cattle with abomasal volvulus: 58 cases (1980-1985). *J. Am. Vet. Med. Assoc.* 192(8):1107-1112. PMID:3372343.
- Gnemmi G. 2006. Endoscopia bovina: dislocazione abomasale sinistra: approccio endoscopico one-step con animale in stazione quadrupedale: valutazione retrospettiva. *Summa* 1:11-21.
- Grymer J. & Sterner K.E. 1982. Percutaneous fixation of left displaced abomasum using a bar suture. *J. Am. Vet. Med. Assoc.* 180(12):1458-1461. PMID:6284690.
- Huckabee W.E. 1958. Relationships of pyruvate and lactate during anaerobic metabolism. I. Effects of infusion of pyruvate or glucose and hyperventilation. *J. Clin. Invest.* 37(2):244-254. <http://dx.doi.org/10.1172/JCI103603>. PMID:13513755.
- Hull B.L. 1972. Closed suturing technique for correction of left abomasal displacement. *Iowa State University Veterinarian* 3:142-144.
- Janowitz H. 1998. Laparoskopische Reposition und Fixation des nach links verlagerten Labmagens beim Rind. *Tierärztl. Praxis G. Grosstiere Nutztiere* 26:308-313.
- Kelton D.F. & Fubini S.L. 1989. Pyloric obstruction after toggle-pin fixation of left displaced abomasum in a cow. *J. Am. Vet. Med. Assoc.* 194(5):677-682. PMID:2647695.
- Lagerweij E. & Numans S.R. 1962. De operatieve behandelingsmethoden van een gedilateerde en gesdiloeerde lebmaag bij het rund. *Tijdschr. Diergeneesk.* 87:328-337.
- Lagerweij E. & Numans S.R. 1968. De operatieve behandeling von de lebmaagdislocatie bij het rund volgens de "Utrechtse", methode. *Tijdschr. Diergeneesk.* 93:366-376.
- Massey C.D., Wang C., Donovan G.A. & Beede D.K. 1993. Hypocalcemia at parturition as a risk factor for left displacement of the abomasum in dairy cows. *J. Am. Vet. Med. Assoc.* 203(6):852-853. PMID:8226240.
- Monnig A.A. 2013. Practical acid-base in veterinary patients. *Vet. Clin. N. Am., Food Anim. Pract.* 43(6):1273-1286, vi. <http://dx.doi.org/10.1016/j.cvsm.2013.07.009>. PMID:24144090.
- Newman K.D., Anderson D.E. & Silveira F. 2005. One-step laparoscopic abomasopexy for correction of left-sided displacement of the abomasum in dairy cows. *J. Am. Vet. Med. Assoc.* 227(7):1142-1145, 1090. <http://dx.doi.org/10.2460/javma.2005.227.1142>. PMID:16220677.
- Peiró J.R., Borges A.S., Gonçalves R.C. & Mendes L.C.N. 2010. Evaluation of a portable clinical analyzer for the determination of blood gas partial pressures, electrolyte concentrations, and hematocrit in venous blood samples collected from cattle, horses, and sheep. *Am. J. Vet. Res.* 71(5):515-521. <http://dx.doi.org/10.2460/ajvr.71.5.515>. PMID:20433376.
- Poulsen J.S.D. 1974. Right-sided abomasal displacement in dairy cows: pre- and postoperative clinical chemical findings. *Nordisk Veterinaermedicin* 26:65-90.
- Rehage J., Mertens M., Stockhofe-Zurwieden N., Kaske M. & Scholz H. 1996. Post-surgical convalescence of dairy cows with left abomasal displacement in relation to fatty liver. *Schweiz. Arch. Tierheilkd.* 138(7):361-368. PMID:8766592.
- Rohrbach B.W., Cannedy A.L., Freeman K. & Slenning B.D. 1999. Risk factors for abomasal displacement in dairy cows. *J. Am. Vet. Med. Assoc.* 214(11):1660-1663. PMID:10363100.
- Seeger T., Kümper H., Failing K. & Doll K. 2006. Comparison of laparoscopic-guided abomasopexy versus omentopexy via right flank laparotomy for the treatment of left abomasal displacement in dairy cows. *Am. J. Vet. Res.* 67(3):472-478. <http://dx.doi.org/10.2460/ajvr.67.3.472>. PMID:16506910.
- Sexton M.F., Buckley W. & Ryan E. 2007. A study of 54 cases of left displacement of the abomasum: February to July 2005. *Irish Vet. J.* 60(10):605-609. <http://dx.doi.org/10.1186/2046-0481-60-10-605>. PMID:21851688.
- Shaver R.D. 1997. Nutritional risk factors in the etiology of left displaced abomasum in dairy cows: a review. *J. Dairy Sci.* 80(10):2449-2453. [http://dx.doi.org/10.3168/jds.S0022-0302\(97\)76197-6](http://dx.doi.org/10.3168/jds.S0022-0302(97)76197-6). PMID:9361217.
- Straiton E.C. & McIntee D.P. 1959. Correction of the displaced abomasum. *Vet. Rec.* 71:871-872.
- Van Leeuwen E., Mensink M.G.S. & De Bont M.F.P.M. 2009. Laparoscopic reposition and fixation of the left displaced abomasum in dairy cattle practice: ten years of experience under field conditions in the Netherlands. *Cattle Pract.* 17:123-127.
- Van Winden S.C.L. & Kuiper R. 2003. Left displacement of the abomasum in dairy cattle: recent developments in epidemiological and etiological aspects. *Vet. Res.* 34(1):47-56. <http://dx.doi.org/10.1051/vetres:2002060>. PMID:12588683.
- Wittek T., Füll M. & Grosche A. 2012. Peritoneal inflammatory response to surgical correction of left displaced abomasum using different techniques. *Vet. Rec.* 171(23):594-600. <http://dx.doi.org/10.1136/vr.101107>. PMID:23092974.
- Yildirim E., Karapinar T. & Hayirli A. 2015. Reliability of i-STAT for the determination of blood electrolyte (K⁺, Na⁺, and Cl⁻) concentration in cattle. *J. Vet. Intern. Med.* 29(1):388-394. <http://dx.doi.org/10.1111/jvim.12526>. PMID:25619525.