

## Evaluation of physiological parameters of dogs submitted to uterine lymphatic mapping using patent blue V dye for anaphylaxis detection<sup>1</sup>

Rebeca C. Justino<sup>2</sup>, Guilherme S. Cardoso<sup>2</sup>, Luiz G.C. Trautwein<sup>2</sup>, Rubens I.A. Alves<sup>3</sup>, Karina K.M.C. Flaiban<sup>3</sup> and Maria Isabel M. Martins<sup>2\*</sup>

**ABSTRACT.**- Justino R.C., Cardoso G.S., Trautwein L.G.C., Alves R.I.A., Flaiban K.K.M.C. & Martins M.I.M. 2016. **Evaluation of physiological parameters of dogs submitted to uterine lymphatic mapping using patent blue V dye for anaphylaxis detection.** *Pesquisa Veterinária Brasileira* 36(12):1209-1214. Departamento de Clínicas Veterinárias, Universidade Estadual de Londrina, Rodovia Celso Garcia, Londrina, PR 86061-900, Brazil. E-mail: [imartins@uel.br](mailto:imartins@uel.br)

Lymphatic mapping has been performed in humans and dogs. Although several cases of anaphylaxis have been reported in humans, there are no such reports in dogs. The objective of this study was to identify the occurrence of adverse reactions to patent blue V dye in bitches undergoing uterine lymphatic mapping procedures using cardiovascular and hematological evaluations. The experiment was performed in 14 mongrel bitches without any reproductive disease, randomly assigned into two equal groups (PBV- uterine lymphatic mapping and OHE; Control - OHE only). The animals were submitted to pre- and postoperative hematological and serum biochemistry exams (7 days). The anesthetic protocol was: sedation (morphine and acepromazine), induction (propofol), maintenance (isoflurane), transoperative analgesia (fentanyl). Systolic blood pressure was monitored throughout the procedure and arterial blood gas analysis was performed immediate pre and postoperatively. For lymphatic mapping was injected patent blue V in the uterine wall, 10 minutes before OEH. Comparisons between the pre- and postoperative parameters within the same animal were performed using the Wilcoxon-Mann-Whitney test. To compare the values between control and PBV group was obtaining the difference between the pre and post of each group, subjected to the Mann-Whitney test (significance of 5%). Differences were observed ( $P < 0.05$ ) between the pre- and postoperative evaluations in the PBV (total protein and the albumin serum), in both groups (arterial partial pressure of oxygen) and in the Control (arterial oxygen saturation). There were no signs of adverse reactions to the patent blue V dye in the healthy bitches submitted to lymphatic uterine mapping.

INDEX TERMS: Uterine lymphatic mapping, patent blue V dye, anaphylaxis, hypersensitivity, bitches, vital dye.

**RESUMO.**- [Avaliação de parâmetros fisiológicos de cães submetidos ao mapeamento linfático uterino usando o corante azul patente V para a detecção de anafilaxia.] O mapeamento linfático tem sido realizado em humanos e cães. Embora inúmeros casos de anafilaxia já tenham sido

relatados em humanos, não existem tais relatos em cães. O objetivo deste estudo foi identificar a ocorrência de reações adversas ao corante azul patente V em cadelas submetidas ao mapeamento linfático uterino, usando avaliações cardiovasculares e hematológicas. O experimento foi realizado em 14 cadelas mestiças, divididas igualmente em dois grupos (PBV- mapeamento linfático uterino e OEH; Controle - apenas OEH). Os animais foram submetidos a exames hematológicos e bioquímicos séricos no pré e pós-operatório (7 dias). O protocolo anestésico foi: sedação ( morfina e acepromazina), indução (propofol), manutenção (isoflurano), analgesia trans-operatória (fentânil). A pressão arte-

<sup>1</sup> Received on April 17, 2016.

Accepted for publication on July 19, 2016.

<sup>2</sup> Departamento de Clínicas Veterinárias, Universidade Estadual de Londrina (UEL), Rodovia Celso Garcia PR-445 Km 380, Campus Universitário, Londrina, PR 86061-900, Brazil. \*Corresponding author: [imartins@uel.br](mailto:imartins@uel.br)

<sup>3</sup> Departamento de Medicina Veterinária Preventiva, UEL, Rodovia Celso Garcia PR-445 Km 380, Campus Universitário, Londrina, PR 86061-900, Brazil.

rial sistólica foi monitorada durante todo o procedimento e hemogasometria arterial no pré e pós-operatório imediato. Para o mapeamento linfático foi injetado azul patente V na parede uterina, 10 minutos antes de realizar a OEH. Comparações entre os valores do pré e pós-operatório do mesmo animal foram realizados pelo teste Wilcoxon-Mann-Whitney. Para a comparação dos valores entre Controle e PBV foi realizado a obtenção da diferença entre os valores pré e pós de cada grupo, submetidas ao teste de Mann-Whitney (significância de 5%). Diferenças foram observadas ( $p < 0,05$ ) entre as avaliações pré e pós-operatórias no PBV (proteína total e albumina), ambos os grupos (pressão parcial de oxigênio arterial) e no Controle (saturação de oxigênio arterial). Não houve sinais de reação adversa ao corante azul patente V em cadelas saudáveis submetidas ao mapeamento linfático uterino.

TERMOS DE INDEXAÇÃO: Mapeamento linfático uterino, azul patente V, anafilaxia, hipersensibilidade, cadelas, corante vital.

## INTRODUCTION

The blue dye infusing into tissue has been used since the first decades of the last century and allows visualization of the lymphatic vessels and lymph nodes (Sanders & Florey 1940). Since there is a high incidence of uterine cancer in humans, several studies were conducted to provide a better understanding about the lymphatic drainage of this organ (Burke et al. 1996, Echt et al. 1999, Levenback et al. 2002, Altgassen et al. 2007, Bin Li et al. 2007). Uterine malignant neoplasias are rare in dogs, although some papers have reported the occurrence (Cave et al. 2002, Klein 2007, Wenzlow et al. 2009, Tsioli et al. 2011). In contrast, cases of canine uterus infection and inflammation are very common (Watts et al. 1998, Pretzer 2008, Fontaine et al. 2009). Studies focusing on reliable prognostic factors, that might also be used to reach an early diagnosis of uterine diseases, have increased (Weiss et al. 2004, Sant'Anna et al. 2014, Mir et al. 2013).

Lymph nodes receives drainage from specific regions of the body and responds in a particular manner to each type of disease (Cowell et al. 2003). The assessment of sentinel lymph nodes by observing changes in their characteristics in cases of uterine disorders in dogs could facilitate early diagnosis and establish patterns for utilization in non-invasive auxiliary exams.

The patent blue dye belongs to the family of triphenylmethane dyes, which are widely used for coloring textiles, paints, cosmetics, foods (E131), and drugs, such as laxatives (Montgomery et al. 2002, EFSA 2013). This dye is widely used for human lymphatic mapping, for research, and for clinical purposes (Aquino et al. 2012, Viehl et al. 2013).

Although the prevalence of anaphylaxis in small animals is unknown, it is likely that anaphylactic reactions have become more frequently observed due to the increasing exposure of patients to antigenic substances (Shmuel & Cortes 2013).

Hypotension and cardiovascular collapse are the mainly circulatory changes observed in dogs, as well as signs of liver abnormalities (Greenway & Oshiro 1973, Dowling 2009, Quantz et al. 2009). Anaphylactic clinical reactions are spe-

cies-dependent and associated with high concentrations of mast cells in the regions (Noviana et al. 2004, Fujita 1964). The gastrointestinal tract and liver venous system are affected first, resulting in hepatic congestion and portal hypertension (Greenway & Oshiro 1973, Quantz et al. 2009).

Several reports of severe adverse reactions to the patent blue V dye have been reported (Jeudy et al. 2008, Bricou et al. 2009, Hunting et al. 2010, Lucas et al. 2010, Hou-Chuan Lai et al. 2011). These reactions are possibly associated with IgE actions, but the mechanisms underlying the allergic reaction to patent Blue remain unclear (Mertes et al. 2008, Hunting et al. 2010).

Mostly patients undergoing lymphatic mapping are submitted to local and/or general anesthesia. It is known that drugs administered for anesthesia procedures can interfere with an animal's physiological parameters. Isoflurane is an inhaled halogenated anesthetic that has minimal cardiovascular effects (Conceição et al. 2005). This drug does not sensitize the myocardium to catecholamine and induces peripheral vascular resistance and blood pressure by decreasing  $\beta$ -adrenergic stimuli (Paget et al. 1991). The use of blue dyes associated, or not, with local anesthetics can cause allergic reactions, suggesting that blue dye itself is a potential allergen (Hirsch et al. 1982). There are no reports of adverse reactions in dogs using patent blue dye, but several reports of anaphylactic reactions are described in humans, with symptoms such as erythema, hypotension, tachycardia, and decreased oxygen saturation (Hirsch et al. 1982, Del Massa et al. 2005, Shinzato et al. 2006, Jeudy et al. 2008, Bricou et al. 2009, Hunting et al. 2010, Lucas et al. 2010, Rodrigues et al. 2010, Hou-Chuan Lai et al. 2011).

The objective of this study was to identify the occurrence of adverse reactions to patent blue V dye in bitches submitted to uterine lymphatic mapping procedures using cardiovascular and hematological evaluations.

## MATERIALS AND METHODS

**Ethics statement.** The study was approved by the animal ethics committee of the institution, the Ethics Committee on the Use of Animals - Universidade Estadual de Londrina (n° 183/12). All of the procedures were authorized by the owners of the dogs.

**Dye.** A sterile, buffered concentration of 2.5% aqueous solution of patent blue V dye (Bleu Patente V<sup>®</sup>, Delpharm Tours, Chambray Lès Tours, France) was used for the uterine lymphatic mapping. The bis sodium salt of patent blue V (diethylamino-4-fenil) (hidroxi-5-dissulfo-2,4-fenil) anhydride methanol is a member of the triphenylmethane family. Regardless of the route of administration, patent blue V dye is eliminated within 24-48 hours by bile and mainly by urine, which becomes strongly colored. For this experiment 0.4 to 0.6mL of patent blue V was used, divided in three subserosal injections (one on each horn and one in uterine body).

**Animals.** Healthy mongrel bitches (n=14) aged from 1 to 6 years (2.4±1.3) and weighing between 7 and 15 kg (8.6±3.8) were submitted to elective ovariohysterectomy (OHE). These dogs were randomly assigned into two equal groups: Patent blue v dye uterine infusion and OHE group (PBV) and OHE only group (Control).

**Anesthetic-analgesic protocol.** Intramuscular acepromazine (0.03 mg/kg) and morphine (0.5mg/kg) were used 30 minutes before surgery for the pre-anesthetic medication. Anesthesia was induced by intravenous propofol (5mg/kg) and maintained with inhaled isoflurane, with a 100% fractional inspired oxygen

concentration (FiO<sub>2</sub>). Fentanyl (5µg/kg, intravenous) was administered 5 minutes before clamping the ovarian pedicles. A single subcutaneous injection of Ketoprofen (1mg/kg) was used for analgesia during surgery and oral meloxicam (0.1mg/kg, every 24 hours for 4 days) were used to relieve postoperative pain.

**Experimental groups.** The seven bitches in the PBV group were submitted to uterine lymphatic mapping and OHE. After the celiotomy, uterine location and abdominal cavity isolation, 0.4ml of patent blue dye was injected into the subserosal layer of the uterine body and horns using a 1-ml syringe and a 26G needle. The OHE was performed 10 minutes after massaging the local application.

In the Control group, the seven bitches were submitted only to OHE, using the technique of 3 clamps for hemostasis and the transfixion of the ovarian pedicles and uterine stump with non-absorbable Nylon 2-0 (Shalon suturas, Goiânia, Brasil).

**Hematological parameters.** Venous blood samples (5ml) were collected about 1 hour before surgery and 7 days after the OHE procedure in conjunction with skin suture removal from the external saphenous and/or jugular veins. The following biochemical parameters were assayed with Dimension Xpand plus® equipment (Siemens Healthcare Diagnostics Inc – EUA): total serum protein (PT), albumin (ALB), serum creatinine (CRE), alanine amino transferase (ALT), and alkaline phosphatase (ALP). The reference values to the biochemical parameters were: ALT- 10 to 88 UI/L; ALP- 10 to 96 UI/L; PT- 5.4 to 7.5g/dL; ALB- 2.3 to 3.8mg/dL; CRE- 0.5 to 1.5mg/dL (Viana 2007).

For the blood gas analysis, an internal femoral artery puncture with a heparinized syringe was performed pre- and postoperatively, immediately after intubation and extubation, respectively. The following variables were analyzed with blood gas immediately after collection (OmniC, F. Hoffmann - La Roche Ltda): arterial partial pressure of oxygen (PO<sub>2</sub>), arterial partial pressure of carbon dioxide (PCO<sub>2</sub>), arterial oxyhemoglobin saturation (SO<sub>2</sub>), arterial bicarbonate (HCO<sub>3</sub>), and arterial blood pH.

**Cardiovascular parameters.** Heart rate values were recorded every 5 minutes using an esophageal stethoscope. Heart rate values 20% above baseline or 160bpm were considered tachycardia. Systolic blood pressure was monitored by manual measurements every 5 minutes using a sphygmomanometer with a cuff adapted to the left forelimb below the elbow joint and a Doppler (DV-10®, Microem Produtos Médicos Ltda, Brasil). For systolic blood pressure values up to 80mmHg (10% below the value considered the lower physiological limit 90mmHg) were considered normal for systolic blood pressure.

**Statistical analysis.** Comparisons between the pre- and postoperative parameters within the same animal were performed using the Wilcoxon-Mann-Whitney test. For comparison of values between groups, first was obtained the difference between the pre and postoperative moment of each group, and after, these differences were evaluated by Mann-Whitney test. BioStat 5.0 software (Instituto de Desenvolvimento Sustentável Mamirauá, Tefé-AM, Brazil) was used, with a level of statistical significance of 5%.

## RESULTS

### Surgery procedure

The mean duration of the surgery was 54.3 (±6.1) minutes for the PBV and 42.9 (±8.6) minutes for the Control.

### Hematological parameters

The serum biochemical parameters and the blood gas parameters are presented in Table 1.

Among the biochemical parameters in the PBV group,

**Table 1. Median (Q1-Q3) of serum biochemical parameters in the pre-operative and after 7 days from surgery and arterial blood gas parameters in pre and immediate postoperative of 7 bitches subjected to lymphatic mapping with patent blue V dye and OHE (PBV) and 7 bitches subjected only to OHE (Control). Londrina, 2013**

Parameters		Groups	
		PBV	Control
ALT (U/L)	Pre	43 (39-49)	40 (37-58)
	Post	38 (38-42)	43 (42-49)
ALP (U/L)	Pre	59 (55-76)	69 (60-93)
	Post	67 (52-83)	86 (79-96)
Protein (g/dL)	Pre	6.8* (6.5-7.5)	6.1 (5.9-7.3)
	Post	6.4* (6.3-6.5)	6.5 (6.1-7.1)
Albumine (g/dL)	Pre	2.6* (2.5-2.8)	2.7 (2.7-2.8)
	Post	2.5* (2.3-2.7)	2.9 (2.7-3.0)
Creatinine (mg/dL)	Pre	0.98 (0.88-1.06)	1.00 (0.85-1.00)
	Post	1.00 (0.88-1.23)	1.00 (0.90-1.15)
PO <sub>2</sub> (mmHg)	Pre	221.2* (153.8-331.3)	409.9* (263.3-437.5)
	Post	102* (92-105)	87.5* (87.0-97.5)
SO <sub>2</sub> (%)	Pre	99.6 (99.1-99.9)	99.9* (99.8-100.0)
	Post	96.7 (95.6-97.2)	95.1* (93.9-96.0)
PCO <sub>2</sub> (mmHg)	Pre	40.7 (39.9-46.9)	43.2 (40.4-49.7)
	Post	44.9 (42.9-45.6)	44.9 (42.1-47.7)
cHCO <sub>3</sub> (mmol/L)	Pre	20.6 (20.4-21.5)	20.2 (19.6-22.0)
	Post	21.1 (21.0-22.0)	19.3 (19.0-22.2)
pH	Pre	7.32 (7.27-7.35)	7.29 (7.27-7.31)
	Post	7.30 (7.30-7.31)	7.30 (7.27-7.35)

\* Values which showed significant differences within each group (p<0.05). PO<sub>2</sub> = arterial partial pressure of O<sub>2</sub>; SO<sub>2</sub> = O<sub>2</sub> arterial saturation; PCO<sub>2</sub> = arterial partial pressure of CO<sub>2</sub>; cHCO<sub>3</sub> = arterial bicarbonate concentration.

there were differences (P<0.05) in the total protein and albumin levels, with higher values in the preoperative evaluation compared with the postoperative values. There were no differences (P>0.05) in the biochemical parameters for the control group and when compared the difference of pre and post-operative moment between the groups.

There were no differences (p>0.05) in blood gas parameters when compared the difference of pre and post-operative moment between the groups. There were differences (p<0.05) between the pre- and postoperative periods in the arterial PO<sub>2</sub> of both the PBV and the Control groups and in the arterial SO<sub>2</sub> of the Control group. In both cases, higher values were observed in the preoperative evaluation compared with the postoperative values.

### Cardiovascular parameters

The dispersion of heart rate and systolic blood pressure values of each animal is demonstrated in four box plot graphics (Fig.1). In Table 2 it is possible to observe the difference between the systolic blood pressure and the heart beat at the time of patent blue v dye infusion and five minutes later.

## DISCUSSION

The widespread use of patent blue dye implies that a large number of individuals have already been exposed to this compound. The patent blue V belongs to the family of triphenylmethane dyes, which are widely used for coloring textiles, paints, cosmetics, foods (E131), and drugs such as

laxatives (Montgomery et al. 2002, EFSA 2013). This fact may partially explain the numerous reports of type I hypersensitivity reactions in human patients undergoing lymphatic mapping using this dye, as these reactions typically occur after a previous exposure to the allergen (Montgomery et al. 2002, Hunting et al. 2010).

In the present study, blue-colored urine was observed in all of the G-PBV animals immediately after surgery. This adverse effect is in agreement with the package insert of this drug and with a previous report (Hou-Chuan Lai et al. 2011).

The physiological parameters clearly indicate that the animals used in the present study did not exhibit hypersensitivity to this dye, confirming the reported absence of hypersensitivity reactions to the patent blue V dye in dogs. As observed in Table 1, all of the biochemical parameters evaluated were within the normal range, including total protein and serum albumin (reference values: 5.4 to 7.5g/dl and 2.3 to 3.8mg/dl respectively), which showed pre- and postoperative levels that were different in the experimental group (Viana 2007). It is most likely that this difference does not have any clinical relevance because no therapeutic intervention took place and all of the patients

remained clinically stable postoperatively. The decrease in the serum protein concentration may be associated with the appetite loss that often occurs following invasive procedures, such as OHE, even when analgesics are used (Hardie et al. 1997, Mathews 2000). This finding also may also be related to the manipulation of the abdominal structures and the duration of the procedure, which were both greater in the G-PBV group.

The heart rate and systolic blood pressure remained clinically stable throughout the surgical procedure in both groups, even immediately after the dye infusion. The values obtained in this study, in both groups, are similar to those found by Borges et al. (2008), in control group (healthy dogs maintained in general anesthesia with isoflurane inhalation). In the reactions observed in humans, most of the patients showed signs of a reaction a few minutes after the infusion (Del Massa et al. 2005, Rodrigues et al. 2010).

There were no differences ( $P>0.05$ ) in the ALT levels between the pre- and postoperative periods in both groups, and the values remained within the normal physiological limits, suggesting no signs of anaphylaxis in the animals submitted to patent blue V dye (Viana 2007, Quantz et al. 2009). After anaphylaxis, ALT serum levels can rapidly in-

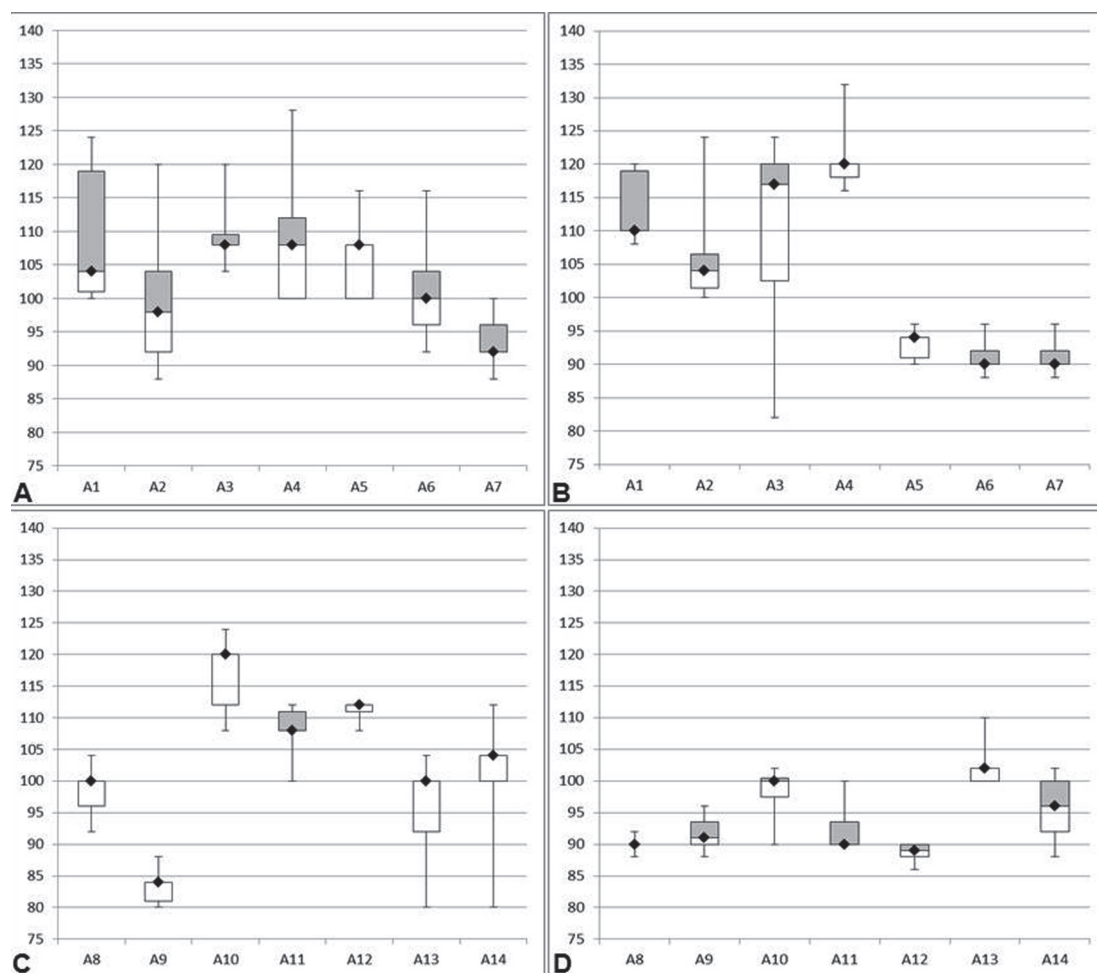


Fig.1. (A) Graphics of box plot distribution of: heart beat (bpm), (B) systolic blood pressure (mmHg) of 7 bitches (A1-A7) during uterine lymphatic mapping with patent blue V, followed by OHE; (C) heart beat (bpm); (D) systolic blood pressure (mmHg) of seven bitches (A8-A14) during ovariectomy procedure. Boxes represent the range values from the 25th percentile to the 75th percentile. The median is represented by symbol ( $\blacklozenge$ ). The minimum and the maximum values are showed at the end of the whiskers.



**Table 2. Values of heart beat and systolic blood pressure at the moment of patent blue v uterine infusion and 5 minutes later in G-PBV bitches (subjected to lymphatic mapping with patent blue V dye and OHE). Londrina, 2013**

Animals	Heart beat (bpm)			Systolic blood pressure (mmHg)		
	5 min. before	Infusion	After 5 min.	5 min. before	Infusion	After 5 min.
A1	102	118	124	110	120	120
A2	100	88	92	112	100	100
A3	108	108	120	98	100	124
A4	112	128	112	120	132	120
A5	116	112	108	96	90	92
A6	92	96	116	88	90	96
A7	96	92	100	90	90	98

crease due to liver injury and then return to the normal range after 2-3 weeks. Although this elevated level is not a specific marker for anaphylaxis, it may occur during severe cases of type 1 hypersensitivity reactions (Quantz et al. 2009).

Patent blue V dye has been widely used for lymphatic mapping in human patients suffering from cancer (Bats et al. 2011, Lavy et al. 2014, Verbeek et al. 2014). The accuracy of some of the parameters evaluated during the anesthesia monitoring, such as pulse oximetry, can be affected by this dye (Hou-Chuan Lai et al. 2011). Lymphatic mapping using isosulfan dye in dogs reduced the transcutaneous oxygen saturation, although no significant decrease was observed in the blood gas analysis (Kahlenberg et al. 2001). The differences between the pulse oximetry and blood gas analysis values can be explained by the interference of the isosulfan dye in the absorption spectra of the oxyhemoglobin from the pulse oximeter (Hou-Chuan Lai et al. 2011, Kahlenberg et al. 2001). In the present study, the PO<sub>2</sub> concentrations in both groups remained above minimal physiological described for dogs (Kaneko 1997). The differences observed in the PO<sub>2</sub> concentration between the pre- and postoperative periods in both groups can be explained by the interval between the extubation and the blood collection (range 1-5 minutes). During intubation, all of the animals were receiving 100% oxygen. Importantly, no significant differences ( $P>0.05$ ) were observed between the groups when comparing the blood gas parameters. Therefore, it can be inferred that there was no interference of the dye in these parameters, and there were no signs of anaphylaxis.

Many authors have described systemic cardiovascular signals associated with hypersensitivity in humans, and hypotension was the most cited (Shinzato et al. 2006, Bricou et al. 2009, Hunting et al. 2010, Lucas et al. 2010). Hypotension caused by an anaphylactic reaction to dyes can be confused with the hypotension commonly observed during anesthesia and is usually reversed by the pain stimuli from the surgical procedure, superficialization of anesthetic level, and an increase in intravenous fluids (Hunting et al. 2010). In the present study, there was no systolic blood pressure decrease that suggested hypotension caused by the patent blue dye.

It is noteworthy that the animals used in this study were healthy and presented normal preoperative parameters. In addition, there were no owner complaints and no reports

of changes in clinical signs. Conversely, mostly of the reports of anaphylactic reactions in humans comprise individuals suffering from chronic diseases, as cancer (Mertes et al. 2008). This difference in health status may be relevant to the occurrence of anaphylactic reactions, and its influence on the imbalance of the immune system should be considered.

## CONCLUSION

Based on the evaluations of serum biochemical parameters, as ALT and ALP, and cardiovascular parameters, such as heart rate and systolic blood pressure, it is possible to suggest that patent blue V dye is safe for use in healthy bitches during uterine lymphatic mapping.

**Acknowledgements.-** The authors express their gratitude to Dr. Katia Cristina Silva-Santos for her assistance with the manuscript translation and correction, to the employees and residents of the Laboratory of Clinical Pathology, the Surgical Center of Veterinary Hospital / State University of Londrina (HV / UEL), the Post Graduate Program in Animal Science (UEL) for its financial support, and the Coordination of Improvement of Higher Education Personnel (CAPES) for granting the master's scholarship.

**Conflicts of interest.-** The authors have declared no conflicts of interest.

## REFERENCES

- Altgassen C., Pagenstecher J., Homung D. & Hornemann A. 2007. A new approach to label sentinel nodes in endometrial cancer. *Gynecol. Oncol.* 105:457-461.
- Aquino J.U., Pinheiro L.G.P., Vasques P.H.D., Rocha J.I.X., Cruz D.A., Beserra H.E.O. & Cavalcante R.V. 2012. Experimental canine model for sentinel lymph node biopsy in the vulva using technetium and patent blue dye. *Acta Cirurgica Brasileira* 27:102-108.
- Bats A.S., Buénerd A., Querleu D., Leblanc E., Darai E., Morice P., Marret H., Gillaizeau F., Mathevet P. & Lécure F. 2011. Diagnostic value of intraoperative examination of sentinel lymph node in early cervical cancer: a prospective, multicenter study. *Gynecol. Oncol.* 123:230-235.
- Bin Li, Xiao-Guang Li, Ling-Ying Wu, Wen-Hua Zhang, Shu-Min Li, Cheng Min & Ju-zhen Gao. 2007. A pilot study of sentinel lymph nodes identification in patients with endometrial cancer. *Bull. Cancer* 94:1-4.
- Borges P.A., Nunes N., Barbosa V.F., Conceição E.D., Nishimori C.D., Paula D.P., Carareto R., Thiesen R. & Santos P.A. 2008. Variáveis cardiopulmonares, índice biespectral e recuperação anestésica em cães anestesiados pelo isoflurano, tratados ou não com tramadol. *Arq. Bras. Med. Vet. Zootec.* 60:613-619.
- Burke T.W., Levenback C., Tornos C., Morris M., Wharton J.T. & Gershenson D.M. 1996. Intraabdominal lymphatic mapping to direct selective pelvic and paraaortic lymphadenectomy in women with high-risk endometrial cancer: results of a pilot study. *Gynecol. Oncol.* 62:169-173.
- Bricou A., Barranger E., Uzan S. & Darai E. 2009. Anaphylactic shock during the sentinel lymph node procedure for cervical cancer. *Gynecol. Oncol.* 114:375-376.
- Cave T.A., Hine R., Howie F., Thompson H. & Argyle D.J. 2002. Uterine carcinoma in a 10-month-old golden retriever. *J. Small Anim. Pract.* 43:133-135.
- Conceição E.D.V., Nishimori C.T., Moraes P.C., Paula D.P., Carareto R., Freitas P.M.C. & Nunes N. 2005. Parâmetros eletrocardiográficos e cardiovasculares em cães anestesiados pelo isoflurano e submetidos à hipovolemia aguda. *Ciência Rural* 35:1351-1356.
- Cowell R.L., Dorsey K.E. & Meinkoth J.H. 2003. Lymph node cytology. *Vet. Clin. North Am., Small Anim. Pract.* 33:47-67.
- Del Massa E.C., Grion L.F.C. & Ghaname N.S. 2005. Reação alérgica ao corante azul patente. *São Paulo Med. J.* 123:53.

- Dowling P.M. 2009. Anaphylaxis, p.727-730. In: Silverstein D.C. & Hopper K. (Eds), *Small Animal Critical Care Medicine*. Saunders Elsevier, St Louis.
- Echt M.L., Finan M.A., Hoffman M.S., Kline R.C., Roberts W.S. & Fiorica J.V. 1999. Detection of sentinel lymph nodes with lymphazurin in cervical, uterine and vulvar malignancies. *South Med. J.* 92:204-208.
- EFSA 2013. Panel on Additives and Products or Substances used in Animal Feed (FEEDAP). Scientific opinion on the safety and efficacy of patent blue V (E 131) as feed additive for non-food producing animals. *EFSA Journal* 11:3108.
- Fontaine E., Levy X., Grellet A., Luc A., Bernex F., Boulouis H.J. & Fontbonne A. 2009. Diagnosis of endometritis in the bitch: a new approach. *Reprod. Domest. Anim.* 44:196-199.
- Fujita T. 1964. Characteristic distribution of mast cells in dog liver: a consideration on the mechanism of anaphylactic shock. *Arch. Histol. Japon. Nihon Soshikigaku Kiroku* 24:435-445.
- Greenway C.V. & Oshiro G. 1973. Effects of histamine on hepatic volume (outflow block) in anaesthetized dogs. *Brit. J. Pharmacol.* 47:282-290.
- Hardie E.M., Hansen B.D. & Carroll G.S. 1997. Behavior after ovariohysterectomy in the dog: what's normal? *Appl. Anim. Behav. Sci.* 51:111-128.
- Hirsch J.I., Tisnado J., Cho S.R. & Beachley M.C. 1982. Use of isosulfan blue for identification of lymphatic vessels: experimental and clinical evaluation. *Am. J. Roentgenol.* 139:1061-1064.
- Hou-Chuan Lai, Huan-Ming Hsu, Chen-Hwan Cherng, Shinn-Long Lin, Ching-Tang Wu, Jyh-Cherng Yu & Chun-Chang Yeh. 2011. Interference of patent blue dye with pulse oximetry readings, methemoglobin measurements, and blue urine in sentinel lymph node mapping: a case report and review of the literature. *Acta Anaesthesiol. Taiwan* 49:162-164.
- Hunting A.S., Nop A., Johansson S.G., Andersen F., Wilhelmsen V. & Guttormsen A.B. 2010. Anaphylaxis to patent blue V. *J. Clinical Aspects Allergy* 65:117-123.
- Jeady G., Louvier N., Rapennes T., Goujon E., Fraisse J., Dalac-Rat S. & Collet E. 2008. Immediate patent blue-induced hypersensitivity during sentinel node detection: the value of cutaneous tests. *Ann. Dermatol. Vener.* 135:461-465.
- Kahlenberg M.S., Kane J.M., Kanter P.M., Weber T.K., Gibbs J.F., Rodriguez-Bigas M.A. & Petrelli N.J. 2001. Hepatic lymphatic mapping: a pilot study for porta hepatis lymph node identification. *Cancer Invest.* 19:256-260.
- Kaneko J.R. 1997. Clinical biochemistry of domestic animal, p.932. In: Kaneko J.R. (Ed.), *Clinical Biochemistry of Domestic Animal*. 5th ed. Academic, San Diego.
- Klein M.K. 2007. Tumors of the female reproductive system, p.610-618. In: Withrow S.J. & Vail D.M. (Eds), *Small Animal Clinical Oncology*. Elsevier Saunders, Philadelphia.
- Lavy R., Kapiev A., Hershkovitz Y., Poluksht N., Rabin I., Chikman B., Shapira Z., Wasserman I., Sandbank J. & Halevy A. 2014. Tumor differentiation as related to sentinel lymph node status in gastric cancer. *World J. Gastrointest. Surg.* 6:1-4.
- Levenback C., Coleman R.L., Burke T.W., Lin W.M., Erdman W., Deavers M. & Delpassand E.S. 2002. Lymphatic mapping and sentinel node identification in patients with cervix cancer undergoing radical hysterectomy and pelvic lymphadenectomy. *J. Clin. Oncol.* 20:688-693.
- Lucas N., Interne S.B., Laine P., Nicolie B. & Fondrinier E. 2010. Choc anaphylactique et bleu patente: à propos de quatre cas et revue de la littérature. *J. Gynecol. Obst. Bio. Rev.* 39:116-120.
- Mathews K.A. 2000. Pain assessment and general approach to management. *Vet. Clin. North Am., Small. Anim. Prakt.* 30:729-755.
- Mertes P.M., Malinovsky J.M., Mouton-Faivre C., Bonnet-Boyer M.C., Benhajjoub A., Lavaud F., Valfrey J., O'Brien J., Pirat P., Lalourcey L. & Demoly P. 2008. Anaphylaxis to dyes during the perioperative period: reports of 14 clinical cases. *J. Allergy Clin. Immun.* 122:348-352.
- Mir F., Fontaine E., Albaric O., Greer M., Vannier F., Schlafer D.H. & Fontbonne A. 2013. Findings in uterine biopsies obtained by laparotomy from bitches with unexplained infertility or pregnancy loss: an observational study. *Theriogenology* 79:312-322.
- Montgomery L.L., Thorne A.C., Van Zee K.J., Fey J., Heerdt A.S., Gemignani M., Port E., Petrek J., Cody H.S. Cody 3rd & Borgen P.I. 2002. Isosulfan blue dye reactions during sentinel lymph node mapping for breast cancer. *Anesth. Analg.* 95:385-388.
- Noviana D., Mamba K., Makimura S. & Horii Y. 2004. Distribution, histochemical and enzyme histochemical characterization of mast cells in dogs. *J. Mol. Histol.* 35:123-132.
- Paget P.S., Kampine J.P., Schmeling W.T. & Warltier D.C. 1991. Comparison of the systemic and coronary hemodynamic actions of desflurane, isoflurane, halothane, and enflurane in the chronically instrumented dog. *Anesthesiology* 74:539-551.
- Pretzer S.D. 2008. Clinical presentation of canine pyometra and mucometra: a review. *Theriogenology* 70:359-363.
- Quantz J.E., Miles M.S., Reed A.L. & White G.A. 2009. Elevation of alanine transaminase and gallbladder wall abnormalities as biomarkers of anaphylaxis in canine hypersensitivity patients. *J. Vet. Emerg. Crit. Care* 19:536-544.
- Rodrigues M.A.P.A., Mazoni A.C.O., Carneiro P.C.A., Haeffner J.C. & Accetta Neto A. 2010. Efeito adverso do corante azul patente em paciente com câncer de mama, submetida à segmentectomia e biópsia de linfonodo sentinela (ls): relato de caso. *Revta Assoc. Med. Fluminense* 43:18-19.
- Sanders A.G. & Florey H.W. 1940. The Effects of the Removal of Lymphoid Tissue. *Brit. J. Exp. Pathol.* 21:275-287.
- Sant'Anna M.C., Giordano L.G.P., Flaiban K.K.M.C., Muller E.E. & Martins M.I.M. 2014. Marcadores prognósticos na piometra canina. *Arq. Bras. Med. Vet. Zootec.* 66:1711-1717.
- Shinzato J.Y., Marcaccini A.C.P., Braga A.F.A., Ribeiro A.R., Rubio J.E.M. & Souza J.P.D. 2006. Reação anafilática ao corante azul patente durante a biópsia do linfonodo sentinela em câncer de mama inicial; relato de caso. *Revta Bras. Ginecol. Obstet.* 28:728-732.
- Shmuel D.L. & Cortes Y. 2013. Anaphylaxis in dogs and cats. *J. Vet. Emerg. Crit. Care* 23:377-394.
- Tsioli V.G., Gouletsou P.G., Loukopoulos P., Zavlaris M. & Galatos A.D. 2011. Uterine leiomyosarcoma and pyometra in a dog. *J. Small Anim. Pract.* 52:121-124.
- Verbeek F.P., Troyan S.L., Mieog J.S.D., Liefers G.J., Moffitt L.A., Rosenberg M., Hirshfield-Bartek J., Gioux S., Velde C.J.H., Vahrmeijer A.L. & Frangiomi J.V. 2014. Near-infrared fluorescence sentinel lymph node mapping in breast cancer: a multicenter experience. *Breast Cancer Res. Treatm.* 143:333-342.
- Viana F.A.B. 2007. Valores bioquímicos de mamíferos domésticos, p.339. In: Viana F.A.B. (Ed.), *Guia Terapêutico Veterinário*. 2nd ed. Gráfica Editora CEM Ltda, Lagoa Santa.
- Viehli C.T., Guller U., Langer I., Laffer U., Oertli D. & Zuber M. 2013. Factors influencing the success of in vivo sentinel lymph node procedure in colon cancer patients: Swiss prospective, multicenter study sentinel lymph node procedure in colon cancer. *World J. Surg.* 37:873-877.
- Watts J., Wright P. & Lee C. 1998. Endometrial cytology of the normal bitch throughout the reproductive cycle. *J. Small Anim. Pract.* 39:2-9.
- Weiss R.R., Calomeno M.A., Sousa R.S., Briersdorf S.M., Calomeno R.A. & Muradás P. 2004. Avaliação histológica, hormonal e bacteriológica da piometra na cadela. *Arch. Vet. Sci.* 9:81-87.
- Wenzlow N., Tivers M.S., Selmic L.E., Scurrrell E.J., Baines S.J. & Smith K.C. 2009. Haemangiosarcoma in the uterine remnant of a spayed female dog. *J. Small Anim. Pract.* 50:488-491.