

Retina assessment by optical coherence tomography of diabetic dogs¹

Michelle B.P. Braga-Sá^{2*}, Paulo S.M. Barros², Juliana S. Jorge², Pamela Dongo²,
Paula Finkensieper³, Aline A. Bolzan², Sung S. Watanabe⁴ and Angélica M.V. Safatle²

ABSTRACT.- Braga-Sá M.B.P., Barros P.S.M., Jorge J.S., Dongo P., Finkensieper P., Bolzan A.A., Watanabe S.S. & Safatle A.M.V. 2018. [Retina assessment by optical coherence tomography of diabetic dogs.] *Pesquisa Veterinária Brasileira* 38(10):1966-1971. Laboratório de Investigação em Oftalmologia Comparada, Faculdade de Medicina Veterinária e Zootecnia, Universidade de São Paulo, Avenida Prof. Dr. Orlando Marques de Paiva 87, São Paulo, SP 05508-270, Brazil. E-mail: michellebarbosa@usp.br

Diabetes mellitus is one of the most common endocrine disorders characterized by relative or absolute lack of insulin; this can lead to several ocular manifestations, among them diabetic retinopathy and cataracts. Diabetic retinopathy (DR) is a microangiopathy that involves retinal precapillary arterioles, postcapillary venules, and large vessels, causing them to be functionally and anatomically incompetent. Hyperglycemia seems to be the most probable cause of damage to the retina due to interference in cellular metabolism and transduction processes. The aim of this study was to evaluate retinal thickness in eight diabetic dogs, four females and four males of different breeds and ages ranging from 6 to 15 years, by optical coherence tomography (OCT) and to compare them with non-diabetic dogs. Assessment provided by OCT in diabetic dogs showed retinal layers thinning and loss of stratification when compared to non-diabetic dogs (198µm versus 219µm respectively), with statistical significance ($p=0.008$). OCT images may suggest that diabetes mellitus causes retinal neuropathy in dogs, as also seen in diabetic humans.

INDEX TERMS: Optical coherence tomography, OCT, retina, dogs, retinal detachment, retinal atrophy, clinics.

RESUMO.- [Avaliação da retina de cães diabéticos pela tomografia de coerência óptica.] Diabete melito é umas das principais endocrinopatias, caracterizada pela deficiência relativa ou absoluta de insulina, que pode resultar em diversas manifestações oculares, sendo as mais frequentes a retinopatia diabética e a catarata. Retinopatia diabética (RD) é uma microangiopatia que afeta primeiramente as arteríolas pré-capilares, capilares, vênulas pós-capilares e vasos de maior calibre, causando incompetência funcional e

anatômica dos vasos retinianos. A hiperglicemia parece ser a causa mais provável da lesão retiniana, interferindo nas vias de metabolismo celular e no processo de transdução. Objetivou-se neste estudo avaliar e comparar a espessura retiniana total em oito cães diabéticos, quatro fêmeas e quatro machos, de diversas raças, com idade variando de seis a 15 anos, com auxílio de tomografia de coerência óptica (OCT) e comparar com a de cães não diabéticos. A espessura e arquitetura retiniana realizada pela OCT nos cães diabéticos, demonstrou afinamento das camadas da retina e perda da estratificação em comparação com os cães não diabéticos (198µm versus 219µm, respectivamente), sendo esta redução estatisticamente significativa ($p=0,008$). Baseado nas imagens da OCT pode-se sugerir que a diabete melito, no cão, cause neuropatia retiniana como descrito em humanos diabéticos.

TERMOS DE INDEXAÇÃO: Tomografia de coerência óptica, OCT, retina, cães, diabete melito, retinopatia diabética, clinica.

¹ Received on November 6, 2017.

Accepted for publication on December 18, 2017.

² Laboratório de Investigação em Oftalmologia Comparada, Departamento de Cirurgia, Faculdade de Medicina Veterinária e Zootecnia, Universidade de São Paulo (USP), Avenida Prof. Dr. Orlando Marques de Paiva 87, São Paulo, SP 05508-270, Brazil. *Corresponding author: michellebarbosa@usp.br

³ Laboratório de Anestesiologia, Faculdade de Medicina, Universidade de São Paulo (USP), Av. Dr. Arnaldo 455, Cerqueira César, São Paulo, SP 01246-903.

⁴ Faculdade de Medicina, Universidade Federal de São Paulo (Unifesp), Rua Sena Madureira 1500, Vila Clementino, São Paulo, SP 04021-001.

INTRODUCTION

Diabetes mellitus (DM) is a complex, multifactorial disease characterized by the absolute or relative lack of insulin (Beam et al. 1999) most frequently in elderly and middle-aged dogs (Fleeman & Rand 2001, Feldman & Nelson 2004). A cataract is described as one of the first symptoms of diabetes in dogs and usually results in visual impairment; diabetic retinopathy (DR) is the most common cause of vision loss among people (Landry et al. 2004).

DR mainly affects precapillary arterioles, postcapillary venules and greater vessels of the retina (Bosco et al. 2005, Crawford et al. 2009, Abrams et al. 2011). In humans, the onset of the disease is characterized by microaneurysms formation from small capillary beds sacculations that rupture and progress to hemorrhagic spots with or without exudation (Narfstrom & Petersen-Jones 2013). Diabetic retinopathy in humans can be classified according to its evolution, according to Early Treatment Diabetic Retinopathy Study (ETDRS) in mild non-proliferative DR, moderate to severe non-proliferative DR or preproliferative DR and proliferative DR (Corrêa & Eagle Junior 2005).

In dogs with spontaneous DM, DR takes three to five years to develop, whereas in dogs with induced DM it develops in approximately 2.3 years (Cullen & Webb 2013). This is characterized by vascular basement membrane thickening, pericytes loss, which leads to microaneurysms, capillary obstruction and smooth muscle cells and retinal arterioles damage (Muñana 1995). The first microvascular lesions only become visible, both in diabetic humans and dogs, after a few years of the onset of the disease (Kern & Engerman 1995, Cullen & Webb 2013).

Chronic hyperglycemia has a major role in the pathophysiology of microvascular damage in retinal tissue, leading to circulating changes such as decreased vascular tone, altered blood flow, increased vascular permeability, extravasations, edema, vascular obstruction, which leads to neovascularization with abnormal fragile vessels that tear and lead to hemorrhages and retinal detachment (Bosco et al. 2005). Some key points of retinal physiology may be predisposed to damage caused by diabetes. A lack of a myelin sheath on retinal axons, requiring more energy to function. Second, the amount of blood vessels able to absorb light is relatively low, and retinal internal vessels are hypoxic. And third, the inner retina (Nerve fiber layer, Ganglion cells layer, Inner plexiform layer and Inner nuclear layer) has fewer mitochondria than the outer layers. These characteristics of high metabolic demand and low vascular supply may limit the adaptation of the retina to metabolic stress (Serrarbassa et al. 2008).

Most cases of diabetic retinopathy in dogs are subclinical, and there are no reports of blindness from these complications (Muñana 1995). Thus, in dogs with diabetes, non-proliferative or background retinopathy occurs but not with the proliferative symptoms that usually develop in people (Narfstrom & Petersen-Jones 2013).

A new *in vivo* microscopy technique, the Optical Coherence Tomography (OCT), has been developed and allows evaluation of the retina's constitution and its structural integrity (Narfstrom & Petersen-Jones 2013), contributing to diagnosis and monitoring of several retinal diseases (Guedes & Yamane 2003, Gouveia et al. 2006, Song et al. 2010).

OCT is a recent addition in veterinary ophthalmology and its use is not widespread in most veterinary facilities. However, since it is a non-invasive, non-contact and high-resolution exam, it has a useful tool in the diagnosis of retinal and optic nerve diseases (Pugliese et al. 2006).

The main difference to obtain the images between man and canine is the head alignment that is challenging mainly in dolichocephalic dogs. Therefore the necessity to anesthetize the patients included in studies is emphasized (Hernandez-Merino et al. 2011).

OCT has allowed retinal assessment of type 1 and type 2 diabetic patients in people, displaying ganglion cells and nerve fibers thinning, with neurodegenerative effect in the early stages of the disease (Van Dijk et al. 2010, 2012). To the authors' knowledge, there are no reports of OCT use in diabetic dogs.

Our purpose was to investigate fundoscopic changes related to diabetic retinopathy in dogs by use of OCT, since could be models to the human disease.

MATERIALS AND METHODS

The study group included eight diabetic dogs (Diabetic mellitus group - DMG) of different breeds, four females and four males, aging from 6 to 15 years, mean age 10.3 years (± 3.2 years), aphakic (n=7) and pseudophakic (n=1). Control group (CG) consisted of nine healthy dogs (five females and four males) that varied in age from four to 15 years, mean age 6.9 years (± 3.8 years). Phacoemulsification was performed in the diabetic dogs previously so that optical coherence tomography (OCT) could be performed.

The patients were submitted to ophthalmologic evaluation, which included: Schirmer tear test[®] (Ophthalmos, São Paulo, Brazil); Fluorescein test (Fluorescein strips[®], Ophthalmos, São Paulo, Brazil); Tonometry (Tono-Pen XL[®], Bio-Rad X, Jacksonville, USA), and evaluation of the anterior segment (Kowa portable slit lamp, Tokyo, Japan). Ophthalmoscopy (Binocular indirect ophthalmoscope IO-H[®], Neitz Instruments, Tokyo, Japan) was performed after pupil dilation with 1% tropicamide eye drops (Ciclodrin, Latinofarma, São Paulo, Brazil). Assessment of retinal function, as a preoperative examination, was performed by 2000 Veris System Electroretinograph (ElectroDiagnostic Imaging Inc., Milpitas, USA), animals with extinguished ERG or that was compatible with progressive retinal atrophy were excluded. All patients underwent retinography (Kowa Genesis DF[®], Tokyo, Japan) after cataract surgery for documentation of the eye fundus survey findings.

Spectralis OCT (Heidelberg Engineering Spectralis OCT; Heidelberg Engineering, Franklin, USA) was used to perform OCT exam. Pupils of both eyes were dilated prior to examination with 1% tropicamide eye drops (Ciclodrin, Latinofarma, São Paulo, Brazil). All patients were submitted to general anesthesia to obtain proper quality images.

Animals were pre-medicated with an intramuscular injection of acepromazine (0.05mg/kg) (Acepran[®], Univet, São Paulo, Brazil) and meperidine (3mg/kg) (Petidina[®], Cristália, São Paulo, Brazil). Induction was performed with 5mg/kg of intravenous propofol (Propovan[®], Cristália, São Paulo, Brazil) and maintenance was performed with isoflurane (Forane[®], Abbott, São Paulo, Brazil) in 100% oxygen circular circuit (Aespire 7900, GE Healthcare, São Paulo, Brazil). Physiological variables, heart rate and rhythm, peripheral oxyhemoglobin saturation, respiratory rate, end-expired carbon dioxide concentration, inspiratory and expired isoflurane concentration, non-invasive blood pressure and temperature were monitored. All animals were positioned on a pantograph table in

sternal recumbency in front of the OCT device and the head was positioned on the head support. In some patients, atraumatic forceps and blepharostat were used under local anesthesia (Anestalcon®, Alcon Labs, São Paulo, Brazil) to keep eye static and open avoiding artifacts in the images. All corneas were constantly moistened with artificial lubricants (Systane®, Alcon-Labs, São Paulo, Brazil) and 0.9% saline solution to prevent dryness and maintain good image quality. The presence of tapetum lucidum in this species required adjustments in the apparatus, such as lighting and focus parameters.

To obtain images, the device was placed close to the eye, aided by a joystick. Retinal images were manually measured by Lines, Raster Lines and Radial Lines protocols. As the equipment was developed for human retinas, whole retinal thickness was manually measured with the caliper, by the distance between the retinal surface (nerve fiber layer) and the first visually reflective layer, the retinal pigment layer (RPE).

Choice of protocol varied according to pupillary diameter (for instance posterior synechiae that could prevent adequate pupillary dilatation) and/or opacity of the posterior capsule, since diabetic dogs of this study underwent previous phacoemulsification. Superior retina was assessed due to the difficult positioning of the head and precluded the acquisition of images of the other quadrants of the retina. Gray scale was used for better understanding of the images.

The OCT measurements were compared between the DM and Control groups by normality test (D'Agostino-Pearson test) and unpaired *t* test with significance level of 5%. This study was conducted at the Laboratory of Investigation in Comparative Ophthalmology, College of Veterinary Medicine, University of São Paulo, and was approved by the Institutional Animal Ethics Committee.

RESULTS

The purpose of optical coherence tomography (OCT) as a tool for assessment of retina structure in diabetic dogs was to suggest correlation with diabetic retinopathy. Total retinal thickness in the CG ranged from 203µm to 238µm (Table 1) and from 180µm to 227µm in the DMG (Table 2). The Figure 1 shows an OCT retinal image of the one dog belonging to CG, without alterations.

Until OCT was performed, average time after cataract surgery was 11 months and the average diabetes duration was 19 months (ranging from 12 to 29 months). None of the diabetic dogs presented neither ophthalmic alterations nor intraocular pressure changes. All patients from this study were receiving only medication prescribed for glycemic control.

Half of the patients from DMG had retinal thickness decreased (Fig.2 and 3). A diabetic dog presented a marked reduction of a small distorted area of the retinal architecture and hyperreflexia at the same site evaluated by OCT, reinforcing focal retinal atrophy (Fig.4), which was confirmed by retinography, indicated by a hyperreflective area (Fig.5).

Statistical analyses showed significant differences between mean OCT values for DMG and CG, with values of $198 \pm 17 \mu\text{m}$ and $219 \pm 11 \mu\text{m}$ ($p=0.008$) respectively.

DISCUSSION

The authors state that is the first study of optical coherence tomography (OCT) in retina of diabetic dogs that had previous phacoemulsification, until now. In addition, the absence of studies on retinal disease in these patients using cutting-edge technology, such as OCT, engaged us for this research.

Table 1. Epidemiological data of healthy dogs

Dog	Breed	Gender	Age (years)	Whole retinal thickness (µm)
1	Cocker Spaniel	F	10	220
2	Poodle	F	9	203
3	Mixed breed	F	15	209
4	Lhasa Apso	M	4	219
5	Pinscher	F	4	230
6	Shih Tzu	F	6	238
7	Maltese	M	5	212
8	Poodle	M	4	219
9	Poodle	M	5	217

Table 2. Epidemiological data of diabetic dogs

Dog	Breed	Gender	Age (years)	Whole retinal thickness (µm)
1	Mixed Breed	F	15	214
2	Maltese	M	13	181
3	Poodle	F	10	186
4	Poodle	M	10	227
5	Maltese	F	8	180
6	Retriever Labrador	M	7	204
7	Pug	M	6	201
8	Dachshund	F	13	191

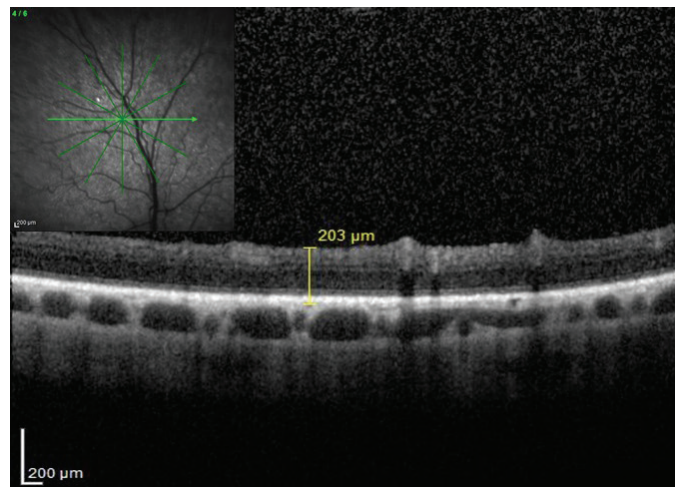


Fig.1. Retina of a 9-year-old healthy female Poodle from control group, with whole retinal thickness of 203µm, obtained by Infrared and OCT assessments.

DM is an endocrine disorder frequent in dogs which mainly affects the elderly and middle aged individuals (Beam et al. 1999, Fleeman & Rand 2001, Guptill et al. 2003, Feldman & Nelson 2004, Catchpole et al. 2005, Davison et al. 2005), like those of our study, which the mean age was 10.3 years.

Optical coherence tomography (OCT), is widely used in human ophthalmology by vitreous and retinal expert

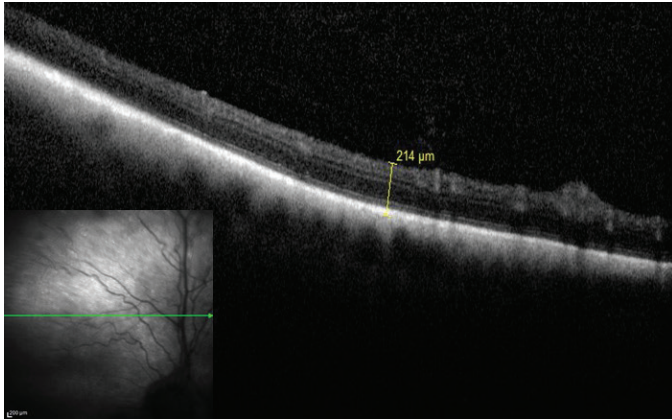


Fig.2. Temporal superior retina of a 15-year-old female, mixed breed, diabetic (case 1), obtained by infrared and OCT assessments. Note stratification of the preserved inner layer, with whole retinal thickness of 214 μ m.

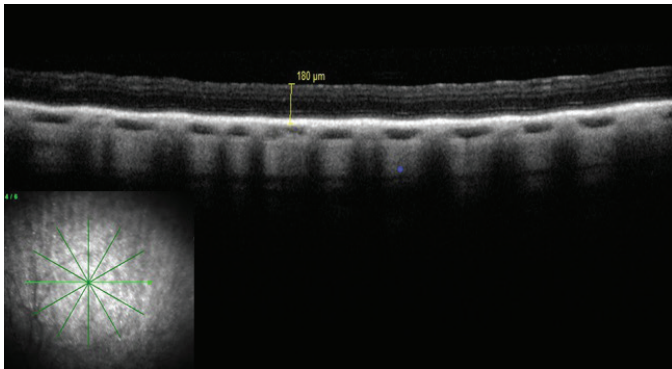


Fig.3. Peripheral radial retina of an 8-year-old female, Maltese, diabetic (case 5), obtained by infrared and OCT assessments. Note stratification of tapetal area and retinal layers with diffuse reduction. Whole retinal thickness of 180 μ m.

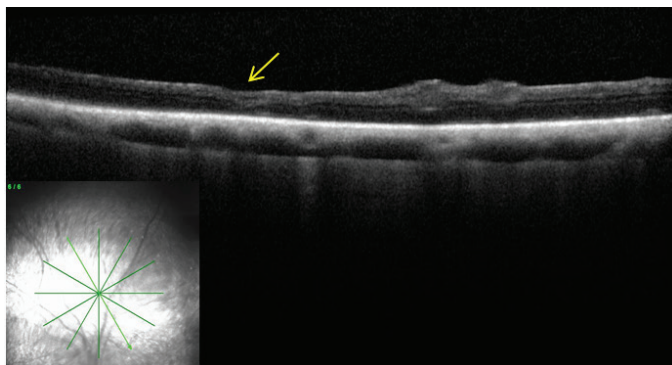


Fig.4. Radial scans of the superior retina of a 13-year-old female, Dachshund, diabetic (case 8), obtained by Infrared and OCT assessments. Note marked focal thinning and disorganization without stratification of retinal architecture (arrow).

clinicians to evaluate macular edema, epiretinal membranes, vitreous-macular traction, macular holes, subretinal fluid, photoreceptor and/or RPE layer changes, and of neovascular

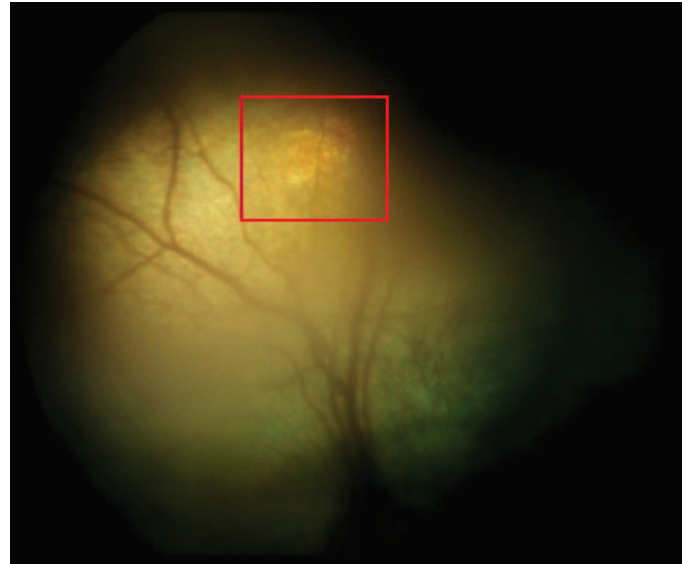


Fig.5. Retinography of a 13-year-old diabetic female Dachshund (case 8). Note altered coloration with hyperreflexia of the tapetal area (square). Such alteration can be assessed by OCT (Fig.4) and indicates focal retinal atrophy.

membranes in the choroid. It also helps to detect changes in the inner retinal layer and optic nerve head in patients with glaucoma and other optic neuropathies (McLellan & Rasmussen 2012). And OCT is been a reality in some veterinary hospitals around the world and even in Brazil to study several diseases in retina, such as progressive retinal atrophy, retinal detachment and also as our study diabetic retinopathy.

As previously described, DR is a common complication of DM and leads to blindness (Gaucher et al. 2007). Numerous studies have shown neural apoptosis, loss of ganglion cell bodies, glial reactivation and decreased thickness of the internal retinal layers in the early stages of DR in humans. It is proposed that diabetes causes retinal neuropathy due to microvascular mechanism (Van Dijk et al. 2010). Not only in humans, but experimental studies in animals describe apoptosis of neural and glial cells in the early stages of DR (Biallostowski et al. 2007). Likewise, to investigate funduscopy the changes regarding to diabetic dogs become valuable whereas that dog could be models to the human disease.

Several studies have shown a decrease in whole retinal thickness by OCT in patients with DR or compared to non-diabetic patients, indicating that the initial neurodegenerative effect on the retina in diabetes occurs even if the vascular component of DR remains minimal (Van Dijk et al. 2010, 2012). Indeed, this data corroborates with the OCT findings in our study, which mean retinal thickness was 198 μ m for DMG and 219 μ m for CG, being statistically significant, suggesting that the concept of neurodegeneration affects even the diabetic dogs.

One of the dogs presented marked thinning with disorganization of the internal retinal architecture indicating focal atrophy (Fig.4). This image was correlated with the retinography that revealed a hyperreflective area (Fig.5). According to Monti et al. (1976), emphasize that hyperreflexia may indicate recent injury or characterize the transition from progressive phase to a degenerative inactive phase and could

be observed it in other pathological conditions. Regardless, this finding is not pathognomonic of diabetes, indicating only retinal lesion.

One limitation of this study was lack of pet owner's cooperation in attending the appointments and bringing the patients for examination, because general anesthesia was required, besides imprecise information given on anamneses. Other important limitations were the opacity of the posterior lens capsule and the presence of synechiae in the postoperative period, which disturbed OCT's cut pattern, and therefore the retinal area evaluated was random in diabetic patients.

Diabetic patients after cataract surgery tend to have more inflammation in the immediate postoperative period, in addition to frequent inflammatory episodes after surgery (Bras et al. 2006). In diabetic humans the inflammatory reaction after cataract surgery was also more intense in relation to nondiabetics (Zaczek & Zetterstrom 1998), contributing to synechiae formation, as well as posterior capsule opacity.

The position of the head is the most important factor influencing the execution of the SD-OCT exam in canine patients, imposing a challenge for the acquisition of high quality images, especially in dolichocephalic breeds. This adds greatly to the reasons why general anesthesia is required for most veterinary patients (Hernandez-Merino et al. 2011) except for extremely calm and cooperative dogs (Grahn et al. 2008, Safatle et al. 2015). Therefore, all animals in this study were submitted to general anesthesia in order to facilitate the acquisition of images and thereby improve their quality. Furthermore, our study focused on evaluating the superior retina only due to the difficult positioning of the head and hindered capture of high quality images of the other quadrants of the retina, since the OCT device is configured for human use.

CONCLUSIONS

Our results, compared with the literature, suggest that dogs in the early stages of diabetic retinopathy (DR), have a neurodegenerative change, similar to diabetic humans.

Imaging techniques, such as optical coherence tomography (OCT) should be used as part of the ophthalmologic examination in diabetic dogs.

Acknowledgements.- This study was supported by FAPESP grant nº 2011/24039-8.

REFERENCES

- Abrams K.L., Stabila P.F., Kauper K. & Elliott S. 2011. Vascular endothelial growth factor in diabetic nondiabetic canine cataracts patients. *Vet. Ophthalmol.* 14(2):93-99. <<http://dx.doi.org/10.1111/j.1463-5224.2010.00846.x>> <PMid:21366824>
- Beam S., Correa M.T. & Davidson M.G. 1999. A retrospective-cohort study on the development of cataracts in dogs with diabetes mellitus: 200 cases. *Vet. Ophthalmol.* 2(3):169-172. <<http://dx.doi.org/10.1046/j.1463-5224.1999.00073.x>> <PMid:11397260>
- Biallostowski C., Van Velthoven M.E.J., Michels R.P.J., Schlingemann R.O., Devries J.H. & Verbraak F.D. 2007. Decreased optical coherence tomography-measured pericentral retinal thickness in patients with diabetes mellitus type 1 with minimal diabetic retinopathy. *Brit. J. Ophthalmol.* 91(9):1135-1138. <<http://dx.doi.org/10.1136/bjo.2006.111534>> <PMid:17383994>
- Bosco A., Lerário A.C., Soriano D., Santos R.F., Massote P., Galvão D., Franco A.C., Purisch S. & Ferreira A.R. 2005. Retinopatia diabética. *Arq. Bras.*

- Endocrinol. Metabol.* 49(2):217-227. <<http://dx.doi.org/10.1590/S0004-27302005000200007>> <PMid:16184249>
- Bras I.D., Colitz C.M.H., Saville W.J.A., Gemensky-Metzler A.J. & Wilkie D.A. 2006. Posterior capsular opacification in diabetic and nondiabetic canine patients following cataract surgery. *Vet. Ophthalmol.* 9(5):317-327. <<http://dx.doi.org/10.1111/j.1463-5224.2006.00458.x>> <PMid:16939460>
- Catchpole B., Ristic J.M., Fleeman M. & Davison L.J. 2005. Canine diabetes mellitus: can old dogs teach us new tricks? *Diabetology* 48(10):1948-1956. <<http://dx.doi.org/10.1007/s00125-005-1921-1>> <PMid:16151773>
- Corrêa Z.M.S. & Eagle Junior J.R. 2005. Aspectos patológicos da retinopatia diabética. *Arq. Bras. Oftalmol.* 68(3):410-414. <<http://dx.doi.org/10.1590/S0004-27492005000300028>> <PMid:16059581>
- Crawford T.N., Alfaro 3rd D.V., Kerrison J.B. & Jablon E.P. 2009. Diabetic retinopathy and angiogenesis. *Curr. Diabetes Rev.* 5(1):8-13. <<http://dx.doi.org/10.2174/157339909787314149>> <PMid:19199892>
- Cullen C.L. & Webb A.A. 2013. Ocular manifestations of systemic disease. 1. The dog, p.1897-1977. In: Gelatt K.N., Gilger B.C. & Kern T.J. (Eds), *Veterinary Ophthalmology*. 5th ed. Blackwell Publishing, Iowa.
- Davison L.J., Herrtage M.E. & Catchpole B. 2005. Study of 253 dogs in united kingdom with diabetes mellitus. *Vet. Rec.* 156(15):467-471. <<http://dx.doi.org/10.1136/vr.156.15.467>> <PMid:15828742>
- Feldman E.C. & Nelson R.W. 2004. Canine diabetes mellitus, p.486-538. In: Feldman E.C. & Nelson R.W. (Eds), *Canine and Feline Endocrinology and Reproduction*. 4th ed. W.B. Saunders, St Louis.
- Fleeman L.M. & Rand J.S. 2001. Management of canine diabetes. *Vet. Clin. N. Am., Small. Anim. Pract.* 31(5):855-880. <[http://dx.doi.org/10.1016/S0195-5616\(01\)50003-0](http://dx.doi.org/10.1016/S0195-5616(01)50003-0)>
- Gaucher D., Chiappore J.A., Pâques M., Simonutti M., Boitard C., Sahel J.A., Massin P. & Picaud S. 2007. Microglial changes occur without neural cell death in diabetic retinopathy. *Vis. Res.* 47(5):612-623. <<http://dx.doi.org/10.1016/j.visres.2006.11.017>> <PMid:17267004>
- Gouveia E.B., Morales M.S.A., Allemann N., Matte G., Berezovsky A. & Sallum J.M.F. 2006. Aspectos da tomografia de coerência óptica na doença de stargardt: relato de caso. *Arq. Bras. Oftalmol.* 69(4):589-592. <<http://dx.doi.org/10.1590/S0004-27492006000400025>> <PMid:17119737>
- Grahn B.H., Sandmeyer L.L. & Breaux C. 2008. Retinopathy of cotton de tular dogs: clinical manifestations, electroretinographic, ultrasonographic, fluorescein and indocyanine green angiographic, and optical coherence tomographic findings. *Vet. Ophthalmol.* 11(4):242-249. <<http://dx.doi.org/10.1111/j.1463-5224.2008.00632.x>> <PMid:18638350>
- Guedes V. & Yamane R. 2003. Tomografia de coerência óptica, p.225-236. In: Yamane R. (Eds), *Semiologia Ocular*. 2ª ed. Cultura Médica, Rio de Janeiro.
- Guptill L., Glickman L. & Glickman N. 2003. Time trends and risk factors for diabetes mellitus in dogs: analysis of veterinary medical data base. *Vet. J.* 165(3):240-247. <[http://dx.doi.org/10.1016/S1090-0233\(02\)00242-3](http://dx.doi.org/10.1016/S1090-0233(02)00242-3)> <PMid:12672370>
- Hernandez-Merino E., Kecova H., Jacobson S.J., Hamouche K.N., Nzokwe R.N. & Grozdanic S.D. 2011. Spectral domain optical coherence tomography (sd-oct) assessment of healthy female canine retina and optic nerve. *Vet. Ophthalmol.* 14(6):400-405. <<http://dx.doi.org/10.1111/j.1463-5224.2011.00887.x>> <PMid:22050777>
- Kern T.S. & Engerman R.L. 1995. Vascular lesions in diabetes are distributed non-uniformly within the retina. *Exp. Eye Res.* 60(5):545-549. <[http://dx.doi.org/10.1016/S0014-4835\(05\)80069-7](http://dx.doi.org/10.1016/S0014-4835(05)80069-7)> <PMid:7615020>
- Landry M.P., Herring I.P. & Panciera D.L. 2004. Fundoscopic findings following cataract extraction by means of phacoemulsification in diabetic dogs: 52 cases (1993-2003). *J. Am. Vet. Med. Assoc.* 225(5):709-716. <<http://dx.doi.org/10.2460/javma.2004.225.709>> <PMid:15457664>
- McLellan G.J. & Rasmussen C.A. 2012. Optical coherence tomography for the evaluation of retinal and optic nerve morphology in animal subjects:

- practical considerations. *Vet. Ophthalmol.* 15(Suppl.2):13-28. <<http://dx.doi.org/10.1111/j.1463-5224.2012.01045.x>> <PMid:22805095>
- Monti F, Bellan B, Peruccio C. & Berardi S. 1976. The clinical picture of diabetic retinopathy in dogs. *Folia Vet. Lat.* 6(3):249-274. <PMid:1010501>
- Muñana K.R. 1995. Long-term complications of diabetes mellitus. 1. Retinopathy, nephropathy, neuropathy. *Vet. Clin. N. Am., Small Anim. Pract.* 25(3):715-730. <[http://dx.doi.org/10.1016/S0195-5616\(95\)50064-6](http://dx.doi.org/10.1016/S0195-5616(95)50064-6)> <PMid:7660543>
- Narfström K. & Petersen-Jones S. 2013. Disease of the canine ocular fundus, p.1303-1392. In: Gelatt K.N., Gilger, B.C. & Kern T.J. (Eds), *Veterinary Ophthalmology*. 5th ed. Blackwell Publishing, Iowa.
- Pugliese A., Trombetta C.J., Bonanno G., Freno M.C., Nasso S. & Di Pietro S. 2006. Oct in the dog and cat: morphostructural patterns and clinical features of the fundus. *Vet. Res. Comun.* 30(S1):313-315. <<http://dx.doi.org/10.1007/s11259-006-0069-x>>
- Safatle A.M.V., Braga-Sá M.B.P. & Barros P.S.M. 2015. Aspectos da tomografia de coerência óptica em cães com retinopatia. *Pesq. Vet. Bras.* 35(2):153-159. <<http://dx.doi.org/10.1590/S0100-736X2015000200010>>
- Serrarbassa P.D., Dias A.F.G. & Vieira M.F. 2008. Novos conceitos em retinopatia diabética: dano neurológico versus dano vascular. *Arq. Bras. Oftalmol.* 71(3):459-463. <<http://dx.doi.org/10.1590/S0004-27492008000300030>> <PMid:18641842>
- Song S.E., Aggio F.B. & Farah M.E. 2010. Distrofias maculares, p.285-288. In: Farah M.E. (Eds), *Tomografia de Coerência Óptica*. 2ª ed. Cultura Médica, Rio de Janeiro.
- Van Dijk H.W., Verbraak F.D., Kok P.H.B., Stehouwer M., Garvin M.K., Sonka M., DeVries J.H., Schlingemann R.O. & Abràmoff M.D. 2012. Early neurodegeneration in the retina of type 2 diabetic patients. *Invest. Ophthalm. Visual Sci.* 53(6):2715-2719. <<http://dx.doi.org/10.1167/iovs.11-8997>> <PMid:22427582>
- Van Dijk H.W., Verbraak F.D., Kok P.H., Garvin M.K., Sonka M., Lee K., DeVries J.H., Michels R.P., Van Velthoven M.E., Schlingemann R.O. & Abràmoff M.D. 2010. Decreased retinal ganglion cell layer thickness in patients with type 1 diabetes. *Invest. Ophthalm. Visual Sci.* 51(7):3660-3665. <<http://dx.doi.org/10.1167/iovs.09-5041>> <PMid:20130282>
- Zaczeck A. & Zetterstrom C. 1998. Aqueous flare intensity after phacoemulsification in patients with diabetes mellitus. *J. Cataract Refract. Surg.* 24(8):1099-1104. <[http://dx.doi.org/10.1016/S0886-3350\(98\)80104-1](http://dx.doi.org/10.1016/S0886-3350(98)80104-1)> <PMid:9719970>