

The clinical value of lung ultrasound in premature infants with bronchopulmonary dysplasia

Jingyi Xu¹ , Yikang Fu¹ , Fang Wang¹ , Wen Zhou¹ , Lan Chen¹ , Ling Liu^{1*} 

SUMMARY

OBJECTIVE: This study aimed to explore the risk factors of bronchopulmonary dysplasia in premature infants and the clinical application value of lung ultrasound in the diagnosis of bronchopulmonary dysplasia.

METHODS: A total of 80 premature infants with a gestational age of <32 weeks or a birth weight of <1,500 g who were treated in our hospital from January to August 2021 were randomly divided into a bronchopulmonary dysplasia group (n=12) and a non-bronchopulmonary dysplasia group (n=62). The clinical data, lung ultrasound, and X-ray image characteristics of the two groups were compared.

RESULTS: Among the 74 preterm infants, 12 preterm infants were diagnosed with bronchopulmonary dysplasia, and 62 preterm infants were determined not to have bronchopulmonary dysplasia. There were significant differences in sex, severe asphyxia, invasive mechanical ventilation, premature membrane ruptures, and intrauterine infection between the two groups ($p<0.05$). Lung ultrasound showed abnormal pleural lines and alveolar-interstitial syndrome in all 12 patients with bronchopulmonary dysplasia and vesicle inflatable signs in 3 patients. Before clinical diagnosis, the accuracy, sensitivity, specificity, positive predictive value, and negative predictive value of lung ultrasound in the diagnosis of bronchopulmonary dysplasia were 98.65, 100, 98.39, 92.31, and 100%, respectively. The accuracy, sensitivity, specificity, positive predictive value, and negative predictive value of X-rays in the diagnosis of bronchopulmonary dysplasia were 85.14, 75.00, 87.10, 52.94, and 94.74%, respectively.

CONCLUSION: The diagnostic efficiency of lung ultrasound for premature bronchopulmonary dysplasia is better than that of X-rays. The application of lung ultrasound can screen patients with bronchopulmonary dysplasia early for timely intervention.

KEYWORDS: Premature birth. Bronchopulmonary dysplasia. Lung. Ultrasonography.

INTRODUCTION

Bronchopulmonary dysplasia (BPD) is one of the most common and serious respiratory diseases in premature infants¹ and is life-threatening². In recent years, the incidence of BPD has increased³. Since the pathogenesis of BPD is not yet clear, there is still no effective clinical treatment for BPD, and only supportive care is used. To further improve the survival rate of premature infants and life quality in later growth and development, early and effective diagnosis of BPD is particularly important. It is necessary to identify the occurrence of BPD in premature infants early and take preventive and control measures. The diagnostic criteria formulated by the National Institute of Child and Human Development (NICHD) are not of great value for early diagnosis (within 28 days). Although X-rays are applied in early diagnosis, they are not convenient for detection and cannot be used at the bedside. Moreover, due to radiation, X-rays cannot be used for continuous monitoring. With the rapid development of ultrasound technology, lung ultrasound (LUS) has been widely used in the diagnosis

of paediatric lung diseases. As a method for the diagnosis and treatment of pulmonary diseases in children, LUS has a high probability of producing a correct diagnosis and a high sensitivity and specificity⁴. At present, the application of LUS in the diagnosis of neonatal diseases is gradually being promoted and recognised by many clinicians. In this study, the NICHD's standard was used as the gold standard for BPD diagnosis, and the predictive values of LUS and X-ray examinations for BPD in premature infants were compared.

METHODS

Research objects

Preterm infants under 32 weeks who were admitted to our hospital from January 2021 to August 2021 were selected as the research subjects (a total of 248 neonates under 32 weeks were admitted during the period). Inclusion criteria include (1) admission within 24 h after birth and (2) a gestational

¹Guiyang Maternal and Child Health Care Hospital, Department of Neonates – Guiyang, China.

*Corresponding author: liulingxll@163.com

Conflicts of interest: the authors declare there is no conflicts of interest. Funding: This study was funded by the 2020 Guiyang City High-level Innovative Young Health Talent Training Program and the Project of Guiyang Science and Technology Bureau.

Received on August 19, 2022. Accepted on October 14, 2022.

age score at birth of <32 weeks or a birth weight of <1500 g. Exclusion criteria include (1) the mother received an abnormal non-invasive DNA test or amniocentesis during her obstetric examination; (2) severe congenital malformations were suggested before birth; (3) imaging showed congenital pulmonary dysplasia, such as a congenital diaphragmatic hernia or isolated lung; or (4) corrected gestational age before 36 weeks of death. A total of 80 neonates were randomly enrolled. Treatment was ceased for three of these patients due to financial difficulties, and three died during treatment. The final sample size was 74.

The participants were divided into a BPD group (n=12) and a non-BPD group (n=62). The diagnostic criteria of BPD follow the consensus of the NICHD: children with a gestational age of <32 weeks should be diagnosed with BPD at 36 weeks of corrected gestational age or 28 days after birth (56 days at the latest). The diagnostic criterion includes any neonate who is oxygen-dependent [inspired oxygen concentration (FiO₂) >21%] for more than 28 days⁵.

Research methods

Lung ultrasound inspection

Lung ultrasound examination method: Neonates were placed in supine and lateral positions, and GE LOGIQ P6 Pro and GE high-frequency line shock probe (15 Hz) ultrasonic diagnostic apparatuses were used for ultrasonography in a quiet state. The parasternal line, the anterior axillary line, the posterior axillary line, and the double nipple line were divided into six lung areas, namely, anterior superior, anterior inferior, superior axillary, axillary, posterior superior, and posterior inferior. A total of 12 lung areas on both sides were scanned, and the images were saved. The first LUS examination was performed within 24 h after the neonate was admitted to the hospital, and thereafter, it was reviewed twice a week until discharge.

Observation indicators for the diagnosis of BPD by LUS include the following: ① abnormal pleural line, ② B-line, ③ alveolar-interstitial syndrome, and ④ signs of vesicular effusion or bronchial fluid filling.

Chest X-ray examination

A MobileDiagnost wDR (Philips Medical DMC GmbH) machine was selected, and the supine position and anterior-posterior views were taken. X-ray examinations were performed within 24 h of the neonate's admission, and chest X-ray examinations were performed at 4 weeks after birth or at 36 weeks of corrected gestational age.

Observational indicators of the X-ray diagnosis of BPD: ① Stage I (1–3 days): ground-glass-like changes in both lungs, ② Stage II (4–10 days): complete opacity of both lungs, ③ Stage III (11–30 days): small transparent cysts with restarting between linear or patchy shadows in both lung fields, and ④ Stage IV (after 1 month): the luminal areas of both lung fields enlarged to form vesicles, with hyperinflation and atelectasis.

Statistical analysis

The SPSS version 22.0 software was used for statistical analysis. The measurement data were analysed with an independent sample t-test, and the count data were analysed with a χ^2 test. A p<0.05 indicated a statistically significant difference.

RESULTS

Comparison of clinical data between bronchopulmonary dysplasia and non-bronchopulmonary dysplasia

Among the 74 premature infants, 12 were patients with BPD, and 62 were patients without BPD. There were 11 males and 1 female in the BPD group, with an average age of 29.29±2.79 weeks and a weight of 1240±75.41 g. There were 31 males and 31 females in the non-BPD group, with an average age of 30.43±1.71 weeks and a weight of 1439±40.65 g. There were significant differences in birth weight, gender, severe asphyxia, use of invasive mechanical ventilation, premature rupture of membranes, and intrauterine infection between the two groups (p<0.05) (see Table 1).

Image features of lung ultrasound and X-ray diagnosis of bronchopulmonary dysplasia

A total of 12 children with BPD underwent dynamic LUS examination (Figure 1A). All of them showed abnormal pleural lines and alveolar-interstitial syndrome changes, and three patients showed signs of air vesicles.

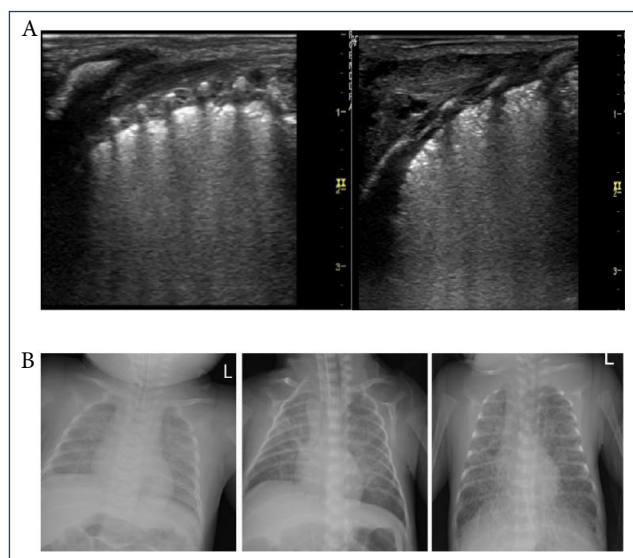
A total of 12 children with BPD were examined using X-rays (Figure 1B). There were three cases with no obvious abnormal features, nine cases with bilateral lung ground-glass-like changes, five cases with linear or patchy shadows, and three cases with cystic translucent shadows.

Comparison of bronchopulmonary dysplasia prediction results between lung ultrasound and X-rays

Before clinical diagnosis, the LUS results were consistent with the confirmed cases in 73 children, and the diagnostic

Table 1. Comparison of clinical data between the bronchopulmonary dysplasia group and non-bronchopulmonary dysplasia group.

Group	Gestational age (week)	Sex (male/female)	Born body (g)	Small for gestational age (yes/no)	Severe asphyxia (yes/no)	Invasive mechanical ventilation (yes/no)
Non-BPD group (n=62)	30.43±1.71	31/31	1439±40.65	7/55	1/61	20/42
BPD group (n=12)	29.29±2.79	11/1	1240±75.41	3/9	3/9	8/4
t/ χ^2 value	1.91	7.11	2.09	1.62	10.75	5.06
p	0.06	0.01	0.04	0.20	<0.01	0.02
Group	Premature rupture of membranes (yes/no)	Intrauterine infection (yes/No)	Preeclampsia (yes/no)	Gestational diabetes (yes/no)	Prenatal use of antibiotics (yes/no)	Prenatal hormone use (yes/no)
Non-BPD group (n=62)	46/16	5/57	4/58	6/56	26/36	46/16
BPD group (n=12)	4/8	5/7	1/11	0/12	2/10	6/6
t/ χ^2 value	7.66	9.71	0.06	1.26	2.73	2.82
p	<0.01	<0.01	0.81	0.26	0.10	0.09

**Figure 1.** (A) Lung ultrasound image features. (B) X-ray image features.

accuracy was 98.65%. When LUS was used to predict BPD, its sensitivity, specificity, positive predictive value, and negative predictive value were 100, 98.39, 92.31, and 100%, respectively. The X-ray results were consistent with the confirmed cases in 63 children, and the diagnostic accuracy rate was 85.14%. When X-rays were used to predict BPD, their sensitivity, specificity, positive predictive value, and negative predictive value were 75.00, 87.10, 52.94, and 94.74%, respectively (see Table 2).

DISCUSSION

Prolonged use of supplemental oxygen for BPD in preterm infants, high mortality, residual airway hyperresponsiveness in surviving infants, repeated lower respiratory tract infections, feeding difficulties, and growth retardation⁶⁻⁸ make the prevention and treatment of BPD a key research topic in the Department of Neonatology. Compared with the non-BPD group, the BPD group had lower birth weights and a higher proportion of male infants, severe asphyxia, invasive mechanical ventilation, premature membrane ruptures, and intrauterine infections. This is generally consistent with previous reports of risk factors for BPD in preterm infants^{9,10}. There was an inverse linear relationship between low birth weight and the incidence of BPD. Neonates with a birth weight of <1500 g have a 20% chance of developing BPD¹¹, and those with a birth weight of <1000 g have an even higher chance of developing BPD¹². The high risk of BPD in premature infants with very low birth weights is mainly related to the defective development of their organs¹³. The high incidence of BPD in male infants is mainly due to the relationship between oestrogen and pulmonary surfactant production. Costeloe et al. reported that the incidence of BPD in male infants was twice that of female infants¹⁴. Invasive mechanical ventilation produces a large amount of toxic peroxide substances under high concentrations of oxygen, causing lung damage and increasing the incidence of BPD¹⁵. Infection is a key link in the occurrence of BPD. Intrauterine infection can induce the premature rupturing of membranes. Relevant

Table 2. Clinical value of lung ultrasound and X-rays in predicting bronchopulmonary dysplasia (%).

Inspection method	Sensitivity (%)	Specificity (%)	Positive predictive value (%)	Negative predictive value (%)	Diagnostic accuracy (%)
LUS	100	98.39	92.31	100	98.65
X-rays	75.00	87.10	52.94	94.74	85.14

literature reports that when the mother has an intrauterine infection, the inflammatory factors that are produced can mediate foetal lung injury in preterm infants¹⁶. Birth weight, asphyxia, invasive mechanical ventilation, premature membrane rupture, and intrauterine infection can be used as important indicators for predicting BPD in preterm infants.

In recent years, LUS examination has been widely used in the diagnosis of respiratory diseases in premature infants. Compared with computed tomography (CT) and X-ray examinations, LUS has the advantages of being able to be carried out at the bedside, without radiation, and being able to be dynamically monitored¹⁷. Some studies of ultrasound for the diagnosis of BPD have been reported. Alonso-Ojebarrera et al. performed a dynamic LUS examination on 59 premature infants with a gestational age of ≤ 32 weeks and/or birth weight of $\leq 1,500$ g¹⁸. Their results show that the sensitivity and specificity of LUS for diagnosing BPD were 71 and 80%, respectively, at 1 week after birth; 74 and 100%, respectively, at 2 weeks after birth; and 100 and 100%, respectively, at 4 weeks after birth. The experimental results of Balany et al. indicated that LUS can be used as an auxiliary examination method to predict the risk of BPD in premature infants¹⁹. In this study, before the clinical diagnosis of BPD, the accuracy, sensitivity, specificity, positive predictive value, and negative predictive value of LUS in diagnosing BPD were 98.65, 100, 98.39, 92.31, and 100%, respectively, which are significantly higher than the clinical efficacy index of X-rays for the diagnosis of BPD. The characteristic images of LUS in children with BPD +are mainly abnormal pleural lines, alveolar-interstitial syndrome, and changes in air vesicle signs. The results of this study are basically consistent with the previous reports of Liu et al.²⁰. Liu et al. observed ultrasound signs such as pleural line abnormalities (insect-eaten changes), interstitial pulmonary syndrome, and air vesicle signs, and the sensitivity and specificity for diagnosing BPD were both 100%. It is completely feasible to use LUS to replace X-rays in neonatal wards for the early diagnosis of neonatal BPD²⁰.

However, this study has certain limitations. First, when using ultrasound to diagnose BPD, although physicians in the

ultrasound department took the pictures and read the reports independently of each other, due to the subjectivity of interpretation and the influence of clinical information, the results may be biased in selection and measurement. Second, this study discussed only the diagnostic value of LUS for BPD but not its correlation with clinical features (such as the degree of lung lesions). Third, the sample size of this study was small, and an experiment with a large sample should be conducted in the future to confirm the generalisability of the results of this study.

CONCLUSION

In the process of clinical diagnosis and treatment, intervention strategies should be formulated according to their risk factors to improve the survival rate and prognosis of premature infants. As an effective detection method to predict the occurrence of BPD in premature infants, LUS can replace X-ray examination to guide the clinical formulation of accurate treatment plans, track the progress and outcome of the disease, and reduce the incidence of BPD. Therefore, LUS is recommended for clinical use.

ETHICS APPROVAL AND CONSENT TO PARTICIPATE

This study was conducted in accordance with the Declaration of Helsinki and approved by the ethics committee of Guiyang Maternal and Child Health Care Hospital.

AUTHORS' CONTRIBUTIONS

JX: Conceptualization, Formal Analysis, Investigation, Methodology, Project administration, Resources, Supervision, Visualization, Writing – original draft, Writing – review & editing. **YF:** Data curation, Investigation, Software. **LL:** Data curation, Methodology, Project administration, Writing – review & editing. **FW:** Data curation, Software. **WZ:** Data curation, Validation. **LC:** Data curation, Validation.

REFERENCES

1. Yu HK, Liu X, Chen JK, Li ZH, Wang S, Huang JH, et al. Clinical value of lung ultrasound score in diagnosis and prognosis of children with severe pneumonia. *Chin J Ultrasound Med.* 2019;35(3):229-31.
2. Neonatal Group of Pediatrics Branch of Chinese Medical Association, Editorial Board of Chinese Journal of Pediatrics. Expert consensus on clinical management of premature infants with bronchopulmonary dysplasia. *Chin J Pediatrics.* 2020;58(5):358-9. <https://doi.org/10.3760/cma.j.cn112140-20200317-00254>
3. Yin X, Zong SY, Tang YL, Liu Y, Jiang LH. The value of pulmonary ultrasound scoring in predicting bronchopulmonary dysplasia in premature infants. *Chin J Ultrasound Med.* 2019;3(12):1076-8.
4. Kiciński P, Kęsiak M, Nowiczewski M, Gulczyńska E. Bronchopulmonary dysplasia in very and extremely low birth weight infants – analysis of selected risk factors. *Pol Merkur Lekarski.* 2017;42(248):71-5. PMID: 28258680
5. Li RW. Research progress of diagnostic criteria for bronchopulmonary dysplasia. *J Clin Pediatrics.* 2021;39(4):308-12.
6. Li JF, Zhu XP. Analysis of risk factors for bronchopulmonary dysplasia in very low birth weight infants. *Matern Child Health Care China.* 2018;33(23):5565-9.
7. Villamor-Martínez E, Pierro M, Cavallaro G, Mosca F, Kramer B, Villamor E. Probiotic supplementation in preterm infants does not affect the risk of bronchopulmonary dysplasia: a meta-analysis of randomized controlled trials. *Nutrients.* 2017;9(11):1197. <https://doi.org/10.3390/nu9111197>
8. Kim JK, Chang YS, Sung S, Ahn SY, Yoo HS, Park WS. Trends in survival and incidence of bronchopulmonary dysplasia in extremely preterm infants at 23–26 weeks gestation. *J Korean Med Sci.* 2016;31(3):423-9. <https://doi.org/10.3346/jkms.2016.31.3.423>
9. Daurat A, Millet I, Roustan JP, Maury C, Taourel P, Jaber S. Thoracic trauma severity score on admission allows to determine the risk of delayed ARDS in trauma patients with pulmonary contusion. *Injury.* 2016;47(1):147-53. <https://doi.org/10.1016/j.injury.2015.08.031>
10. Mojoli F, Bouhemad B, Mongodi S, Lichtenstein D. Lung ultrasound for critically ill patients. *Am J Respir Crit Care Med.* 2019;199(6):701-14. <https://doi.org/10.1164/rccm.201802-0236CI>
11. Lardón-Fernández M, Uberos J, Molina-Oya M, Narbona-López E. Epidemiological factors involved in the development of bronchopulmonary dysplasia in very low birth-weight preterm infants. *Minerva Pediatr.* 2017;69(1):42-9. <https://doi.org/10.23736/S0026-4946.16.04215-8>
12. Maturu P, Wei-Liang Y, Jiang W, Wang L, Lingappan K, Barrios R, et al. Newborn mice lacking the gene for cyp1a1 are more susceptible to oxygen-mediated lung injury, and are rescued by postnatal β -naphthoflavone administration: implications for bronchopulmonary dysplasia in premature infants. *Toxicol Sci.* 2017;157(1):260-71. <https://doi.org/10.1093/toxsci/kfx036>
13. Chen JR. Risk factors analysis and early prediction of bronchopulmonary dysplasia in premature infants. Shantou University. 2021. <https://doi.org/10.27295/d.cnki.gstou.2021.000482>
14. Costeloe KL, Hennessy EM, Haider S, Stacey F, Marlow N, Draper ES. Short term outcomes after extreme preterm birth in England: comparison of two birth cohorts in 1995 and 2006 (the EPICure studies). *BMJ.* 2012;345:e7976. <https://doi.org/10.1136/bmj.e7976>
15. Principi N, Di Pietro GM, Esposito S. Bronchopulmonary dysplasia: clinical aspects and preventive and therapeutic strategies. *J Transl Med.* 2018;16(1):36. <https://doi.org/10.1186/s12967-018-1417-7>
16. Voynow JA. "New" bronchopulmonary dysplasia and chronic lung disease. *Paediatr Respir Rev.* 2017;24:17-8. <https://doi.org/10.1016/j.prrv.2017.06.006>
17. Davidson LM, Berkelhamer SK. Bronchopulmonary dysplasia: chronic lung disease of infancy and long-term pulmonary outcomes. *J Clin Med.* 2017;6(1):4. <https://doi.org/10.3390/jcm6010004>
18. Alonso-Ojembarrena A, Lubián-López SP. Lung ultrasound score as early predictor of bronchopulmonary dysplasia in very low birth weight infants. *Pediatr Pulmonol.* 2019;54(9):1404-9. <https://doi.org/10.1002/ppul.24410>
19. Balany J, Bhandari V. Understanding the impact of infection, inflammation, and their persistence in the pathogenesis of bronchopulmonary dysplasia. *Front Med (Lausanne).* 2015;2:90. <https://doi.org/10.3389/fmed.2015.00090>
20. Liu J. Diagnosis of common neonatal lung diseases: the necessity and feasibility of ultrasound instead of X-ray. *China Pediatr Emerg Med.* 2019;26(8):565-70.

