



Revista da
ASSOCIAÇÃO MÉDICA BRASILEIRA

www.ramb.org.br



Review article

Assessment of fetal behavior using four-dimensional ultrasonography: current knowledge and perspectives☆

Hélio Antonio Guimarães Filho^a, Edward Araujo Júnior^{a,*},
Carlos Fernando de Mello Júnior^b, Luciano Marcondes Machado Nardoza^a,
Antonio Fernandes Moron^a

^aDepartment of Obstetrics, Universidade Federal de São Paulo, São Paulo, SP, Brazil

^bDiscipline of Radiology, Universidade Federal da Paraíba, João Pessoa, PB, Brazil

ARTICLE INFO

Article history:

Received 19 September 2012

Accepted 2 May 2013

Keywords:

Fetal behavior

Fetal awareness

Four-dimensional ultrasonography

A B S T R A C T

In the last decades, the development of real-time ultrasonography has allowed the direct view of the fetus in the uterus, as well as assessing its activity. The advent of three-dimensional ultrasonography (3D) at the end of the 80s initiated a new era in diagnostic imaging for Obstetrics, dramatically increasing the possibility of studying the fetus. Recently, a new technique allowing the 3D image to be transformed into real-time was introduced: the four-dimensional (4D) ultrasonography. It allows the continuous monitoring of fetal face and other surface areas, such as the extremities. Some studies have already assessed this new methodology for fetal behavior observation during different stages of pregnancy, trying to understand better the relationship between fetal central nervous system maturation and the implications for its behavior. In this article, the authors review the current use of 4D ultrasonography in the assessment of fetal behavior, and discuss the possibilities of the technique to show the neurological development of the fetus, by means of watching movement and facial expressions. They also highlight the potential applicability of this new method in this new research area of fetal medicine.

© 2012 Elsevier Editora Ltda. All rights reserved.

Avaliação do comportamento fetal por meio da ultrassonografia de quarta dimensão: conhecimento atual e perspectivas futuras

R E S U M O

Durante as últimas décadas, o desenvolvimento da ultrassonografia em tempo real tem possibilitado a visualização direta do feto no útero, bem como a avaliação de sua atividade. Com o advento da ultrassonografia tridimensional (3D) no final dos anos 1980, iniciou-se uma nova era no diagnóstico por imagem em Obstetrícia, ampliando-se sobremaneira a possibilidade do estudo fetal. Recentemente, uma técnica que permitiu que a imagem 3D

Palavras-chave:

Comportamento fetal

Consciência fetal

Ultrassonografia

de quarta dimensão

☆ Study conducted at the Department of Obstetrics, Universidade Federal de São Paulo, São Paulo, SP, Brazil.

* Corresponding author.

E-mail: araujojred@terra.com.br (E. Araujo Júnior).

fosse transformada em um modo em tempo real foi introduzida e tem sido chamada de ultrassonografia em quarta dimensão (4D), a qual permite o monitoramento contínuo da face fetal e de outras áreas da superfície do feto, como, por exemplo, suas extremidades. Alguns estudos já se ocuparam em avaliar esta nova metodologia na observação do comportamento fetal durante diferentes estágios da gestação, na tentativa de melhor entender as relações entre a maturação do sistema nervoso central do feto e suas implicações em seu padrão de comportamento. No presente artigo, os autores realizam uma revisão sobre o uso atual da ultrassonografia 4D na avaliação do comportamento fetal, discorrendo sobre as perspectivas da técnica em espelhar, por meio da observação de padrões de movimentos e expressões faciais, o desenvolvimento neurológico do feto, destacando as potenciais aplicabilidades dessa tecnologia como nova área de pesquisa em medicina fetal.

© 2012 Elsevier Editora Ltda. Todos os direitos reservados.

Introduction

Three-dimensional ultrasonography (3DUS) is one of the most recent technological advances in diagnostic medicine. It was initially introduced in 1989, though still with several limitations, only allowing static observation of the fetal surface.¹ With the digitalization of equipment, images started to be obtained much quicker and, by improving its resources, since 1998, the method has become popular, particularly in the area of Obstetrics and Gynecology.^{2,3}

A technique that allowed the three-dimensional image (3D) to be transformed in a real-time mode was recently introduced and has been called four-dimensional ultrasonography (4DUS). This new diagnostic tool allows the continuous monitoring of the fetal face and other areas of the fetal surface, such as his/her extremities, by obtaining sequential three-dimensional images.^{4,5} Such technological progress is enabling the emergence of new possibilities for the study of fetal behavior, such as, e.g., perception of complex facial movements that can be assessed as to its expression and duration.¹⁻⁵

Ultrasonographic studies have showed a fascinating diversity of fetal intrauterine activities. Analyses of the dynamics of fetal behavior compared to the assessment of its morphology are leading to the assumptions that the pattern of fetal behavior directly reflects the maturation and development processes of the central nervous system (CNS) of the fetus.^{4,6-9}

Formation of the central nervous system and development of fetal behavior

The complexity of the structural development of the CNS is reflected in the complexity of its sensory motor, cognitive, emotional, and behavioral development. The occurrence of the first spontaneous fetal movements between the 7th-8th post-conceptional week matches the formation of the first synapses and brain's electrical activity.⁶ The first reflex movements are strong and indicate a still very limited number of synapses in this stage. The hands show reflex activity around week 10, while the lower limbs start these

reflexes around week 14. Then the number of synapses significantly increases between weeks 13 and 15,⁷ provided that about 15 different fetal movements can be observed at week 15. A significant number of synapses can be seen preceding the cerebral cortex only at the end of this period, probably forming a substrate for the onset of the cortical electrical activity, observed at week 19. The influence of the supraspinal structures on fetal motor behavior during the period between weeks 17 and 20 was confirmed by studies in anencephalic fetuses.¹⁰ The spinothalamic tract is formed at week 20 and myelinated around week 29 of pregnancy, provided that the thalamic-cortical connections penetrate into the cortical plate between weeks 24-26. At week 29, the functional connection between the periphery and functioning cortex is established.^{6,7} However, some investigations indicate that facial reflexes in response to somatic stimulation, which could indicate emotional reaction to pain, are developed during early pregnancy.⁹ These reflexes seem to be coordinated by subcortical systems and probably reflect the development of these lower brain circuits.¹¹⁻¹³ According to Kurjak et al.,⁹ these facial reflexes to somatic stimulation began at week 7 and would be fully present at week 11. These facial reflexes would begin at week 7 due to the lateral curvature of the body, so that at week 11, in addition to this reflex, the fetus would also have general body movements, jolts, isolated movements of arms and legs, sucking, deglutition, hand on face, ante/retroflexion of the head, head rotation, breathing movement and stretching, mouth opening and yawning.

The number of spontaneous movements tends to increase until week 32, when it starts to decrease. This reduction is deemed a result of the brain maturation process, as well as a consequence of the physiological reduction in the amniotic fluid volume. Simultaneously to the reduction in the number of general movements, an increased number of facial movements may be observed, including opening/closing of jaw, swallowing, and chewing. This pattern is deemed a reflex of the normal development of the fetus' brain. The REM and non-REM sleep in human fetuses starts to appear at weeks 33 and 35, indicating that the connection of neurons in the cortical-thalamic area and in the brainstem starts to function in this period.¹⁰ Therefore, the fetal behavior pattern changes as the nervous system matures.^{6,7,11-13}

Description of the four-dimensional ultrasonography technique

The evaluation of fetal behavior through 4DUS may be performed from early stages of pregnancy to the last trimester. Therefore, we use a convex volumetric transducer for automatic scan, starting off with a regular fetal assessment through the two-dimensional mode. After establishing the region of interest (ROI) to be assessed, the 4D mode is activated and 3D live images are reconstructed based on the 2D images selected through an acquisition plan. In state-of-the-art 4DUS equipment, volumetric data quickly processed already enable us to calculate now more than 40 volumes per second, which provides the examination with a real-time effect. To visualize fetal movements, the transducer should be positioned as to capture a sagittal view of the fetal trunk, including the head, thorax and abdomen. The three-dimensional volume is automatically obtained this way. After the surface mode is selected (rendering), the 4D images are shown on the screen, and they may be videotaped during a variable period of observation. To observe facial expression, the transducer should be positioned so the image is obtained in a sagittal view of the fetal face, including forehead, nose and chin. This procedure enables the observation of movements and expressions of the fetal face. The assessment is based on the analysis of the following points of reference: forehead and eyebrow region; flexible nasal tissue and nasolabial fold; oral cavity and tongue; lower lip and chin; eyelids and eyes; mouth and its angles, and facial expression.¹⁻⁵

Patterns of fetal behavior evaluated through four-dimensional ultrasonography

An increased number of axosomatic and axodendritic synapses occur in two different phases of fetal development. The first phase occurs between weeks 8 and 10 and the second between weeks 12 and 15. This is directly correlated with the periods of differentiation of fetal movements and with the onset of the complex patterns of its activity. After 10 weeks, several types of head movements may be observed, provided that in this phase there are usually accidental contact of the hands with the face and mouth. Between weeks 10.5 and 12, the fetus starts to show breathing movements. With 11 weeks, three new patterns, namely opening of jaw, flexion of the head and stretching, and complex movements are added to the repertoire. Yawns occur a little later than the irregular jaw movements. These have the same pattern in children and adults and, therefore, are easily identifiable. In the first trimester, a tendency for an increased frequency of regular fetal movements can be observed with the increase in the gestational age.¹⁴

At the beginning of the second trimester (13-16 weeks), the 4DUS enables the visualization of all four extremities of the fetus, and also to recognize isolated hand movements. Five types of isolated hand movements may be recognized: hand to the head; hand to the chin; hand close to the chin; hand to the face; hand close to the face; hand to the eye and hand to

the ear (Fig. 1). During the course of pregnancy, however, the spontaneous fetal movements are influenced by many external factors, as, e.g., shot of corticosteroids for lung maturation, maternal emotional stress and smoking.¹⁵ Additionally, they may also change under pathological conditions, such as maternal diabetes and intrauterine growth restriction.^{16,17} On the other hand, the fetal facial activity and expression may be analyzed through observation of the following aspects: eye opening and closing, perceived by the movement of the eyelids; mouth movements, which consist of a series of rhythmic movements involving jaw and tongue; eyelid and mouth movements (blinking movement of the eyelids and jaw movement, simultaneously); yawning (slow, prolonged and wide jaw opening, followed by fast closing with simultaneous head retroflexion and, sometimes, hands up high); tongue expulsion; mouthing (pouting); smiling (draws angle of mouth laterally), and scowling (bilateral contraction of the eyebrows and mimic muscles between them).

Perspectives of the four-dimensional ultrasonography in the assessment of fetal behavior

Assessing the integrity of the fetal and neonatal CNS is a major challenge for the modern perinatal medicine. Although there were many efforts in order to achieve this objective, the direct assessment of the functional condition of the fetus CNS has not been possible up to now. However, with the advent of the 4DUS, the possibility to assess the intrauterine behavior pattern of the human fetus seems to have given its initial step. The 4DUS offers practical means to assess the neurological development, as well as to detect anatomic pathologies. The first studies of fetal behavior through 4DUS have evidenced that this method may help to better understand both motor and somatic development of the fetus, in addition to assess the complex facial activity and expressions, starting a new era as to the understanding of the fetal neurological status.¹⁸⁻²²

Kurjak et al.² tried to correlate the prenatal behavior pattern (facial expressions and hand movements) observed in the 4DUS with the postnatal pattern, in order to assess potential differences in the frequency of movements during early fetal and neonatal period. They observed a continuous behavior pattern during the fetal and neonatal period, especially with respect to the isolated movements of the eyes, mouth and eyelid opening, yawning, tongue expulsion, smiling, and hand to face movements. Authors suggest that observing not only the number, but also the quality of these fetal movements may enable the prediction of unfavorable intrauterine neurological conditions.

Another study aimed at observing different fetal face expressions and movements during a fetal behavior study through 4DUS, at the second and third trimesters of pregnancy, as a probable manifestation of fetal awareness. A tendency for an increased frequency of facial expressions as the gestational age increases was observed. The nature of each facial movement included the speed, range and strength of the movement combined with a complex perception of it, suggesting that observing the behavioral quality may be a good

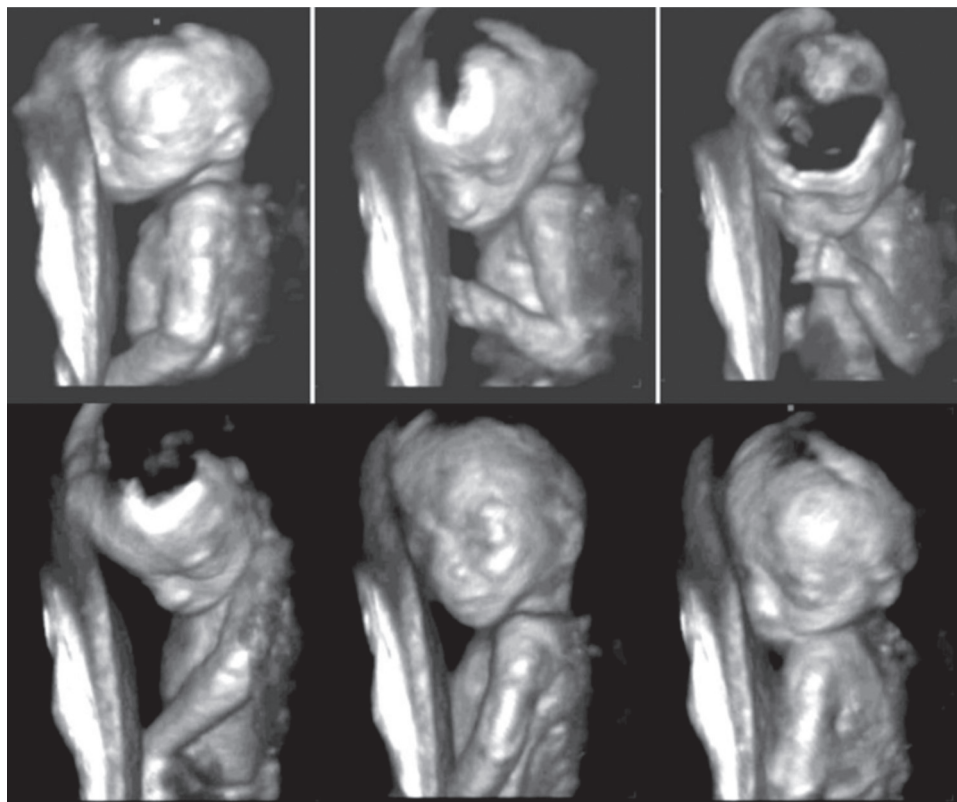


Fig. 1 – 4DUS of a 22-week pregnancy in which it is possible to observe a sequence of movements of the head (anteflexion), left upper limb (forearm flexion) and hand (hand to face movement).

predictor of neurological disability. According to these authors, different facial movements and expressions observed through 4DUS may indicate signs of fetal awareness.⁹

Several authors have been studying the effects of 4DUS on the maternal and paternal relationship with their fetus. Many parents see 2D images as abstract. With 3D/4D images, they recognize the fetus and his/her characteristics, being able to bond with him/her. Mothers even report greater emotional attachment to the fetus, increased motivation to go through certain difficulties related to the pregnancy, and reduced anxiety, providing a positive effect on the pregnancy. When questionnaires were applied, we found out that most patients reported positive aspects in 4DUS when compared to 2DUS, such as a stronger feeling of emotion, which makes the interpretation of images easier and reinforces the affective bond between mother and child.^{9,13,18,19}

In 2008, a multicenter study developed a scoring system (KANET test) to assess the fetal neurological status through 4DUS. This scoring system consists in the assessment of 10 fetal behavior parameters scored as 1, 2, or 3 according to the result of the analysis (Fig. 2). The new scoring system was retrospectively applied in a group of 100 low-risk pregnant women. After delivery, a postnatal neurological assessment was performed and all neonates assessed as normal reached a score between 14 and 20, which we assumed to be a score of optimal neurological development. Subsequently, the same scoring system was applied in a group of 120 high-risk pregnancies, in which, based on neonatal neurological findings,

three subgroups of newborns were found: normal, mildly or moderately abnormal, and abnormal. Normal neonates showed a prenatal score between 14 and 20; mildly or moderately abnormal neonates showed a prenatal score between 5 and 13; while the infants designated as neurologically abnormal showed a prenatal score between 0 and 5. The time of fetal assessment in all groups was 30 minutes. The study concluded that this new scoring system proposed to assess the fetal neurological status can help in the detection of changes in the fetal neural development in cases of in utero brain impairment²³ (Table 1).

In a recent study, the Croatian group assessed the fetal behavior of low and high-risk pregnancies through 4DUS by using the KANET test for comparison between the groups. We studied 116 high-risk pregnancies and 110 low-risk pregnancies. The newborns were assessed by the Amiel-Tison neurological assessment at term (ATNAT test), which is a test applied for neurological evaluation of term newborns. After delivery, the results of the KANET test were compared, in both groups, with the results of the ATNAT test. There was a statistically significant difference between the low and high-risk groups in 8 of 10 parameters of the KANET test: anteflexion of the head, eye blinking, facial expressions, mouth movements, hand movements, hands to face movement, fist and finger movements and general movements. There were no differences in the assessment of cranial sutures and leg movements. The comparison between the KANET and ATNAT tests showed statistical significance, with moderate correlation

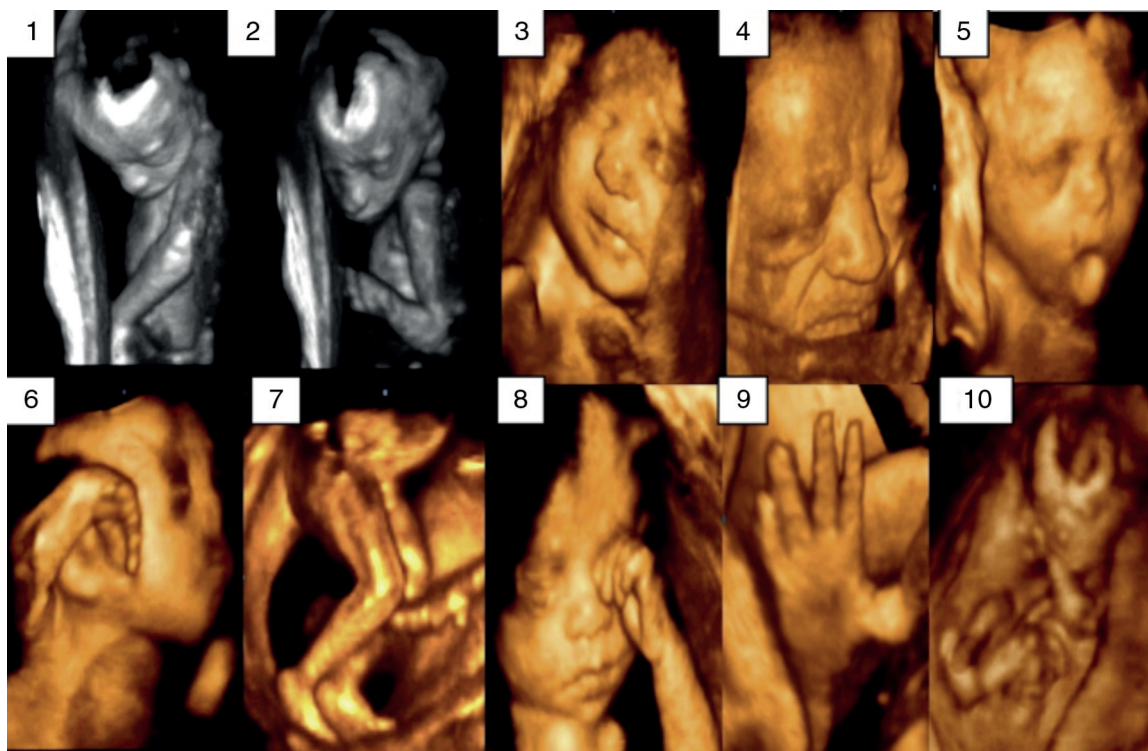


Fig. 2 – KANET test. Parameters of assessment by 4DUS: 1) anteflexion of the head; 2) sutures; 3) eye blinking; 4) facial expressions (grimace); 5) mouth opening; 6) hand movement; 7) leg movement; 8) hand to face movement; 9) finger movements; 10) general movements.

between both of them; which means that the pediatric neurology examination (ATNAT) mostly confirmed the findings from US4D prenatal (KANET). This study concluded that the

difference in fetal behavior between the low and high-risk groups was evident, and these preliminary results are quite promising. However, this draws attention to the fact that more

Table 1 – Neurological scoring system for fetuses through 4DUS (KANET test). Adapted from Kurjak, et al.²

Sign	Score			Sign score
	1	2	3	
Isolated anteflexion of the head	Abrupt	Small variation (0-3 movements)	Variable in the whole variation, many alternations (> 3 movements)	
Cranial sutures	Overlapping sutures	Normal sutures with CC below normal size (< 2 SD)	Normal cranial sutures with normal CC	
Eye blinking		Not frequent (0-5 times)	Frequent (> 5 times)	
Change in facial expressions (grimace or tongue expulsion)		Not frequent (0-5 times)	Frequent (> 5 times)	
Mouth opening (babbling and yawning)		Not frequent (0-3 times)	Frequent (> 3 times)	
Hand movements	Limited	Poor repertoire	Variable and complex	
Leg movements	Limited	Poor repertoire	Variable and complex	
Hand to face movement	Abrupt	Small variation (0-5 movements)	Variable in the whole variation, many alternations (> 6 movements)	
Finger movements	Clenched fist (neurological thumb)	Invariably limited movements	Smooth and complex, variable movements	
General perception of movements	Definitively abnormal	Uncertain	Normal	
				Total score

CC, cranial circumference; SD, standard deviation.

studies are necessary before the KANET test is recommended for use in clinical practice.²⁴

New results about the 4DUS potential when assessing fetal behavior in high-risk pregnancies were recently published. KANET test was applied to a large number of fetuses for one year. The objective of the study was to assess the behavior of a large sample of normal fetuses and fetuses from high-risk pregnancies for a comparative study between both groups. In this prospective cohort study, the KANET test was applied to 620 singleton pregnancies between weeks 26 and 38. The high-risk group included: threat of preterm birth with or without premature rupture of membranes, previous child with diagnosis of cerebral palsy, hypertension during pregnancy with or without preeclampsia, diabetes before pregnancy or gestational diabetes, intrauterine growth restriction, polyhydramnios, Rh alloimmunization, hemorrhaging, and maternal fever > 39 °C. A statistically significant difference was found between the fetuses in the low-risk group compared to some high-risk subgroups as to KANET scores. Among the fetuses with abnormal KANET score, one of the most frequent events was the group of fetuses with threat of preterm birth. Up to now, this was the study with the largest number of fetuses in which the test was applied.²⁵ This and other studies already demonstrated the test potential to detect and detail abnormal behavior of fetuses in normal conditions and in high-risk pregnancies.²⁶⁻²⁹

Conclusion

A better understanding of the relationship between the structural and functional development of the fetal brain may make the distinction between the normal and abnormal patterns of fetal behavior possible, in addition to enable early detection of brain dysfunctions during prenatal period. The possibility to assess motor activity and facial movement by 4DUS may expand our knowledge on the functional development of the CNS of fetuses, allowing for the assessment of its integrity in the future. Indeed, this new method for studying fetal behavior brought an important contribution to the understanding of functions that are still obscure as to the development of the fetal CNS, having a great potential for the investigation of intrauterine neurological deficits, which will certainly encourage future researches aiming at a better comprehension of the neurological development of fetuses.

Conflicts of interest

All the authors declare to have no conflicts of interest.

REFERENCES

1. Kurjak A, Carrera JM, Medic M, Azumendi G, Andonotopo W, Stanojevic M. The antenatal development of fetal behavioral patterns assessed by four-dimensional sonography. *J Matern Fetal Neonatal Med* 2005;17:401-16.
2. Kurjak A, Stanojevic M, Andonotopo W, Salihagic-Kadic A, Carrera JM, Azumendi G. Behavioral pattern continuity from

- prenatal to postnatal life – a study by four-dimensional (4D) ultrasonography. *J Perinat Med* 2004;32:346-53.
3. Hata T, Kanenishi K, Akiyama M, Tanaka H, Kimura K. Real-time 3-D sonographic observation of fetal facial expression. *J Obstet Gynaecol Res* 2005;31:337-40.
4. Andonotopo W, Medic M, Salihagic-Kadic A, Milenkovic D, Maiz N, Scazzocchio E. The assessment of fetal behavior in early pregnancy: comparison between 2D and 4D sonographic scanning. *J Perinat Med* 2005;33:406-14.
5. Visser GH, Laurini RN, dec Vries JI, Bekedam DJ, Pretchl HF. Abnormal motor behavior in anencephalic fetuses. *Early Human Dev* 1985;12:173-83.
6. Humphrey T. Some correlations between the appearance of human fetal reflexes and the development of the nervous system. *Prog Brain Res* 1964;4:93-135.
7. Kostovic I, Judas M, Petanjek Z, Simic G. Ontogenesis of goal-directed behavior: anatomo-funcional considerations. *Int J Psychophysiol* 1995;19:85-102.
8. Kurjak A, Azumendi G, Veccek N, Kupesic S, Solak M, Varga D, et al. Fetal hand movements and facial expression in normal pregnancy studied by four-dimensional sonography. *J Perinat Med* 2003;31:496-508.
9. Kurjak A, Stanojevic M, Andonotopo W, Scazzocchio-Duenas E, Azumendi G, Carrera JM. Fetal behavior assessed in all three trimesters of normal pregnancy by four-dimensional ultrasonography. *Croat Med J* 2005;46:772-80.
10. Andonotopo W, Kurjak A, Kosuta MI. Behavior of an anencephalic fetus studied by 4D sonography. *J Matern Fetal Neonatal Med* 2005;17:165-8.
11. Nijhuis JG. Fetal behavior. *Neurobiol Aging* 2003;24:1-6.
12. Sparling JW, Wilhelm IJ. Quantitative measurement of fetal movement: fetal-posture and movement assessment (F-PAM). *Phys Occup Ther Pediatr* 1993;12:97.
13. Kurjak A, Stanojevic M, Predojevic M, Laušin I, Salihagic-Kadic A. Neurobehavior in fetal life. *Semin Fetal Neonatal Med*. 2012; 17:319-23.
14. Salihagic-Kadic A, Kurjak A, Medic M, Andonotopo W, Azumendi G. New data about embryonic and fetal neurodevelopment and behavior obtained by 3D and 4D sonography. *J Perinat Med* 2005;33:478-90.
15. Relier JP. Influence of maternal stress on fetal behavior and brain development. *Biol Neonate* 2001;79:168-71.
16. Andonotopo W, Kurjak A. The assessment of fetal behavior of growth restricted fetuses by 4D sonography. *J Perinat Med* 2006;34:471-8.
17. Allen CL, Kisilevsky BS. Fetal behavior in diabetic and non-diabetic pregnant women: An exploratory study. *Dev Psychobiol* 1999;35:69-80.
18. Stanojevic M, Kurjak A, Salihagic-Kadic A, Vasilj O, Miskovic B, Shaddad AN, Ahmed B, et al. Neurobehavioral continuity from fetus to neonate. *J Perinat Med* 2011;39:171-7.
19. Kuno, A, Akiyama M, Yamashiro C, Tanaka H, Yanagihara T, Hata T. Three-dimensional sonographic assessment of fetal behavior in the early second trimester of pregnancy. *J Ultrasound Med* 2011;20:1271-5.
20. Amiel-Tison C, Gosselin J, Kurjak A. Neurosonography in the second half of fetal life: a neonatologist's point of view. *J Perinat Med* 2006;34:437-46.
21. Horimoto N, Koyanagi T, Satoh S, Yoshizato T, Nakano H. Fetal eye movement assessed with realtime ultrasonography: are there rapid and slow eye movements? *Am J Obstet Gynecol* 1989;163:1480-4.
22. Yigiter AB, Kavak ZN. Normal standards of fetal behavior assessed by four-dimensional sonography. *J Matern Fetal Neonatal Med* 2006;19:707-21.

23. Kurjak A, Miskovic B, Stanojevic M. New scoring system for fetal neurobehavior assessed by three- and four-dimensional sonography. *J Perinat Med* 2008;36:73-81.
24. Miskovici B, Vasilj O, Stanojevic M. The comparison of fetal behavior in high risk and normal pregnancies assessed by four dimensional ultrasound. *J Matern Fetal Neonatal Med* 2010;23:1461-7.
25. Kurjak A, Stanojevic M, Azumendi G, Carrera JM. The potential of four-dimensional (4D) ultrasonography in the assessment of fetal awareness. *J Perinat Med* 2005;33:46-53.
26. Abo-Yaqoub S, Kurjak A, Mohammed AB, Shadad A, Abdel-Maaboud M. The role of 4-D ultrasonography in prenatal assessment of fetal neurobehaviour and prediction of neurological outcome. *J Matern Fetal Neonatal Med* 2012;25:231-6.
27. Talic A, Kurjak A, Stanojevic M, Honemeyer U, Badreldeen A, DiRenzo GC. The assessment of fetal brain function in fetuses with ventrikulomegaly: the role of the KANET test. *J Matern Fetal Neonatal Med* 2012;25:1267-72.
28. Kurjak A, Talic A, Honemeyer U, Stanojevic M, Zalud I. Comparison between antenatal neurodevelopmental test and fetal Doppler in the assessment of fetal well being. *J Perinat Med*. 2013;41:107-14.
29. Warner J, Hains SM, Kisilevsky BS. An exploratory study of fetal behavior at 33 and 36 weeks gestational age in hypertensive women. *Dev Psychobiol* 2002;41:156-68.