

# Tuberculous peritonitis following intestinal perforation in malignancy

 Jiyoung Hwang<sup>1</sup>  
 Seong Sook Hong<sup>1</sup>  
 Hyun-joo Kim<sup>1</sup>  
 Yun-Woo Chang<sup>1</sup>  
 Bo Da Nam<sup>1</sup>  
 Eunsun Oh<sup>1</sup>  
 Eunji Lee<sup>1</sup>

**1.** Department of Radiology, Soonchunhyang University College of Medicine, Seoul Hospital, Seoul, Republic of Korea

<http://dx.doi.org/10.1590/1806-9282.64.05.408>

## SUMMARY

*Tuberculous peritonitis is one of the most common causes of exudative ascites, especially in the young, and is an important cause of extra-pulmonary disease. However, tuberculous peritonitis is challenging to diagnose because there are no pathognomonic clinical features or imaging findings. Therefore, it is commonly misdiagnosed as another type of peritoneal disease, especially so in elderly patients with malignant disease. In this report, we described two cases of tuberculous peritonitis that were observed after intestinal perforation in elderly patients with malignancies. These diagnoses were established by laparoscopic peritoneal biopsy or AFB cultures of the ascitic fluid. Both patients were treated with anti-TB medications.*

**KEYWORDS:** Peritonitis. Tuberculosis. Intestinal Perforation. Neoplasms. Multidetector Computed Tomography.

## INTRODUCTION

The peritoneum is a common site for tuberculosis involvement of the abdomen.<sup>1</sup> Tuberculous peritonitis accounts for 2% of all extrapulmonary infections.<sup>2</sup> This diagnosis, however, is difficult to reach in the absence of any pathognomonic clinical features or imaging findings. The radiologic features of tuberculous peritonitis can be easily confused with those of other peritoneal diseases, including peritoneal carcinomatosis, primary peritoneal mesothelioma, peritonitis, and rarely lymphoma.<sup>3-7</sup> Therefore, it is difficult to identify tuberculous peritonitis, especial-

ly in elderly patients with malignant disease and a recent history of intestinal perforation. In this study, we report two cases of tuberculous peritonitis that were observed after intestinal perforation in patients with malignancies.

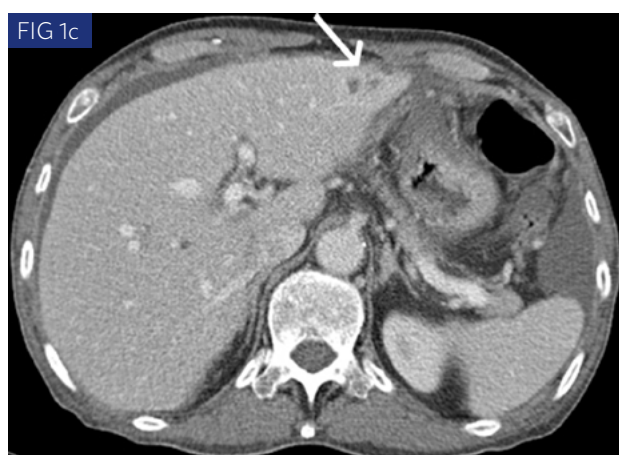
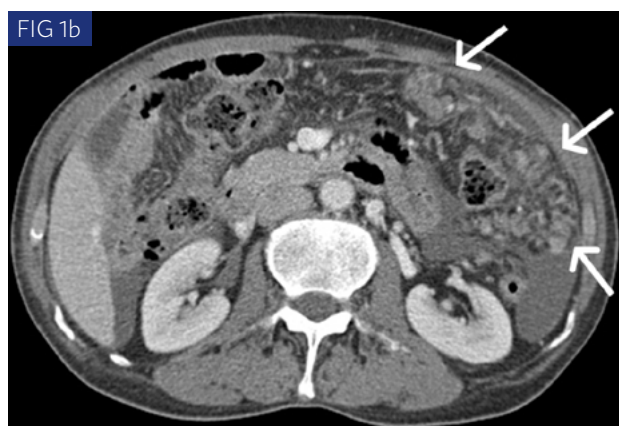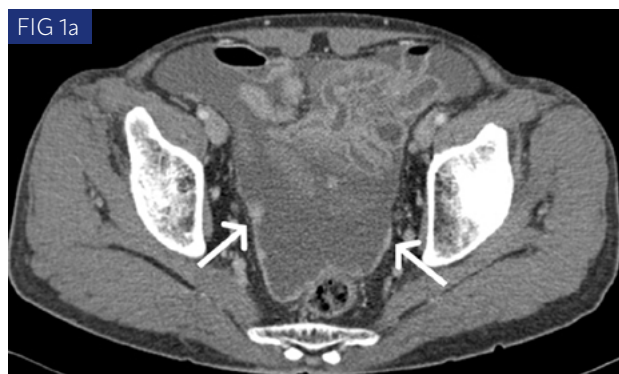## CASE REPORT

The first patient was a 66-year-old man was admitted for epigastric pain, poor oral intake, and a 6-kg weight loss over 2 months. He had under-

DATE OF SUBMISSION: 24-Jul-2017  
 DATE OF ACCEPTANCE: 05-Aug-2017  
 CORRESPONDING AUTHOR: Seong Sook Hong  
 59 Daesagwan-ro, Yongsan-gu  
 Seoul – 04408 – South Korea  
 E-mail: jy0707hwang@schmc.ac.kr

hongses@schmc.ac.kr  
 reonora@schmc.ac.kr  
 ywchang@schmc.ac.kr  
 namboda@schmc.ac.kr  
 sophiaoes@schmc.ac.kr  
 domain3923@schmc.ac.kr

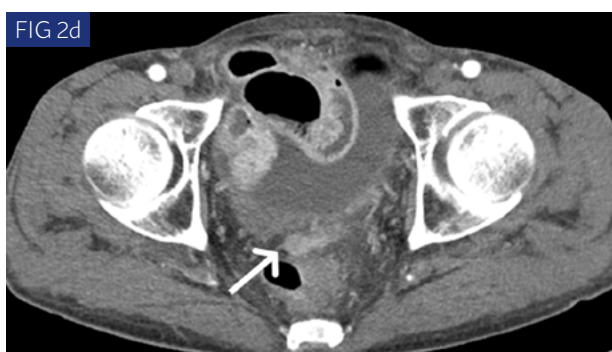
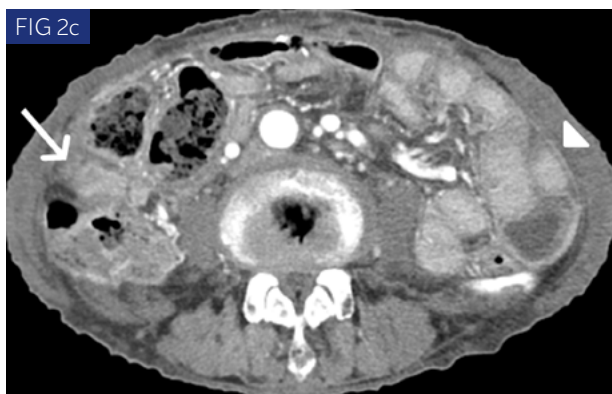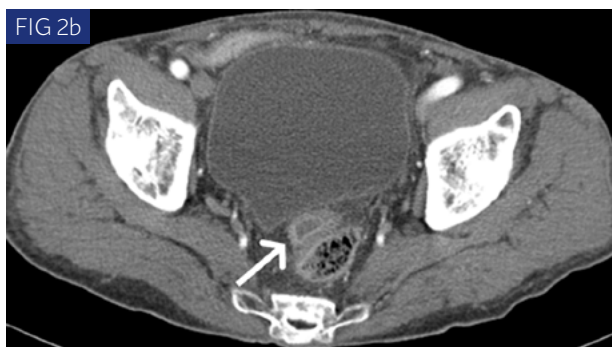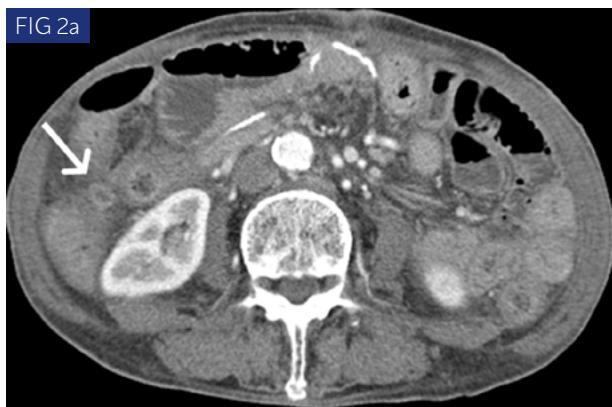gone endoscopic submucosal dissection (ESD) for pathologically-proven gastric cancer, 2 months prior to the presentation. The diagnosis was confirmed as early gastric cancer (pT1a according to



**FIGURE 1.** A 66-year-old man with tuberculous peritonitis. a-c. Contrast-enhanced abdominal CT images show a large volume of ascites with irregular and nodular thickening of the parietal peritoneum (arrows in a), enhancing nodules (arrows in b), soft tissue stranding in the omentum, and small low-attenuation lesions in the left lateral segment of the liver (arrow in c).

the American Joint Committee on Cancer staging system 8th edition). Subsequently, abdominal radiographs and contrast-enhanced abdominal CT revealed a localized perforation at the ESD site. The patient had a history of pulmonary tuberculosis 30 years prior to his current presentation. Laboratory findings were unremarkable, except for an elevated CRP of 6.49 mg/dl (normal, 0.0–0.5). Physical examination revealed no tenderness or rebound tenderness of the abdomen. Contrast-enhanced abdominal CT obtained 8 days after ESD showed segmental, layered wall thickening with a hemoclip at the greater curvature side of the gastric antrum. There was a small amount of associated extraluminal free air, fluid collection, and minute soft tissue stranding in the surrounding fat. Otherwise, there was no abnormal lymphadenopathy, free ascetic fluid or peritoneal thickening. Contrast-enhanced abdominal CT obtained 2 months later revealed a new large-volume ascites and irregular nodular thickening of the parietal peritoneum (Fig. 1a). Enhancing nodules and soft tissue stranding were also identified in the omentum (Fig. 1b). There were multiple low-attenuated nodules <1 cm in diameter in the left lateral segment of the liver (Fig. 1c). Extraluminal free air in the perigastric area had resolved. These findings were worrying and could indicate liver metastasis and peritoneal carcinomatosis. Therefore, an ultrasound-guided liver biopsy and paracentesis were performed. There were no malignant cells on the histopathological analysis. Both ascitic fluid culture, and staining for acid-fast bacilli (AFB) were negative. The adenosine deaminase (ADA) level was 90 units/L. Finally, a laparoscopic peritoneal biopsy was ultimately in the peritoneum and omentum. Intraoperative findings included multiple whitish nodules in the peritoneum, omental cake, and a large volume of ascites. The histopathological results revealed chronic granulomatous inflammation. The final diagnosis was confirmed to be tuberculous peritonitis. The patient was treated with anti-tuberculous medications for 9 months.

The second patient was a 76-year-old man who presented abdominal pain and poor oral intake. This patient had a surgical history of a pylorus-preserving pancreatoduodenectomy for distal bile duct cancer. He was also treated with hormone therapy for prostate cancer 8 years prior to presentation.



**FIGURE 2.** A 76-year-old man with tuberculous peritonitis. a, b. Contrast-enhanced abdominal CT images obtained 2 weeks after revision of the gastrojejunostomy for marginal ulcer perforation show a few small fluid collections confined within an enhancing rim in the abdomen and pelvis (arrows in a,b). c, d. Abdominal CT images obtained 6 weeks later demonstrate enhancing soft tissue lesions replacing the fluid collections (arrow in c, d) and a moderate amount of ascites with diffuse peritoneal thickening (arrowhead in c).

Two months prior to presentation, the patient underwent revision gastrojejunostomy for marginal ulcer perforation with panperitonitis. Physical examination revealed no tenderness or rebound tenderness of the abdomen. Laboratory findings on presentation were only remarkable for a mild elevation of CRP to 1.20 mg/dl (normal, 0.0 – 0.5), and anemia with a hemoglobin level of 10.0 g/dL (normal, 13-17) and hematocrit 31.2% (normal, 29-52). Tumor markers, including CA19-9 (7.75 U/mL; normal, 2-37), CEA (0.38 ng/mL; normal, 0-6.0) and PSA (0.01 ng/mL; normal 0-40) were within normal range. Contrast-enhanced abdominal CT obtained 2 weeks later (after revision of gastrojejunostomy for marginal ulcer perforation) showed a few small fluid collections confined within an enhancing rim in the abdomen and pelvis (Fig. 2a, b). A follow-up abdominal CT obtained 6 weeks later demonstrated a complex fluid collection, evidenced by an enhancing soft tissue lesion, with an interval increase in size (Fig. 2c, d). There was also a moderate amount of new ascites, diffuse thickening of the peritoneum, and nodules (Fig. 2c). Ultrasonography-guided biopsy of the peritoneal nodule and diagnostic paracentesis were performed. The tissue biopsy revealed a foreign body reaction to the suture material. There were no malignant cells on the tissue biopsy or ascitic fluid. The ADA level in the ascitic fluid was 40 units/L. The AFB culture of the ascitic fluid was positive for *Mycobacterium tuberculosis*. Thus, the patient was diagnosed with tuberculous peritonitis and treated with anti-tuberculous medications.

## DISCUSSION

Both of these patients had nonspecific and complicated presentations, which made it difficult to accurately diagnose tuberculous peritonitis. It was challenging to distinguish tuberculous peritonitis from other differential diagnoses, including peritoneal carcinomatosis, and other peritonitis. Most cases of tuberculous peritonitis result from the reactivation of long-latent foci of tuberculous infection in the peritoneum. Other mechanisms of pathogenesis include hematogenous spread from an adjacent, or distant active primary site. For instance, tuberculosis can spread in the blood from primary pulmonary lesions or directly from caseous abdominal lymph nodes, abscesses, intes-

tinal segments, or fallopian tubes.<sup>1, 8-10</sup> Neither of the two patients had active tuberculosis infection, although one had a remote history of pulmonary tuberculosis. Several known risk factors for TB include old age, male gender, previous anti-TB treatment, gastrectomy, and chemotherapy treatments for malignancy.<sup>11, 12</sup> There is an increased risk of TB incidence after chemotherapy in patients with a history of TB.<sup>11</sup> Therefore, we hypothesize that tuberculous peritonitis develops from the reactivation of long-latent foci of a tuberculous infection in patients with risk factors for tuberculosis. Interestingly, in our cases, tuberculous peritonitis was observed approximately 2 months after the intestinal perforation. There have been many reported cases in which there was intestinal perforation secondary to intestinal tuberculosis. There are also a few cases in which intestinal perforation was related to tuberculous peritonitis. However, to the best of our knowledge, tuberculous peritonitis that develops after intestinal perforation (without intestinal tuberculosis) has not been previously reported. In the cases presented here, the association of tuberculous peritonitis and intestinal perforation is uncertain. However, we hypothesize that the decreased immunity after an intestinal perforation with associated peritonitis could increase the risk of tuberculosis reactivation.<sup>11, 13</sup>

Tuberculous peritonitis is one of the most common causes of exudative ascites. It presents a variable amount of exudative ascites, soft-tissue infiltration, and thickening of the peritoneum, mesentery, and omentum. There also may be caseous lymph nodes. Relative characteristic features of tuberculous peritonitis include smooth thickening and strong contrast enhancement of the parietal peritoneum, soft-tissue infiltration of the mesenteric leaves, and a smudged or dirty appearance of the omentum. In contrast, nodular peritoneal thickening and a nodular or caked appearance are more suggestive of peritoneal carcinomatosis. However, these CT findings can overlap between the two diseases, it difficult to distinguish them.<sup>5-7, 14</sup> Peritoneal carcinomatosis is unusual in patients with EGC, despite its occurrence in our first case; however, nodular peritoneal thickening and a nodular or caked appearance on CT images made it more challenging to diagnose the tuberculous peritonitis.

There are no pathognomonic clinical features of tuberculous peritonitis. Abdominal swelling and malaise are the most frequent symptoms, while ascites is the most frequent sign at presentation.<sup>1, 8, 15</sup> Although the presence of thoracic tuberculosis may be suggestive of associated abdominal tuberculosis, only 15% of patients with abdominal TB have evidence of pulmonary disease.<sup>16</sup> Therefore, the differential diagnosis between tuberculous peritonitis and peritoneal carcinomatosis remains challenging, especially in elderly patients with malignancies because of their variable presentations and the limitations of available diagnostic tests. Therefore, one must have a high level of suspicion in patients with unexplained ascites and thickening of the peritoneum, mesentery, and omentum. This is particularly true in high-risk patients because the two diseases require entirely different treatment pathways and prognoses.

Definitive diagnosis of tuberculous peritonitis can only be made by identification of caseating granulomas, positive AFB, culture for *Mycobacterium tuberculosis*, or polymerase chain reaction. The rates of positive AFB and positive ascitic fluid culture vary significantly in different series. There is a relatively high rate of false-negative results.<sup>1, 17</sup> Although ADA activity in the ascitic fluid is a helpful marker of tuberculous peritonitis, it may be insufficient to distinguish tuberculous peritonitis from peritoneal carcinomatosis. Therefore, early diagnosis with tissue biopsy or laparoscopic exploration may be needed.<sup>1, 17, 18</sup>

In conclusion, there are no pathognomonic clinical features or imaging findings for tuberculous peritonitis. Therefore, one must have a high level of suspicion in patients with unexplained ascites and thickening of the peritoneum, mesentery, and omentum. The suspicion should be even greater for high-risk patients, since early diagnosis is critical for the appropriate management and improved of prognosis for patients with tuberculous peritonitis.

#### ACKNOWLEDGMENTS

This work was supported by the Soonchunhyang University Research Fund.

**PALAVRAS-CHAVE:** Peritonite. Tuberculose. Perfuração intestinal. Neoplasias. Tomografia computadorizada multidetectores.

## REFERENCES

1. Marshall JB. Tuberculosis of the gastrointestinal tract and peritoneum. *Am J Gastroenterol.* 1993;88(7):989-99.
2. Forssbohm M, Zwahlen M, Loddenkemper R, Rieder HL. Demographic characteristics of patients with extrapulmonary tuberculosis in Germany. *Eur Respir J.* 2008;31(1):99-105.
3. Dahlene DH Jr, Stanley RJ, Koehler RE, Shin MS, Tishler JM. Abdominal tuberculosis: CT findings. *J Comput Assist Tomogr.* 1984;8(3):443-5.
4. Bankier AA, Fleischmann D, Wiesmayr MN, Putz D, Kontrus M, Hübsch P, et al. Update: abdominal tuberculosis - unusual findings on CT. *Clin Radiol.* 1995;50(4):223-8.
5. Rodríguez E, Pombo F. Peritoneal tuberculosis versus peritoneal carcinomatosis: distinction based on CT findings. *J Comput Assist Tomogr.* 1996;20(2):269-72.
6. Ha HK, Jung JJ, Lee MS, Choi BG, Lee MG, Kim YH, et al. CT differentiation of tuberculous peritonitis and peritoneal carcinomatosis. *AJR Am J Roentgenol.* 1996;167(3):743-8.
7. Akhan O, Pringot J. Imaging of abdominal tuberculosis. *Eur Radiol.* 2002;12(2):312-23.
8. Bastani B, Shariatzadeh MR, Dehdashti F. Tuberculous peritonitis: report of 30 cases and review of the literature. *Q J Med.* 1985;56(221):549-57.
9. Singh MM, Bhargava AN, Jain KP. Tuberculous peritonitis. An evaluation of pathogenetic mechanisms, diagnostic procedures and therapeutic measures. *N Engl J Med.* 1969;281(20):1091-4.
10. Dineeen P, Homan WP, Grafe WR. Tuberculous peritonitis: 43 years' experience in diagnosis and treatment. *Ann Surg.* 1976;184(6):717-22.
11. Huang SF, Li CP, Feng JY, Chao Y, Su WJ. Increased risk of tuberculosis after gastrectomy and chemotherapy in gastric cancer: a 7-year cohort study. *Gastric Cancer.* 2011;14(3):257-65.
12. Kim HR, Hwang SS, Ro YK, Jeon CH, Ha DY, Park SJ, et al. Solid-organ malignancy as a risk factor for tuberculosis. *Respirology.* 2008;13(3):413-9.
13. Chandra RK. 1990 McCollum Award lecture. Nutrition and immunity: lessons from the past and new insights into the future. *Am J Clin Nutr.* 1991;53(5):1087-101.
14. Pereira JM, Madureira AJ, Vieira A, Ramos I. Abdominal tuberculosis: imaging features. *Eur J Radiol.* 2005;55(2):173-80.
15. Burack WR, Hollister RM. Tuberculous peritonitis. A study of forty-seven proved cases encountered by a general medical unit in twenty-five years. *Am J Med.* 1960;28:510-23.
16. Manohar A, Simjee AE, Haffeejee AA, Pettengell KE. Symptoms and investigative findings in 145 patients with tuberculous peritonitis diagnosed by peritoneoscopy and biopsy over a five year period. *Gut.* 1990;31(10):1130-2.
17. Hillebrand DJ, Runyon BA, Yasmineh WG, Rynders GP. Ascitic fluid adenosine deaminase insensitivity in detecting tuberculous peritonitis in the United States. *Hepatology.* 1996;24(6):1408-12.
18. Martinez-Vazquez JM, Ocaña I, Ribera E, Segura RM, Pascual C. Adenosine deaminase activity in the diagnosis of tuberculous peritonitis. *Gut.* 1986;27(9):1049-53.

