

Refractory celiac disease type 2: how to diagnose and treat?

Jonathan Soldera^{1*} , Karina Salgado² , Karla Lais Pêgas^{2,3} 

SUMMARY

Refractory celiac disease is an uncommon condition which might be associated to poor prognosis. It is often treated with immunosuppressive medications, with poor results. It is divided in type 1 and type 2, the latter carrying a high risk for lymphoma and mortality. A case of a 41 year old female patient with refractory celiac disease type 2 is reported. She was treated with oral budesonide for six months, achieving histological remission.

KEYWORDS: Celiac disease. Budesonide. Diet, gluten-free.

INTRODUCTION

Celiac disease (CD) is defined as an immune-mediated disease, which affects genetically predisposed individuals. The immune response is triggered by the ingestion of gluten, which is present in cereals such as wheat, rye, and barley. In countries with high proportion of European descendants, it is estimated to affect 1% of the population as its incidence and prevalence has been rising¹⁻³. Diagnosis of CD is made by an association of positive antibodies (generally, anti-transglutaminase for adults and anti-gliadin for children) and a duodenal biopsy demonstrating villous atrophy and an increase in intraepithelial lymphocytes (IELs) amount. The only treatment currently available is lifelong gluten-free diet (GFD), which normalizes antibodies and duodenal histology and improves symptoms¹⁻³. Steroids are generally reserved at presentation only for celiac crisis⁴.

Refractory celiac disease (RCD) is a severe and uncommon presentation of CD, occurring in <2% of celiac patients. It should be suspected in a patient who still has symptoms of malabsorption and villous atrophy on duodenal biopsies, even after at least 6 months of GFD¹. It is paramount to confirm

that GFD orientation is being strictly followed and to exclude malignancy and other causes of nonresponse to GFD.

The suspicion of RCD should prompt immunohistochemistry and/or flow cytometry of the duodenal biopsies, in order to stratify RCD into two types (Table 1). RCD type 1 is associated with normal CD3, CD4, and CD8 surface markers on lymphocytes, without clonal gene rearrangement of the gamma chain of the T-cell receptor (TCR). RCD type 2 is associated with aberrant clonal IELs that lack surface expression of CD3, CD4, and CD8 and is associated with TCR gamma gene rearrangement². RCD type 2 carries a higher risk for T-cell lymphoma and mortality, and it is treated with strict GFD and the use of immunosuppressive medications, although with poor results³.

The purpose of this study is to report a case of a female patient diagnosed with CD in an uncommon situation, during an investigation of chronic alteration of serum amylases. She was later diagnosed with RCD type 2 after 2 years of follow-up and went into remission with the use of oral budesonide, a novel treatment option for these cases.

¹Universidade de Caxias do Sul – Caxias do Sul (RS), Brazil.

²Universidade Federal de Ciências da Saúde de Porto Alegre – Porto Alegre (RS), Brazil.

³Irmandade Santa Casa de Misericórdia de Porto Alegre – Porto Alegre (RS), Brazil.

*Corresponding author: jonathansoldera@gmail.com

Conflicts of interest: the authors declare there are no conflicts of interest. Funding: none.

Received on October 15, 2020. Accepted on November 16, 2020.

DESCRIPTION

A female patient, 41 years old, previously healthy, sought care due to unspecific abdominal pain, weight loss, and elevation of pancreatic enzymes for more than 1 year. Workup had shown normal abdominal magnetic resonance imaging (MRI) and computerized tomography, serum amylase level at 276 U/L (reference=120 U/L), lipase values of 16 U/L, and a negative in parasitological stool examination test. Anti-transglutaminase IgA was 128 U/mL (reference=10 U/mL), and anti-gliadin IgA was 212 U/mL (reference=30 U/mL). She underwent upper digestive endoscopy, which showed duodenum with severe atrophy, with MARSH IIIb in biopsies. The patient was oriented to start following GFD and showed some improvement of symptoms and normalization of serum amylases.

After 2 years of strict GFD with a follow-up by an experienced dietitian, she still presented daily mild abdominal pain, anemia, and occasional watery diarrhea, with normalization of anti-transglutaminase IgA and anti-gliadin IgA. Abdominal MRI was normal. Upper digestive endoscopy showed atrophic duodenum with MARH IIIa in biopsies (Figure 1A). Immunohistochemistry was performed, showing positive CD3 in the IELs and positive CD8 in 50% or less of IELs stained

by CD3 (Figure 2). She was then diagnosed with RCD type 2. Her adherence to GFD was reviewed and confirmed again by another dietitian, and oral budesonide (OB) in the dose of 3 mg three times a day (Entocort®) was started, as stated in the study by Mukewar et al.: “Directions for taking OB were as follows:

1. first daily capsule: open the capsule, empty contents into applesauce and stir, grind the medicine between the teeth, rinse and swallow with a glass of water;
2. second daily capsule: open the capsule, empty contents into applesauce, stir, rinse and swallow with a glass of water;
3. third daily capsule: swallow the whole capsule”¹.

After 6 months of treatment with OB, upper digestive endoscopy showed recovery of duodenal atrophy (Figure 1B), with MARSH I on biopsies (Figure 3). She was successfully tapered off OB and remained asymptomatic on strict GFD after 2 years of follow-up.

DISCUSSION

In this case, summarized in Table 2, two important topics of CD are discussed: uncommon presentations, such as an unspecific

Table 1. Diagnostic findings for refractory celiac disease type 1 and 2 on duodenal biopsy immunochemistry or flow cytometry

RCD	Type 1	Type 2
IEL phenotype	IEL are CD3+/CD8+. CD3+/CD8- <40–50% by immunohistochemistry, and <20–25% by flow cytometry.	IEL mostly aberrant. IEL CD3+/CD8- >40–50% by immunohistochemistry, and >20–25% by flow cytometry.
TCR Gamma gene rearrangement polymerase chain reaction	Polyclonal TCR	Monoclonal TCR

RCD: refractory celiac disease; IEL: intra-epithelial lymphocyte; TCR: T-cell receptor.

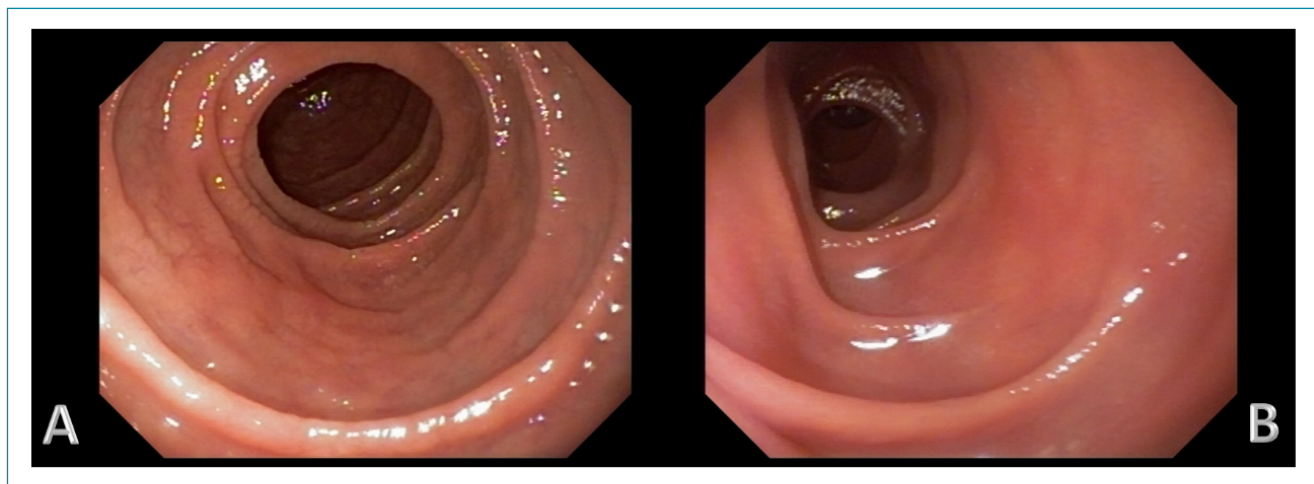


Figure 1. Upper digestive endoscopy (duodenum). (A) Duodenal atrophy and severe scalloping of duodenal folds; (B) Resolution of duodenal lesion.

abdominal pain associated with unspecific laboratory alterations, and RCD, which prevalence is bound to increase as CD prevalence continues to grow worldwide.

Most patients diagnosed with CD improve greatly with GFD, and complete clinical and histological response does not occur in every celiac patient. A small group of these patients will present persistent duodenal atrophy and recurrent symptoms (such as, anemia, diarrhea, abdominal pain, and weight loss), despite strict adherence to GFD^{1,2}. RCD is defined by persistent or recurrent symptoms associated with villous atrophy and increased IELs despite 6–12 months of strict confirmed GFD, after the exclusion of malignancy and other causes of lack or loss of response to GFD^{1,2}. Causes that should be considered in this step of differential diagnosis are: tropical sprue, autoimmune enteropathy, hypogammaglobulinemia, idiopathic AIDS enteropathy, eosinophilic gastroenteritis, Whipple disease, intestinal T-cell lymphoma, ulcerative jejunitis, collagenous sprue, giardiasis, other parasitic infections, and ischemic enteritis^{2,4,5}.

RCD is considered an uncommon condition, which might be related to a poor prognosis. In order to better stratify prognosis, it is divided into type 1 and type 2^{2,3,6}. It is sub-classified by the detection of abnormal IEL phenotype, which helps clarify prognosis. The current methods can be done in fixed (double CD3/CD8 immunohistochemistry and TCR clonal rearrangement by PCR) or on fresh frozen intestinal tissue (flow cytometry). The abnormal phenotype is supported by the loss of normal surface markers CD3, CD4, and CD8 with preserved expression of intracytoplasmic CD3 in more than 50% of IELs as evaluated by immunohistochemistry¹ or more than 20–25% as determined by flow cytometry and detection of TCR chains clonal rearrangement by PCR^{2,6}.

Abnormal IELs are the hallmark of RCD type 2, which is associated with poor prognosis because of a higher risk of progression to T-cell lymphoma^{1-3,5,6}. This was the major limitation

of the reported case: due to the unavailability of flow cytometry, diagnosis of RCD type 2 was made using immunohistochemistry, which is a method that can reveal dominant aberrant

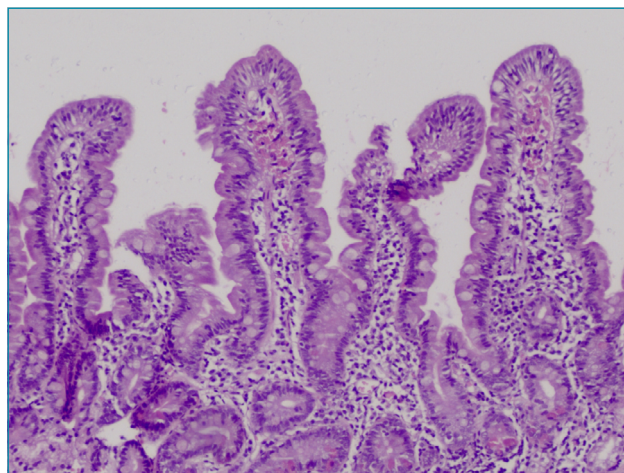


Figure 3. Duodenal biopsy (H.E, 100x). Recovery of the villous architecture, with discrete increase in IEL infiltrates (MARSH I).

Table 2. Summary of the reported case.

Clinical presentation	41 years old female patient. Abdominal pain. Elevation of serum amylases.
Diagnostic tests	Normal computed tomography. Celiac disease serology positive. Duodenal biopsy: MARSH IIIb.
Evolution	Persistent abdominal pain. Strict adherence to gluten-free diet. After 2 years of diagnosis: MARSH IIIa.
Final treatment	Immunohistochemistry: RCD type 2. Use of oral budesonide for 6-months. MARSH I at the end of treatment.

RCD: refractory celiac disease.

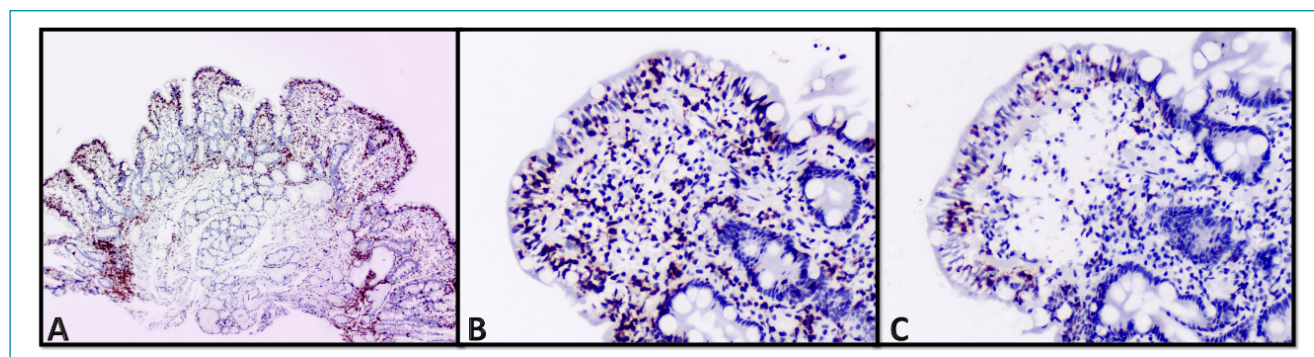


Figure 2. Duodenal biopsy and immunohistochemistry. (A) (anti-CD3 T lymphocytes, 100x): Villous with partial atrophy, fusion, and high number of IELs; (B) (anti-CD3 T Lymphocytes, 200x): Intraepithelial lymphocytosis (more than 30 lymphocytes/100 enterocytes); (C) (anti-CD8 T lymphocytes, 200x): Intraepithelial lymphocytosis in duodenal biopsy. The number of lymphocytes highlighted by antibody anti-CD8 is significantly lower than those stained with anti-CD3 (Figure 2A).

IEL populations only when they make up over 50% of IELs⁷. However, in patients with a moderate aberrant IEL population (between 20 and 50%), a significant number of patients will be undetected^{8,9}. The lack of sensitivity of immunohistochemistry can be largely explained by the inability of this method to distinguish between cell surface and intracellular expression of CD3, the latter being the hallmark of aberrant IELs, whereas flow cytometric analysis can differentiate cytoplasmic from membranous CD3 expression. Therefore, it is a superior method to identify patients at a higher risk for T-cell lymphoma, since it can better analyze TCR clonality⁵. Immunohistochemistry also has two major problems: it lacks specificity and an underlying disease can be inadequately classified as RCD type 2¹⁰; and it has a higher inter-observer variability¹¹. This lower sensitivity should be outweighed against the fact that this technique is easily applicable and readily available, whereas flow cytometric analysis of IELs requires fresh duodenal biopsies and skilled analysts¹¹.

CD is considered to be an uncommon cause of nonpancreatic elevation of amylases and lipases—this laboratorial finding is believed to occur in about 25% of celiac patients¹². In a study comprised of 54 celiac patients, most of the elevated values were lower than twofold the reference values. After 12 months of GFD, serum amylase level was elevated in three cases and lipases in two cases, and these patients had not strictly adhered to the GFD¹². It is reasonable, therefore, to screen patients with elevated serum amylases or lipases levels for CD, in the absence of signs of pancreatic disease.

Although GFD is being strictly followed by CD patients, mortality when compared to non-celiac controls is still higher, with a hazard ratio of 1.21. This higher risk of death is associated with cardiovascular disease, cancer, and respiratory disease¹³. This mortality increases even more in the presence of RCD. The 5-year survival rates described vary from 80% to 96% for RCD type 1 and 44% to 58% for RCD type 2¹⁴. Evolution to T-cell lymphoma in RCD type 2 generally occurs in patients with advanced age and if a late diagnosis of CD has been made. In this context, increased levels of lactate dehydrogenase and β -2-microglobulin might suggest that RCD has evolved to lymphoma, a life-threatening complication of RCD type 2¹⁵.

RCD is often treated with immunosuppressive medications. Prednisone (0.5–1 mg/kg/day) or a combination of

prednisone and azathioprine (2 mg/kg/day) are clinically effective for most patients with RCD type 1. Clinical response to steroids is observed in the majority of patients with RCD type 2. However, mucosal recovery is infrequent, and progression to T-cell lymphoma might not be totally preventable^{1,2,5,6}. Therefore, current immunosuppressive treatments for RCD type 2, such as azathioprine, achieve poor results and might increase the risk of T-cell lymphoma.

In a study developed at Mayo Clinic by Mukewar et al., 43 patients with RCD type 1 and 13 patients with RCD type 2 were enrolled. There were two deaths related to lymphoma: one patient with RCD type 1 and one with RCD type 2. All patients were treated with OB, with a response of 92% in both RCD type 1 and 2¹. It is expected a recovery of duodenal mucosa with treatment with OB in a 6-month interval, although some patients might not be tapered off the medication¹.

In another study, published by Therrien et al., 42 patients with non-responsive CD treated with budesonide 9 mg daily were showed an inferior result compared with the study by Mukewar et al. It was found that, within 1 year of therapy, 25% of patients had clinical and mucosal recovery and 17% had both persistent symptoms and mucosal damage¹⁶.

CONCLUSION

In conclusion, it is significant to screen celiac patients with persistent symptoms or villous atrophy for RCD. This screening should accompany an extensive review of the adherence to GFD. Afterwards, with the use of immunohistochemistry and/or flow cytometry, these patients should be stratified into RCD type 1 or type 2, with an objective of prognosticating the disease. If RCD type 2 is present, the physician should be aware of the higher risk of T-cell lymphoma. OB should then be considered as an effective treatment with a low rate of adverse effects.

AUTHORS' CONTRIBUTIONS

JS: Conceptualization, Writing – Original Draft, Writing – Review & Editing. **KS:** Data Curation, Writing – Original Draft, Writing – Review & Editing. **KLP:** Data Curation, Writing – Original Draft, Writing – Review & Editing.

REFERENCES

1. Mukewar SS, Sharma A, Rubio-Tapia A, Wu TT, Jabri B, Murray JA. Open-capsule budesonide for refractory celiac disease. *Am J Gastroenterol*. 2017;112(6):959-67. <https://doi.org/10.1038/ajg.2017.71>
2. Rubio-Tapia A, Murray JA. Classification and management of refractory coeliac disease. *Gut*. 2010;59(4):547-57. <https://doi.org/10.1136/gut.2009.195131>

3. West J. Celiac disease and its complications: a time traveller's perspective. *Gastroenterology*. 2009;136(1):32-4. <https://doi.org/10.1053/j.gastro.2008.11.026>
4. Soldera J, Coelho GP, Heinrich CF. Life-threatening diarrhea in an elderly patient. *Gastroenterology*. 2020;7:S0016-5085(20)35026-5. <https://doi.org/10.1053/j.gastro.2020.07.054>
5. Al-Toma A, Volta U, Auricchio R, Castillejo G, Sanders DS, Cellier C, et al. European Society for the Study of Coeliac Disease (ESsCD) guideline for coeliac disease and other gluten-related disorders. *United European Gastroenterol J*. 2019;7(5):583-613. <https://doi.org/10.1177/2050640619844125>
6. Malamut G, Afchain P, Verkarre V, Lecomte T, Amiot A, Damotte D, et al. Presentation and long-term follow-up of refractory celiac disease: comparison of type I with type II. *Gastroenterology*. 2009;136(1):81-90. <https://doi.org/10.1053/j.gastro.2008.09.069>
7. Serre NPM, Cellier C, Jabri B, Delabesse E, Verkarre V, Roche B, et al. Distinction between coeliac disease and refractory sprue: a simple immunohistochemical method. *Histopathology*. 2000;37(1):70-7. <https://doi.org/10.1046/j.1365-2559.2000.00926.x>
8. van Wanrooij RL, Schreurs MW, Bouma G, von Blomberg BM, Tack GJ, Verbeek WH, et al. Accurate classification of RCD requires flow cytometry. *Gut*. 2010;59(12):1732. <https://doi.org/10.1136/gut.2010.223438>
9. Liu H, Brais R, Lavergne-Slove A, Jeng Q, Payne K, Ye H, et al. Continual monitoring of intraepithelial lymphocyte immunophenotype and clonality is more important than snapshot analysis in the surveillance of refractory coeliac disease. *Gut*. 2010;59(4):452-60. <https://doi.org/10.1136/gut.2009.186007>
10. Malamut G, Meresse B, Cellier C, Cerf-Bensussan N. Refractory celiac disease: from bench to bedside. *Semin Immunopathol*. 2012;34(4):601-13. <https://doi.org/10.1007/s00281-012-0322-z>
11. van Wanrooij RL, Müller DM, Neefjes-Borst EA, Meijer J, Koudstaal LG, Heideman DA, et al. Optimal strategies to identify aberrant intra-epithelial lymphocytes in refractory coeliac disease. *J Clin Immunol*. 2014;34(7):828-35. <https://doi.org/10.1007/s10875-014-0075-7>
12. Carroccio A, Di Prima L, Scalici C, Soresi M, Cefalù AB, Noto D, et al. Unexplained elevated serum pancreatic enzymes: a reason to suspect celiac disease. *Clin Gastroenterol Hepatol*. 2006;4(4):455-9. <https://doi.org/10.1016/j.cgh.2005.12.027>
13. Lebwahl B, Green PHR, Söderling J, Roelstraete B, Ludvigsson JF. Association between celiac disease and mortality risk in a swedish population. *JAMA*. 2020;323(13):1277-85. <https://doi.org/10.1001/jama.2020.1943>
14. Nijeboer P, van Wanrooij R, van Gils T, Wierdsma NJ, Tack GJ, Witte BI, et al. Lymphoma development and survival in refractory coeliac disease type II: histological response as prognostic factor. *United European Gastroenterol J*. 2017;5(2):208-17. <https://doi.org/10.1177/2050640616646529>
15. Volta U, Caio G, De Giorgio R. Mistakes in refractory coeliac disease and how to avoid them. Vienna: UEG Education; 2019. [cited on Oct. 15, 2020]. Available from: <https://ueg.eu/a/149>
16. Therrien A, Silvester JA, Leonard MM, Leffler DA, Fasano A, Kelly CP. Enteric-release budesonide may be useful in the management of non-responsive celiac disease. *Dig Dis Sci*. 2021;66(6):1989-97. <https://doi.org/10.1007/s10620-020-06454-5>

