








# Image guidance for endoscopic sinus surgery: systematic review and meta-analysis

Maria Luísa Nobre<sup>1,2</sup> , Ayane Cristine Alves Sarmiento<sup>1</sup> , Henrique de Paula Bedaque<sup>2</sup> , Kleyton Santos Medeiros<sup>3</sup> , Ricardo Ney Cobucci<sup>4</sup> , José Diniz Júnior<sup>2</sup> , Ana Katherine Gonçalves<sup>1,5\*</sup> 

## INTRODUCTION

Chronic rhinosinusitis (CRS) is characterized by persistent symptomatic inflammation of the nasal and paranasal mucosa<sup>1,2</sup>. It affects 5–28% of the population and impacts patients' socio-economic conditions and quality of life. Healthcare costs are higher for rhinosinusitis than for peptic ulcers, asthma, and hay fever<sup>1-4</sup>.

The etiology of CRS involves bacterial superantigens, epithelial cell defects, biofilm formation, T-helper 1 and 2 inflammation, and tissue remodeling<sup>5-8</sup>. Endoscopic sinus surgery (ESS) has brought advances in the treatment of CRS<sup>8</sup>. Reducing inflammation and preventing remodeling of the mucosa by facilitating access to topical therapies are potential disease-modifying benefits of surgery<sup>1</sup>. However, it has the potential for complications due to its anatomical proximity with essential structures (skull base, orbit, internal carotid artery, and optic nerve)<sup>9</sup>.

The risk of injuries is higher in revision surgeries due to the removal of anatomical landmarks in previous procedures<sup>10-12</sup>. The complication rate of ESS is 0.5%, which can be considered low risk<sup>13,14</sup>. However, complications can result in serious repercussions<sup>13,15</sup>.

Intraoperative image-guided surgery (IGS) is a technology for confirming locations in anatomically challenging fields<sup>10</sup>. The tracking system allows for the real-time determination of the instrument's location related to anatomical landmarks<sup>2,16</sup>, which may allow surgeons to treat more of the patient's disease. If a more complete surgery is performed, the quality of life of patients may be improved, and revision rates may be reduced<sup>2,16</sup>.

There is a lack of scientific evidence to determine the indications and recommend the use of IGS in CRS<sup>17</sup>. This review aims to analyze trials that compare ESS with and without IGS.

## METHODS

The Preferred Reporting Items for Systematic Reviews and Meta-Analyses (PRISMA) guidelines were followed<sup>18,19</sup>. The protocol is registered with the International Prospective Register of Systematic Reviews (PROSPERO CRD42020214791) and published in *BMJ Open*<sup>20</sup>.

### Inclusion criteria

The inclusion criteria were the clinical trials that compared the outcomes of patients with CRS who underwent ESS with and without IGS.

### PICOT strategy

- Population/participants: Adults diagnosed with CRS.
- Intervention: ESS with image guidance.
- Comparator/control: ESS without image guidance.
- Outcomes: Complications, quality of life, operative time, and missed paranasal sinuses.
- Type of study: Clinical trials.

### Patient and public involvement

There was no patient or public involvement in the study planning or application process, or during the analysis or dissemination of the results.

### Search strategy

PubMed, Embase, Scopus, Web of Science, SciELO, Cochrane Central Register of Controlled Trials (CENTRAL), LILACS, and ClinicalTrials.gov were searched with no limitations to date or language. All electronic databases were searched on November 22, 2022.

<sup>1</sup>Universidade Federal do Rio Grande do Norte, Health Sciences Postgraduate Program – Natal (RN), Brazil.

<sup>2</sup>Universidade Federal do Rio Grande do Norte, Department of Surgery – Natal (RN), Brazil.

<sup>3</sup>Liga Norte Riograndense Contra o Câncer – Natal (RN), Brazil.

<sup>4</sup>Universidade Potiguar, Postgraduate Program in Biotechnology – Natal (RN), Brazil.

<sup>5</sup>Universidade Federal do Rio Grande do Norte, Department of Gynecology and Obstetrics – Natal (RN), Brazil.

\*Corresponding author: anakatherine\_ufrnet@yahoo.com.br

Conflicts of interest: the authors declare there is no conflicts of interest. Funding: none.

Received on May 26, 2023. Accepted on July 20, 2023.

## Data collection and analysis

The articles retrieved were imported to EndNote Web, and duplicates were removed. Two authors independently screened the results by title, abstract, and full text to determine inclusion criteria. A third reviewer resolved the discrepancies.

## Data extraction and management

Two independent authors extracted data from the included studies. The latter were inserted into a database. Meta-analysis was conducted on the outcomes that could be combined.

## Risk of bias assessment

The Cochrane Risk of Bias tool was used to evaluate the random sequence generation, allocation concealment, blinding of participants, blinding of the outcome assessment, incomplete outcome data, selective reporting, and other biases<sup>21</sup>.

## Assessment of heterogeneity

Heterogeneity was assessed using  $I^2$  statistics, in which <25% was considered to indicate low heterogeneity, between 25 and 50% moderate heterogeneity, and >50% high heterogeneity.

## Measures of the treatment effect

Operative time, as a continuous variable, was collected as means and standard error. The risk ratio was calculated for dichotomous data on complications and missed paranasal sinuses. This was performed using the Review Manager (RevMan, version 5.4) software.

## Analysis

RevMan 5.4 was used to perform the statistical analysis. In the heterogeneity assessment, when  $I^2$  was >50%, a random-effects model was used, whereas when  $I^2$  was <50%, a fixed-effect model was applied.

All included studies were qualitatively summarized in Table 1 for comparison.

## Grading quality of evidence

The Grading of Recommendations, Assessment, Development, and Evaluation (GRADE) approach was used to evaluate the strength of the evidence on the systematic review results<sup>22</sup>.

## RESULTS

A total of 3,281 articles were retrieved from databases and imported to EndNote Web (576 were duplicates). Two independent authors screened the 2,705 titles, and 193 of the titles were assessed for eligibility based on abstracts. After full-text

analysis, six studies were found to meet the inclusion criteria, of which five could be combined in the meta-analysis. The PRISMA flow diagram summarizes the study selection process (Figure 1). Qualitative synthesis is shown in Table 1.

## Quality of life assessment

Two studies assessed the quality of life of patients, using different instruments or measures; thus, the data could not be combined into a meta-analysis.

Javer et al. compared the quality of life of patients with CRS who underwent ESS with and without the aid of IGS using a validated quality of life tool RSOM-31. The patients completed the form preoperatively and 6 months postoperatively. The IGS demonstrated a statistically significant improvement in all the 31 questions, while the ESS group demonstrated a statistically significant improvement in 13 of the 31 questions<sup>23</sup>. This study had an uneven sample size (80 patients in the IGS group and 15 patients in the control group). Moreover, there were differences in the characteristics between the two groups before the intervention. The control group had 30% of the included patients with stage 4 of the disease on CT scan, compared to 76% of the intervention group. The latter reflects in the scores of the preoperative RSOM-31, which showed higher scores for the IGS group before surgery compared to the ESS group.

Strauss et al. evaluated the subjective findings of 300 patients who underwent ESS, 150 with IGS and 150 without IGS, 6 months postoperatively. The preoperative Lund-Mckay score was similar between the two groups. In the IGS group, 73% (65 out of 89) of the patients referred to a general sense of well-being compared to 69% (49 out of 71) in the ESS group. Persistent complaints were reported by 16% (14 out of 89) of the IGS and 30% (21 out of 71) of the ESS group. Moreover, 96% of patients who underwent the procedure with IGS stated that they would undergo surgery again compared to 85% of patients who were operated on without IGS<sup>24</sup>.

## Complications

The number of complications that occurred in each group from the studies was combined in a meta-analysis, as shown in Figure 2. There was a trend toward a lower risk of complications with the use of IGS, although it did not reach statistical significance (risk ratio (RR): 0.53; 95% confidence interval (CI), 0.20–1.41;  $p=0.20$ )<sup>25-27</sup>.

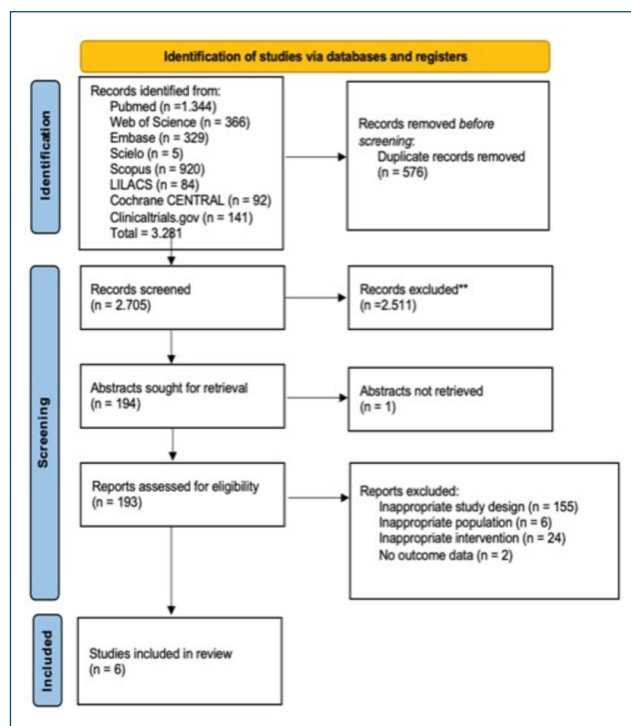
## Operative room time

Stelter et al. found that the operations lasted for an average of 16 min longer with the aid of IGS than with conventional

**Table 1.** Qualitative synthesis of the included studies.

Study	Population	n	Results	Conclusion
Javer and Genoway <sup>23</sup>	CRS	IGS: 80 ESS: 15	A significant improvement in quality of life was observed following IGS compared with ESS in the sub-groups of nasal symptoms, ear symptoms, general symptoms, and practical problems.	The improvement in overall quality of life six months post-ESS appeared to be further enhanced when computer assistance was added to endoscopic sinus surgery.
Jiang and Liang <sup>28</sup>	CRS (revision surgery)	IGS: 51 ESS: 30	IGS: 83 out of 91 sphenoid sinuses were successfully opened. ESS: 35 out of 51 sphenoid sinuses were successfully opened.	IGS was a beneficial procedure for opening the sphenoid sinus, especially in revision cases.
Lorenz et al. <sup>26</sup>	CRS	IGS: 35 ESS: 35	IGS: Two patients had complications. ESS: Six patients had complications.	The question, whether by using IGS a higher security can be reached with a lower complication rate, cannot be answered so far.
Singh et al. <sup>20</sup>	CRS	IGS: 30 ESS: 30	IGS: No complications. Operating room time: 165.68 (±6.55) ESS: One complication (orbital swelling) Operating room time: 163.33 (±5.43)	The additional time taken for device setup and registration was effectively overcome by the reduced intraoperative time. Complications did not differ significantly with or without IGS.
Stelter et al. <sup>27</sup>	CRS	IGS: 80 ESS: 77	IGS: Two missed paranasal sinuses/three complications ESS: Five missed paranasal sinuses/three complications.	Navigation should have an assured place in training and teaching for paranasal sinus operations. Even if this new technology means extra costs, it was welcomed by all study participants (surgeons and patients).
Strauss et al. <sup>24</sup>	CRS	IGS: 150 ESS: 150	Incision-suture time: 10.1 min less with IGS. Preparation time: 7 min more with IGS. Successful sinusotomy: IGS: 31/31   ESS: 9/40. Patient assessment: General feeling of well-being: 73% IGS/69% ESS; Minimal improvement, no improvement, or worsening 16% IGS/30% ESS; Would have the surgery again: 96% IGS/85% ESS.	The advantages of the examined navigation system compared to the gold standard of ESS are proven. Navigation assistance led to reduced intraoperative time, increased postoperative results, and lowered the workload of the surgeons.

CRS: chronic rhinosinusitis; IGS: image-guided surgery; ESS: endoscopic sinus surgery.

**Figure 1.** PRISMA flow diagram of the selection process.

ESS. Singh et al. documented a smaller difference: IGS group 165.68±6.55 (mean±SE); ESS group 163.33±5.43<sup>25,27</sup>.

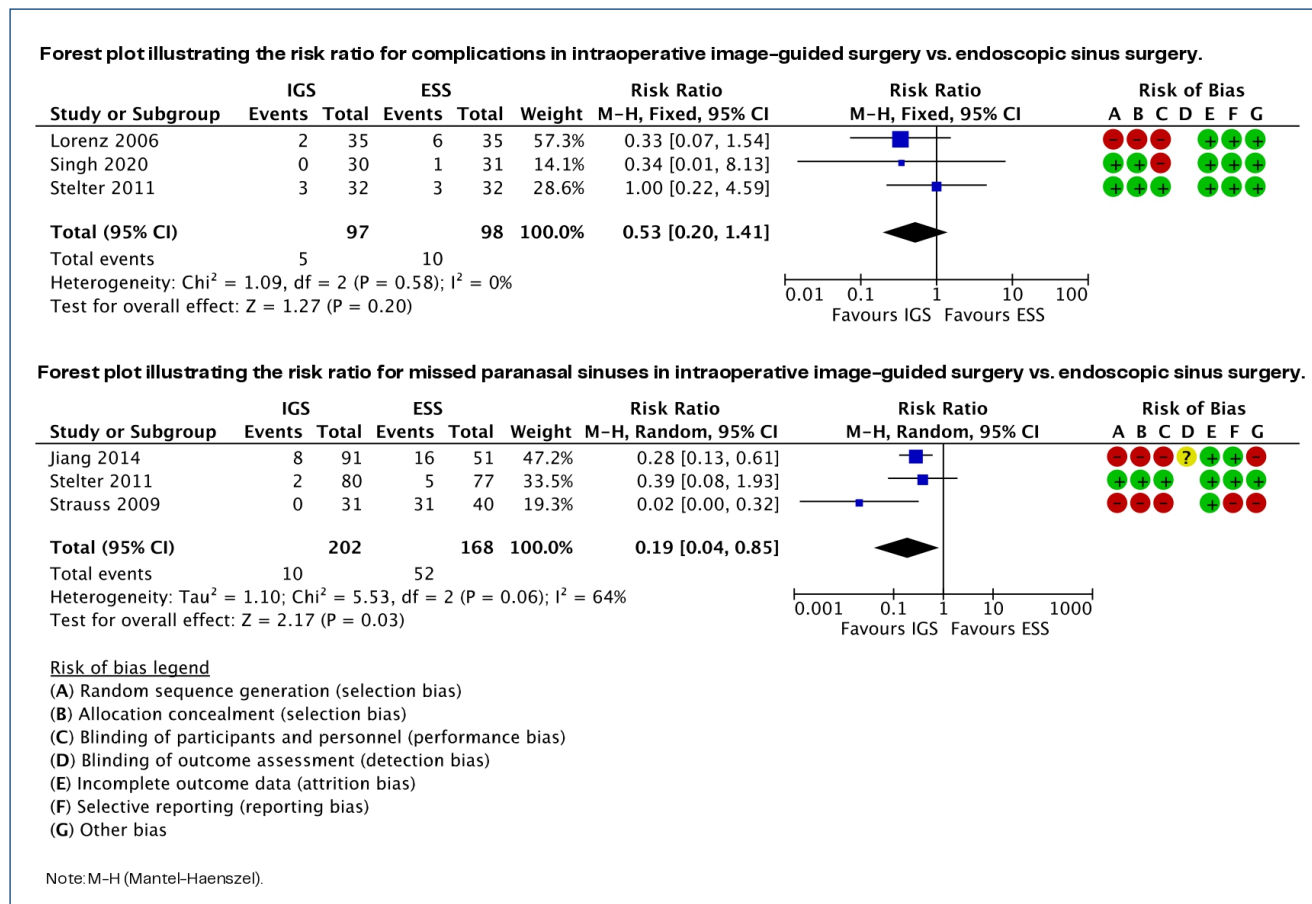
### Missed paranasal sinuses

Three of the included studies evaluated the number of diseased paranasal sinuses that should have been opened during surgery but were missed. These data were combined into a meta-analysis and are presented in Figure 2. Due to high heterogeneity, a random-effects model was used to estimate the RR. A statistically significant lower incidence of missed paranasal sinuses in the IGS group was demonstrated by the RR 0.19 [0.04, 0.085], 95%CI, p=0.03<sup>24,27,28</sup>.

### Risk of bias assessment

Only Singh et al. and Stelter et al. had a clear statement regarding the randomization and allocation processes. This raises concerns about the possibility of bias in the interpretation of the review results.

The strength of the evidence assessed by GRADE was low to moderate due to the small number of events, the risk of bias in the included studies, and the high heterogeneity among the studies.



**Figure 2.** (A) A forest plot illustrating the risk ratio for complications in intraoperative image-guided surgery vs. endoscopic sinus surgery. (B) A forest plot illustrating the risk ratio for missed paranasal sinuses in intraoperative image-guided surgery vs. endoscopic sinus surgery.

## DISCUSSION

The paranasal sinuses are anatomically close to vital and delicate structures, such as the skull base, orbit, internal carotid artery, and optic nerve. Broad and detailed anatomical knowledge is essential for surgeons to perform safe and effective procedures<sup>8</sup>.

Intraoperative imaging provides a greater operative domain. Undoubtedly, a thorough knowledge of anatomy is essential for nasal surgeons. Nevertheless, malformations, previous surgeries, and nasal polyposis can make orientation in the surgical field difficult, even for an experienced surgeon<sup>11</sup>.

Vreudenburg et al. and Dalgorf et al. found a reduction in the likelihood of total, major, and orbital complications in ESS with the use of IGS. They included case-control and cohort studies in their systematic reviews, while the current review did not. The small number of clinical trials on the subject was a limitation of our findings, hence the low incidence of complications in ESS<sup>15,29</sup>.

Tschopp et al. conducted a case-control study comparing ESS with and without image guidance and did not reach

statistical significance for the reduction of complications. However, they calculated the necessary sample size to achieve significant conclusions regarding the prevention of complications based on their complication rate. In their analysis, a sample size of at least 880 was necessary to draw reliable conclusions on the subject<sup>30</sup>.

Despite the limited number of studies that conducted quality of life assessments in patients with CRS who underwent ESS with and without IGS, the evidence suggests a greater improvement in the quality of life of patients operated on with navigation. Due to the heterogeneity of the outcome measures used in the literature, it is difficult to combine or compare data from different studies<sup>23,24</sup>.

One concern since the inception of IGS is that it would lead to an increase in operative time and therefore elevate procedure cost. Evidence from the literature suggests that IGS increases the preparation time, but it may lead to a reduction in the incision-to-suture time, thereby compensating for the overall operating room time<sup>25,27,30,31</sup>.

In addition to the possible decrease in the complication rate for ESS, the possibility of opening more of the diseased paranasal sinuses is an important question. This review provides evidence that IGS may be more effective than conventional ESS. To the best of our knowledge, this is the first study to present this evidence. Whether this may lead to better patient-reported outcome measures should be the subject of future research<sup>24,27,28</sup>.

The small number of high-quality studies with a low risk of bias is a limitation of this review. New clinical trials are important to better elucidate the role of image guidance in endoscopic surgery of the paranasal sinus.

## CONCLUSION

Image guidance is a valuable tool in ESS for patients with CRS. It provides the surgeon with important orientation information, increasing the efficacy of ESS in opening diseased

paranasal sinuses. Moreover, IGS may reduce complication rates and improve quality of life of patients. The findings of this review are limited by the bias of the primary studies included. More high-quality clinical trials are needed to confirm this evidence.

## AUTHORS' CONTRIBUTIONS

**MLN:** Conceptualization, Data curation, Formal Analysis, Investigation, Methodology, Project administration, Software, Visualization, Writing – original draft. **AKG:** Conceptualization, Project administration, Supervision, Writing – review & editing. **ACAS:** Conceptualization, Data curation, Investigation, Software, Visualization, Writing – original draft. **HPB:** Data curation, Formal Analysis. **KSM:** Formal Analysis, Methodology, Validation. **JDJ:** Project administration, Supervision, Writing – review & editing. **RNC:** Validation, Writing – review & editing.

## REFERENCES

- Fokkens WJ, Lund VJ, Hopkins C, Hellings PW, Kern R, Reitsma S, et al. European position paper on rhinosinusitis and nasal polyps 2020. *Rhinology*. 2020;58(Suppl S29):1-464. <https://doi.org/10.4193/Rhin20.600>
- Orlandi RR, Kingdom TT, Smith TL, Bleier B, DeConde A, Luong AU, et al. International consensus statement on allergy and rhinology: rhinosinusitis 2021. *Int Forum Allergy Rhinol*. 2021;11(3):213-739. <https://doi.org/10.1002/alr.22741>
- Chen Y, Dales R, Lin M. The epidemiology of chronic rhinosinusitis in Canadians. *Laryngoscope*. 2003;113(7):1199-205. <https://doi.org/10.1097/00005537-200307000-00016>
- Wahid NW, Smith R, Clark A, Salam M, Philpott CM. The socioeconomic cost of chronic rhinosinusitis study. *Rhinology*. 2020;58(2):112-25. <https://doi.org/10.4193/Rhin19.424>
- Rudmik L, Soler ZM. Medical Therapies for adult chronic sinusitis: a systematic review. *JAMA*. 2015;314(9):926-39. <https://doi.org/10.1001/jama.2015.7544>
- McCormick JP, Thompson HM, Cho DY, Woodworth BA, Grayson JW. Phenotypes in chronic rhinosinusitis. *Curr Allergy Asthma Rep*. 2020;20(7):20. <https://doi.org/10.1007/s11882-020-00916-6>
- Grayson JW, Hopkins C, Mori E, Senior B, Harvey RJ. Contemporary classification of chronic rhinosinusitis beyond polyps vs no polyps: a review. *JAMA Otolaryngol Head Neck Surg*. 2020;146(9):831-8. <https://doi.org/10.1001/jamaoto.2020.1453>
- Wormald PJ. Endoscopic sinus surgery. 4th ed. Thieme Medical Publishers, Inc.; 2018.
- Sharma BS, Ranwa A, Garg K. Complication avoidance in endonasal endoscopic pituitary surgery. *Neurol India*. 2020;68(Supplement):S85-91. <https://doi.org/10.4103/0028-3886.287665>
- Sedaghat AR. Chronic rhinosinusitis. *Am Fam Physician*. 2017;96(8):500-6. PMID: 29094889
- Alanin MC, Hopkins C. Effect of functional endoscopic sinus surgery on outcomes in chronic rhinosinusitis. *Curr Allergy Asthma Rep*. 2020;20(7):27. <https://doi.org/10.1007/s11882-020-00932-6>
- Ayoub N, Walgama E, Thamboo A, Chitsuthipakorn W, Patel ZM, Nayak JV, et al. Correlation between extent of sinus surgery, radiographic disease, and postoperative outcomes. *Rhinology*. 2020;58(1):36-44. <https://doi.org/10.4193/Rhin19.213>
- Krings JG, Kallogieri D, Wineland A, Nepple KG, Piccirillo JF, Getz AE. Complications of primary and revision functional endoscopic sinus surgery for chronic rhinosinusitis. *Laryngoscope*. 2014;124(4):838-45. <https://doi.org/10.1002/lary.24401>
- Koizumi M, Suzuki S, Matsui H, Fushimi K, Yamasoba T, Yasunaga H. Trends in complications after functional endoscopic sinus surgery in Japan: a comparison with a previous study (2007-2013vs. 2013-2017). *Auris Nasus Larynx*. 2020;47(5):814-9. <https://doi.org/10.1016/j.anl.2020.04.003>
- Vreugdenburg TD, Lambert RS, Atukorale YN, Cameron AL. Stereotactic anatomical localization in complex sinus surgery: a systematic review and meta-analysis. *Laryngoscope*. 2016;126(1):51-9. <https://doi.org/10.1002/lary.25323>
- Schmale IL, Vandelaar LJ, Luong AU, Citardi MJ, Yao WC. Image-guided surgery and intraoperative imaging in rhinology: clinical update and current state of the art. *Ear Nose Throat J*. 2021;100(10):NP475-86. <https://doi.org/10.1177/0145561320928202>
- Beswick DM, Ramakrishnan VR. The utility of image guidance in endoscopic sinus surgery: a narrative review. *JAMA Otolaryngol Head Neck Surg*. 2020;146(3):286-90. <https://doi.org/10.1001/jamaoto.2019.4161>
- Moher D, Shamseer L, Clarke M, Ghersi D, Liberati A, Petticrew M, et al. Preferred reporting items for systematic review and meta-analysis protocols (PRISMA-P) 2015 statement. *Syst Rev*. 2015;4(1):1. <https://doi.org/10.1186/2046-4053-4-1>
- Page MJ, McKenzie JE, Bossuyt PM, Boutron I, Hoffmann TC, Mulrow CD, et al. The PRISMA 2020 statement: an updated guideline for reporting systematic reviews. *BMJ*. 2021;372:n71. <https://doi.org/10.1136/bmj.n71>

20. Nobre ML, Sarmiento ACA, Nobre MG, Bedaque HP, Medeiros KS, Cobucci RN, et al. Image guidance for endoscopic sinus surgery in patients with chronic rhinosinusitis: a systematic review and meta-analysis protocol. *BMJ Open*. 2022;12(4):e053436. <https://doi.org/10.1136/bmjopen-2021-053436>
21. Higgins JPT, Thomas J, Chandler J, Cumpston M, Li T, Page MJ, Welch VA, editors. *Cochrane handbook for systematic reviews of interventions version 6.3 (updated February 2022)*. Cochrane; 2022. Available from: [www.training.cochrane.org/handbook](http://www.training.cochrane.org/handbook)
22. Guyatt GH, Oxman AD, Vist GE, Kunz R, Falck-Ytter Y, Alonso-Coello P, et al. GRADE: an emerging consensus on rating quality of evidence and strength of recommendations. *BMJ*. 2008;336(7650):924-6. <https://doi.org/10.1136/bmj.39489.470347.AD>
23. Javer AR, Genoway KA. Patient quality of life improvements with and without computer assistance in sinus surgery: outcomes study. *J Otolaryngol*. 2006;35(6):373-9. <https://doi.org/10.2310/7070.2006.0083>
24. Strauss G, Limpert E, Strauss M, Hofer M, Dittrich E, Nowatschin S, et al. [Evaluation of a daily used navigation system for FESS]. *Laryngorhinootologie*. 2009;88(12):776-81. <https://doi.org/10.1055/s-0029-1237352>
25. Singh A, Kumar R, Thakar A, Sharma SC, Bhalla AS. Role of image guided navigation in endoscopic surgery of paranasal sinuses: a comparative study. *Indian J Otolaryngol Head Neck Surg*. 2020;72(2):221-7. <https://doi.org/10.1007/s12070-019-01773-0>
26. Lorenz KJ, Frühwald S, Maier H. [The use of the BrainLAB Kolibri navigation system in endoscopic paranasal sinus surgery under local anaesthesia. An analysis of 35 cases]. *HNO*. 2006;54(11):851-60. <https://doi.org/10.1007/s00106-006-1386-7>
27. Stelter K, Ertl-Wagner B, Luz M, Muller S, Ledderose G, Siedek V, et al. Evaluation of an image-guided navigation system in the training of functional endoscopic sinus surgeons. A prospective, randomised clinical study. *Rhinology*. 2011;49(4):429-37. <https://doi.org/10.4193/Rhino11.035>
28. Jiang RS, Liang KL. Image-guided sphenoidotomy in revision functional endoscopic sinus surgery. *Allergy Rhinol (Providence)*. 2014;5(3):116-9. <https://doi.org/10.2500/ar.2014.5.0093>
29. Dalgorf DM, Sacks R, Wormald PJ, Naidoo Y, Panizza B, Uren B, et al. Image-guided surgery influences perioperative morbidity from endoscopic sinus surgery: a systematic review and meta-analysis. *Otolaryngol Head Neck Surg*. 2013;149(1):17-29. <https://doi.org/10.1177/0194599813488519>
30. Tschopp KP, Thomaser EG. Outcome of functional endonasal sinus surgery with and without CT-navigation. *Rhinology*. 2008;46(2):116-20. PMID: 18575012
31. Metson R, Cosenza M, Gliklich RE, Montgomery WW. The role of image-guidance systems for head and neck surgery. *Arch Otolaryngol Head Neck Surg*. 1999;125(10):1100-4. <https://doi.org/10.1001/archotol.125.10.1100>

