







# Pathological fracture after radiotherapy: systematic review of literature

 Cláudio Beling Gonçalves Soares<sup>1</sup>  
 Ivana Duval de Araújo<sup>2</sup>  
 Bruno Jannotti Pádua<sup>3</sup>  
 José Carlos Souza Vilela<sup>4</sup>  
 Rodrigo Henriques Reis Souza<sup>3</sup>  
 Luiz Eduardo Moreira Teixeira<sup>5</sup>

1. MD, Doctorate student on Surgery at the Faculty of Medicine, UFMG, Belo Horizonte, MG, Brasil

2. Ph.D., Department of Surgery, UFMG, Belo Horizonte, MG, Brasil

3. MD, Department of Orthopedics and Traumatology, Unimed-BH, Belo Horizonte, MG, Brasil

4. MSc, Department of Orthopedics and Traumatology, Unimed-BH, Doctorate Student on surgery at the Faculty of Medicine, UFMG, Belo Horizonte-MG, Brasil

5. Ph.D., Department of the Musculoskeletal System, UFMG, Belo Horizonte-MG, Brasil

<http://dx.doi.org/10.1590/1806-9282.65.6.902>

## SUMMARY

**OBJECTIVE:** To evaluate the epidemiological data and available treatments for fractures secondary to radiotherapy treatment.

**METHODS:** Identification of publications on pathological skeletal fractures previously exposed to ionizing radiation.

**RESULTS:** The incidence of fractures after irradiation varies from 1.2% to 25% with a consolidation rate of 33% to 75%, being more frequent in the ribs, pelvis, and femur. The time elapsed between irradiation and fracture occurs years after radiotherapy. Risk factors include age above 50 years, female gender, extensive periosteal detachment, circumferential irradiation, tumor size, and anterior thigh location. The etiology is still uncertain, but cellular disappearance, reduction of bone turnover and activity were observed hematopoietic as possible causes of failure of consolidation.

**CONCLUSION:** There is no consensus in the literature on the factors related to the development of fractures, with radiation dose, previous tumor size and periosteal detachment being suggested as potential factors.

**KEYWORDS:** Fractures, Spontaneous. Fracture Healing. Radiotherapy. Radiation Effects.

## INTRODUCTION

Radiotherapy is a therapeutic technique based on the use of ionizing radiation, commonly used in cancer treatments. It has been applied as adjuvant or isolated therapy for the local control of different types of cancer. Although it is an important therapeutic tool for oncology patients, radiotherapy is not exempt from adverse effects. Ionizing radiation also affects the healthy tissues of the body, which may lead to complications often difficult to solve. Specifically, in the skeletal tissue, it can lead to osteonecro-

sis, actinic osteitis, pathological fractures, failure of consolidation, and osteomyelitis<sup>1</sup>.

Pathologic fractures after the bone is exposed to ionizing radiation, although relatively infrequent<sup>2</sup>, have challenging treatment due to the high rate of complications, especially the failure in consolidation and infection, leading to disastrous functional results<sup>3</sup>.

The objective of this study is to critically and systematically review the literature available on this topic. The review will focus on epidemiological data,

DATE OF SUBMISSION: 13-Jan-2019

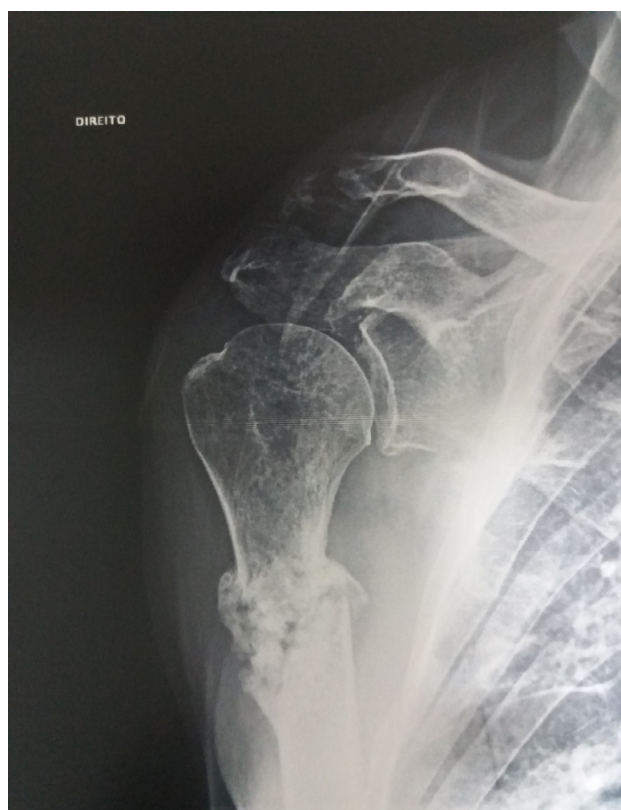DATE OF ACCEPTANCE: 09-Feb-2019

CORRESPONDING AUTHOR: Bruno Pádua

Av. do Contorno 3097 Santa Efigênia – Belo Horizonte, MG, Brasil – 30110-017

E-mail: med.jannotti@gmail.com

**FIGURE 1** - RADIOGRAPHIC IMAGING OF PATHOLOGICAL FRACTURE OF THE RIGHT PROXIMAL HUMERUS IN PATIENTS WITH UNDIFFERENTIATED PLEOMORPHIC SARCOMA AFTER TWO YEARS OF TREATMENT WITH RESECTION AND RADIOTHERAPY.



especially risk factors, as well as the treatments available for these fractures.

## METHODS

This systematic review was conducted by identifying publications about pathological fractures on skeletons previously exposed to ionizing radiation. We considered relevant randomized prospective clinical trials, meta-analyses, and systematic reviews of the literature. We considered less relevant studies with case series and case reports.

The search began by determining the keywords, after formulating the structured question. The keywords were determined based on the PubMed, Lilacs,

and SciELO databases. We included in this systematic review articles published in English, Spanish, and Portuguese. The relevant keywords identified are shown in Table 1.

After identifying the keywords, they were searched in the PubMed ([www.ncbi.nlm.nih.gov/pubmed](http://www.ncbi.nlm.nih.gov/pubmed)), Lilacs ([lilacs.bvsalud.org](http://lilacs.bvsalud.org)), and SciELO ([www.scielo.org](http://www.scielo.org)) databases. The results were classified hierarchically based on the relevance of the study. Finally, after retrieving the publications, the search was expanded with the use of the *related citations* and *see all* tools, inside the PubMed database. We also searched for publications in the Ovid Cochrane Database of Systematic Reviews and the Ovid Cochrane Database of Controlled Trials.

## RESULTS

We did not identify in the PubMed, Cochrane, LILACS, and SciELO databases relevant publications that include randomized prospective clinical trials, meta-analyses, and systematic reviews of the literature. All publications retrieved are of lesser importance, including case series and case reports.

We retrieved 38 publications in English, from the PubMed database, in humans<sup>4-25</sup>. We did not identify any publications on the subject in the Lilacs and SciELO platforms. Table 2 shows the number of articles retrieved for each combination of keywords.

These studies were ranked based on the number of patients included in the study. We also identified nine experimental studies performed on animals.

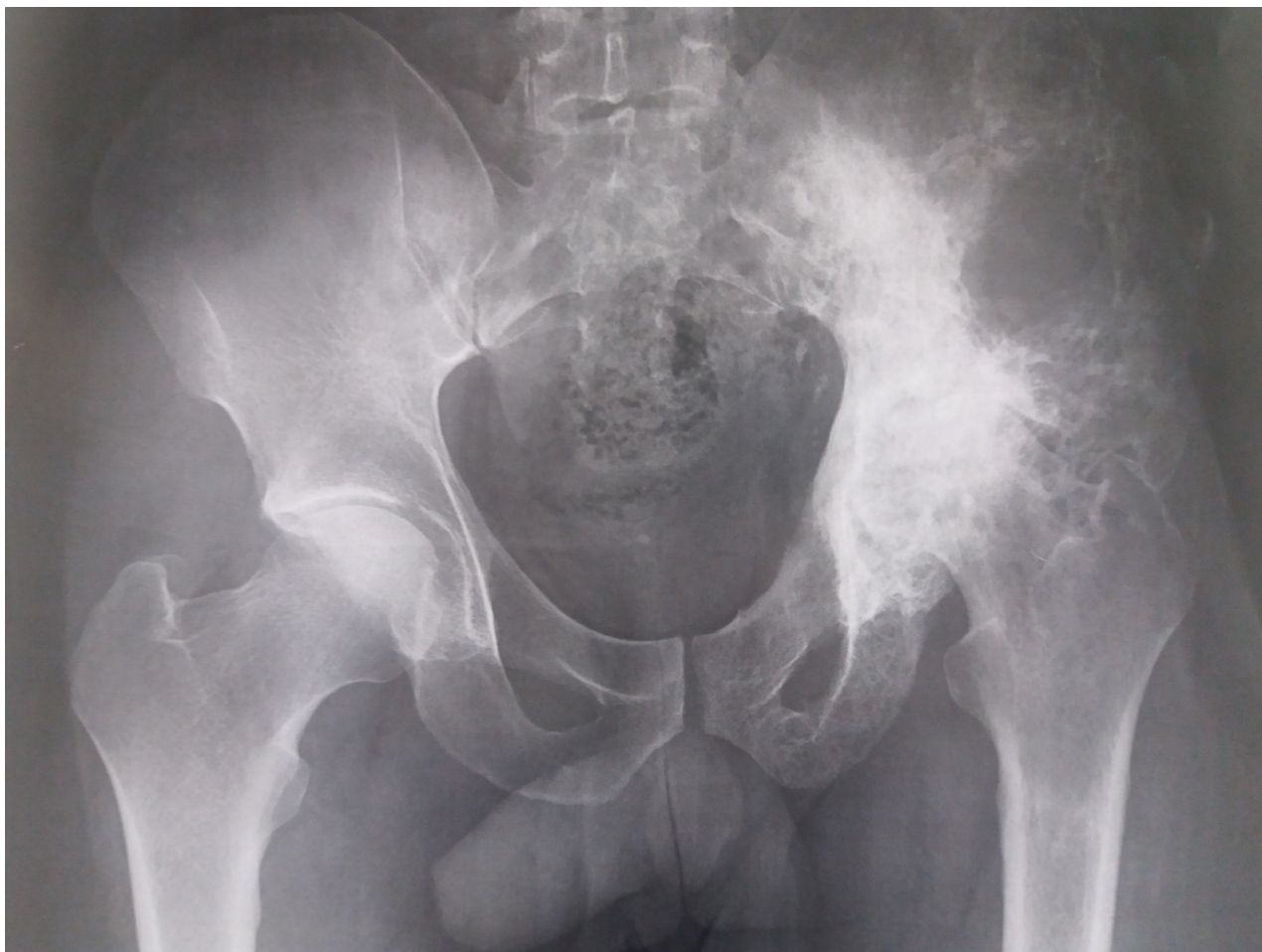## DISCUSSION

Radiotherapy, despite its important adjuvant effect in the treatment of cancer and even of some noncancerous lesions, is not devoid of complications. In the skeleton, its deleterious effect can lead to fractures, delay of consolidation, osteonecrosis, complications of the operative wound and, when performed on children, physeal growth disorders<sup>2</sup>.

**TABLE 1** - KEYWORDS IDENTIFIED IN PORTUGUESE, SPANISH, AND ENGLISH.

| Portuguese              | Spanish                 | English [MeSH Terms]   |
|-------------------------|-------------------------|------------------------|
| Fraturas espontâneas    | Fracturas Espontâneas   | Fractures, Spontaneous |
| Consolidação da fratura | Curación de Fractura    | Fracture Healing       |
| Radioterapia            | Radioterapia            | Radiotherapy           |
| Efeitos de radiação     | Efectos de la Radiación | Radiation Effects      |

**FIGURE 2** - RADIOGRAPHIC IMAGING OF ACTINIC OSTEONECROSIS IN THE LEFT HIP BONE OF A PATIENT AFTER RADIOTHERAPY.



### EPIDEMIOLOGY

The fractures, despite being relatively infrequent, have high rates of complications. The incidence of fractures after irradiation varies from 1.2% to 25%<sup>26-29</sup>. In most publications, the incidence is approximately 3%. However, fractures are difficult to treat.

The consolidation ratio ranges from 33% to 75%. When it evolves to a consolidation failure, a secondary infection is often present. Of these, 43% required amputation to resolve the complication.


The fractures can occur in any bone previously irra-

**TABLE 2** - FREQUENCY OF RELEVANT PUBLICATIONS FOR THE COMBINATION OF KEYWORDS OBTAINED FROM THE PUBMED DATABASE.

|                                |                           |             |
|--------------------------------|---------------------------|-------------|
| "Fracture Healing"[Mesh]       | "Radiation Effects"[Mesh] | 12 results  |
| "Fractures, Spontaneous"[Mesh] | "Radiation Effects"[Mesh] | 81 results  |
| "Fractures, Spontaneous"[Mesh] | "Radiotherapy"[Mesh]      | 163 results |
| "Fractura Healing"[Mesh]       | "Radiotherapy"[Mesh]      | 10 results  |

**TABLE 3** - FREQUENCY OF COMPLICATIONS FROM RADIOTHERAPY.

| Complication                         | Frequency   |
|--------------------------------------|-------------|
| Fractures                            | 1.2% to 25% |
| Delay of consolidation               | >45%        |
| Osteonecrosis                        | 15%         |
| Complications of the operative wound | 10% to 28%  |
| Physeal growth disorders             | 60%         |

**CHART 1** - FREQUENCY OF PUBLICATION AND INCLUSION IN THE STUDY**TABLE 4** - RISK FACTORS FOR PATHOLOGIC FRACTURES AFTER RADIOTHERAPY.

|  |
|--|
| Age over 50 years.                                 |
| Female gender.                                     |
| Location of the fracture: ribs, pelvis, and femur. |
| Tumor size: larger size, greater frequency.        |
| Periosteal detachment.                             |
| Circumferential femoral irradiation.               |

diated. They are more frequent in the ribs, in patients irradiated for treating breast cancer, on the pelvis, in patients treated for cancer in abdominal and pelvic organs<sup>11,30,31</sup> and in the femurs, and in patients treated for soft tissue sarcomas. Of these fractures, those that have a greater functional impact are the femoral ones, because they require surgical treatment and lead to greater mechanic repercussions.

Several studies seek to relate pathological fractures after radiotherapy and risk factors. After evaluating 89 patients with soft tissue sarcomas of the thigh treated with surgical resection and radiotherapy, Blaes et al.<sup>1</sup> identified as risk factors the periosteal detachment performed at the moment of the tumor resection, the circumferential irradiation of the femur, and tumors located in the anterior compartment of the thigh. Other factors such as age, gender,

radiation dose, association with chemotherapy, extension of the irradiation field, and histology showed no association with femoral fractures. An important aspect of the study was the follow-up time. The time elapsed between the irradiation and the fracture was very relevant since the fracture occurs many years after radiotherapy.

Gortzak et al.<sup>29</sup>, in a study with 22 patients who presented pathologic fracture of the femur from 101 patients treated using the association of surgery and radiotherapy for thigh sarcomas, identified as risk factors age, female gender, tumor location in the anterior compartment of the thigh, the tumor size, dose of radiation used and degree of periosteal detachment.

In their publication, which evaluated risk factors for pathologic fractures, Lin et al.<sup>27</sup> observed no relevance of the dose of radiation employed in the treatment to the occurrence of a fracture. The relevant factor observed in their study was the periosteal detachment during the surgical treatment. On the other hand, Holt et al.<sup>32</sup>, in spite of its small case series, found evidence that a high dose of radiotherapy, defined as between 60 and 66 Gy, was statistically more dangerous as a risk factor than a low dose, defined as 50 Gy.

Therefore, there is no consensus in the literature about which risk factors are really related to the fractures after radiotherapy treatments. Table 4 lists the risk factors observed with greater frequency in the largest series of cases published in the literature.

## ETIOLOGY

Some studies have tried to explain the reason why fractures in irradiated bones have greater consolidation difficulty. These studies are experimental and use animals, particularly rats.

In an experimental study after femoral exposure, radiotherapy at a dose of 18 Gy and fracture in rats, Nicholls et al.<sup>33</sup> observed the evolution toward consolidation failure when examining the femurs in micro-CT. The images showed an absence of callus formation, with a production deficiency of the osteoid and chondroid matrix. However, they did not evaluate the cellularity of the sample.

In a classical publication on the topic, Maeda et al.<sup>34</sup> demonstrated, in an experimental study in rats, the histological evolution of an irradiated bone, not fractured. Over the first two weeks, there is a disap-



pearance of bone cells, a reduction of bone turnover and of hematopoietic activity, without biomechanical repercussion. Between six and 18 weeks, histological changes are maintained, with a gradual increase in bone resorption, reduced cortical thickness, and increased bone porosity. After 18 weeks, they observed the gradual improvement of bone porosity and of the number of osteocytes, and increased periosteal bone formation, leading the bone tissue to the physiological state.

By evaluating the effectiveness of the use of amifostine for preventing the death of osteocytes in rat jaws irradiated and fractured, Donneys et al.<sup>35</sup> observed a decreased number of osteocytes in the fracture and increased gaps in the matrix. These findings demonstrate that the cell death of osteocytes at the site of irradiation where the fracture is located is greater than when the fracture occurs in non-irradiated bones. This same study showed an inability of the bone tissue to produce a new matrix after the fracture in a bone exposed to ionizing radiation.

Generally, we classify failures of consolidation as vascular and avascular. This differentiation indicates the presence or absence of biological stimulus to bone consolidation. The studies on the subject demonstrate the biological effect of ionizing radiation on normal bones, showing the death of osteocytes and the tissue inability to regenerate, perhaps due to cell deficiency at the fracture site. The scientific literature lacks data on vascularization of the fracture site in irradiated bone tissue, because the typical fracture is repopulated by cells from neovascularization, and this detail needs more in-depth studies.

## TREATMENT OF PATHOLOGIC FRACTURES AFTER RADIOTHERAPY

Some publications address the prevention of fractures after radiotherapy, especially in cases that include thigh tumors. In their study assessing risk factors for pathologic femoral fractures after treatments for thigh sarcomas, Gortzak et al.<sup>29</sup> suggest intramedullary nailing for patients who meet the criteria for risk of fracture.

In a publication with 22 patients victims of a pathologic fracture after radiotherapy, Sternheim et al.<sup>3</sup> demonstrated a high degree of failure after femoral intramedullary nailing. They reported 86% of complications, of which 82% were failures of consolidation. Of the 22 patients, five presented failure

of synthesis material after pseudoarthrosis and two had infected pseudoarthrosis.

Primary arthroplasty as a treatment for pathologic fractures after radiotherapy is defended for injuries on some specific locations. Kim et al.<sup>2</sup> published 36 patients with femoral fractures. Of these, 30 were diaphyseal fractures and 06 trochanteric fractures. Of the 36 fractures, 6 were treated with primary arthroplasty and 30 with osteosynthesis. The patients submitted to osteosynthesis had more complications and need for reoperation with greater frequency than those submitted to arthroplasty. The authors suggest further investigation of primary arthroplasty as a treatment for pathologic femoral fractures after radiotherapy.

In view of the high rate of complication of the treatment of fractures after radiotherapy, some authors suggest the introduction of factors that can collaborate with the consolidation. Duffy et al.<sup>36</sup> treated 17 patients with 18 femoral fractures after radiotherapy, with vascularized fibular graft associated with an autologous graft. They reported consolidation in 16 patients in an average time of 9.4 months. These results were not replicated in other studies<sup>2</sup>.

In an experimental study on rats, Nicholls et al.<sup>37</sup> assessed the effectiveness of the morphogenetic protein 7 (BMP7, OP-1) in the consolidation of fractures after radiotherapy. They did not observe the effectiveness of the protein in the consolidation of fractures.

In another study on rats, Donneys et al.<sup>35</sup> demonstrated that Amifostine is effective to prevent the death of osteocytes at the site of fracture of femurs exposed to ionizing radiation. This is a drug developed to prevent febrile neutropenia in patients undergoing chemotherapy treatment because it seems to have a cytoprotective activity. There are no studies proving its effectiveness in human bone tissue.

This systematic review could not determine a safe and effective therapeutic method for pathologic fractures secondary to radiotherapy.

## CONCLUSION

There are studies in the literature relevant to the topic. All publications relating to the subject consist of case reports and case series, or experimental trials on rats.

Due to the absence of relevant studies, there is

no consensus in the literature evaluated on factors related to the development of fractures. The dose of radiation, previous size of the tumor, and the periosteal detachment are suggested as potential factors.

The treatment is difficult and with high rates of non-consolidation.

**Conflict of interest:** The authors declare there are no conflicts of interest in the present

## RESUMO

**OBJETIVO:** Avaliar dados epidemiológicos e tratamentos disponíveis para fraturas secundárias ao tratamento radioterápico.

**MÉTODOS:** Identificação de publicações sobre as fraturas patológicas ocorridas em esqueleto previamente exposto à radiação ionizante.

**RESULTADOS:** A incidência de fraturas após irradiação varia de 1,2% a 25% com taxa de consolidação de 33% a 75%, sendo mais frequente em costelas, pelve e fêmur. O tempo decorrido entre a irradiação e a fratura ocorre anos após a radioterapia. Os fatores de risco incluem idade acima de 50 anos, sexo feminino, descolamento periosteal extenso, irradiação circunferencial, tamanho do tumor e localização anterior na coxa. A etiologia ainda é incerta, mas foram observados desaparecimento celular, redução do turnover ósseo e da atividade hematopoiética como possíveis causas da falha de consolidação.

**CONCLUSÃO:** Não há consenso na literatura avaliada sobre os fatores relacionados ao desenvolvimento de fraturas, sendo a dose de radiação, o tamanho prévio do tumor e o descolamento periosteal sugeridos como fatores potenciais.

**PALAVRAS-CHAVE:** Fraturas espontâneas. Consolidação da fratura. Radioterapia. Efeitos de radiação.

## REFERENCES

- Blaes AH, Lindgren B, Mulrooney DA, Wilson L, Cho C. Pathologic femur fractures after limb-sparing treatment of soft-tissue sarcomas. *J Cancer Surviv.* 2010;4(4):399-404.
- Kim HJ, Healey JH, Morris CD, Boland PJ. Site-dependent replacement or internal fixation for post-radiation femur fractures after soft tissue sarcoma resection. *Clin Orthop Relat Res.* 2010;468(11):3035-40.
- Sternheim A, Saidi K, Lochab J, O'Donnell PW, Eward WC, Griffin A, et al. Internal fixation of radiation-induced pathological fractures of the femur has a high rate of failure. *Bone Joint J.* 2013;95-B(8):1144-8.
- Van Duyn EB, Werker PM, van der Werken C. Free vascularised fibula transplantation for treatment of a fractured femur after radiation therapy. *Injury.* 2001;32(1):82-6.
- Blomlie V, Rofstad EK, Talle K, Sundfjør K, Winderen M, Lien HH. Incidence of radiation-induced insufficiency fractures of the female pelvis: evaluation with MR imaging. *AJR Am J Roentgenol.* 1996;167(5):1205-10.
- Wei RL, Jung BC, Manzano W, Sehgal V, Klempner SJ, Lee SP, et al. Bone mineral density loss in thoracic and lumbar vertebrae following radiation for abdominal cancers. *Radiother Oncol.* 2016;118(3):430-6.
- Aoki M, Sato M, Hirose K, Akimoto H, Kawaguchi H, Hatayama Y, et al. Radiation-induced rib fracture after stereotactic body radiotherapy with a total dose of 54-56 Gy given in 9-7 fractions for patients with peripheral lung tumor: impact of maximum dose and fraction size. *Radiat Oncol.* 2015;10:99.
- Dhakal S, Chen J, McCance S, Rosier R, O'Keefe R, Constine LS. Bone density changes after radiation for extremity sarcomas: exploring the etiology of pathologic fractures. *Int J Radiat Oncol Biol Phys.* 2011;80(4):1158-63.
- Pellard S, Moss L, Boyce JM, Brown MJ. Diagnostic dilemma of an atraumatic clavicle fracture following radical treatment for laryngeal carcinoma. *J Laryngol Otol.* 2005;119(12):1013-4.
- Beşe NS, Özgüroğlu M, Kamberoğlu K, Karahasanoglu T, Ober A. Pentoxifylline in the treatment of radiation-related pelvic insufficiency fractures of bone. *Radiat Med.* 2003;21(5):223-7.
- Inoue Y, Miki C, Ojima E, Nomoto Y, Kusunoki M. Pelvic insufficiency fractures after preoperative radiotherapy for rectal carcinoma. *Int J Clin Oncol.* 2003;8(5):336-9.
- Huh SJ, Kim B, Kang MK, Lee JE, Lim DH, Park W, et al. Pelvic insufficiency fracture after pelvic irradiation in uterine cervix cancer. *Gynecol Oncol.* 2002;86(3):264-8.
- To EW, Pang PC, Tsang WS, Tsang WM. Pathologic fracture of clavicle after radiotherapy. *AJR Am J Roentgenol.* 2001;176(1):264-5.
- Nyaruba MM, Yamamoto I, Kimura H, Morita R. Bone fragility induced by X-ray irradiation in relation to cortical bone-mineral content. *Acta Radiol.* 1998;39(1):43-6.
- Mumber MP, Greven KM, Haygood TM. Pelvic insufficiency fractures associated with radiation atrophy: clinical recognition and diagnostic evaluation. *Skeletal Radiol.* 1997;26(2):94-9.
- Bliss P, Parsons CA, Blake PR. Incidence and possible aetiological factors in the development of pelvic insufficiency fractures following radical radiotherapy. *Br J Radiol.* 1996;69(822):548-54.
- Blomlie V, Lien HH, Iversen T, Winderen M, Tvera K. Radiation-induced insufficiency fractures of the sacrum: evaluation with MR imaging. *Radiology.* 1993;188(1):241-4.
- Wang EH, Sekyi-Otu A, O'Sullivan B, Bell RS. Management of long-term postirradiation periclavicular complications. *J Surg Oncol.* 1992;51(4):259-65.
- Barak S, Rosenblum I, Czerniak P, Arieli J. Treatment of osteoradionecrosis combined with pathologic fracture and osteomyelitis of the mandible with electromagnetic stimulation. *Int J Oral Maxillofac Surg.* 1988;17(4):253-6.
- Jones AR, Lachiewicz PF. Pathologic Malgaigne fracture following pelvic irradiation. A case report. *Clin Orthop Relat Res.* 1987;(221):226-30.
- Csuka M, Brewer BJ, Lynch KL, McCarty DJ. Osteonecrosis, fractures, and protrusion acetabuli secondary to x-irradiation therapy for prostatic carcinoma. *J Rheumatol.* 1987;14(1):165-70.
- Dalinka MK, Mazzeo VP Jr. Complications of radiation therapy. *Crit Rev Diagn Imaging.* 1985;23(3):235-67.
- Strauss M, Bushey MJ, Chung C, Baum S. Fracture of the clavicle following radical neck dissection and postoperative radiotherapy: a case report and review of the literature. *Laryngoscope.* 1982;92(11):1304-7.
- Sanders B, Adams D, Scaramella J. Advanced osteoradionecrosis of the mandible. *J Oral Med.* 1978;33(3):73-6.
- Sengupta S, Prathap K. Radiation necrosis of the humerus. A report of three cases. *Acta Radiol Ther Phys Biol.* 1973;12(4):313-20.
- Helmstedter CS, Goebel M, Zlotecki R, Scarborough MT. Pathologic fractures after surgery and radiation for soft tissue tumors. *Clin Orthop Relat Res.* 2001;(389):165-72.
- Lin PP, Schupak KD, Boland PJ, Brennan MF, Healey JH. Pathologic femoral fracture after periosteal excision and radiation for the treatment of soft tissue sarcoma. *Cancer.* 1998;82(12):2356-65.
- Hatano H, Morita T, Kobayashi H, Ito T, Segawa H, Saito M. Pathological fracture of the femur ten years after successful radiation therapy for metastatic breast cancer. *Breast Cancer.* 2004;11(3):313-7.

29. Gortzak Y, Lockwood GA, Mahendra A, Wang Y, Chung PW, Catton CN, et al. Prediction of pathologic fracture risk of the femur after combined modality treatment of soft tissue sarcoma of the thigh. *Cancer*. 2010;116(6):1553-9.
30. Oh D, Huh SJ, Nam H, Park W, Han Y, Lim DH, et al. Pelvic insufficiency fracture after pelvic radiotherapy for cervical cancer: analysis of risk factors. *Int J Radiat Oncol Biol Phys*, 2008;70(4):1183-8.
31. Ogino I, Okamoto N, Ono Y, Kitamura T, Nakayama H. Pelvic insufficiency fractures in postmenopausal woman with advanced cervical cancer treated by radiotherapy. *Radiother Oncol*. 2003;68(1):61-7.
32. Holt GE, Griffin AM, Pintilie M, Wunder JS, Catton C, O'Sullivan B, et al. Fractures following radiotherapy and limb-salvage surgery for lower extremity soft-tissue sarcomas. A comparison of high-dose and low-dose radiotherapy. *J Bone Joint Surg Am*. 2005;87(2):315-9.
33. Nicholls F, Janic K, Filomeno P, Willett T, Grynypas M, Ferguson P. Effects of radiation and surgery on healing of femoral fractures in a rat model. *J Orthop Res*. 2013;31(8):1323-31.
34. Maeda M, Bryant MH, Yamagata M, Li G, Earle JD, Chao EY. Effects of irradiation on cortical bone and their time-related changes. A biochemical and histomorphological study. *J Bone Joint Surg*. 1988;70(3):392-9.
35. Donneys A, Tchanque-Fossuo CN, Blough JT, Nelson NS, Deshpande SS, Buchman SR. Amifostine preserves osteocyte number and osteoid formation in fracture healing following radiotherapy. *J Oral Maxillofac Surg*. 2014;72(3):559-66.
36. Duffy GP, Wood MB, Rock MG, Sim FH. Vascularized free fibular transfer combined with autografting for the management of fracture nonunions associated with radiation therapy. *J Bone Joint Surg*. 2000;82(4):544-54.
37. Nicholls F, Ng AH, Hu S, Janic K, Fallis C, Willett T, et al. Can OP-1 stimulate union in a rat model of pathological fracture post treatment for soft tissue sarcoma? *J Orthop Res*. 2014;32(10):1252-63.

