








Atypical presentation of COVID-19 with multi-organ involvement in a pediatric patient

Paulo Ricardo Martins-Filho¹ , Carolina Santos Tavares¹ , Sheila Jaqueline Gomes dos Santos Oliveira^{1,2} , Patrícia Carla Nascimento dos Santos² , Marlon Brandam Brandão Rodrigues² , Victor Santana Santos³ , Débora Cristina Fontes Leite^{2*} 

Studies have shown that severe cases of COVID-19 are particularly rare in pediatric populations and deaths have been registered in less than 0.1% of infected children¹. However, there is emerging evidence of systemic inflammatory response in children with COVID-19 which may be associated with a high risk of unusual multi-organ involvement and unfavorable outcomes^{2,3}.

We described a case of a 6-year-old boy with COVID-19 who was admitted to a pediatric public hospital in Brazil presenting a 5-hour history of acute diarrhea as the first symptom of the disease. On admission, he was afebrile, and his vital signs were unremarkable. Findings on chest radiography were normal (Figure 1A), but laboratory investigation revealed lymphopenia, increased prothrombin time, hypernatremia, hyperkalemia, and metabolic acidosis.

During the first 24 hours of admission, the child progressed to respiratory distress and was admitted to the pediatric intensive care unit (PICU) requiring endotracheal intubation and mechanical ventilation. A nasal swab sample was collected and the result for SARS-CoV-2 testing using RT-PCR assay was positive. After PICU admission, the child presented fever (38.3°C), increased levels of aspartate transaminase (AST), elevated levels of blood urea nitrogen (BUN) and creatinine, high levels of C-reactive protein (CRP), hypernatremia, and hypokalemia. New chest radiography showed no signs of pneumonia (Figure 1B) and blood culture results were negative.

During the clinical course of the disease, the child remained with fever, lymphopenia, liver and kidney impairment, diarrhea, and electrolyte and acid-base imbalance. Moreover, 10 days after PICU admission, a neurological evaluation revealed somnolence, rapidly progressive bilateral limb weakness, generalized

hypotonia, hyporeflexia, and a diagnosis of Guillain-Barré syndrome (GBS) was suspected. However, an attempted lumbar puncture was unsuccessful. Transthoracic echocardiography showed normal cardiac anatomy and function (Figure 2). The treatment during the stay in the PICU included antibiotic therapy with meropenem and azithromycin, ivermectin, dexamethasone, red cell concentrates, and peritoneal dialysis due to renal insufficiency. On day 14 of hospitalization, the child died from cardiac arrest. Laboratory examination results are shown in Table 1.

Although most children have a favorable outcome after confirmed COVID-19 possibly due to limited expression of angiotensin-converting enzyme 2 (ACE2)⁴, it has been proposed that some cases can present a dysregulated immune response associated with the SARS-CoV-2 infection with multi-organ dysfunction even in the absence of significant respiratory involvement. Gastrointestinal symptoms and urinary complications have been reported⁵ and the development of acute kidney injury might be a crucial negative prognostic factor for survival¹. A “multisystem inflammatory syndrome in children” (MIS-C) has been emerged as a new and potentially life-threatening childhood condition associated with SARS-CoV-2 infection and has been characterized by the persistence of fever, severe illness necessitating hospitalization, the manifestation of signs or symptoms of multi-organ dysfunction, laboratory evidence of inflammation and lacking an alternative diagnosis^{2,6}. For these rare cases, it has been proposed the use of steroids and intravenous immunoglobulin, but further clinical trials are needed to implement evidence-based treatment protocols in MIS-C⁶.

¹Universidade Federal de Sergipe, Investigative Pathology Laboratory – Aracaju (SE), Brazil.

²Hospital e Maternidade Santa Isabel, Neonatal Intensive Care Unit – Aracaju (SE), Brazil.

³Universidade Federal de Alagoas, Centre for Epidemiology and Public Health – Arapiraca (AL), Brazil.

*Corresponding author: deboraleite2006@hotmail.com

Conflicts of interest: the authors declare there are no conflicts of interest. Funding: none.

Received on November 05, 2020. Accepted on January 09, 2021.

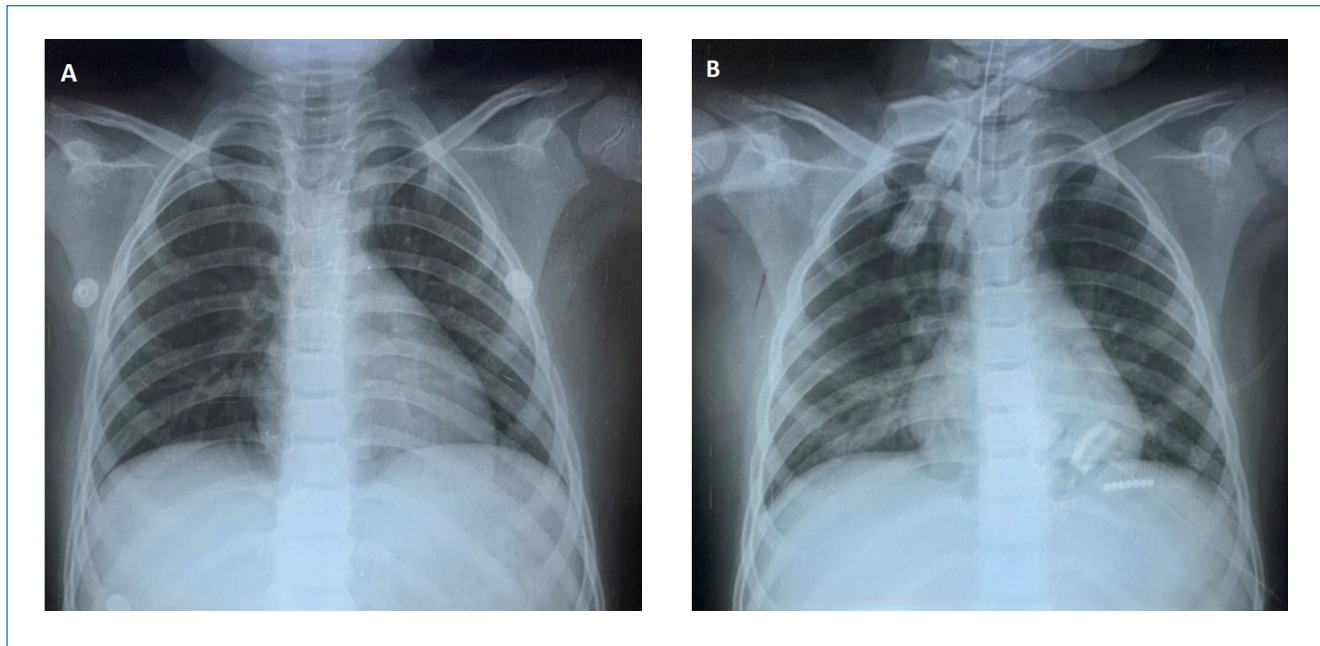


Figure 1. Chest radiographs. No radiological findings of pneumonia were present in the Day 0 (A) and Day 1 (B) of admission.

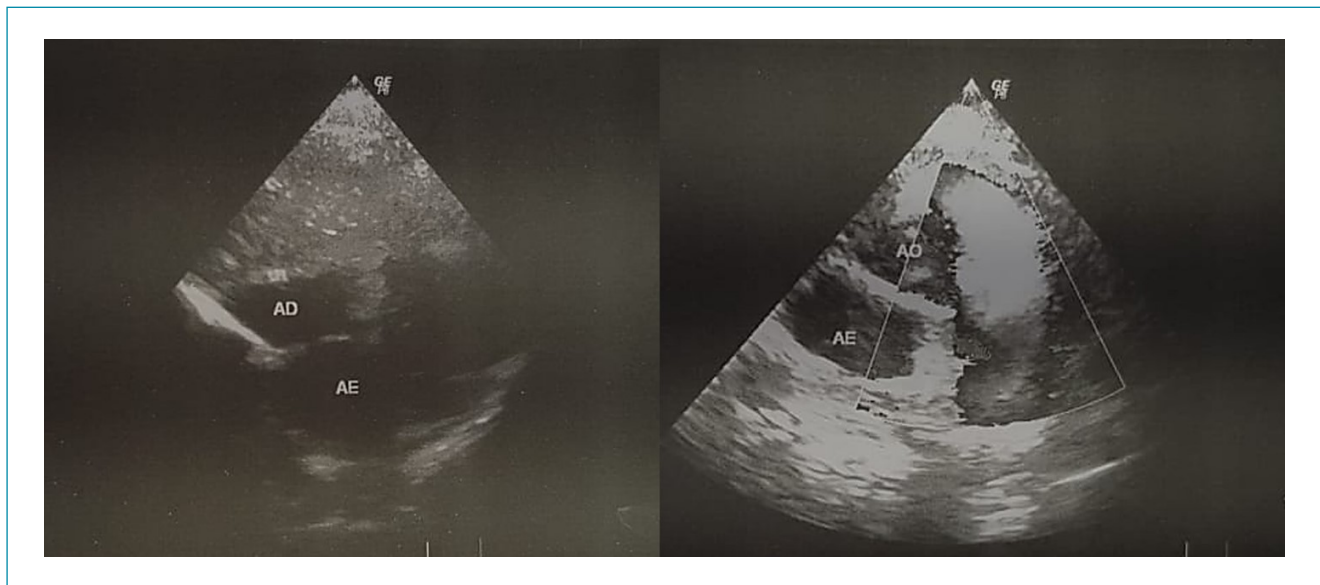


Figure 2. Transthoracic echocardiography. No cardiac morphology and function abnormalities were found previously to the cardiac arrest.

Although a causal association between SARS-CoV-2 infection and neurological symptoms is still unknown, some studies have reported GBS as a complication in adults with COVID-19^{7,8}. To date, no cases of GBS have been reported in children with COVID-19. In the present case, the hypothesis of GBS was sustained based on clinical criteria in the absence of alternative diagnosis for weakness and unavailable electrophysiological and cerebrospinal fluid (CSF) evaluation. There is emerging

evidence that preceded upper respiratory infection or enteritis increased the risk of GBS⁹. Pathogenesis of GBS has been associated with increased levels of IL-6 and TNF-alpha which can lead to demyelination and axonal damage⁹. Since SARS-CoV-2 infection is associated with an aberrant systemic inflammatory response, multi-organ complications that can also lead to respiratory failure such as GBS should be investigated during the clinical course of COVID-19.

Table 1. Laboratory findings during the clinical course of disease.

Parameter	Reference	Result							
		Day 0 ^a	Day 1 ^b	Day 3	Day 4	Day 7	Day 8	Day 10	Day 13
Hematological and coagulation function									
Hemoglobin, g/dL	11.5–14.5	14.1	10.6	10	8.7	16.7	12.3	11.7	10.5
Hematocrit (%)	33–43	41.2	31.4	29.3	25.6	38.1	NA	NA	32.8
WBC, 10 ³ cells/mm ³	4–15.5	15	5.4	3.3	4.5	7	11.6	16.3	3.5
Lymphocytes (%)	25–54	8.9	17	30	23	10	11	15	18
Platelet count, 10 ³ /mm ³	150–450	300	153	147	83	121	162	253	178
INR	0.9–1.2	1.6	NA	NA	NA	0.9	NA	1.5	NA
PT, seconds	8.7–11.5	19.1	NA	NA	NA	NA	NA	NA	NA
APTT, seconds	26–35	24	NA	NA	NA	NA	NA	NA	NA
Liver function tests									
AST, units/L	15–50	NA	78	94	89	NA	85	NA	NA
ALT, units/L	5–55	NA	10	20	32	NA	78	NA	NA
Albumin, g/dL	3.5–5.6	NA	NA	NA	1.9	NA	NA	NA	2.0
Kidney function tests									
Blood urea nitrogen, mg/dL	2–20	NA	92	93	109	130	147	140	52
Creatinine, mg/dL	0.3–0.7	NA	2.9	3.9	4.7	3.2	1.5	1.7	0.9
Inflammatory marker of myocardial injury									
cTnI	Negative	NA	NA	NA	Negative	NA	NA	NA	NA
Serum electrolytes									
Sodium, mEq/L	130–147	159	157	157	168	149	166	185	154
Potassium, mEq/L	3.5–5.1	7	2.2	3.8	2.9	2.6	2.8	6	3.1
Calcium, mEq/L	8.8–10.8	8.3	8.6	9.8	8.7	8.2	8.4	10.2	8.4
Infection-related indices									
CRP, mg/dL	<0.8	NA	96	48	NA	12	<0.8	<0.8	6
Blood gas analysis									
pH	7.35–7.45	7.09	7.38	7.12	7.08	7.38	7.36	7.22	7.41
PO ₂ , mmHg	70–108	77	156.4	98.3	95.1	108.8	85	82.1	72.9
PCO ₂ , mmHg	32–48	39.1	23.5	60.3	58.3	37.3	43	59.4	42
HCO ₃ ⁻ , mEq/L	19–28	11.6	16.4	16.5	14.4	22	23	20.6	25.5
Base excess, mEq/L	-2 – +2	-18.2	-11.5	-10.1	-13.1	-2.8	-1.2	-3.5	1.7
SatO ₂ (%)	90–95	91.2	99.2	94	98	97.4	95	92.6	93.2

^aFirst 24 hours of hospital admission. ^bPediatric intensive care unit admission. WBC: white blood cells; INR: international normalized ratio; PT: prothrombin time; APTT: activated partial thromboplastin time; AST: aspartate transaminase; ALT: alanine transaminase; cTnI: cardiac troponin I; CRP: C-reactive protein; PO₂: partial pressure of oxygen; PCO₂: partial pressure of carbon dioxide; HCO₃⁻: serum bicarbonate; SatO₂: oxygen saturation. NA, not evaluated. Values given in this table are commonly accepted reference ranges compiled from many sources.

This unusual case may provide additional data to better understanding the complexity of COVID-19 and to alert pediatricians who attend critically ill children with the disease.

Studies are urgently needed to better understand the clinical course of children with COVID-19, particularly of those with multi-organ involvement requiring intensive care.

AUTHORS' CONTRIBUTIONS

PRMF: Conceptualization, Writing – original draft. **CST:** Conceptualization. **SJGSO:** Conceptualization, Data curation, Formal Analysis. **PCNS:** Conceptualization, Data

curation, Formal Analysis. **MBBR:** Conceptualization, Data curation, Formal Analysis. **VSS:** Conceptualization, Writing – original draft. **DCFL:** Conceptualization, Data curation, Formal Analysis.

REFERENCES

1. Hoang A, Chorath K, Moreira A, Evans M, Burmeister-Morton F, Burmeister F, et al. COVID-19 in 7780 pediatric patients: a systematic review. *EClinicalMedicine*. 2020;24:100433. <https://doi.org/10.1016/j.eclinm.2020.100433>
2. Nakra NA, Blumberg DA, Herrera-Guerra A, Lakshminrusimha S. Multi-system inflammatory syndrome in children (MIS-C) following SARS-CoV-2 infection: review of clinical presentation, hypothetical pathogenesis, and proposed management. *Children (Basel)*. 2020;7(7):69. <https://doi.org/10.3390/children7070069>
3. Consiglio CR, Cotugno N, Sardh F, Pou C, Amodio D, Rodriguez L, et al. CACTUS Study Team. The immunology of multisystem inflammatory syndrome in children with COVID-19. *Cell*. 2020;183(4):968-81.e7. <https://doi.org/10.1016/j.cell.2020.09.016>
4. Safadi MAP. The intriguing features of COVID-19 in children and its impact on the pandemic. *J Pediatr (Rio J)*. 2020;96(3):265-8. <https://doi.org/10.1016/j.jpeds.2020.04.001>
5. Patel KP, Patel PA, Vunnam RR, Hewlett AT, Jain R, Jing R, et al. Gastrointestinal, hepatobiliary, and pancreatic manifestations of COVID-19. *J Clin Virol*. 2020;128:104386. <https://doi.org/10.1016/j.jcv.2020.104386>
6. Ahmed M, Advani S, Moreira A, Zoretic S, Martinez J, Chorath K, et al. Multisystem inflammatory syndrome in children: a systematic review. *EClinicalMedicine*. 2020;26:100527. <https://doi.org/10.1016/j.eclinm.2020.100527>
7. Ottaviani D, Boso F, Tranquillini E, Gapeni I, Pedrotti G, Cozzio S, et al. Early Guillain-Barré syndrome in coronavirus disease 2019 (COVID-19): a case report from an Italian COVID-hospital. *Neurol Sci*. 2020;41(6):1351-4. <https://doi.org/10.1007/s10072-020-04449-8>
8. Padroni M, Mastrangelo V, Asioli GM, Pavolucci L, Abu-Rumeileh S, Piscaglia MG, et al. Guillain-Barré syndrome following COVID-19: new infection, old complication? *J Neurol*. 2020;267(7):1877-9. <https://doi.org/10.1007/s00415-020-09849-6>
9. Willison HJ, Jacobs BC, van Doorn PA. Guillain-Barré syndrome. *Lancet*. 2016;388(10045):717-27. [https://doi.org/10.1016/S0140-6736\(16\)00339-1](https://doi.org/10.1016/S0140-6736(16)00339-1)

