

# The effects of fat graft and platelet-rich fibrin combination after epineurectomy in rats

Menekşe Kastamoni<sup>1</sup> , Senem Esin Yavaş<sup>2</sup> , Güzin Yesim Ozgenel<sup>3</sup> , Semiha Ersoy<sup>2\*</sup> 

## SUMMARY

**OBJECTIVE:** One of the most important factors that adversely affects the outcome of peripheral nerve surgery is the formation of epineural and extraneural scar tissue after surgery. Many surgical methods and pharmacological and chemical agents have been used to prevent the formation of epineural scar tissue, but satisfactory results have not been achieved in clinical applications. The purpose of this study was to investigate the combined effect of fat graft and platelet-rich fibrin on the formation of epineural scar tissue and on nerve healing in the mature rat model.

**METHODS:** A total of 24 female Sprague-Dawley rats were used. A circumferential segment of epineurium was excised from both bilateral sciatic nerves. The epineurectomized right nerve segment was wrapped with a combination of fat graft and platelet-rich fibrin (experimental group), while the left nerve segment did not receive any surgical procedure other than the epineurectomy (sham group). Notably, 12 randomly selected rats were sacrificed in the fourth week for histopathological examination of early results. The other 12 rats were sacrificed in the eighth week for late results.

**RESULTS:** The formation of fibrosis, inflammation, and myelin degeneration were less common in the experimental group, while nerve regeneration was found to be higher at both 4 and 8 weeks.

**CONCLUSION:** The intraoperative application of a combination of fat graft and platelet-rich fibrin appears to be effective on nerve healing after surgery at both the early and late periods.

**KEYWORDS:** Sciatic neuropathy. Nerve regeneration. Platelet-rich fibrin. Adipose tissue. Receptor, EphA4.

## INTRODUCTION

Epineural and extraneural scar tissue that develops out of control by causing chronic pain and loss of function is an important factor that adversely affects the outcome of peripheral nerve surgery<sup>1</sup>. To prevent perineural scar formation occurring after peripheral nerve surgery, various techniques and agents (wrapping of nerves with various natural materials such as vein, buccal mucosa, fascia tissue, human amniotic membrane, hyaluronic acid injection around the damaged nerve, and 5-fluorouracil) have been tried, but these methods have not solved the problem entirely<sup>2-4</sup>. As the adipose tissue is a rich source of multipotent mesenchymal cells called adipose-derived stem cells<sup>5</sup>, the frequency and importance of using fat grafts during surgical procedures are gradually increasing. In vitro studies have demonstrated that platelet-rich plasma (PRP) and platelet-rich fibrin (PRF) activate the adipose-derived stem cells with secreted factors<sup>6</sup>.

Remyelination is important in the recovery of axonal function after nerve injury. Schwann cells are responsible for

myelination/remyelination in the peripheral nervous system (PNS)<sup>7,8</sup>. The Eph (erythropoietin-producing hepatocellular carcinoma) receptors form the largest family of tyrosine kinase receptors. They are divided into two subfamilies, namely, EphA and EphB, and their ligands are ephrins. It has been reported that the activation of one of these receptors, EphA4, decreases myelination by oligodendrocytes in the central nervous system, while its inhibition increases it<sup>9</sup>. There are few studies showing that EphA4, which is also expressed in intact Schwann cells, negatively regulates myelination by these cells in PNS damage repairs<sup>10,11</sup>.

Considering the studies using fat graft alone and PRF alone, in our experimental study, we aimed to reduce the adhesion and scar formation in the nerves by using the stimulating effect of thrombocytes on adipose tissue-originated stem cells and increasing tissue repair. We also attempted to evaluate the efficacy of the applied treatment with EphA4 expression levels.

<sup>1</sup>Niğde Training and Research Hospital, Department of Plastic Reconstructive and Aesthetic Surgery – Niğde, Turkey.

<sup>2</sup>Bursa Uludağ Üniversitesi, School of Medicine, Department of Histology and Embryology – Bursa, Turkey.

<sup>3</sup>Bursa Uludağ Üniversitesi, School of Medicine, Department of Plastic Reconstructive and Aesthetic Surgery – Bursa, Turkey.

\*Corresponding author: [semihaersoy@uludag.edu.tr](mailto:semihaersoy@uludag.edu.tr)

Conflicts of interest: the authors declare there is no conflicts of interest. Funding: none.

Received on September 30, 2022. Accepted on November 14, 2022.

## METHODS

### Animals

All animals in this study were used according to a protocol approved by the Bursa Uludag University Experimental Animals and Ethics Committee (approval no.: 2019-05/03). A total of 24 12-week-old female Sprague-Dawley rats weighing 250–300 g were used. Animals were kept in groups of four in cages with free access to food and water under alternating 12-h light and dark periods.

### Surgical procedure

All animals were anesthetized by sevoflurane 250 mL (Sojourn, Piramal) via an inhaler. Following the induction of general anaesthesia, rats were placed in a supine position. First, approximately 1 mL of blood was taken from the rat tail artery and placed in the device for centrifugation at the appropriate speed for the preparation of PRF. The rat was then returned to the prone position. After longitudinal skin incisions, bilateral sciatic nerves were accessed via blunt dissection through the gluteus maximus and biceps femoris muscles. Bilateral sciatic nerves, from the sciatic notch to the bifurcation, were exposed. A 0.5-cm-long epineurium segment was circumferentially excised from the main nerve trunk to initiate scar tissue formation. For the right sciatic nerve, the incision was extended to the popliteal region, and approximately 10×10×0.5 mm<sup>3</sup> fat grafts were prepared from the adipose tissue in this area. Meanwhile, the fat graft obtained from the popliteal region was mixed with the PRF, whose centrifuge was finished and ready, and it was wrapped around the epineurectomy area. The left nerve segment did not undergo any surgical procedure other than the epineurectomy and was considered the sham (or control) group. The right sciatic nerve was considered the experimental (or treatment) group. For histopathological examinations, 12 randomly selected rats were euthanized in the fourth week for early results and the remaining 12 rats in the eighth week for late results.

### Histopathology

The right (experimental/treatment group) and the left (sham/control group) nerve segments were removed en bloc with the surrounding tissue, fixed in neutral-buffered 10% formalin solution, dehydrated in alcohol series, and embedded in paraffin. Then, 5- $\mu$ m sections were stained with routine haematoxylin and eosin (H&E) for general morphology and with Masson's trichrome for fibrosis. In addition, one group of sections was stained with the Klüver Barrera method to evaluate myelination, while EphA4 receptor immunohistochemistry was applied to another group of sections. Tissues from a rat without any

procedure were used to see the healthy sciatic nerve structure and to compare it with other groups.

### Immunohistochemistry

Sections were incubated in citrate buffer (pH=6.0) at 98°C and then cooled and rinsed for 3×5 min in TRIS tampon (pH=7.6). They were incubated in a 3% H<sub>2</sub>O<sub>2</sub> blocked endogenous peroxidase activity for 5 min at room temperature and rinsed for 3×5 min in TRIS tampon. Blockage of nonspecific binding protein was done by incubating sections with horse serum (Sigma Aldrich, H1138) for 30 min. Incubation with anti-EphA4 primary antibody (Santa Cruz, sc-365503) was done overnight at 4°C. After rinsed for 3×5 min in TRIS tampon, the sections were incubated with donkey anti-mouse IgM secondary antibody (Jackson Immunoresearch, 715-065-140) for 1 h and ABC solution (VECTOR Laboratories, PK6100) for 2 h. The reactions were visualized with DAB and counterstained with Harris haematoxylin.

Results were independently evaluated by two investigators using a light microscope. Fibrosis, inflammation, and degeneration were evaluated on a three-point scale (mild, moderate, and severe). Regenerative changes around the nerve (remyelination and EphA4 receptor expression) were evaluated on a five-point scale (none, poorly, moderate, well, and perfect). Photographs were taken using an Olympus BX 50 photomicroscope.

### Statistical evaluation

To investigate the differences in histopathological values according to the fourth and eighth weeks for each group, an analysis was made with the Mann-Whitney U test. Wilcoxon signed-ranks test was used to evaluate the early and late results of histopathological values separately. Analyses were made using the SPSS 22.0 package program. Differences were considered statistically significant at  $p < 0.05$ .

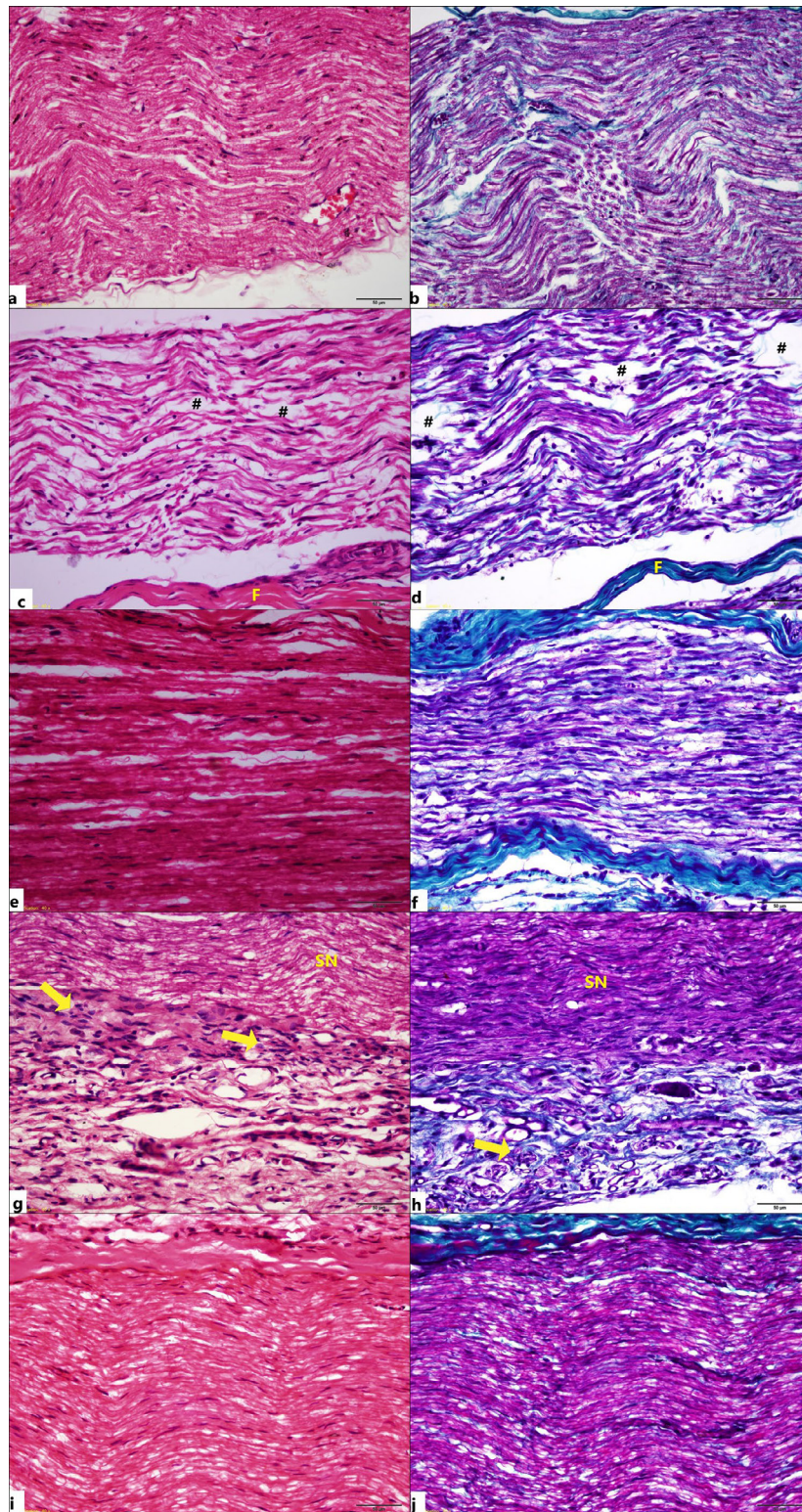
## RESULTS

### Degeneration

Myelin degeneration was more prominent in the sham groups than in the experimental groups in both the early and late periods (Figure 1). It was observed that the application of combined fat graft and PRF significantly reduced myelin degeneration in both the early and late periods (Figure 2A).

### Fibrosis and inflammation

Less collagenous area and inflammation were observed in the sciatic nerves that were wrapped with combined fat graft and



**Figure 1.** Histological appearance of the all groups. Intact sciatic nerve (a, b), 4-week sham group (c, d), 4-week treatment group (e, f), 8-week sham group (g, h), and 8-week treatment group (i, j). (F: Fibrosis; →: Inflammation; SN: Sciatic nerve; #: Degeneration). (a, c, e, g, i: H&E staining, b, d, f, h, j: Masson's trichrome staining).

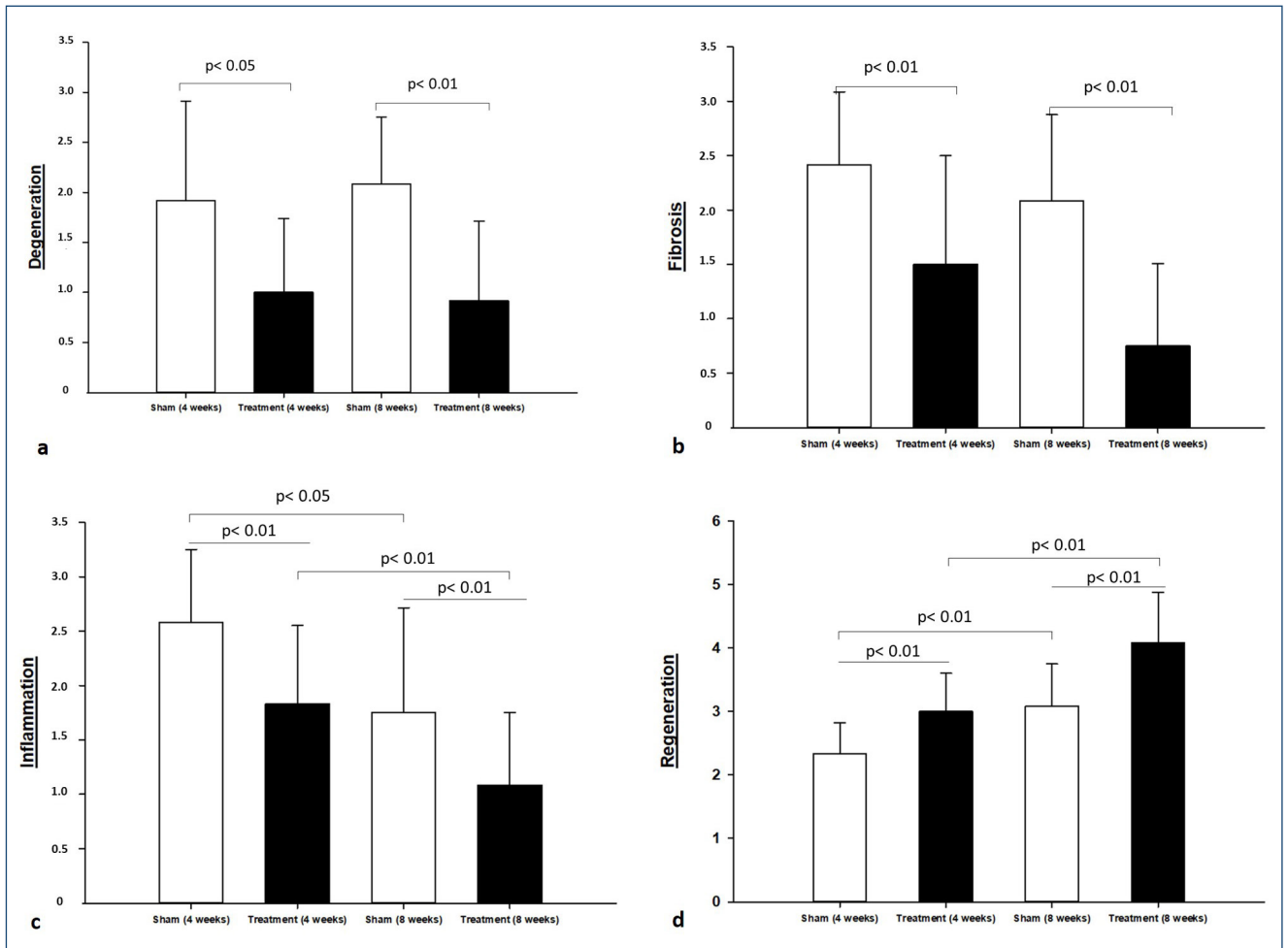


Figure 2. The statistical results.

PRF in both the early and late periods compared to the sham groups (Figure 1). Histopathologically, it was observed that inflammation and fibrosis were statistically significantly reduced in rats treated with 4 and 8 weeks of combined fat grafting and PRF (Figures 2B,C).

### Nerve regeneration/remyelination

Regeneration was observed better in the experimental groups than in the sham groups in both the early and late periods (Figure 1). Intact myelin sheaths in control tissues were stained in a characteristic intense blue colour by the Klüver Barrera method (Figure 3A). It was determined that remyelination was not completed and the stained areas and staining intensity decreased in the 8-week sham group (Figure 3B). The sciatic nerves in the 8-week treatment group were observed to have acquired staining and morphology that is almost similar to those of the control sections (Figure 3C). The 4-week treatment and 4-week sham groups were similar to the 8-week sham group (data not shown).

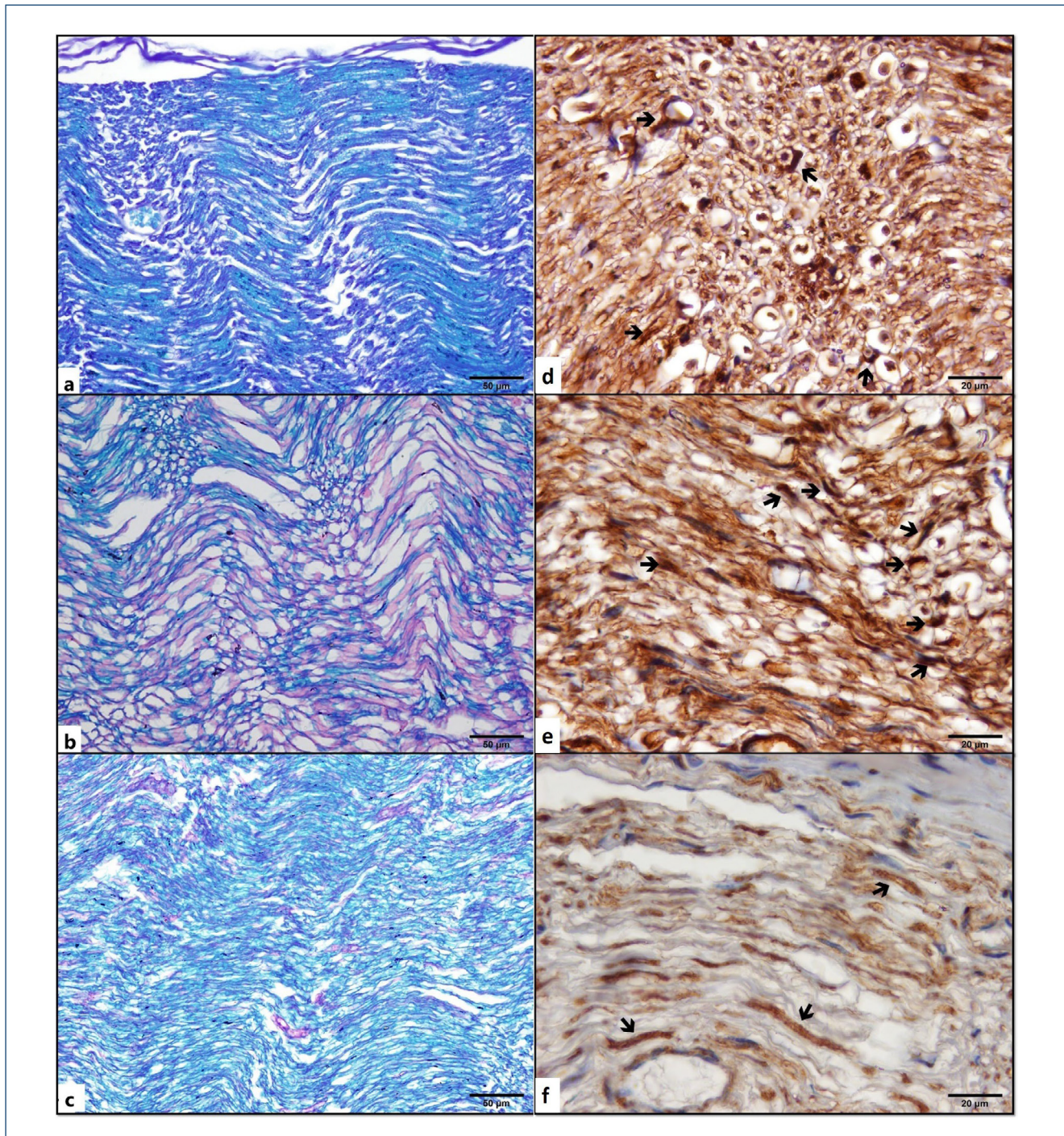
### EphA4 receptor expression

It was observed that the expression of EphA4 in Schwann cells according to the control sections (Figure 3D) was relatively increased in the 4-week early treatment group (Figure 3E). EphA4 immunopositivity in the 8-week treatment group (Figure 3F) was relatively decreased compared to the 4-week treatment group (Figure 3E).

The combined fat graft and PRF application was found to have a statistically significant positive effect on nerve regeneration (decrease in EphA4 expression and increase in remyelination) in both the early and late periods in the experimental groups (Figure 2D).

## DISCUSSION

Perineural adhesions and scar formation occurring after peripheral nerve surgery are unpredictable and undesirable. Despite advances in microsurgery, functional return after classic methods of nerve repair is unsatisfactory<sup>12</sup>. Various applications, such as ADCON-T/<sup>13</sup>, human amniotic fluid with hyaluronic acid<sup>2</sup>, buccal mucosal



**Figure 3.** Myelination and EphA4 receptor expression. Intact sciatic nerve (a), 8-week sham group (b), 8-week treatment group (c) (Klüver-Barrera staining). Intact sciatic nerve (d), 4-week treatment group (e), and 8-week treatment group (f) (EphA4 immunopositivity: →).

graft<sup>3</sup>, and topical 5-fluorouracil<sup>4</sup> are some of the methods used to reduce post-surgical adhesions and scar formation.

There has been a recent interest in adipose-derived stem cells. Adipose tissue is a rich source of these multipotent mesenchymal cells and has a unique advantage of being harvested easily, cheaply,

and safely<sup>5,6</sup>. Several experimental studies with fat grafts have been tried to improve the results of the peripheral nerve surgery. In one study in rats, free fat grafts were applied around the sciatic nerve with epineurectomy and showed that the fat graft reduced perineural scar tension with unexpected degenerative changes in some

cases<sup>14</sup>. In another study in rats, fat grafts have been shown to positively affect early nerve regeneration but have no significant effect on fibrosis and scar formation<sup>15</sup>. In recent years, studies have been conducted by wrapping fat grafts around the nerves and placing the adipose-derived stem cells in the repair line and found that adipose-derived stem cells have a positive effect on nerve healing. Liu et al.<sup>16</sup> showed that adipose-derived stem cells increase the rates of nerve healing and nerve conduction after repair.

Platelet-rich plasma is prepared by centrifuging one's own blood and contains 4–7 times the dense platelet of normal blood concentration. Alpha granules in platelets contain seven basic growth factors: platelet-derived growth factor (PDGF $\alpha$ , PDGF $\beta$ , and PDGF $\gamma$ ), transforming growth factor-beta (TGF $\beta$ 1 and TGF $\beta$ 2), epithelial growth factor (EGF), and vascular endothelial growth factor (VEGF). These growth factors have been shown to modulate cell proliferation, differentiation, angiogenesis, and chemotaxis. The most preferred enrichment methods developed to benefit from the mentioned features of platelets are classical PRP and PRF<sup>17</sup>. One study examined the effects of PRF on the sciatic nerve healing model and found that PRF had an accelerating and complementary effect on peripheral nerve healing histologically<sup>18</sup>. *In vitro* studies showed that the factors released by PRP and PRF activate the adipose-derived stem cells and chemotaxis of these cells<sup>6</sup>. This study is the first one in which completely autologous biological products are used and positive results are obtained in all parameters histologically and no complications are observed.

For nerve regeneration to be functional, both axonal elongation and new myelin synthesis should occur<sup>7,8</sup>. In our study, we concluded that remyelination in the 8-week late treatment and control groups was similar and that the long-term treatment applied had a positive effect on regeneration. Harboe et al.<sup>9</sup> showed that the EphrinA1-EphA4 signalling negatively affects myelination in the central nervous system after injury. Similarly, EphA4 has effect on Schwann cell differentiation and regeneration in PNS injuries. It has been reported that remyelination and axonal regeneration are due to Schwann cell differentiation after peripheral nerve damage in EphA4<sup>-/-</sup> rats<sup>11</sup>. Chen et al.<sup>10</sup> reported that the expression of EphA4 in Schwann cells in the PNS has negative effects on myelination by inhibiting the differentiation of these

cells after injury. Similarly, in our study, insufficient myelination in correlation with the increase in EphA4 expression at the end of 4 weeks and remyelination and axonal recovery in correlation with the decrease in EphA4 expression at the end of 8 weeks suggested that EphA4 had a negative effect on myelination and axonal repair in the sciatic nerve.

## CONCLUSION

Our results show that the use of the fat graft+PRF combination positively affects nerve recovery after epineurectomy histologically in both the early and late periods. The areas of use of the fat graft+PRF combination should be investigated and increased in order to obtain the expected mutual effects and hence positive results. We believe that this study will be a guide in this regard. However, the limitation of our study is that the degree of functional recovery of the sciatic nerves was not evaluated. We also believe that it would be more meaningful to support our histopathological results with functional results. In addition, it is necessary to investigate through which molecular pathways the graft components are effective in the expression of EphA4 in Schwann cells. In this way, EphA4 can be used as a potential molecular marker for peripheral nerve injuries in the clinics in the future.

## ETHICS

This study was conducted at Bursa Uludag University, School of Medicine, Department of Histology and Embryology, Bursa, Turkey, and conducted in accordance with the Declaration of Helsinki. The Ethics Committee approved the study protocol of Bursa Uludag University (approval no.: 2019-05/03).

## AUTHORS' CONTRIBUTIONS

**MK:** Conceptualization, Methodology, Investigation, Resources, Writing – original draft. **SEY:** Data curation, Formal Analysis, Investigation, Methodology, Resources, Writing – original draft. **SE:** Data curation, Formal Analysis, Investigation, Methodology, Resources, Writing – original draft. **GYO:** Conceptualization, Methodology.

## REFERENCES

1. Abrams M, Widenfalk J. Emerging strategies to promote improved functional outcome after peripheral nerve injury. *Restor Neurol Neurosci*. 2005;23(5-6):367-82. PMID: 16477099
2. Ozgenel GY, Filiz G. Combined application of human amniotic membrane wrapping and hyaluronic acid injection in epineurectomized rat sciatic nerve. *J Reconstr Microsurg*. 2004;20(2):153-7. <https://doi.org/10.1055/s-2004-820772>
3. Baltu Y, Uzun H, Özgenel GH. The reduction of extraneural scarring with buccal mucosa graft wrapping around the sciatic nerve: an experimental study in a rat model. *J Plast Surg Hand Surg*. 2017;51(4):259-63. <https://doi.org/10.1080/2000656X.2016.1241790>

4. Cavus Ozkan M, Tuncel B, Ozgenel GY. The effect of topical 5-fluorouracil application on epineural scar tissue in epineurectomized rat sciatic nerve. *Marmara Med J*. 2018;31:1-10. <https://doi.org/10.5472/marumj.342046>
5. PuLLQ, ColemanSR, CuiX, FergusonREH, VasconezHC. Autologous fat grafts harvested and refined by the Coleman technique: a comparative study. *Plast Reconstr Surg*. 2008;122(3):932-7. <https://doi.org/10.1097/PRS.0b013e3181811ff0>
6. Lopez JF, Sarkanen JR, Huttala O, Kaartinen IS, Kuokkanen HO, Ylikomi T. Adipose tissue extract shows potential for wound healing: *in vitro* proliferation and migration of cell types contributing to wound healing in the presence of adipose tissue preparation and platelet rich plasma. *Cytotechnology*. 2018;70(4):1193-204. <https://doi.org/10.1007/s10616-018-0211-y>
7. Jessen KR, Mirsky R. The origin and development of glial cells in peripheral nerves. *Nat Rev Neurosci*. 2005;6(9):671-82. <https://doi.org/10.1038/nrn1746>
8. Jessen KR, Mirsky R. The success and failure of the Schwann cell response to nerve injury. *Front Cell Neurosci*. 2019;13:33. <https://doi.org/10.3389/fncel.2019.00033>
9. Harboe M, Torvund-Jensen T, Kjaer-Sorensen K, Laursen LS. Ephrin-A1-EphA4 signaling negatively regulates myelination in the central nervous system. *Glia*. 2018;66(5):934-50. <https://doi.org/10.1002/glia.23293>
10. Chen R, Yang X, Zhang B, Wang S, Bao S, Gu Y, et al. EphA4 negatively regulates myelination by inhibiting Schwann cell differentiation in the peripheral nervous system. *Front Neurosci*. 2019;13:1191. <https://doi.org/10.3389/fnins.2019.01191>
11. Wang Y, Zheng Z, Hu D. Inhibition of EphA4 expression promotes Schwann cell migration and peripheral nerve regeneration. *Neuroscience Lett*. 2013;548:201-5. <https://doi.org/10.1016/j.neulet.2013.05.022>
12. Maser BM, Vedder N. Nerve repair and nerve grafting. In: Russell RC, editor. *Plastic surgery. Indications, operations, and outcomes*. Vol. 4 (Hand Surgery). New York: Mosby; 2000. p. 2103-19.
13. Petersen J, Russel L, Andrus K, MacKinnon M, Silver J, Kliot M. Reduction of extraneural scarring by ADCON-T/N after surgical intervention. *Neurosurgery*. 1996;38(5):976-83. <https://doi.org/10.1097/00006123-199605000-00025>
14. Dumanian GA, McClinton MA, Brushart TM. The effect of free fat grafts on stiffness of the rat sciatic nerve and perineural scar. *J Hand Surg Am*. 1999;24(1):30-6. <https://doi.org/10.1053/jhsu.1999.jhsu24a0030>
15. Ersen B, Kahveci R, Uğraş N, Ocakoğlu G. Evaluation of effects of fat graft wrapping on early nerve regeneration: an experimental study. *Türkiye Klinikleri J Med Sci*. 2018;38(4):303-8. <https://doi.org/10.5336/medsci.2018-60484>
16. Liu GB, Cheng YX, Feng YK, Pang CJ, Li Q, Wang Y, et al. Adipose-derived stem cells promote peripheral nerve repair. *Arch Med Sci*. 2011;7(4):592-6. <https://doi.org/10.5114/aoms.2011.24127>
17. Wang X, Zhang Y, Choukroun J, Ghanaati S, Miron RJ. Effects of an injectable platelet-rich fibrin on osteoblast behavior and bone tissue formation in comparison to platelet-rich plasma. *Platelets*. 2018;29(1):48-55. <https://doi.org/10.1080/09537104.2017.1293807>
18. Metineren H, Dülgeroğlu TC, Metineren MH. Trombositten zengin fibrinin periferik sinir iyileşmesi üzerindeki histopatolojik etkileri. *Dicle Med J*. 2017;44(3):243-50. <https://doi.org/10.5798/dicletip.338997>

