

## CHONDROSARCOMA IN A PATIENT WITH MULTIPLE OSTEOCHONDROMATOSIS: A CASE REPORT AND REVIEW OF THE LITERATURE\*

Anna Caroline Nobre Gomes<sup>1</sup>, Cláudio Régis Sampaio Silveira<sup>2</sup>, Roberto Guido Santos Paiva<sup>2</sup>, Antônio Gilson Monte Aragão Jr.<sup>2</sup>, José Roberto Cavalcante Castro Jr.<sup>3</sup>

**Abstract** The authors report a case of chondrosarcoma in a 14-year-old female patient with multiple osteochondromatosis who has sought medical assistance complaining of a tumor on the left coxa. CT images of the affected limb have demonstrated osteodestructive lesion on the superior third of the left femur. The diagnosis has been made through a review of the biopsy slide from the service of origin of the patient, confirming the finding of a grade I chondrosarcoma in a chondromatous lesion. Disarticulation of the femoral neck was made because of the large extent of the lesion in muscular groups, subcutaneous cellular tissue and skin. The literature shows a wide variation in rates of malignant transformation of exostosis in patients with this disease, and this is a significant complication in patients affected by this disease.

*Keywords:* Chondrosarcoma; Multiple osteochondromatosis; Computed tomography; Femur.

**Resumo** *Condrossarcoma em paciente com osteocondromatose múltipla: relato de caso e revisão da literatura.* Os autores relatam um caso de condrossarcoma em uma paciente de 14 anos portadora de osteocondromatose múltipla, que procurou assistência médica com a queixa de tumoração na coxa esquerda. Cortes tomográficos do membro afetado evidenciaram lesão osteodestrutiva no terço superior do fêmur esquerdo. O diagnóstico foi feito através da revisão da lâmina do serviço de origem da paciente, confirmando o achado de condrossarcoma grau I em lesão condromatosa. Foi realizada desarticulação do colo femoral devido ao extenso comprometimento de grupos musculares, de tecido celular subcutâneo e de pele. A literatura mostra ampla variação nas taxas de transformação maligna das exostoses em pacientes portadores desta doença, sendo esta uma importante complicação nestes pacientes.

*Unitermos:* Condrossarcoma; Osteocondromatose múltipla; Tomografia computadorizada; Fêmur.

### INTRODUCTION

Multiple osteochondromatosis, also called hereditary multiple exostosis or diaphyseal aclasis, is a bony metaphysis genetically heterogeneous disorder transmitted in an autosomal dominant manner, presenting an incomplete penetrance in female individuals<sup>(1)</sup>. Kivioja *et al.*<sup>(2)</sup> and Schmale *et al.*<sup>(1)</sup> report a 1/50,000 prevalence of this disorder, although another study has shown a 9/1,000,000 in Europe<sup>(3)</sup>. Osteochondromas develop only in bones of endochondral origin as a result of a peripheral dysplasia

of the growth plate<sup>(1)</sup>, causing displacement in areas of the plate. This is the most frequent type of benign bone tumor<sup>(1)</sup> and affects primarily long bones<sup>(1,4,5)</sup>, pelvis, scapula<sup>(2,4)</sup>, ankle and knee<sup>(1)</sup>.

The most severe complication presented by patients affected by multiple osteochondromatosis is the malignant degeneration of cartilaginous exostosis into chondrosarcomas or, more rarely, into other types of sarcomas. A high variation is found in rates of malignant degeneration reported in the literature, with a more recent study reporting a rate of less than 5%<sup>(6)</sup>.

Peripheral chondrosarcomas are less aggressive (or possibly more accessible to surgical excision) than central tumors<sup>(5)</sup>. An adequate treatment implies a complete resection of the tumor and of the bone segment involved. The prognosis for patients with dedifferentiated chondrosarcoma is poor, independently from the therapy method employed; most of patients die as a result of distant metastases within one year after the initial diagnosis<sup>(7)</sup>.

In this study, we present a case of a secondary grade I chondrosarcoma in a patient with multiple osteochondromatosis, and also a literature review.

### CASE REPORT

A female, 14-year-old patient referred to the orthopedics ambulatory, complaining of a tumor on the left coxa. The patient presented with multiple osteochondromatosis, with a painful and slow growing tumor on the lateral surface of the proximal third of the left coxa for two years. There was no familial history of multiple exostoses.

At physical examination, the patients presented with a tumor affecting the anterolateral surface of the posterior third of the left coxa. The left coxa presented 56 cm in diameter, and the right coxa, 46 cm.

A review of the biopsy slide from the service of origin of the patient was made in our service, confirming the finding of a grade I chondrosarcoma in a chondromatous lesion.

\* Study developed at Hospital do Câncer do Ceará Service of Radiology, Fortaleza, CE, Brazil.

1. Student in the fourth year at Faculty of Medicine – Universidade Federal do Ceará.

2. MDs, Radiologists at Hospital do Câncer do Ceará, Titular Members of Brazilian College of Radiology and Diagnostic Imaging.

3. MD, Orthopedist at Hospital do Câncer do Ceará, Titular Member of Brazilian Society of Orthopedics and Traumatology.

Mailing address: Anna Caroline Nobre Gomes. Conjunto Castelo Branco, Quadra F, 187, Presidente Kennedy. Fortaleza, CE, Brazil 60357-250. E-mail: acngomes@yahoo.com.br

Received March 3, 2005. Accepted after revision May 25, 2005.

Axial CT imaging was performed in our service, with 10 mm-thick slices, after iodine contrast mean administration, evidencing an expansile osteodestructive lesion affecting the proximal diaphysis, permeated by gross calcifications and with a solid component invading soft tissues, involving the anterior muscular compartment at the level of the root of the hip. The femoral muscular-nervous bundle was medially dislocated by the lesion, but the vascular permeability was not affected. The lesion measured  $13 \times 12 \times 11.5$  cm in orthogonal planes. Bone excrescences compatible with osteochondroma were observed on the lateral and medial femoral distal diaphysis, with absence of cortical rupture.

Disarticulation of the femoral neck was made because of an extensive involvement of muscular groups, subcutaneous cellular tissue and skin.

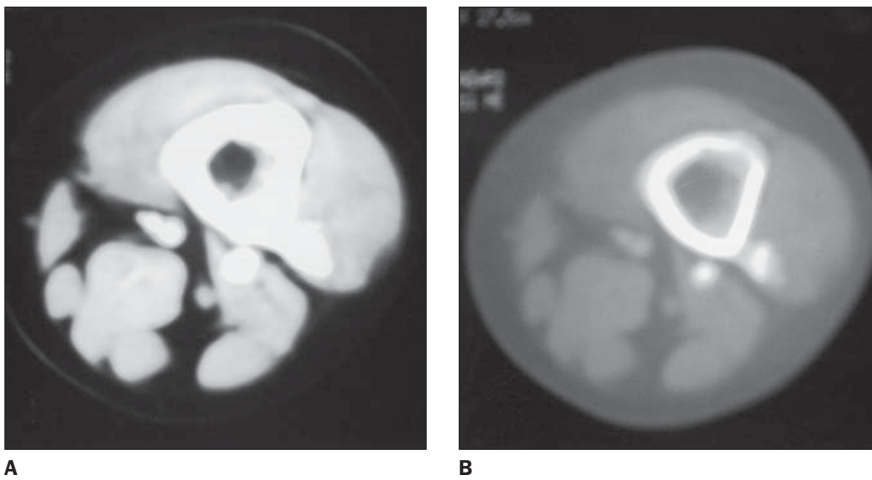
## DISCUSSION

In 1786, John Hunter established the differentiation between solitary and multiple osteochondromatosis, therefore the diagnosis of this disease currently is well established<sup>(3)</sup>. In approximately 10% of cases documented in the series of Schmale *et al.*<sup>(1)</sup> there was no familial history of multiple exostosis, confirming the information already existent in the literature<sup>(4)</sup>. So, the appearance of this disease was associ-

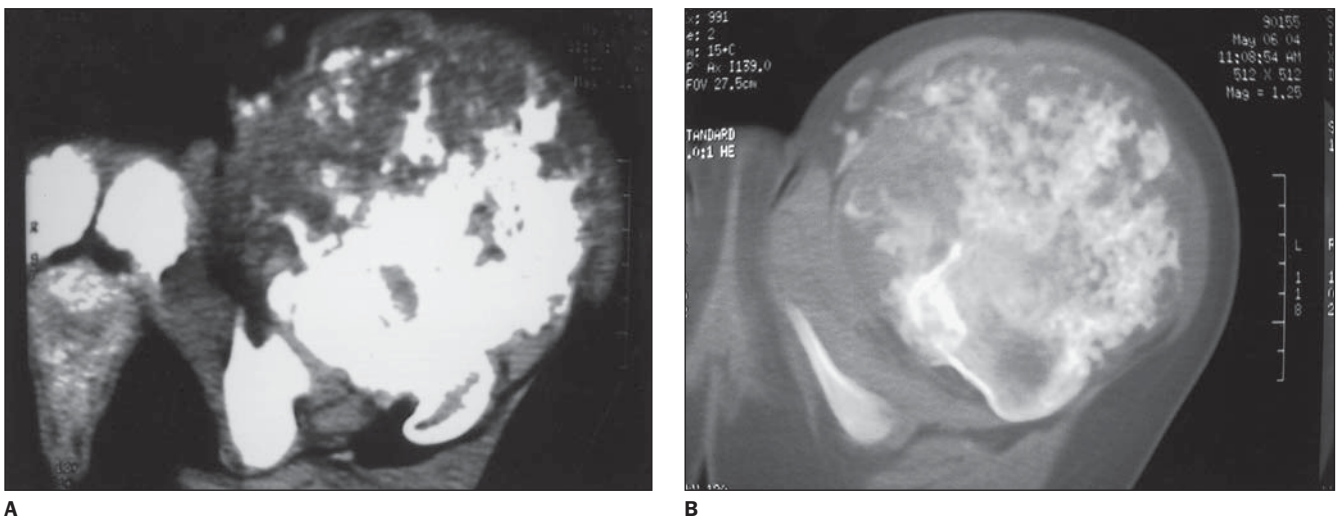
ated with a spontaneous genes mutation<sup>(4)</sup>. In the study of Schmale *et al.*<sup>(1)</sup> an incomplete penetrance of this disorder was not detected in female individuals, but rather an absent detection of small exostoses in this group because of the large deposition of fat tissue during puberty. The data obtained also support the concept that the gene expression is more severe in men.

The radiological finding determining the diagnosis of diaphyseal aclasis is the direct continuity of the mass with the primary bone medullary cavity and absence of subjacent cortex. This occurs because of the bone metaphysis displacement during its growth through a deficient perichondrium, and later formation of spongiosa bone inside the mass as the vessels invade the cartilage. The growth of exostoses occurs during the childhood, ceasing with the end of the adjacent plate growth, and may cause symptoms as a result of local tissues compression, deformities and alterations in length of bones<sup>(2)</sup>.

The growth of one or more exostoses after the end of the skeletal growth period should raise the possibility of a malignant degeneration of the benign tumor<sup>(5,6,8)</sup>. A very frequent symptom is pain<sup>(5,6,8)</sup>, although exostoses growth has been described as slow-growing and painless by Kivioja *et al.*<sup>(2)</sup>, and the malignant degeneration, even as asymptomatic by Bovée *et al.*<sup>(6)</sup>. Other findings are: neurovascular complications<sup>(8)</sup>, pathological fractures<sup>(8)</sup>



**Figure 1.** CT image of coxa, bone window (A) and soft tissues (B). Exostoses on the left femur posterior surface.



**Figure 2.** CT image of coxa, bone window (A) and soft tissues (B). Large expansile, osteodestructive lesion on the left femur proximal diaphysis, permeated by gross calcifications. Chondrosarcoma.

and thickening > 1 cm of the cartilaginous cap in adults<sup>(4,6,8)</sup>. Due their risk of development of a malignant tumor, besides the difficulty in detecting alert symptoms in regions like the pelvis<sup>(2)</sup>, it is advised that such patients are submitted to periodical follow-up with biennial x-rays<sup>(2)</sup>, especially those with exostoses in the most frequent sites of sarcomatous degeneration, that is to say, the pelvis<sup>(1,2,4,5,8)</sup> and shoulder<sup>(1,5,8)</sup>. In case of suspect protuberances, a magnetic resonance imaging (MRI) should be performed<sup>(2)</sup>. Chondrosarcomas rarely affect distal parts of limbs.

Therefore, this complication frequently occurs after puberty and is rare during childhood. Malignization is more frequent in the age range between 20 and 40 years<sup>(8)</sup>, the risk increase being directly proportional to the age of the patient<sup>(1)</sup>.

Chondrosarcomas may be primary or secondary, the latest appearing as a malignant transformation of an enchondroma or, rarely, of an osteochondroma cartilaginous cap. Depending on the site, chondrosarcomas are further subclassified as intramedullary or juxtacortical, and, histologically as conventional (hyaline and/or myxoid), clear cell, dedifferentiated and mesenchymal variants. These sarcomas, usually, have an indolent natural history, presenting with pain and swelling.

The malignant transformation process occurs with a frequency of approximately, 5%<sup>(1,5)</sup>. However, the literature presents wide variations in this rate. Rates as low as 0,6%<sup>(2)</sup> and as high as 25%<sup>(7)</sup> also are described, but probably are a function of: bias in ascertainment and incomplete detection of affected individuals who did not develop a sarcoma, but presented a familial history of hereditary multiple exostosis<sup>(1)</sup>; a prolonged follow-up period, which increases the risk of sarcomatous degeneration<sup>(1)</sup>; differences of ages between study series<sup>(5)</sup>; malignancy criterion<sup>(5)</sup>; and grade of spe-

cialization of the services where the cases come from<sup>(5)</sup>.

X-rays, CT, MRI, arteriography and bone scintigraphy provide findings suggesting the diagnosis of chondrosarcoma<sup>(8)</sup>. The cartilage nodular growth pattern produces radiographically prominent endosteal scalloping. The calcified matrix appears like foci of flaked density, the cartilaginous matrix presenting with mottled, popcorn, stippled or anular calcification<sup>(8)</sup>. Serial x-rays usually provide some indication of malignant transformation<sup>(4,5)</sup>. X-ray as single examination in these cases is rarely conclusive; most frequently the evaluation of all the other evidences should be taken into consideration<sup>(5)</sup>. Sharply defined margins of a lesion may become indistinct<sup>(4,8)</sup>, or the lesion may increase in size<sup>(4,5,8)</sup>, or its mineralization may show a ground glass appearance<sup>(4)</sup>. A relative lucency in a previously mineralized region of the cartilaginous cap also implies the possibility of sarcomatous degeneration<sup>(4,8)</sup>. Although the thickness of the demineralized cartilaginous cap usually is < 1 cm in benign osteochondromas, generally, in cases of malignant transformation, it is > 2 cm<sup>(4)</sup>. Generally, but not always, the evidence of the cartilaginous cap thickness is a reliable sign of malignancy or benignity<sup>(4)</sup>. It may be difficult to evaluate this thickness by means of CT, because of the similar radiodensity of perichondrium, bursa and other juxtaposed tissues<sup>(4)</sup>. The more radiotransparent is the tumor, the higher is the probability of a high grade tumor. A slow-growing and low-grade tumor causes a reactive cortical thickening, while a more aggressive high-grade neoplasm destructs the cortex and forms a soft tissue mass. CT is not useful for differentiating benign from malignant lesions, although a negative CT may rule out the possibility of an exostosis malignant transformation<sup>(2)</sup>. Kivioja *et al.*<sup>(2)</sup>, in their study,

have utilized MRI as a technique for screening in the pelvis, proximal femur and upper humerus, but its utilization for early detection of chondrosarcomas and follow-up of patients with multiple exostoses yet is very limited. For Solomon<sup>(5)</sup>, the diagnosis issue is aggravated by one's attempt to establish a precise differentiation between a benign lesion and a chondrosarcoma. By definition, the term *sarcoma* only can be applied to designate a neoplasm likely to metastize, and this is what is expected to be avoided with an appropriate management of a tumor before it manifests such feature<sup>(5)</sup>. Therefore, it is important to evaluate the probable behavior of the tumor rather than its precise designation<sup>(5)</sup>.

#### REFERENCES

- Schmale GA, Conrad EU 3rd, Raskind WH. The natural history of hereditary multiple exostoses. *J Bone Joint Surg Am* 1994;76:986-992.
- Kivioja A, Hervasti H, Kinnunen J, Kaitila I, Wolf M, Böhlng T. Chondrosarcoma in a family with multiple hereditary exostoses. *J Bone Joint Surg Br* 2000;82:261-266.
- Taniguchi K. A practical classification system for multiple cartilaginous exostosis in children. *J Pediatr Orthop* 1995;15:585-591.
- Ostlere SJ, Gold RH, Mirra JM, Perlman RD. Case report 658: Chondrosarcoma of the proximal phalanx of right fourth finger secondary to multiple hereditary exostoses (MHE). *Skeletal Radiol* 1991;20:145-148.
- Solomon L. Chondrosarcoma in hereditary multiple exostosis. *South Afr Med J* 1974;48:671-676.
- Bovéé JVMG, Sakkers RJB, Geirnaerd MJA, Taminiu AHM, Hogendoorn PCW. Intermediate grade osteosarcoma and chondrosarcoma arising in an osteochondroma. A case report of a patient with hereditary multiple exostoses. *J Clin Pathol* 2002;55:226-229.
- Kilpatrick SE, Pike EJ, Ward WG, Pope TL. Dedifferentiated chondrosarcoma in patients with multiple osteochondromatosis: report of a case and review of the literature. *Skeletal Radiol* 1997;26:370-374.
- Merchan ECR, Sanchez-Herrera S, Gonzalez JM. Secondary chondrosarcoma. Four cases and review of the literature. *Acta Orthop Belg* 1993;59:76-80.