

cyclophosphamide, adriamycin, vincristine, and prednisone. Another PET/CT study, conducted six months later, showed no evidence of disease (Figure 1D).

Hepatic lymphomas are classified as primary or secondary⁽¹⁾. Secondary lymphomas are due to disseminated lymphoproliferative disease, and the reported incidence of secondary non-Hodgkin lymphoma is 16–22%. Primary lymphomas are rare, accounting for only 0.01% of all cases of non-Hodgkin lymphoma^(1,2).

The diagnostic criteria for primary hepatic lymphoma vary in the literature, the most widely used criteria being those proposed by Lei et al.⁽¹⁾: absence of distal lymphadenopathy; absence of bone marrow infiltration or peripheral blood leukocytosis; and laboratory abnormalities related to liver involvement. Caccamo et al.⁽²⁾ included the absence of extrahepatic disease for at least six months after diagnosis. However, some authors have also classified patients with associated regional lymph node disease, splenomegaly, and bone marrow infiltration as having primary hepatic lymphoma, those features being considered indicative of regional extrahepatic evolution^(3–5). The etiology is poorly understood, and there have been reports of cases related to viral infections, such as HIV infection, Epstein-Barr virus infection, and hepatitis, as well as to cirrhosis, prior chemotherapy, and primary biliary cirrhosis^(1,6). The usual symptoms are those associated with involvement of the liver parenchyma, such as jaundice, abdominal pain, and hepatomegaly⁽¹⁾, similar to those of primary lymphoma described in the literature^(1,3,7) and well characterized in our patient due to a common bile duct obstruction. Fever, weight loss, and night sweats, also known as “B symptoms”, may be present but are not the rule⁽¹⁾. Elevated levels of canalicular enzymes is a common laboratory finding⁽¹⁾.

The imaging features of primary lymphomas are nonspecific and may be similar to those of other more common liver tumors, such as cholangiocarcinoma⁽⁸⁾. High-grade lymphomas usually show restricted diffusion on MRI, similar to what was observed in our patient but also seen in some infectious processes, such as abscess and fungal infections, in patients who are immunocompromised⁽⁸⁾, which our patient was not.

According to the current criteria in the literature, our patient had aspects indicative of primary and secondary hepatic lymphoma. Although the biopsy of an enlarged retroperitoneal lymph node was negative for malignancy, the PET/CT scan showed retroperitoneal fluorodeoxyglucose uptake. Although the diagnosis can be made through needle biopsy, it is often made after surgical resection. The standard treatment is systemic chemotherapy^(6,8).

REFERENCES

1. Lei KI, Chow JH, Johnson PJ. Aggressive primary hepatic lymphoma in Chinese patients. Presentation, pathologic features, and outcome. *Cancer*. 1995;76:1336–43.
2. Caccamo D, Pervez NK, Marchevsky A. Primary lymphoma of the liver in the acquired immunodeficiency syndrome. *Arch Pathol Lab Med*. 1986;110:553–5.
3. Osborne BM, Butler JJ, Guarda LA. Primary lymphoma of the liver. Ten cases and a review of the literature. *Cancer*. 1985;56:2902–10.
4. Anthony PP, Sarsfield P, Clarke T. Primary lymphoma of the liver: clinical and pathological features of 10 patients. *J Clin Pathol*. 1990;43:1007–13.
5. Scoazec JY, Degott C, Brousse N, et al. Non-Hodgkin's lymphoma presenting as a primary tumor of the liver: presentation, diagnosis and outcome in eight patients. *Hepatology*. 1991;13:870–5.
6. Ugurluer G, Miller RC, Li Y, et al. Primary hepatic lymphoma: a retrospective, multicenter rare cancer network study. *Rare Tumors*. 2016;8:6502.
7. Steller EJ, van Leeuwen MS, van Hillebergersberg R, et al. Primary lymphoma of the liver – a complex diagnosis. *World J Radiol*. 2012;4:53–7.
8. Tomasian A, Sandrasegaran K, Elsayes KM, et al. Hematologic malignancies of the liver: spectrum of disease. *Radiographics*. 2015;35:71–86.

Gustavo Gomes Mendes^{1,a}, Leonardo Verza^{1,b}, Tércia Neves^{1,c}, Eduardo Nóbrega Pereira Lima^{1,d}, Rubens Chojniak^{1,e}

1. A.C.Camargo Cancer Center, São Paulo, SP, Brazil.

Correspondence: Dr. Leonardo Verza. A.C.Camargo Cancer Center – Departamento de Imagem. Rua Professor Antônio Prudente, 211, Liberdade. São Paulo, SP, Brazil, 01509-010. Email: leoverza9@gmail.com.

a. <https://orcid.org/0000-0001-5630-7966>; b. <https://orcid.org/0000-0002-1287-6056>; c. <https://orcid.org/0000-0002-9209-0300>; d. <https://orcid.org/0000-0003-1608-6964>; e. <https://orcid.org/0000-0002-8096-252X>.

Received 10 August 2017. Accepted after revision 9 October 2017.

<http://dx.doi.org/10.1590/0100-3984.2017.0134>



Uma causa incomum de bronquiectasias: síndrome de Mounier-Kuhn

Mounier-Kuhn syndrome: an unusual cause of bronchiectasis

Sr. Editor,

Paciente do sexo masculino, 49 anos, não tabagista, apresentou-se com queixas de infecções recorrentes do trato respiratório inferior há seis anos, permanecendo assintomático entre os episódios. No exame físico de entrada o paciente apresentava-se em bom estado geral, pressão arterial de 120 × 80 mm/Hg, ausculta cardíaca normal, frequência cardíaca de 77 bpm, ausculta pulmonar com estertores bolhosos esparsos, frequência respiratória de 18 irpm, saturação de oxigênio em ar ambiente de 93%, abdome normal. Tomografia computadorizada (TC) do tórax em inspiração (Figuras 1A, 1B e 1C) mostrou traqueia e brônquios-fontes dilatados (3,5 e 1,8 cm no diâmetro transversal, respectivamente), além de bronquiectasias nas regiões centrais e basais de ambos os pulmões. Corte obtido em expiração (Figura 1D) demonstrou traqueia e brônquios-fontes parcialmente colapsados. O padrão tomográfico foi considerado diagnóstico de traqueobroncomegalia. Espirometria com resultados pré- e pós-broncodilatador: CVF: 87% e 88%; VEF₁: 69% e 75%, VEF₁/CVF: 64% e 69%, FEF: 44% e 52%. Tratado com corticoides e

broncodilatadores, o paciente encontra-se atualmente em acompanhamento ambulatorial.

A importância das doenças traqueobrônquicas tem sido destacada em artigos recentes^(1–4). Traqueobroncomegalia ou síndrome de Mounier-Kuhn é uma doença rara, observada principalmente em homens de meia idade antes da 5ª década de vida⁽⁵⁾, caracterizada por atrofia ou ausência das fibras elásticas ou da musculatura lisa da parede da traqueia e dos brônquios principais, determinando dilatação dessas estruturas^(6–8). Acredita-se que a fraqueza do tecido conjuntivo, associada à inalação de poluentes atmosféricos e tabagismo, representa o principal fator no desenvolvimento dessa afecção⁽⁶⁾. Com as alterações anatômicas e fisiológicas, as vias aéreas flácidas se alargam durante a inspiração e colapsam durante a expiração⁽⁶⁾; além dessa mudança dinâmica, diverticulose brônquica ou traqueal e bronquiectasias são comuns^(7,8).

A apresentação clínica é inespecífica; há acúmulo de secreções, com tosse produtiva, dispneia e infecções de repetição do trato respiratório inferior. Mais raramente, hemoptise ou pneumotórax podem ser observados^(6–8). O diagnóstico é realizado por métodos de imagem. A TC com imagens da traqueia e dos brônquios principais obtidas em inspiração e expiração é o

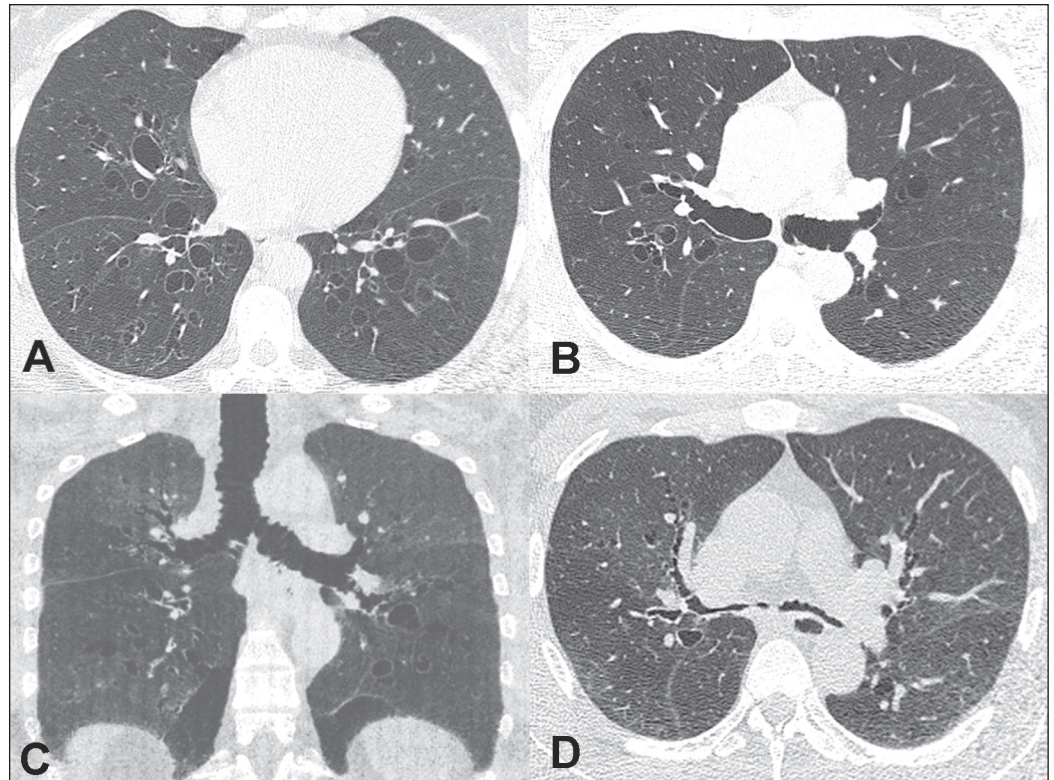


Figura 1. A,B: TC do tórax em inspiração mostrando bronquiectasias bilaterais, além de acentuada dilatação dos brônquios principais. C: Reconstrução coronal mostrando, além das bronquiectasias, dilatação tanto dos brônquios principais como da traqueia. D: Corte obtido em expiração identificando colapso quase completo da árvore brônquica.

exame mais sensível^(7,8). O tratamento é geralmente de suporte, com fisioterapia respiratória, antibioticoterapia adequada para as infecções recorrentes e cessação do tabagismo^(9,10).

Em conclusão, a síndrome de Mounier-Kuhn deve ser considerada em pacientes que apresentam bronquiectasias associadas a dilatação anormal da traqueia e dos brônquios principais na TC do tórax.

REFERÊNCIAS

1. Togni Filho PH, Casagrande JLM, Lederman HM. Utility of the inspiratory phase in high-resolution computed tomography evaluations of pediatric patients with bronchiolitis obliterans after allogeneic bone marrow transplant: reducing patient radiation exposure. *Radiol Bras.* 2017;50:90–6.
2. Duarte ML, Brito MCB, Traple FAL, et al. Plasmacytoma of the trachea: a surprising diagnosis. *Radiol Bras.* 2017;50:66–7.
3. Torres PPTS, Rabahi M, Pinto AS, et al. Primary tracheobronchial amyloidosis. *Radiol Bras.* 2017;50:267–8.
4. Brito MCB, Ota MK, Leitão Filho FSS, et al. Radiologist agreement on the quantification of bronchiectasis by high-resolution computed tomography. *Radiol Bras.* 2017;50:26–31.
5. Woodring JH, Howard RS 2nd, Rehm SR. Congenital tracheobronchomegaly (Mounier-Kuhn syndrome): a report of 10 cases and review of the literature. *J Thorac Imaging.* 1991;6:1–10.

6. Menon B, Aggarwal B, Iqbal A. Mounier-Kuhn syndrome: report of 8 cases of tracheobronchomegaly with associated complications. *South Med J.* 2008;101:83–7.
7. Shin MS, Jackson RM, Ho KJ. Tracheobronchomegaly (Mounier-Kuhn syndrome): CT diagnosis. *AJR Am J Roentgenol.* 1988;150:777–9.
8. Marchiori E, Sousa AS Jr, Zanetti G, et al. Mounier-Kuhn syndrome: the role of bronchiectasis in clinical presentation. *Ann Thorac Med.* 2012;7:51.
9. Collard P, Freitag L, Reynaert MS, et al. Respiratory failure due to tracheobronchomalacia. *Thorax.* 1996;51:224–6.
10. Falconer M, Collins DR, Feeney J, et al. Mounier-Kuhn syndrome in an older patient. *Age Ageing.* 2008;37:115–6.

Rômulo Florêncio Tristão Santos^{1,a}, Tiago Kojun Tibana^{1,b}, Isa Félix Adôrno^{1,c}, Edson Marchiori^{2,d}, Thiago Franchi Nunes^{1,e}

1. Universidade Federal de Mato Grosso do Sul (UFMS), Campo Grande, MS, Brasil. 2. Universidade Federal do Rio de Janeiro (UFRJ), Rio de Janeiro, RJ, Brasil.

Correspondência: Dr. Edson Marchiori. Rua Thomaz Cameron, 438, Valparaíso. Petrópolis, RJ, Brasil, 25685-120. E-mail: edmarchiori@gmail.com.

a. 0000-0002-8679-7369; b. 0000-0001-5930-1383; c. 0000-0002-2106-1211; d. 0000-0001-8797-7380; e. 0000-0003-0006-3725.

Recebido para publicação em 19/9/2017. Aceito, após revisão, em 9/10/2017.

<http://dx.doi.org/10.1590/0100-3984.2017.0167>



Gorham-Stout syndrome: the radiologic-pathologic correlation as a diagnostic pathway when bone is vanishing

Dear Editor,

A 34-year-old previously healthy man presented with a 12-month history of progressive polyarthralgia and edema of the hips, right ankle, and intercostal spaces. He reported no history of trauma. Conventional radiography revealed several mixed lesions (predominantly osteolytic lesions) in the pelvic ring,

proximal femur, distal femur, distal tibia, both tali, and lumbar vertebral bodies, as well as unconsolidated fractures of the costal arches, with no periosteal reaction or associated soft tissue changes (Figure 1). The initial hypotheses of multifocal osteolysis were secondary osteolytic conditions such as infection, cancer (primary or metastatic), inflammatory disorders, and endocrine disorders. The results of laboratory tests (complete blood count, protein profiles, parathyroid hormone level, ionic calcium level, and phosphate level) were normal, as were those