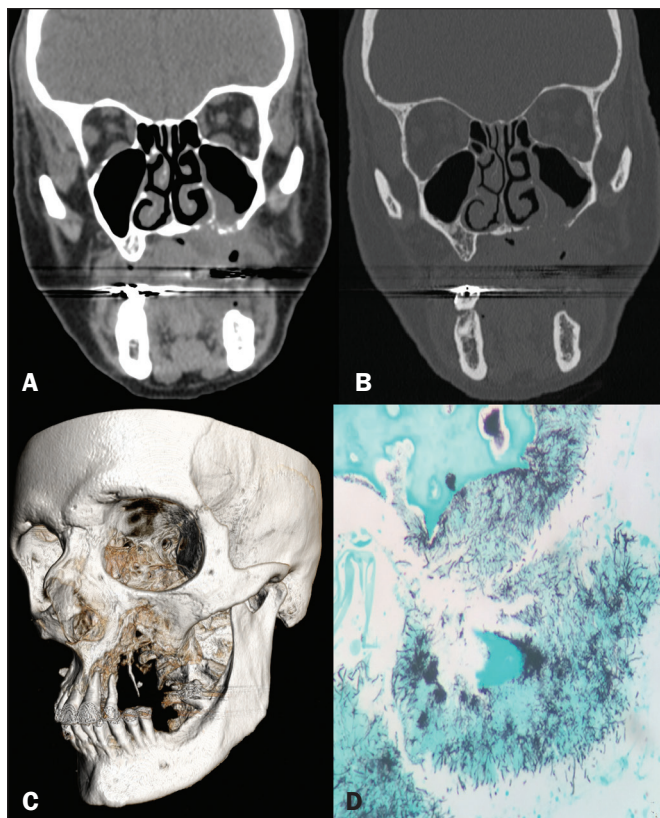

**Figure 1.** Computed tomography of the facial sinuses, with a soft-tissue window (A) and a bone window (B), reconstructed in the coronal plane, showing a soft-tissue density lesion eroding the maxilla, the floor of the maxillary sinus, and the left side of the palate, as well as forming a fistula from the oral cavity to the nasal cavity and to the left maxillary sinus. Three-dimensional reconstruction of a computed tomography scan (C), showing bone erosion in the maxilla and left palate. Grocott's staining (D) showing colonies of filamentous *Actinomyces* bacteria interspersed with bone tissue (magnification,  $\times 400$ ).

and the abdomen/pelvis (in 20%). However, within the cervicofacial region, the maxilla is the least commonly affected site, accounting for only 0.5–9.0% of cases in the head and neck. Bone involvement is even more rare, osteomyelitis being sporadic or secondary to infection at primary sites<sup>(2-4)</sup>. Risk factors for cervicofacial involvement include inadequate oral hygiene, trauma to the oral mucosa, chronic tonsillitis, otitis, mastoiditis, and osteonecrosis induced by radiotherapy or bisphosphonates. It is of note that, different than what is observed for the other affected sites, cervicofacial infection with *Actinomyces* sp. occurs more commonly in patients who are immunocompetent<sup>(2,3)</sup>.

In its acute form, actinomycosis usually manifests as edema of the soft tissues, together with the formation of masses and

abscesses, evolving, chronically, to dissemination of the infection to the adjacent soft tissues, then the fascial planes, externalizing itself through fistulas of the skin and paranasal sinuses. However, it is rarely seen in combination with osteomyelitis<sup>(3)</sup>.

On computed tomography, actinomycosis appears as a mass with ill-defined borders, soft-tissue density, and contrast enhancement, together with fluid collections and fistulas. The differential diagnosis includes fungal ulcers, carcinoma, idiopathic midline granuloma, and osteomyelitis of the maxilla caused by other germs<sup>(5)</sup>. In the histopathological analysis, hematoxylin-eosin staining reveals chronic abscess with polymorphonuclear leukocytes, granulation tissue and fibrosis, Grocott's staining revealing colonies of bacilli forming "sulfur granules", which represent tangled filaments of *Actinomyces*, present in abscesses, exudates of the sinus tract, or tissues infiltrated by the lesions<sup>(3,6)</sup>.

Penicillin G is the drug of choice for the treatment of actinomycosis, requiring long courses of antibiotic therapy. Surgical management is reserved for the drainage of bulky abscesses, marsupialization of chronically infected sinus tracts, excision of fibrotic lesions, and debridement of necrotic bone tissue<sup>(2)</sup>.

Therefore, despite its rarity, it is important to bear actinomycosis of the maxilla in mind as a differential diagnosis, mainly in cases of aggressive lesions of the mouth related to the above-mentioned predisposing factors.

#### REFERENCES

1. Crossman T, Herold J. Actinomycosis of the maxilla – a case report of a rare oral infection presenting in general dental practice. *Br Dent J.* 2009;206:201–2.
2. Valour F, Sénéchal A, Dupieux C, et al. Actinomycosis: etiology, clinical features, diagnosis, treatment, and management. *Infect Drug Resist.* 2014;7:183–97.
3. Heo SH, Shin SS, Kim JW, et al. Imaging of actinomycosis in various organs: a comprehensive review. *Radiographics.* 2014;34:19–33.
4. Sezer B, Akdeniz BG, Günbay S, et al. Actinomycosis osteomyelitis of the jaws: report of four cases and a review of the literature. *Journal of Dental Sciences.* 2017;12:301–7.
5. Meethal AC, Pattamparambath M, Balan A, et al. Actinomycotic osteomyelitis of the maxilla – a delusive presentation. *J Clin Diagn Res.* 2016;10:ZJ01–3.
6. Elder DE, Elenitsas R, Johnson BL Jr, et al. *Lever's histopathology of the skin.* 10th ed. Philadelphia, PA: Lippincott Williams & Wilkins; 2009.

Lívia de Oliveira Antunes<sup>1</sup>, Rafael da Silveira Borges<sup>1</sup>, Wania Vasconcelos de Freitas<sup>1</sup>, Simone Rachid de Souza<sup>2</sup>, Diogo Goulart Corrêa<sup>3</sup>

1. Hospital Casa de Portugal, Rio de Janeiro, RJ, Brazil. 2. Hospital Federal do Andaraí, Rio de Janeiro, RJ, Brazil. 3. Hospital Casa de Portugal e Universidade Federal do Rio de Janeiro (UFRJ), Rio de Janeiro, RJ, Brazil. Correspondence: Dra. Lívia de Oliveira Antunes. Rua Gustavo Sampaio, 88, ap. 902, Leme. Rio de Janeiro, RJ, Brazil, 22010-010. E-mail: li\_antunes@hotmail.com.

<http://dx.doi.org/10.1590/0100-3984.2017.0062>



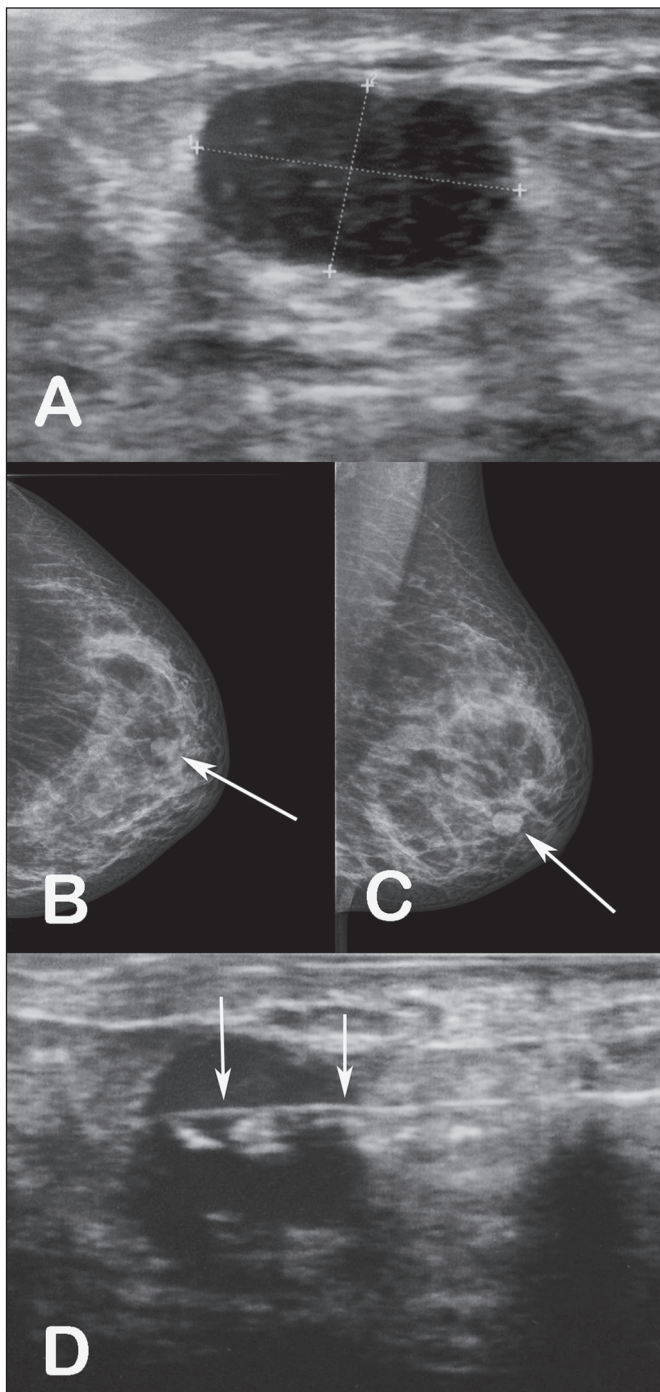
#### Tubular adenoma of the breast: radiological and ultrasound findings

Dear Editor,

A 34-year-old female patient presented to the breast diagnostic clinic with a palpable nodule in the lower outer quadrant of the left breast. Ultrasound showed a solid, hypoechoic, well-circumscribed nodule, measuring 12 × 8 mm, in the lower outer quadrant of the left breast (Figure 1A). The nodule had not been visible on an ultrasound examination performed a year earlier. Mammography revealed a well-circumscribed, isodense nodule,

measuring 12 mm, in the lower outer quadrant of the left breast (Figures 1B and 1C), corresponding to the lesion observed on ultrasound. A percutaneous core biopsy was performed (Figure 1D), the histopathological analysis of which showed tubular adenoma of the breast, consistent with the radiological and ultrasound findings. Therefore, it was recommended that the patient undergo another ultrasound examination in six months and be followed in the breast disease department.

Tubular adenoma of the breast is a rare benign epithelial tumor of the breast that has not been widely studied; the World



**Figure 1.** **A:** Ultrasound showing a well-circumscribed, hypoechoic nodule, measuring 12 × 8 mm, in the lower outer quadrant of the left breast. **B,C:** Mammography, in craniocaudal and mediolateral oblique views, respectively, showing a well-circumscribed, isodense nodule, measuring 12 mm, in the lower outer quadrant of the left breast. **D:** Ultrasound-guided percutaneous core biopsy of the nodule. The arrows indicate the needle within the nodule.

Health Organization defines it as a “benign, usually round, nodules formed by a compact proliferation of tubular structures composed of typical epithelial and myoepithelial cell layers”<sup>(1,2)</sup>.

Although four cases of malignant transformation of tubular adenoma have been reported in the literature, studies indicate that there is no high risk for carcinoma<sup>(1)</sup>. Tubular adenoma

accounts for 0.13–1.7% of all benign neoplasms of the breast<sup>(3)</sup>. Although the size of the tumor ranges from 1 cm to 7.5 cm, it rarely exceeds 5 cm<sup>(4)</sup>. The vast majority of cases are in young women, and the disease is much more rare in postmenopausal women, 90% of the patients being under 40 years of age (mean, 31 years). Nevertheless, there have been reports of its occurrence in males. It has not been found to be associated with oral contraceptive use or pregnancy<sup>(4,5)</sup>. It is considered a variant of fibroadenoma, appearing in the same clinical context and with overlapping imaging characteristics<sup>(6)</sup>. It can be difficult to make the histological differentiation between tubular adenoma and fibroadenoma if the tubular adenoma has a relatively abundant stromal component or the fibroadenoma shows significant proliferation of small ducts<sup>(1)</sup>.

Clinically, tubular adenomas of the breast can be asymptomatic, occasionally being detected on mammography or physical examination as a palpable nodule that gradually increases in size<sup>(4)</sup>. On mammography and ultrasound, these tumors have the appearance of noncalcified fibroadenomas<sup>(7)</sup>. On mammography, the lesions typically appear as well-circumscribed nodules, with no evidence of calcifications. However, in older patients, punctate or irregular calcifications can be observed, findings that justify a biopsy to exclude malignant neoplasm of the breast. Occasionally, mammography shows lesions with ill-defined margins. On ultrasound, the tumors are generally described as hypoechoic, well-circumscribed nodules. Noncalcified tubular adenomas generally have a relatively homogeneous internal texture and may have posterior acoustic reinforcement<sup>(4)</sup>. Other differential diagnoses that should be included are ductal adenomas, lactating adenoma, gestational hyperplasia, and ductal carcinoma<sup>(8)</sup>. Sengupta et al.<sup>(3)</sup>, analyzing 32 confirmed cases of tubular adenoma, concluded that, although radiological and cytological studies can distinguish between benign and malignant lesions, the final diagnosis depends on the histopathology<sup>(3)</sup>.

#### REFERENCES

1. Saimura M, Anan K, Mitsuyama S, et al. Ductal carcinoma in situ arising in tubular adenoma of the breast. *Breast Cancer*. 2015;22:428–31.
2. Persaud V, Talerman A, Jordan R. Pure adenoma of the breast. *Arch Pathol*. 1968;86:481–3.
3. Sengupta S, Pal S, Biswas BK, et al. Preoperative diagnosis of tubular adenoma of breast – 10 years of experience. *N Am J Med Sci*. 2014;6:219–23.
4. Irshad A, Ackerman SJ, Pope TL, et al. Rare breast lesions: correlation of imaging and histologic features with WHO classification. *Radiographics*. 2008;28:1399–414.
5. Zuhair AR, Maron AR. Tubular adenoma of the breast: a case report. *Case Reports in Clinical Medicine*. 2014;3:323–6.
6. Salemis NS, Gemenetzi G, Karagkiouzis G, et al. Tubular adenoma of the breast: a rare presentation and review of the literature. *J Clin Med Res*. 2012;4:64–7.
7. Krishna Reddy C, Mahesh Kumar K, Indira V, et al. Tubular adenoma of breast mimicking as fibroadenoma: a rare case presentation. *Sch Acad J Biosci*. 2014;2:894–6.
8. Sengupta S, Pal S, Biswas BK, et al. Evaluation of clinico-radio-pathological features of tubular adenoma of breast: a study of ten cases with histopathological differential diagnosis. *Iran J Pathol*. 2015;10:17–22.

**Rodrigo Amaral Rodrigues<sup>1</sup>, Carmen Lúcia Arantes Pereira Azevedo<sup>1</sup>, Maria Célia Resende Djahjah<sup>1</sup>, Talita Siemann Santos Pereira<sup>1</sup>**

1. Hospital Universitário Clementino Fraga Filho da Universidade Federal do Rio de Janeiro (HUCFF-UFRJ), Rio de Janeiro, RJ, Brazil. Correspondence: Dr. Rodrigo Amaral Rodrigues. Rua Hugo Panasco Alvim, 211, Recreio dos Bandeirantes. Rio de Janeiro, RJ, Brazil, 22795-306. E-mail: rr-amaral@hotmail.com.

<http://dx.doi.org/10.1590/0100-3984.2017.0012>