

# RADIOGRAPHIC IMAGE OF FECAL LOADING IN THE CECUM AS A DIAGNOSTIC SIGN OF ACUTE APPENDICITIS\*

Andy Petroianu<sup>1</sup>

**Abstract** **OBJECTIVE:** Although the radiological features of acute appendicitis are well documented, the value of the plain radiography has not been fully appreciated yet. The present study was aimed at determining the frequency of association between acute appendicitis and a radiological sign characterized as an image of fecal loading in the whole cecum. **MATERIALS AND METHODS:** Plain abdominal radiographs of 100 consecutive adult patients with acute appendicitis proved by surgery and histology were assessed. The presence of fecal loading characterized by hypotransparency in the whole cecum, and sometimes also in the ascending colon, was observed. **RESULTS:** The image of fecal loading in the cecum was found in 97% of cases of acute appendicitis, independently of age, gender, skin color or stage of appendicitis. **CONCLUSION:** The present study suggests that the presence of radiological images of fecal loading in the cecum may be a useful sign for the diagnosis of acute appendicitis.

*Keywords:* Appendicitis; Radiography; Cecum; Fecal loading; Diagnosis.

**Resumo** *Imagem radiográfica de acúmulo fecal no ceco, como sinal diagnóstico de apendicite aguda.*

**OBJETIVO:** Apesar de os achados radiográficos de apendicite aguda serem bem documentados, o valor da radiografia simples ainda não foi completamente determinado. O objetivo do presente estudo foi estabelecer a frequência da associação de apendicite aguda a um sinal radiográfico caracterizado por imagem de acúmulo fecal ocupando todo o ceco. **MATERIAIS E MÉTODOS:** Foram realizadas radiografias simples de abdome de 100 pacientes consecutivos com apendicite aguda, comprovada por operação e exame anatomopatológico. Pesquisou-se, nas radiografias, a presença de imagem de acúmulo fecal no ceco, caracterizada por hipotransparência ocupando todo o ceco e, eventualmente, também o cólon ascendente. **RESULTADOS:** A imagem de acúmulo fecal no ceco foi encontrada em 97% dos doentes, independentemente de idade, sexo, cor da pele ou estágio da apendicite. **CONCLUSÃO:** Este estudo sugere que a presença de imagem radiográfica de acúmulo fecal no ceco pode ser um sinal útil no diagnóstico de apendicite aguda.

*Unitermos:* Apendicite; Radiografia; Ceco; Acúmulo fecal; Diagnóstico.

## INTRODUCTION

Abdominal pain in the right lower quadrant is probably one of the most challenging problems in medicine<sup>(1)</sup>. In the majority of patients, acute appendicitis is diagnosed on the basis of clinical examination, leukocyte count, abdominal radiographic studies, and abdominal ultrasound<sup>(1,2)</sup>. However, possible inaccuracy of these

studies and tests may lead to a high rate of misdiagnosis which, according to the literature, results in up to 15% of unnecessary appendicectomies<sup>(1,3,4)</sup>. In order to avoid misdiagnosis, more expensive and sophisticated diagnostic methods such as computed tomography and scintigraphy have been proposed although not presenting any diagnostic advantage in cases of the so called right-sided pain<sup>(2)</sup>.

In the presence of acute abdomen, the plain abdominal radiograph on anteroposterior view, remains considered as relevant and extremely useful, but little significance has been attributed to this method as a complementary study for the diagnosis of acute appendicitis. Main findings of this diagnostic method are: adynamic ileus (51–81% of cases), increase in soft-tissue density in the right-lower quadrant (12–33%), appendicoliths (7–14%), and deformity of the cecum (4–5%)<sup>(1-3,5-9)</sup>.

The objective of the present study was to evaluate a new radiographic sign ob-

served in patients with acute appendicitis: the image of fecal loading in the cecum.

## MATERIALS AND METHODS

The present study was approved by the Committee of Ethics of Faculty of Medicine Surgery Department, and by the Committee of Ethics in Human Research of Universidade Federal de Minas Gerais (UFMG).

The sample of the present study included 100 consecutive patients (62 men and 38 women) with ages ranging between 10 and 73 years, submitted to surgery for acute appendicitis confirmed by transoperative study and anatomopathological evaluation. These patients were attended at the Emergency Sector of UFMG Clinics Hospital, Instituto Alfa de Gastroenterologia of UFMG Clinics Hospital, and Hospital Júlia Kubitschek in Belo Horizonte.

The research consisted in analyzing plain abdominal radiographies (anteroposterior view), obtained as a routine in those

\* Study developed at Instituto Alfa de Gastroenterologia – Hospital das Clínicas da Universidade Federal de Minas Gerais (UFMG), Belo Horizonte, MG, Brazil.

1. Titular Professor, Department of Surgery at Faculty of Medicine – Universidade Federal de Minas Gerais (UFMG), Belo Horizonte, MG, Associate Professor in Surgical Technique and Experimental Surgery, Universidade Federal de São Paulo/Escola Paulista de Medicina (Unifesp/EPM), São Paulo, SP, Associate Professor in Surgical Gastroenterology, Faculdade de Medicina de Ribeirão Preto – Universidade de São Paulo (FMRP-USP), Ribeirão Preto, SP, PhD in Physiology and Pharmacology, Instituto de Ciências Biológicas – Universidade Federal de Minas Gerais (UFMG), Belo Horizonte, MG, Brazil, Researcher IA for CNPq.

Mailing address: Prof. Dr. Andy Petroianu. Avenida Afonso Pena, 1626, ap. 1901. Belo Horizonte, MG, Brazil, 30130-005. E-mail: petroian@medicina.ufmg.br

Received August 11, 2006. Accepted after revision October 11, 2006.

institutions for investigating patients with acute abdomen. All of these studies were performed in a less-than-24-hour period before the surgical procedure, and with no previous intestinal preparation, to investigate the presence of hypotransparent images of intracecal mass intermixed with hypertransparent bubbles characteristic of fecal loading. This sign was considered as positive when the hypotransparent image extended throughout the cecum and, sometimes, also the ascending colon. The size of this image was not taken into consideration since in some cases the cecum presented with normal dimensions, while in other situations it was found dilated due to the fecal loading.

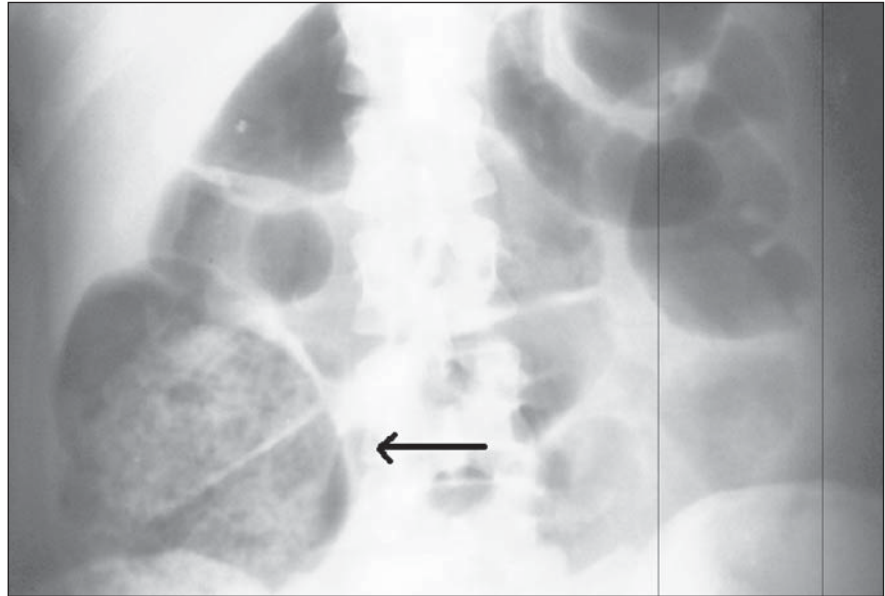
## RESULTS

There was no difficulty in the development of the present study, since radiographies were part of the routine diagnostic workup of patients with acute abdomen. The stage of appendicular involvement ranged from an initial edematous appendicitis to advanced appendicitis, with necrosis, perforation and peritonitis.

The presence of radiographic image of fecal loading in the cecum was observed in 97% of the cases, independently of the disease stage. In some cases, dilatation of the cecum was found as a result of the higher amount of feces in the cecum (Figure 1). In some cases, the image of the fecal loading extended up to the hepatic angle of the colon.

## DISCUSSION

Although a few studies suggest that plain abdominal radiography is not helpful in the diagnosis of acute abdomen, this diagnostic method remains as part of the routine practice in the majority of medical emergency services<sup>(1-3,5-9)</sup>. However, radiographic signs described in the literature are not steadily found or characteristic of appendicitis. This lack of specificity raises doubts about the inclusion of the abdominal radiography in the routine diagnostic workup in the suspect of acute appendicitis<sup>(1,2)</sup>. Also, it must be noted that ultra-



**Figure 1.** Plain abdominal radiograph - anteroposterior view of patient with acute appendicitis. Observe fecal loading in the cecum (arrow).

sound and computed tomography started being considered as more sensitive methods for diagnosing acute appendicitis<sup>(10,11)</sup>.

In the present prospective study with consecutive patients, the image of fecal loading in the cecum presented a sensitivity of 97%. The frequency of this sign is higher than the frequency of other signs included as part of the clinical, laboratory and even imaging workups for patients with acute appendicitis.

The results of the present study seem to demonstrate that the finding of fecal loading in the cecum on plain abdominal radiographs may be a sign associated with acute appendicitis. Further research is necessary to confirm the sensitivity of this sign, and to determine its specificity for acute appendicitis in relation to other inflammatory, right-sided abdominal conditions.

## Acknowledgment

The author would like to thank Doctor Luiz Ronaldo Alberti – Hospital Júlia Kubitschek for his help in the data collection for the present study.

## REFERENCES

1. Boleslawski E, Panis Y, Benoist S, Denet C, Mariani P, Valleur P. Plain abdominal radiography as a routine procedure for acute abdominal pain of

the right lower quadrant: prospective evaluation. *World J Surg* 1999;23:262–264.

2. Rao PM, Rhea JT, Rao JA, Conn AKT. Plain abdominal radiography in clinically suspected appendicitis: diagnostic yield, resource use, and comparison with CT. *Am J Emerg Med* 1999;17:325–328.
3. Thorpe JAC. The plain abdominal radiograph in acute appendicitis. *Ann R Coll Surg Engl* 1979;61:45–47.
4. Petroianu A, Oliveira Neto JE. Prevalence of acute appendicitis in a mixed population. *Dig Surg* 1997;14:195–197.
5. Shimkin PM. Radiology of acute appendicitis. *AJR Am J Roentgenol* 1978;130:1001–1004.
6. Marincek B. Nontraumatic abdominal emergencies: acute abdominal pain: diagnostic strategies. *Eur Radiol* 2002;12:2136–2150.
7. Bondrager KL. Abdome e procedimentos contrastados comuns. In: Bondrager KL, editor. *Técnica radiológica e bases anatómicas*. 3ª ed. Rio de Janeiro, RJ: Guanabara Koogan, 2003;211–250.
8. Sivit CJ. Imaging the child with right lower quadrant pain and suspected appendicitis: current concepts. *Pediatr Radiol* 2004;34:447–453.
9. Oncel M, Degirmenci B, Demirhan N, Hakyemez B, Altuntas YE, Aydinli M. Is the use of plain abdominal radiographs (PAR) a necessity for all patients with suspected acute appendicitis in emergency services? *Curr Surg* 2003;60:296–300.
10. Pinto Leite N, Pereira JM, Cunha R, Pinto P, Sirlin C. CT evaluation of appendicitis and its complications: imaging techniques and key diagnostic findings. *AJR Am J Roentgenol* 2005;185:406–417.
11. Mun S, Ernst RD, Chen K, Oto A, Shah S, Mileski WJ. Rapid CT diagnosis of acute appendicitis with IV contrast material. *Emerg Radiol* 2006;12:99–102.