



REVISTA BRASILEIRA DE ANESTESIOLOGIA

Official Publication of the Brazilian Society of Anesthesiology
www.sba.com.br



SCIENTIFIC ARTICLE

Ultrasound and nerve stimulator guided continuous femoral nerve block analgesia after total knee arthroplasty: a multicenter randomized controlled study

Fen Wang^a, Li-Wei Liu^a, Zhen Hu^a, Yong Peng^a, Xiao-Qing Zhang^b, Quan Li^{a,*}

^a Department of Anesthesiology, Shanghai Tenth People's Hospital, Tongji University School of Medicine, Shanghai, China

^b Department of Anesthesiology, Tongji Hospital, Tongji University School of Medicine, Shanghai, China

Received 23 May 2013; accepted 9 July 2013

Available online 29 October 2013

KEYWORDS

Arthroplasty;
Replacement;
Knee;
Ultrasound;
Nerve stimulator;
Continuous femoral
nerve block

Abstract

Background and objectives: Postoperative analgesia is crucial for early functional excise after total knee arthroplasty. To investigate the clinical efficacy of ultrasound and nerve stimulator guided continuous femoral nerve block analgesia after total knee arthroplasty.

Methods: 46 patients with ASA grade I–III who underwent total knee arthroplasty received postoperative analgesia from October 2012 to January 2013. In 22 patients, ultrasound and nerve stimulator guided continuous femoral nerve block were performed for analgesia (CFNB group); in 24 patients, epidural analgesia was done (PCEA group). The analgesic effects, side effects, articular recovery and complications were compared between two groups.

Results: At 6 h and 12 h after surgery, the knee pain score (VAS score) during functional tests after active exercise and after passive excise in CFNB were significantly reduced when compared with PCEA group. The amount of parecoxib used in CFNB patients was significantly reduced when compared with PCEA group. At 48 h after surgery, the muscle strength grade in CFNB group was significantly higher, and the time to ambulatory activity was shorter than those in PCEA group. The incidence of nausea and vomiting in CFNB patients was significantly reduced when compared with PCEA group.

Conclusion: Ultrasound and nerve stimulator guided continuous femoral nerve block provide better analgesia at 6 h and 12 h, demonstrated by RVAS and PVAS. The amount of parecoxib also reduces, the incidence of nausea and vomiting decreased, the influence on muscle strength is compromised and patients can perform ambulatory activity under this condition.

© 2013 Sociedade Brasileira de Anestesiologia. Published by Elsevier Editora Ltda. All rights reserved.

* Corresponding author.

E-mail: liquan0508@yeah.net (Q. Li).

PALAVRAS-CHAVE

Artroplastia;
Substituição;
Joelho;
Ultrassom;
Estimulador de nervo;
Bloqueio femoral
contínuo

Bloqueio contínuo do nervo femoral guiado por ultrassom e estimulador de nervo para analgesia após artroplastia total de joelho: estudo multicêntrico, randomizado e controlado

Resumo

Justificativa e objetivos: Analgesia pós-operatória é fundamental para o exercício funcional precoce logo após a artroplastia total de joelho. O objetivo foi investigar a eficácia clínica do bloqueio contínuo do nervo femoral guiado por ultrassom e estimulador de nervo em analgesia após artroplastia total do joelho.

Métodos: 46 pacientes, estado físico ASA I-III, submetidos à artroplastia total de joelho, receberam analgesia pós-operatória de outubro de 2012 a janeiro de 2013. Em 22 pacientes, o bloqueio femoral contínuo foi guiado por ultrassom e estimulador de nervo para analgesia (grupo BFC); em 24 pacientes, analgesia foi administrada por via epidural (grupo ACP). Os efeitos analgésicos, efeitos colaterais, recuperação articular e complicações foram comparados entre os dois grupos.

Resultados: Às 6 e 12 horas após a cirurgia, os escores de dor no joelho (escore EVA) durante os testes funcionais após exercício ativo e passivo foram significativamente menores no grupo BFC que no grupo ACP. A quantidade usada de parecoxib nos pacientes do grupo BFC foi significativamente menor em comparação com o grupo ACP. Quarenta e oito horas após a cirurgia, o grau de força muscular no grupo BFC foi significativamente maior e o tempo de atividade ambulatoria foi menor que no grupo ACP. A incidência de náusea e vômito em pacientes do grupo BFC foi significativamente menor em comparação ao grupo ACP.

Conclusão: O bloqueio femoral contínuo guiado por ultrassom e estimulador do nervo proporcionaram melhor analgesia às 6 e 12 horas, demonstrada por EVA-R e EVA-P. A quantidade de parecoxib também foi menor, a incidência de náusea e vômito diminuiu, a influência sobre a força muscular é comprometida e os pacientes podem realizar atividade ambulatorial sob essa condição.

© 2013 Sociedade Brasileira de Anestesiologia. Publicado por Elsevier Editora Ltda. Todos os direitos reservados.

Introduction

After total knee arthroplasty (TKA), some patients usually develop moderate to severe joint pain. Postoperative analgesia is crucial for early functional excise after TKA. Although a lot of strategies have been developed for analgesia,^{1,2} the clinical efficacy of these strategies is still poor or their side effects may influence the post-operative articular recovery. Continuous femoral nerve block (CFNB) has been successfully applied in the analgesia after TKA.³ Accurate puncture and catheterization may increase the efficacy of block. In this study, we summarized the results of ultrasound and nerve stimulator guided CFNB and patient control epidural analgesia (PCEA) which were performed after TKA from October 2012 to March 2013 in three hospitals in Shanghai (Tenth People's Hospital, Tongji Hospital and Changzheng Hospital). This was a prospective, randomized, controlled study aiming to compare the analgesic effect of CFNB and PCEA, which may help us to identify a better tool for analgesia.

Materials and methods**General information**

This study was approved by the Institutional Review Board (IRB) of each hospital. Patients receiving TKA were recruited

into this study from October 2012 to March 2013. Exclusion criteria included: patients were unable to sign the informed consent due to problems in language or cognition, patients received epidural block (including patients who refused to participate, with platelet count of $<100 \times 10^9/L$ or coagulation dysfunction) and those had contradictions for CFNB (such as infection at puncture site, a history of femoral popliteal bypass surgery) or administration of drugs used in this study. A total of 45 patients with ASA grade I-III who received unilateral TKA were recruited into present study ($n=25$ in Tenth People's Hospital; $n=10$ in Tongji Hospital; $n=10$ in Changzheng Hospital). These patients were randomly assigned into two groups and received ultrasound and nerve stimulator guided CFNB and PCEA, respectively. There were no marked differences in the demographics of these patients between two groups ($p > 0.05$) (Table 1).

Methods

Venous access was prepared before surgery. Blood pressure, electrocardiogram and pulse oximetry were non-invasively monitored. Patients were asked to lie in a supine position, and the affected hip slightly abducted followed by routine sterilization. In CFNB group, ultrasound (MicroMaxx Ultrasound System, Sonosite S-Nerve, USA) and nerve stimulator (Stimuplex DIG, B.Braun Melsungen AG, Germany) guided CFNB was performed. In brief, intra-plane technique was used. High-frequency ultrasound probe (MicroMaxx

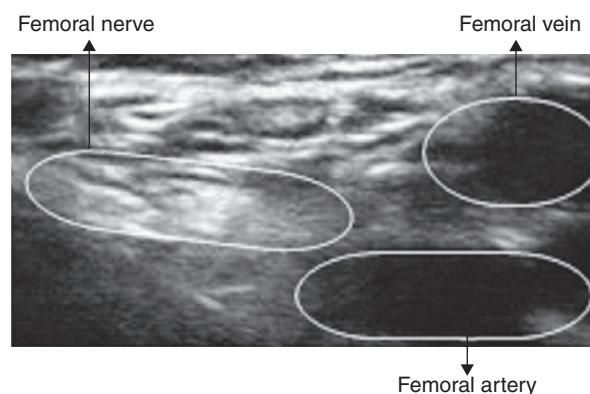
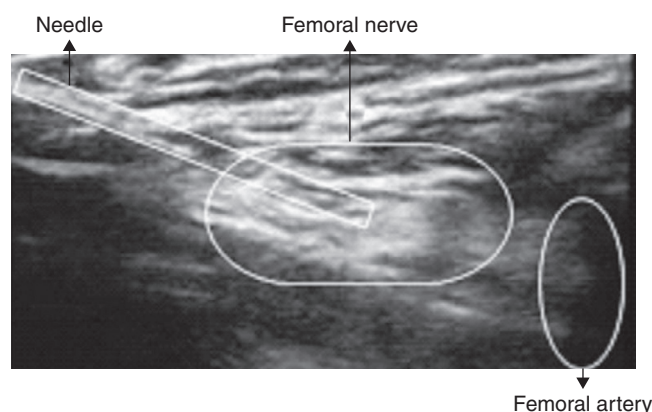
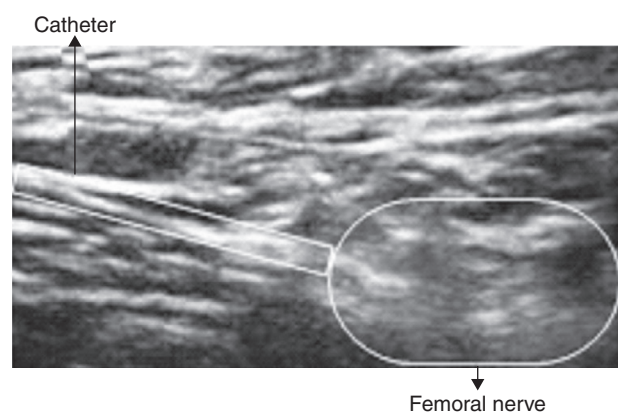
Table 1 Demographics of patients in two groups.

	Age (years)	Male/female		BMI (kg/m ²)	Time of operation (min)
		Male	Female		
CFNB (n=23)	68.08 ± 7.0	8	15	23.7 ± 2.7	86.4 ± 16.8
PCEA (n=22)	66.91 ± 8.6	9	13	23.9 ± 3.0	85.7 ± 17.5
t(x ²)	t=0.52	x ² =0.006		t=-0.76	t=0.64
p	0.98	0.94		0.48	0.57

HFL38x/13-6MHz Transducer) was placed at the middle point of inguinal ligament. The pulsatile annular structure without echo was the femoral artery. The probe moved outward to identify femoral nerve which was oval or triangular in shape and hyperechoic. After localizing femoral nerve, puncture was done toward femoral nerve with continuous plexus block kit (Contiplex D 18G*3", B.Braun, Germany) and the angle between needle and skin was 30. The stimulation current was 1 mA, wave width was 0.3 ms and frequency was 2 Hz. The needle was modified slightly until the quadriceps contracted obviously and/or the patella moved upward. Then, the stimulation current reduced to 0.3–0.5 mA. The presence of contraction of quadriceps suggested that the needle was at the correct site. Before catheterization, 2% lidocaine (4 mL) was injected, and the catheter was 5–7 cm inward. Then, the catheter was fixed when there was no blood during withdrawing. In PCEA group, epidural puncture was done at L₂₋₃ intervertebral space, followed by catheterization. After fixing the catheter, 2% lidocaine (4 mL) was injected. Five minutes later, the anesthetic effect was detected at the affected knee. After surgery, 0.2% ropivacaine (20 mL) was injected via the catheter for analgesia. Then, an analgesia pump was connected (Shanghai Chengyi Industrial Co. Ltd). In CFNB group, 0.2% ropivacaine was injected at a rate of 8 mL/h, the pulse dose of 5 mL and lock-out time of 30 min. In PCEA group, 0.2% ropivacaine was injected at a rate of 5 mL/h, pulse dose of 2 mL and lock-out time of 30 min. At 0.5 h before surgery, intramuscular injection was done with 10 mg of metoclopramide and 2.5 mg of droperidol for prevention of post-operative vomiting and nausea. General anesthesia was done via the laryngeal mask and induction anesthesia was performed with midazolam at 0.02–0.04 mg/kg, fentanyl at 1 μg/kg, propofol at 1–2 mg/kg and sulfonic acid cis-atracurium at 0.15 mg/kg sequentially. Anesthesia was maintained with sevoflurane during surgery. Fentanyl and sulfonic acid cis-atracurium were administered if it was necessary. After surgery, patients were routinely treated with celecoxib (Pfizer, USA). For patients with severe pain, parecoxib (40 mg; Pfizer, USA) was administered intravenously. If non-responsive, morphine was intravenously transfused (Figs. 1–4).

Observations

The operation time in CFNB group was recorded. The operation time referred to the interval from sterilization to the fixation of catheter. In both groups, the anesthetic effect was evaluated according to the response of affected knee

**Figure 1** Before puncture.**Figure 2** After successful puncture.**Figure 3** Catheterization.

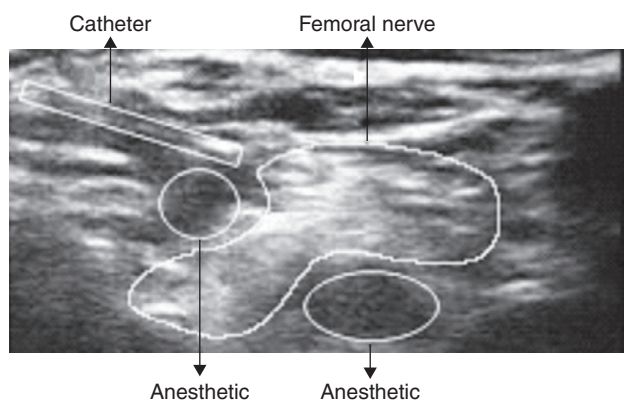


Figure 4 Injection of drugs.

and intact knee to stimulation at 5 min after initial injection of 2% lidocaine: when compared with intact knee with obvious pain, absence of pain suggests favorable anesthesia, reduced pain indicates moderate anesthesia and comparable pain shows poor anesthesia. Visual analog score (VAS) was used for evaluation. At 1 h, 6 h, 12 h, 24 h and 48 h, VAS of affected lower limb at rest (RVAS), after active excise (IVAS) and continuous passive excise (PVAS), the maximal range of motion (ROM), degree of sedation, additional dose of parecoxib and morphine, sleeping condition, muscle strength, side effects (nausea, vomiting, hypotension, chills and limb numbness), time to ambulatory activity, and interval from surgery to discharging were determined. Follow up was done by a physician who was blind to this study.

Statistical analysis

Statistical analysis was done according to SPSS version 20. Quantitative data underwent homogeneity of variance test. Data with homogeneity of variance were expressed as mean \pm standard deviation ($\bar{X} \pm s$). Comparisons between two groups were done with independent *t* test. Data with heterogeneity of variance were expressed as median (maximum, minimum). Comparisons between two groups were performed with Mann-Whitney *U* test. Qualitative data were compared with Person Chi-Square test. The anesthetic effect was compared with Mann-Whitney *U* test. A value of $p < 0.05$ was considered statistically significant.

Results

VAS and recovery

In CFNB group, the mean operation time was 8.3 ± 2.2 min. After injection of 2% lidocaine (4 mL), the anesthetic effect was comparable ($p > 0.05$). In CFNB group, good anesthesia was found in 2 patients and moderate anesthesia in 21. In PCEA group, good anesthesia was found in 1 patient and moderate anesthesia in 21. The injection rate of ropivacaine was 8.1 mL/h in CFNB group, and 5.23 mL/h in PCEA group. In CFNB group, at 6 h and 12 h after surgery, the IVAS and PVAS were better than those in PCEA group. In addition, in CFNB group, at 48 h after surgery, the muscle strength score (4.05 ± 0.84) was significantly higher than that in PCEA group

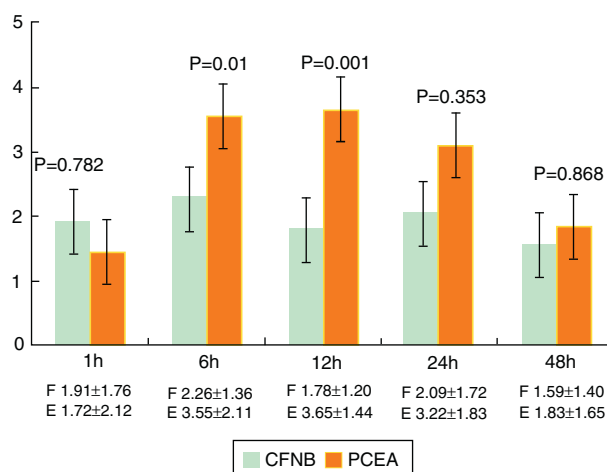


Figure 5 IVAS in two groups. At 6 h and 12 h after surgery, the IVAS in CFNB group was significantly lower than that in PCEA group. CFNB: continuous femoral nerve block; PCEA: patient control epidural analgesia.

(3.50 ± 0.62 , $p = 0.028$). Moreover, the time to ambulatory activity in CFNB group was also shorter than that in PCEA group (40.93 ± 16.04 h vs. 60.55 ± 22.91 h, $p < 0.05$) (Fig. 5).

Additional dose of analgesics

The additional dose of parecoxib was 640 ± 100 mg in CFNB group, and 1000 ± 240 mg in PCEA group, showing marked difference ($\chi^2 = 4.4$, $p = 0.036$). In addition, the additional dose of morphine, the maximal ROM, extent of sedation and sleeping state were comparable between two groups ($p > 0.05$) (Table 2).

Side effects

In PCEA group, side effects were evident, and the incidence of nausea and vomiting was higher than that in CFNB group. However, the incidences of hypertension, chills, and lower limb numbness were comparable between two groups (Table 2).

Discussion

Rehabilitation after TKA is an important determinant of post-operative functional reconstruction of knee. The severe pain during excise is mainly caused by quadriceps spasm. Femoral nerve innervates the skin in front of knee and the quadriceps. Complete femoral nerve block may significantly attenuate the knee pain after TKA, make the quadriceps in a relax status and relieve the excise induced pain of affected limbs after TKA. Continuous femoral nerve block has special advantage in the analgesia after TKA.

Traditionally, blind exploration and nerve stimulator guidance are used for the location of femoral nerve. Blind exploration according to the anatomic markers and abnormal sensation usually fail to identify the diffuse of local anesthetics, and thus the anesthetic effect cannot be assured. Moreover, this procedure may damage the nerve and surrounding blood vessels. Classic nerve stimulator

Table 2 Analgesics, side effects and articular recovery in two groups.

	CFNB (n = 23)	PCEA (n = 22)	p
Mean infusion rate (mL/h)	8.1	5.23	
Parecoxib (mg)	640 ± 100	1000 ± 240	0.036
Morphine (mg)	20 ± 9.5	25 ± 10.0	0.65
Nausea and vomiting (n)	5	14	0.004
Hypotension (n)	1	4	0.141
Chill (n)	2	2	0.963
Foot numbness (n)	1	3	0.274
ROM (°)	40.75 ± 14.52	35.25 ± 18.50	0.351
Muscle power at 48 h	4.05 ± 0.84	3.50 ± 0.62	0.028
Time getting out of the bed (h)	40.93 ± 16.04	60.55 ± 22.91	0.002
Time stay in hospital (days)	12.87 ± 1.96	13.95 ± 1.99	0.08

ROM, range of motion.

guided peripheral nerve block has very high efficiency. Fanelli et al.⁴ and Franco et al.⁵ independently performed prospective studies with a large sample size, and the effective rate was as high as 94% and 98.8%, respectively. However, the efficacy of nerve stimulator is still not optimal, and might cause unpredictable damage to the nerve.⁶ In recent years, the technique of ultrasound guided femoral nerve block is improved significantly. When compared with nerve stimulator, ultrasound can display the nerves and surrounding structures, the anatomic variations, the location of needle and the diffusion and anesthetics.⁷ A meta-analysis showed that guided nerve location has higher success rate as compared to nerve stimulator.⁸ In addition, this procedure is time-consuming, the nerve block is rapidly acquired and the block is long-lasting.⁹ Studies also reveal that this procedure has better block efficiency, reduces the dose of local anesthetics used and decreases the risk for damage to blood vessels.^{10,11} In a systemically retrospective study, the anesthetic effect was compared between ultrasound guided nerve block and traditional nerve stimulator guided nerve block. Results showed that the anesthetic effect was comparable when these procedures were done by experienced physicians.¹² Liu et al.¹³ found that there were no marked differences in the failure rate of nerve block, the degree of satisfaction and the severity of post-operative neurological symptoms after ultrasound and nerve stimulator guided nerve block. This might be attributed to the high success rate of both procedures conducted by experienced physicians, and there is little space for improvement of success rate. Currently, few studies are carried out to investigate ultrasound and nerve stimulator guided femoral nerve block. In the present study, ultrasound and nerve stimulator guided femoral nerve block were performed after TKA, aiming to identify an ideal analgesic method after TKA.

Continuous epidural analgesia has definite effectiveness, and few systemic side effects. It has been widely applied in clinical practice. However, this procedure still causes hypotension, intestinal obstruction, urinary retention, motor block, and walk limitation.¹⁴ To prevent peri-operative deep vein thrombosis in patients receiving TKA, anti-coagulation therapy (such as rivaroxaban) is usually performed at the second day after surgery. Rivaroxaban is an oral medication and specifically, selectively and directly inhibit Xa factor, which then suppresses

the transformation of prothrombin into thrombin preventing thrombosis.¹⁵ After treatment with rivaroxaban, the incidences of total venous thrombosis and major venous thrombosis are lower than those after treatment with enoxaparin.^{16,17} However, meta analysis showed that the mean incidence of bleeding was 7% after rivaroxaban treatment, which was higher than that after enoxaparin treatment.^{16,17} de la Fuente et al.¹⁸ found that there were no thrombosis related complications and death within 30 days after surgery, but the markers of hypercoagulable state reduced to different extents after epidural analgesia. Rivaroxaban treatment increases the possibility of epidural hematoma,¹⁴ which significantly limits the wide application of epidural analgesia.

In the present study, the analgesic effect was compared between patients received ultrasound and nerve stimulator guided continuous femoral nerve analgesia and epidural analgesia after TKA. Results showed the VAS was comparable at 1 h after surgery. This may be attributed to the incomplete disappearance of analgesia induced by general anesthetics, and the analgesic effect of 0.2% ropivacaine reaching a peak. In CFNB group, the VASs during active excise and passive excise at 6 h and 12 h after surgery were markedly lower than those in PCEA group, suggesting that CFNB has better analgesia, especially in relieving motor pain. Under the CFNB, the nerve and needle can be identified, and the catheter can accurately place on the surface of femoral nerve, which assures that the local anesthetics diffuse around the femoral nerve.¹⁹ This may simultaneously block femoral nerve, lateral femoral cutaneous nerve and obturator nerve,¹⁶ which significantly attenuates the rest pain and motion pain of affected limbs. Ultrasound and nerve stimulator have complementary advantages for localization. Nerve puncture was done under visualization and nerve stimulator was used to induce quadriceps contraction and elevation of the patella, which assure the success rate of puncture and significantly shorten the time for puncture.²⁰ In our study, the operation time was 8.3 ± 2.2 min, which was markedly shorter than that under the guidance with nerve stimulator alone²⁰ (11.5 ± 7.0 min). In CFNB group, the VAS was not markedly reduced at 24 h and 48 h after surgery, which may be associated with intense pain due to step-by-step excise. Continuous femoral nerve block may dilate unilateral blood vessels, which improve the blood supply and

is beneficial for the prevention of deep vein thrombosis.²¹ Thus, this procedure is especially suitable for old patients who are usually bedridden and have poor general condition. Generally, 0.2% ropivacaine is used in continuous femoral nerve block, and the maximal dose is no more than 800 mg within 24 h.²² Scott et al.²³ found that the motor nerve block of ropivacaine was positively related to its concentration, and 0.2% ropivacaine could achieve the balance between optimal analgesia and minimal motion block. In continuous femoral nerve block, ropivacaine at a low concentration is usually used, which has definite analgesic effect and little influence on muscle strength. In CFNB group, the muscle strength score at 48 h after surgery was significantly higher than that in PCEA group, and the time to ambulatory activity was also shortened, which reduces the complications related to prolonged bed rest. After TKA, favorable femoral nerve block may provide similar or even better analgesia than epidural analgesia, and have lower incidence of complications.^{24,25} When compared with PCEA group, the favorable femoral nerve block induced analgesia reduced the required dose of parecoxib, which, on one hand, reduce the side effects of analgesics, and on the other hand, attenuate the economic burden of patients.

In CFNB group, the incidence of nausea and vomiting was significantly lower than that in patients receiving epidural analgesia,²⁶ which might be attributed to increased dose of morphine in PCEA group. In addition, bleeding was not observed in two groups, but patients treated with rivaroxaban paid more attention to the epidural analgesia. One patient in CFNB group and 3 patients in PCEA group developed foot numbness on the first day of surgery, which resolved spontaneously, but evident damage to nerves was not observed. Studies with large sample size showed, during the ultrasound and nerve stimulator guided localization for peripheral nerve block, the incidence of toxic events of local anesthetics was 0/9069, and the incidence of nerve injury persistent for more than 1 year was very rare.²⁷ Of note, the ultrasonography is highly dependent on the skill of operators,²⁸ and ultrasound cannot completely abolish the possibility of damage to nerves.²⁹ Thus, physicians still pay attention to the side effects of this procedure.

At 6 h and 12 h after TKA, the VAS in patients receiving ultrasound and nerve stimulator guided continuous femoral nerve block (CFNB) for analgesia was significantly lower than that in patients receiving epidural analgesia, and required smaller amount of parecoxib. In addition, CFNB had less influence on muscle strength and patients receiving CFNB had shorter time to ambulatory activity and lower incidence of nausea and vomiting. Thus, CFNB is an ideal method for analgesia after TKA.

However, the duration of this study was still short, and the long-term effect of analgesia in different ways is required to be closely monitored. Whether CFNB can reduce the damage to nerve is required to be determined in future studies.

Funding

This study was supported financially by the Shanghai Education Committee Key Project (13ZZ024) and Ph.D. Mentor Culture Project (12HBB109).

Conflicts of interest

The authors declare no conflicts of interest.

Acknowledgements

We are grateful to all authors of the publications included in this study for contributing information, as required. The authors declare that there is no conflict of interest.

References

- Hu Y, Geng LC. Efficacy of intravenous analgesia and epidural analgesia after knee arthroplasty: a comparative study. *China Pract Med.* 2011;6:97–8.
- Qian WW, Weng XS, Fei Q. Application study of periarticular multimodal drug injection in total knee arthroplasty. *Natl Med J China.* 2010;90:2593–6.
- Li L, Luo M, Feng J, et al. Effect of continuous femoral nerve block and epidural analgesia on rehabilitation after total knee arthroplasty surgery. *Orthop J China.* 2009;17:1139–41.
- Fanelli G, Casati A, Garancini P, et al. Nerve stimulator and multiple injection technique for upper and lower limb blockade: failure rate, patient acceptance, and neurologic complications. *Study Group on Regional Anesthesia. Anesth Analg.* 1999;88:847–52.
- Franco CD, Vieira ZE. 1001 subclavian perivascular brachial plexus blocks: success with a nerve stimulator. *Reg Anesth Pain Med.* 2000;25:41–6.
- Albrecht E, Niederhauser J, Gronchi F, et al. Transient femoral neuropathy after knee ligament reconstruction and nerve stimulator-guided continuous femoral nerve block: a case series. *Anaesthesia.* 2011;66:850–1.
- Marhofer P, Greher P, Kapral S. Ultrasound guidance in regional anaesthesia. *Br J Anaesth.* 2005;94:7–17.
- Ponde V, Desai AP, Shah D. Comparison of success rate of ultrasound-guided sciatic and femoral nerve block and neurostimulation in children with arthrogryposis multiplex congenita: a randomized clinical trial. *Paediatr Anaesth.* 2013;23:74–8.
- Abrahams MS, Aziz MF, Fu RF, et al. Ultrasound guidance compared with electrical neurostimulation for peripheral nerve block: a systematic review and meta-analysis of randomized controlled trials. *Br J Anaesth.* 2009;102:408–17.
- Marhofer P, Schrögendorfer K, Koinig H, et al. Ultrasonographic guidance improves sensory block and onset time of three-in-one blocks. *Anesth Analg.* 1997;85:854–7.
- Marhofer P, Schrögendorfer K, Wallner T, et al. Ultrasonographic guidance reduces the amount of local anesthetic for 3-in-1 blocks. *Reg Anesth Pain Med.* 1998;23:584–8.
- Liu SS, Ngeow JE, Yadeau JT. Ultrasound-guided regional anesthesia and analgesia: a qualitative systematic review. *Reg Anesth Pain Med.* 2009;34:47–59.
- Liu SS, Zayas VM, Gordon MA, et al. A prospective, randomized, controlled trial comparing ultrasound versus nerve stimulator guidance for inter scalene block for ambulatory shoulder surgery for postoperative neurological symptoms. *Anesth Analg.* 2009;109:265–71.
- Maheshwari AV, Blum YC, Shekhar L, et al. Multimodal pain management after total hip and knee arthroplasty at the Ranawat Orthopaedic Center. *Clin Orthop Relat Res.* 2009;467:1418–23.
- Roehrig S, Straub A, Pohlmann J, et al. Discovery of the novel anti-thrombotic agent 5-chloro-N-({(5S)-2-oxo-3-[4-(3-oxomorpholin-4-yl)phenyl]-1,3-oxazolidin-5-yl)methyl}

- thiophene-2-carboxamide (BAY 59-7939): an oral, direct factor Xa inhibitor. *J Med Chem.* 2005;48:5900–8.
16. Lassen MR, Ageno W, Borris LC, et al. Rivaroxaban versus enoxaparin for thromboprophylaxis after total knee arthroplasty. *N Engl J Med.* 2008;358:2776–86.
 17. Turpie AG, Lassen MR, Davidson BL, et al. Rivaroxaban versus enoxaparin for thromboprophylaxis after total knee arthroplasty (RECORD4): a randomised trial. *Lancet.* 2009;373:1673–80.
 18. de la Fuente Tornero E, Garutti Martínez I, Gutiérrez Tonal B, et al. Comparison of hemostatic markers under different techniques for anesthesia-analgesia in total hip or knee replacement. *Rev Esp Anesthesiol Reanim.* 2010;6:333–40.
 19. Winnie AP, Ramamuaahy S, Dunaai Z. The inguinal para-vascular technic of lumbar plexus anesthesia: the “3-in-1block”. *Anesth Analg.* 1973;52:989–96.
 20. He DD, Jia DL, Guo XY. Analgesic effects of ultrasonography combined with nerve stimulation guidance for continuous femoral nerve block after total knee arthroplasty. *Chin J Mini Invas Surg.* 2011;11:304–7.
 21. Ye WQ, Yu XR, Gu GS, et al. Femoral nerve block for relieving pain after total knee arthroplasty. *Nurs Foreign Med Sci.* 2004;23:516.
 22. Zhuang XL, Zeng YM, Chen BL. *Modern anesthesiology.* Beijing: People’s Health Publishing House; 2006.
 23. Scott DA, Chamley DM, Mooney PH, et al. Epidural ropivacaine infusion for postoperative analgesia after major lower abdominal surgery a dose finding study. *Anesth Analg.* 1995;81:982–6.
 24. Fowler SJ, Symons J, Sabato S, et al. Epidural analgesia compared with peripheral nerve blockade after major knee surgery: a systematic review and meta-analysis of randomized trials. *Br J Anaesth.* 2008;100:154–64.
 25. Szczukowski MJ, Hines JA, Snell JA, et al. Femoral nerve block for total knee arthroplasty patients: a method to control post-operative pain. *J Arthroplasty.* 2004;19:720–5.
 26. Shanthanna H, Huilgol M, Manivackam VK, et al. Comparative study of ultrasound-guided continuous femoral nerve blockade with continuous epidural analgesia for pain relief following total knee replacement. *Indian J Anaesth.* 2012;56:270–5.
 27. Orebaugh SL, Kentor ML, Williams BA. Adverse outcomes associated with nerve stimulator-guided and ultrasound-guided peripheral nerve blocks by supervised trainees: update of a single-site database. *Reg Anesth Pain Med.* 2012;37:577–82.
 28. Denny NM, Harrop-Griffiths W. Location, location, location! Ultrasound imaging in regional anaesthesia. *Br J Anaesth.* 2005;94:1–3.
 29. Reiss W, Kurapati S, Shariat A. Nerve injury complicating ultrasound/electro-stimulation guided supra clavicular brachial plexus block. *Reg Anesth Pain Med.* 2010;35:400–1.