



REVISTA BRASILEIRA DE ANESTESIOLOGIA

Official Publication of the Brazilian Society of Anesthesiology
www.sba.com.br



CLINICAL INFORMATION

Bilateral subdural hematoma secondary to accidental dural puncture



Sofía Ramírez*, Elena Gredilla, Blanca Martínez, Fernando Gilsanz

Servicio de Anestesiología y Reanimación, Hospital Universitario La Paz, Madrid, Spain

Received 25 May 2014; accepted 4 July 2014
Available online 28 April 2015

KEYWORDS

Accidental dural puncture;
Epidural analgesia;
Post-dural puncture headache;
Subdural hematoma;
Epidural blood patch

PALAVRAS CHAVE

Dura-Máter;
Analgésia epidural;
Cefaleia pós-punção dural;
Hematoma subdural;
Placa de sangue epidural

Abstract

We report the case of a 25-year-old woman, who received epidural analgesia for labor pain and subsequently presented post-dural puncture headache. Conservative treatment was applied and epidural blood patch was performed. In the absence of clinical improvement and due to changes in the postural component of the headache, a brain imaging test was performed showing a bilateral subdural hematoma.

The post-dural puncture headache is relatively common, but the lack of response to established medical treatment as well as the change in its characteristics and the presence of neurological deficit, should raise the suspicion of a subdural hematoma, which although is rare, can be lethal if not diagnosed and treated at the right time.

© 2014 Sociedade Brasileira de Anestesiologia. Published by Elsevier Editora Ltda. All rights reserved.

Hematoma subdural bilateral secundário a punção dural acidental

Resumo

Apresentamos o caso clínico de uma paciente de 25 anos de idade, na qual uma técnica peridural foi realizada durante o trabalho de parto e posteriormente apresentou cefaleia com características de cefaleia pós-punção dural. Foi iniciado tratamento conservador e tampão de sangue peridural. Devido a ausência de melhora clínica e à mudança do componente postural da cefaleia, decidiu-se realizar um exame de imagem cerebral que demonstrou a presença de hematoma subdural bilateral.

A cefaleia pós-punção dural é relativamente frequente, mas a falta de resposta ao tratamento médico instaurado, assim como a mudança em suas características e a presença de foco

* Corresponding author.

E-mail: soframirez@gmail.com (S. Ramírez).

nerológico, devem levantar a suspeita de presença de um hematoma subdural que, embora infrequente, pode chegar a ser devastador se não for diagnosticado e tratado oportunamente. © 2014 Sociedade Brasileira de Anestesiologia. Publicado por Elsevier Editora Ltda. Todos os direitos reservados.

Introduction

The post-dural puncture headache (PDPH) is the most common complication after a neuroaxial¹ anesthesia. In turn, the subdural hematoma (SDH) is a rare, but potentially severe complication of dural puncture, which requires early diagnosis and treatment. Initially the diagnosis of SDH is complicated because the early symptoms are similar to those of PDPH, but when the headache does not respond to standard medical treatment, losing its postural characteristics or being accompanied by other neurological disorders, it is necessary to suspect of an intracranial pathology and urgently perform a neuroimaging scan to allow diagnosis and correct treatment.

Clinical case

A 25-five-year-old woman, gesta three at 39th week of gestation, was admitted to hospital due to early uterine activity. Her personal history pointed out that in her first birth she did not receive epidural analgesia due to impossibility of performing the technique. With a cervical dilation of 2 cm, and after gynecological evaluation, the patient requested epidural analgesia to control labor pain. With prior explanation of the risks, and after signing informed consent, an epidural technique was performed. After various attempts, using a 18 G Tuohy needle and loss of resistance to air, the epidural space was located at L3–L4 and the catheter was left in this position. Following a negative aspiration test, a dose test of 3 mL bupivacaine 0.25% with epinephrine 1:200,000 was administered with no hemodynamic changes or immediate sensory or motor blockade. The initial dose was 0.25% levobupivacaine 10 mL and then an epidural infusion of 0.125% levobupivacaine + fentanila 2 µg mL⁻¹ at 10 mL h⁻¹ was connected.

Labor was uneventful and 2 h later, after eutocic birth, a girl of 3090 g was born with Apgar score 8 at 1 min and 9 at 5 min. After staying for surveillance in postpartum area, the epidural catheter was removed, and the patient went to the room.

With 24 h postpartum the anesthesia service was called because the patient had severe headache, with appreciation of pain in simple verbal scale (SVS) 9/10, which worsened with standing position and improved when recumbent. Although dura mater puncture has not been noticed, there was suspicion of a possible PDPH and with this supposed diagnosis analgesic treatment was started with paracetamol 1 g IV/6 h and dexketoprofen 50 mg IV/8 h. After 48 h of headache onset, due to persistent symptoms despite medical treatment administered and diagnosis of PDPH, epidural blood patch (EBP) was performed with no other events.

Initially, the results were satisfactory, since the patient reported improvement in headache during the first hours, but the next day she showed non-orthostatic headache, with maximum intensity in the supine position, in SVS 10/10 associated with tinnitus and cervical contracture. Due to lack of clinical improvement, with change of headache characteristics and after ruling out neurological focus on physical examination, brain and lumbar spine nuclear magnetic resonance (MRI) was ordered, which showed bilateral intracranial SDH (Figs. 1 and 2). The Neurosurgery Service was consulted, indicating treatment with IV corticosteroids (dexamethasone 4 mg IV every 8 h) and requesting computed tomography (CT) control in a week.

With 24 h of treatment initiation with corticosteroids, the patient reported improvement in headache, SVS 3/10 and after 48 h she reported no headache or other symptoms. The patient remained in hospital for another week for medical treatment and medical supervision. Control cranial CT showed improvement of lesions and due to satisfactory progress, with total remission of headache and without the presence of neurological focus, she was discharged with corticoid oral treatment in a descending regimen during 20 days and control by neurosurgery service.

Discussion

The incidence of accidental dural puncture described in the literature after performance of an epidural technique varies from 0.4 to 6%,² but only 60% of patients develop PDPH.³ In our anesthesia service at Maternal Hospital La Paz numbers

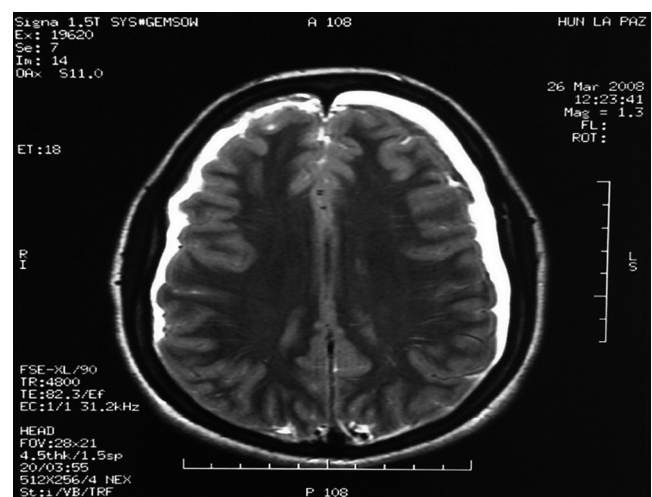


Figure 1 Axial section of brain magnetic resonance where a bilateral subdural hematoma is observed.

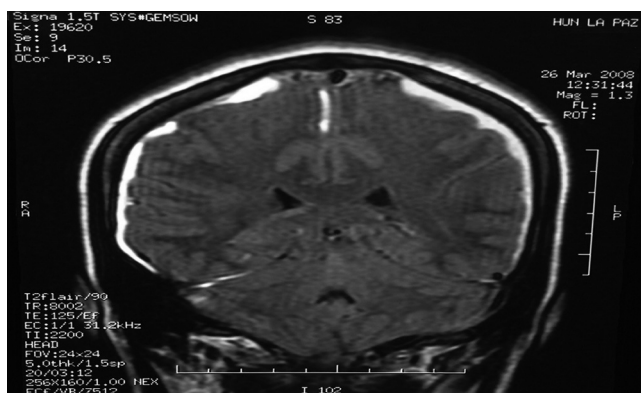


Figure 2 Coronal section of brain magnetic resonance where bilateral subdural hematoma is observed.

are similar, with an incidence of accidental dural puncture of 0.6%, and of PDPH of 56%.⁴

According to the diagnostic criteria established by the International Headache Society, PDPH is characterized by its postural character, worsening at the 15 min of standing or sitting position, and improving in a similar time with decubitus; it develops within 5 days of puncture and resolves spontaneously within a period of one week in 95% of cases or in the following 48 h of the performance of an EBP.³

The SDH is a rare but potentially fatal complication of dural puncture, as a result of a spinal anesthesia or accidental dural puncture during epidural technique.² Although the literature collects only isolated cases of SDH secondary to neuroaxial anesthesia, it is estimated that the prevalence of this condition is 1/500,000–1/1,000,000.⁵

Postulated mechanisms for PDPH and SDH are similar: the loss of cerebrospinal fluid (CSF) through the hole created in the dura mater causes a reduction of volume and subsequently in spinal and intracranial pressure. This intracranial hypotension causes a caudal displacement of the spinal cord and the brain, with traction of brain structures that are sensitive to pain, thereby causing the headache. The venous drainage of the brain is performed through the veins in the dural bridges, that run from the brain into the dural sinuses, and that have their weakest part in the subdural space, and it is precisely the traction of these veins that cause their detachment and subsequent emergence of a SDH and increased intracranial pressure.⁶ Thus, in patients with SDH, two clinical phases can be observed as a result of changes generated on intracranial pressure: initially they present with a headache with a clear postural component (associated with intracranial hypotension). In a later stage they show increased intensity of headache with loss of orthostatic component, without improvement with the usual treatment of PDPH and including clinical worsening after performance of an EBP and that may be accompanied by neurological focus signs (related to intracranial hypertension).¹

Conventional treatment of PDPH includes the administration of analgesics and antiemetics. In case of persistent headache despite these measures, an EBP can be performed, which is currently considered the definitive treatment of this clinical entity. The postulated mechanism for its efficacy is dual: first it compresses the thecal sac, increasing the pressure on the lumbar neuraxial channel, leading to the passage

of CSF from the spinal canal to the brain and thereby causing improvement of headache; on the other hand, maintenance of the therapeutic effect is attributed to the formation of a clot which prevents escape of CSF.³

In our hospital we performed the EBP in case of severe PDPH that persists 48 h after puncture and initiation of analgesic treatment. The procedure consists of making an epidural puncture, preferably in the same intervertebral space where the accidental dural puncture was performed or below, and once the epidural space is located, 15–20 mL of autologous blood from a forearm vein is aseptically collected, and is injected through epidural route, with care being taken to stop injection if the patient complains of back pain or pain in the lower limbs. Subsequently the patient should remain supine for one hour in the resuscitation area.

Regarding the diagnosis of SDH after accidental dural puncture, it is important to note that if there is a headache that does not respond to usual treatment for PDPH, which loses its postural character (orthostatic or non-orthostatic), which worsens after the completion of a EBP or that reappears after remission, an intracranial complication should be suspected, and a neuroradiology study – brain CT or MRI – should be performed to rule out the presence of a SDH.⁷ As for these diagnostic tests, it was shown that both CT and MRI in isodense phase may not show the presence of a SDH, and therefore they should be performed with contrast to avoid false negatives in their results.^{1,8} This was the procedure that was followed in our patient's case.

Treatment of SDH can be medical or surgical, depending on its size and the severity of symptoms.² Most of the time, small (<5 mm) and little symptomatic hematomas respond clinically and radiologically satisfactorily with conservative medical treatment. On the other hand, patients with larger hematomas and marked neurological deterioration usually require urgent surgical drainage.^{9,10} In our case, the patient had no neurological focus, so a conservative approach was chosen, with good clinical results.

In conclusion, after an accidental dural puncture, the presence of severe, progressive headache, with changing of its postural component, no improvement or even worsening after the completion of a EBP, and associated with other neurological signs, a warning sign should be considered for intracranial complications, as it is for SDH. This is an infrequent situation, but can become catastrophic, producing persistent neurological sequelae and even death. Thus, it is necessary to insist on early diagnosis and treatment of this clinical entity.

Conflict of interests

The authors declare no conflict of interest.

References

1. Zeidan A, Farhat O, Maaliki H, et al. Does postdural puncture headache left untreated lead to subdural hematoma? Case report and review of the literature. *Int J Obstet Anesth.* 2006;15:50–8.
2. Nepomuceno R, Herd A. Bilateral subdural hematoma after inadvertent dural puncture during epidural analgesia. *J Emerg Med.* 2013;44:227–30.

3. Gaiser RR. Postdural puncture headache: a headache for the patient and a headache for the anesthesiologist. *Curr Opin Anesthesiol.* 2013;26:296–303.
4. Martínez Serrano B [thesis] Cefalea postpunción dural tras analgesia epidural para trabajo de parto. Madrid: Facultad de Medicina, Universidad Autónoma; 2006.
5. Machurot PY, Vergnion M, Fraipont V, et al. Intracranial subdural hematoma following spinal anesthesia: case report and review of the literature. *Acta Anaesthesiol Belg.* 2010;61:63–6.
6. K K, Chatterjee N, Shrivastava A, et al. Sub-dural hematoma following spinal anesthesia treated with epidural blood patch and burr-hole evacuation: a case report. *Middle East J Anesthesiol.* 2013;22:117–20.
7. Liang MY, Pagel PS. Bilateral interhemispheric subdural hematoma after inadvertent lumbar puncture in a parturient. *Can J Anaesth.* 2012;59:389–93.
8. Vaughan DJ, Stirrup CA, Robinson PN. Cranial subdural haematoma associated with dural puncture in labour. *Br J Anaesth.* 2000;84:518–20.
9. Abbinante C, Lauta E, di Venosa N, et al. Acute subdural intracranial hematoma after combined spinal-epidural analgesia in labor. *Minerva Anesthesiol.* 2010;76:1091–4.
10. Kayacan N, Arici G, Karsli B, et al. Acute subdural haematoma after accidental dural puncture during epidural anaesthesia. *Int J Obstet Anesth.* 2004;13:47–9.