



REVISTA BRASILEIRA DE ANESTESIOLOGIA

Publicação Oficial da Sociedade Brasileira de Anestesiologia
www.sba.com.br



CLINICAL INFORMATION

Dural sinus thrombosis following epidural analgesia for delivery: a clinical case



Marco Aurelio Dornelles^{a,b,c,*}, Luis M. Pereira^c

^a Sociedade Brasileira de Anestesiologia, Rio de Janeiro, RJ, Brazil

^b Sociedade Portuguesa de Anestesiologia, Lisboa, Portugal

^c Hospital de Faro, Centro Hospitalar do Algarve, Algarve, Portugal

Received 9 March 2016; accepted 26 July 2016

Available online 24 August 2016

KEYWORDS

Epidural complication;
Post-Dural Puncture Headache (PDPH);
Dural Sinus Thrombosis

Abstract

Background and objectives: Neurological complications of spinal anesthesia are rare conditions. Headache caused by low pressure of the cerebrospinal fluid is one of the most frequent, which occurs after post-dural puncture. A comprehensive history and physical exam must be carried out before making the diagnosis of Post-Dural Puncture Headache (PDPH) and additional tests are necessary to exclude the possibility of developing serious neurological complications such as Dural Sinus Thrombosis (DST). According to the Case Report a differential diagnosis between Dural Sinus Thrombosis with PDPH is discussed.

Case report: A 22 year-old lady, ASA Physical Status Class I was admitted at 39 weeks of gestation for delivery. For labor pain relief she requested epidural for analgesia, but unfortunately accidental dural puncture occurred. She developed an occipital headache and neck pain in the second day postpartum which was relieved by both lying down and supporting treatment such as rehydration, analgesics and caffeine. On day third postpartum she was discharged without complaints. On day fifth postpartum the pain returned and became more intense and less responsive to oral analgesics. She was admitted to the hospital to do a complete neurological and image investigation that showed a lesion consistent with the diagnosis of cortical vein thrombosis and Dural Sinus Thrombosis (DST). She was treated with oral anticoagulants. After two days, a repeated magnetic resonance image (MRI) showed partial canalization of the central sinus thrombus. The patient was discharged from hospital five days after her admission without any of the initial symptoms.

* Corresponding author.

E-mail: marcodornelles49@gmail.com (M.A. Dornelles).

PALAVRAS-CHAVE

Complicação epidural;
Cefaleia pós-punção dural;
Trombose de seios durais

Conclusion: The report describes a patient who developed severe headache following continuous epidural analgesia for delivery. Initially it was diagnosed as PDPH, however with the aid of MRI the diagnosis of DST was later established and treated. DST is a rare condition and is often underdiagnosed. Because of its potentially lethal complications, it should always be considered in acute headache differential diagnosis.

© 2018 Sociedade Brasileira de Anestesiologia. Published by Elsevier Editora Ltda. This is an open access article under the CC BY-NC-ND license (<http://creativecommons.org/licenses/by-nc-nd/4.0/>).

Trombose de seios durais após analgesia peridural para parto: caso clínico**Resumo**

Justificativa e objetivos: As complicações neurológicas da raquianestesia são condições raras. A cefaleia causada pela baixa pressão do fluido cerebrospinal é uma das mais frequentes que ocorre após a punção dural. Anamnese completa e exame físico geral devem ser realizados antes de fazer o diagnóstico de cefaleia pós-punção dural (CPPD) e testes adicionais são necessárias para excluir a possibilidade de complicações neurológicas graves, como trombose de seios durais (TSD). De acordo com o relato do caso, discutiremos o diagnóstico diferencial entre TSD e CPPD. **Relato de caso:** Paciente de 22 anos, estado físico ASA I, foi admitida com 39 semanas de gestação para o parto. Para alívio da dor do trabalho de parto, a paciente solicitou analgesia peridural, mas infelizmente ocorreu uma punção dural acidental. A paciente desenvolveu cefaleia occipital e dor cervical no segundo dia pós-parto — ambas aliviadas com repouso e terapia de suporte, como reidratação, analgésicos e cafeína. No terceiro dia pós-parto, a paciente recebeu alta sem queixas. No quinto dia pós-parto, a dor retornou e ficou mais intensa e com pouca resposta aos analgésicos orais. Ela foi admitida no hospital para uma completa investigação neurológica e de imagem que mostrou uma lesão compatível com o diagnóstico de trombose venosa cortical e TSD. A paciente foi tratada com anticoagulantes orais. Após dois dias, a repetição de ressonância nuclear magnética (RNM) mostrou canalização parcial de trombo do seio central. A paciente recebeu alta hospitalar cinco dias após a admissão, sem quaisquer dos sintomas iniciais.

Conclusão: O caso descreve uma paciente que desenvolveu cefaleia grave após epidural contínua para o parto. Inicialmente ela foi diagnosticada como CPPD, contudo com o auxílio da RNM foi estabelecido o diagnóstico tardio de TSD. TSD é uma condição rara e frequentemente subdiagnosticada. Ela deve sempre ser considerada como diagnóstico diferencial de cefaleia aguda em decorrência de suas complicações potencialmente letais.

© 2018 Sociedade Brasileira de Anestesiologia. Publicado por Elsevier Editora Ltda. Este é um artigo Open Access sob uma licença CC BY-NC-ND (<http://creativecommons.org/licenses/by-nc-nd/4.0/>).

Introduction

The use of epidural analgesia (EP) to provide pain relief for labor and delivery has become increasingly popular. During the placement of an epidural needle or the catheter, recognizable inadvertent dural puncture may occur in 0.5–10% of the cases depending on the experience of the anesthetist.¹ On the other hand, unrecognized dural puncture occurs in about 1.5% of cases.² Thus it is not uncommon for a patient to develop a persistent postpartum headache following epidural analgesia. Before treating the headache in such patients one has to consider other conditions which can also produce headache. This report describes a patient whose headache was thought to be a spinal headache; however, the cause of her headache was subsequently diagnosed as Dural Sinus Thrombosis (DST).

Case report

A 22 year-old lady, first pregnancy, ASA Physical Status Class I was admitted at 39 weeks of gestation for delivery. The antenatal period, physical examination and blood pressure were normal. For labor pain relief she requested EP for analgesia. Under sterile conditions, using the loss of resistance technique, a 17 Tuohy epidural needle was inserted into L4–L5 interspace. Unfortunately, accidental dural puncture occurred. The needle was removed and replaced in the L3–L4 interspace where the epidural catheter remained successfully. A 10 mL bolus dose of Ropivacaine 2 mg.mL⁻¹ (20 mg) was administered with no untoward effects. Shortly after she progressed to the second stage of labor and had a spontaneous vaginal delivery of a healthy baby.

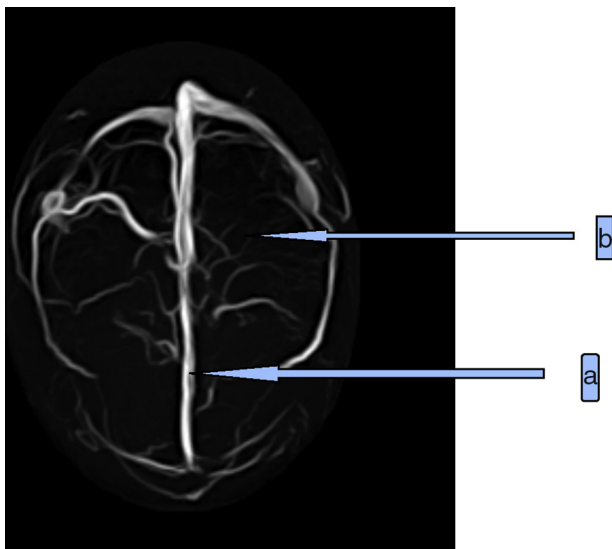


Figure 1 Magnetic resonance venogram – axial view demonstrating reduction of flow in longitudinal sinus (a) and lack of flow in left superior cerebral vein (b).

She remained well after delivery and continued to do so for the next 24h. However, on the second day postpartum, she developed an occipital headache and neck pain, which were both relieved by lying down. Conservative treatment with bed rest, analgesics and i.v. fluid administration to prevent dehydration were advised, but she did not remain in bed and walked frequently. On day third postpartum she was discharged without complaints.

She rested five days at home, but the pain returned and became more intense and less responsive to oral analgesics. She presented to the emergency room complaining of occipital and parietal headache, nausea and sometimes vomiting. The pain became worse on standing up. Sometimes it began at the occipital region and also left side of the skull. She also complained of right arm weakness and some paresthesia and jerky movements. She was admitted to the hospital on the Stroke Unit to do a complete neurological and radiologic investigation and other analysis. There was no focal papilledema and the CT scan was normal. However, an Electroencephalogram (EEG) revealed focal slowing in the left parietal region. Further investigations with Magnetic Resonance Imaging (MRI) revealed a region of increased T1 signal involving the superior sagittal sinus and the left cortical vein with an obvious lesion consistent with the diagnosis of cortical vein thrombosis and Dural Sinus Thrombosis (DST) (Fig. 1). Heparin infusion was initiated and oral Coumadin therapy also until the goal International Normalized Ratio (INR) of 2–3 was reached. After 2 days a repeat MRI showed partial canalization of the central sinus thrombus. The patient was discharged from hospital five days after her admission without any initial symptoms. She is followed up by a stroke consultant with regular INR monitoring for 6 months and she is now headache-free and asymptomatic.

Discussion

A consequence of the increased use of regional anesthesia worldwide is an inevitable increase in associated

complications. The largest ever prospective study into the major complications of EP and spinal anesthetics published concludes that the estimated risk of permanent harm is lower than one in 20,000 and that the risk of permanent injury is about one in 50,000.³

DST is an uncommon complication of pregnancy with an incidence of between 1:3000 and 1:10,000 cases. In the International Study on Cerebral Vein and Dural Sinus Thrombosis (ISCVT), 4.3% of patients died during acute phase of DST and 3.4% within 30 days from symptom onset.⁴

Factors that predispose to DST include the hypercoagulable state of pregnancy and hereditary conditions. Thrombophilia screening (proteins C and S, antithrombin III, lupus anticoagulant, anticardiolipin antibodies, factor V Leiden, and G20210A mutations) are recommended. Sinus thrombosis related to pregnancy usually occurs from the third trimester to four weeks postpartum and the main symptoms include headache, seizures, impaired consciousness, nausea, and vomiting.⁵

CT scanning is the investigation of choice in the acute neurologic situation, often revealing a high density crescent of fresh blood, but when the hematoma becomes isodense on CT, MRI is a more sensitive investigation for detection and optimal delineation.⁴

The treatment of patients with DST involves supportive therapy and sometimes anti-seizure medication. Specific therapy for DST involves anticoagulation or thrombolytic therapy.⁴

The individual time course is highly variable and the death rates series range between 5% and 30%, and probably depend more on case mix than on treatment.⁵

The occurrence of any complication implies an interaction of factors related to the blockade itself and known or unknown preexisting conditions in the patient. It is often difficult, if not impossible, to determine the exact etiology, but unfortunately for the anesthetist, regional blockade usually incriminated till proven otherwise. A thorough history is important to exclude other possible diagnoses before assuming that the headache is of spinal origin. The common and serious causes of persistent headache in the puerperium after regional anesthesia are²: spinal headache; migraine; pregnancy-induced hypertension; meningitis; cerebral tumor; subarachnoid hemorrhage; subdural hematoma; cerebral vein thrombosis. Before the development of seizures or neurological signs it is difficult to distinguish headache of DST from ordinary spinal headache (PDPH). However, there are some distinguishing features of DST: the headache seems to be throbbing in nature, accentuated by movement of the head and assumption of the sitting position, and may be associated with nausea and vomiting. The patient may manifest lethargy, a feeling of numbness and focal non-specific weakness. In the presence of atypical spinal headache following spinal or EP analgesia, MRI may be used to rule out the possibility of DST.³ Otherwise, the use of an Epidural Blood Patch (EBP) to treat spinal headache after accidental dural puncture is well recognized, and although the success rate is as high as 90%,¹ there is evidence to suggest that this treatment can cause DST as the same way after a diagnostic lumbar puncture due to persisting lumbar meningeal wound.²

In conclusion, DST can mimic Post-Dural Puncture Headache (PDPH) and should always be considered in the

differential diagnosis, especially the worsening headache and change in pain character with some neurological symptom associated with a failure of Epidural Blood Patch, indicating increased intracranial pressure.

Conflicts of interest

The authors declare no conflicts of interest.

References

1. Ravindran RS, Albrech WH, Tasch M. Low pressure headache following successful continuous lumbar epidural analgesia. *Anesth Analg.* 1980;59:799–800.
2. Benhamou D, Auroy Y. Overview of regional anesthesia complications. In: Neal JM, Rathmell JP, editors. *Complications in regional anesthesia and pain medicine*. London: Elsevier; 2007. p. 9–16.
3. Cook TM, Counsell D, Wildsmith JAW. Major complications of central neuraxial block: report on the third national audit project of The Royal College of Anaesthetists. *Br J Anaesth.* 2009;102:179–90.
4. Ferro JM, Canhao P, Stam J, et al. Prognosis of cerebral vein and sinus thrombosis: results of the International Study on Cerebral Vein and Dural Thrombosis (ISCVT). *Stroke.* 2004;35:664–70.
5. Cantu C, Barinagarrementeria F. Cerebral venous thrombosis associated with pregnancy and puerperium. Review of 67 cases. *Stroke.* 1993;24:1880–4.