



# REVISTA BRASILEIRA DE ANESTESIOLOGIA

Official Publication of the Brazilian Society of Anesthesiology  
[www.sba.com.br](http://www.sba.com.br)



## SCIENTIFIC ARTICLE

# Changes in the distance between carina and orotracheal tube during open or videolaparoscopic bariatric surgery

Giovani de Figueiredo Locks<sup>a,\*</sup>, Maria Cristina Simões de Almeida<sup>a</sup>,  
Maurício Sperotto Cecon<sup>b</sup>, Karen Adriana Campos Pastório<sup>a</sup>

<sup>a</sup> Universidade Federal de Santa Catarina (UFSC), Florianópolis, SC, Brazil

<sup>b</sup> Ultralitho Centro Médico, Florianópolis, SC, Brazil

Received 14 December 2012; accepted 1 March 2013

Available online 3 April 2014

### KEYWORDS

Endotracheal intubation/complications;  
Obesity;  
Bariatric surgery;  
Pneumoperitoneum;  
Laparotomy

### Abstract

**Objective:** To examine whether there are changes in the distance between the orotracheal tube and carina induced by orthostatic retractor placement or by pneumoperitoneum insufflation in obese patients undergoing gastroplasty.

**Methods:** 60 patients undergoing bariatric surgery by two techniques: open (G1) or videolaparoscopic (G2) gastroplasty were studied. After tracheal intubation, adequate ventilation of both hemitoraxes was confirmed by lung auscultation. The distance orotracheal tube–carina was estimated with the use of a fiber bronchoscope before and after installation of orthostatic retractors in G1 or before and after insufflation of pneumoperitoneum in patients in G2.

**Results:** G1 was composed of 22 and G2 of 38 patients. No cases of endobronchial intubation were detected in either group. The mean orotracheal tube–carina distance variation was estimated in  $-0.03$  cm (95% CI 0.06 to  $-0.13$ ) in the group of patients undergoing open gastroplasty and in  $-0.42$  cm (95% CI  $-0.56$  to  $-1.4$ ) in the group of patients undergoing videolaparoscopic gastroplasty. The extremes of variation in each group were: 0.5 cm to  $-1.6$  cm in patients undergoing open surgery and 0.1 cm to  $-2.2$  cm in patients undergoing videolaparoscopic surgery.

**Conclusions:** There was no significant change in orotracheal tube–CA distance after placement of orthostatic retractors in patients undergoing open gastroplasty. There was a reduction in orotracheal tube–CA distance after insufflation of pneumoperitoneum in patients undergoing videolaparoscopic gastroplasty. We recommend attention to lung auscultation and to signals of ventilation monitoring and reevaluation of orotracheal tube placement after peritoneal insufflation.

© 2014 Sociedade Brasileira de Anestesiologia. Published by Elsevier Editora Ltda. All rights reserved.

\* Corresponding author.

E-mail: [govanilocks@gmail.com](mailto:govanilocks@gmail.com) (G. de Figueiredo Locks).

**PALAVRAS-CHAVE**

Intubação orotraqueal/  
Complicações;  
Obesidade;  
Cirurgia bariátrica;  
Pneumoperitônio;  
Laparotomia

**Mudanças da distância entre a carina e o tubo orotraqueal durante cirurgia bariátrica aberta ou laparoscópica****Resumo**

**Objetivo:** Analisar se há mudanças na distância entre o tubo orotraqueal (TOT) e a carina (CA) induzidas pelo afastador ortostático ou pelo pneumoperitônio em pacientes obesos submetidos a gastroplastia.

**Métodos:** foram estudados 60 pacientes submetidos à cirurgia bariátrica por duas técnicas: aberta (G1) ou videolaparoscópica (G2). Após a intubação orotraqueal, a ventilação adequada de ambos os hemitórax foi confirmada por meio da ausculta pulmonar. A distância TOT-CA foi estimada com o uso de um fibrobroncoscópio antes e após a instalação dos afastadores ortostáticos no G1 ou antes e após a insuflação do pneumoperitônio nos pacientes no G2.

**Resultados:** Integraram o G1 22 pacientes e 38 o G2. Não houve casos de intubação endobrônquica em nenhum dos grupos. A média de variação da distância TOT-CA foi -0,03 cm (95% IC 0,06 a -0,13) no grupo dos pacientes submetidos à gastroplastia aberta e -0,42 cm (95% IC -0,56 a -1,4) no grupo dos pacientes submetidos à gastroplastia videolaparoscópica. Os extremos de variação em cada grupo foram: 0,5 cm a -1,6 cm no dos pacientes submetidos à cirurgia aberta e 0,1 cm a -2,2 cm no dos pacientes submetidos à cirurgia videolaparoscópica.

**Conclusões:** Não houve alteração significativa na distância TOT-CA após instalação dos afastadores ortostáticos nos pacientes submetidos à gastroplastia aberta. Houve redução na distância TOT-CA após a insuflação do pneumoperitônio nos pacientes submetidos à gastroplastia videolaparoscópica. Sugerimos atenção à ausculta pulmonar e aos sinais de monitoração da ventilação e reavaliação do posicionamento do TOT após insuflação peritoneal.

© 2014 Sociedade Brasileira de Anestesiologia. Publicado por Elsevier Editora Ltda. Todos os direitos reservados.

**Introduction**

After intubation, the advancement of the orotracheal tube (OTT) beyond the carina results in ventilation of only one of the lungs. This condition, known as endobronchial intubation or selective intubation, can cause hypoxemia, hypercapnia or excessive intrapulmonary pressure and potentially cause secondary damage, such as brain injury or tracheobronchial rupture, especially in the presence of other comorbidities, such as pneumothorax, shock or trauma.<sup>1,2</sup> Endobronchial intubation is the most common cause of arterial desaturation.<sup>3</sup> The chest five-point auscultation has been the traditional method of confirming OTT position.<sup>4</sup>

A method developed for the study of the tracheobronchial tree is fiberoptic bronchoscopy. It is considered a rapid, safe, and cost-effective diagnostic method.<sup>5</sup> As a confirmatory method for OTT position, the procedure is conducted through OTT, and the direct visualization of carina can detect an incorrect positioning of the tube.<sup>6</sup>

The aim of this study was to examine whether there are changes in the distance between OTT and carina (OTT-CA) induced by the orthostatic retractor or by pneumoperitoneum in obese patients undergoing open or videolaparoscopic gastroplasty, respectively.

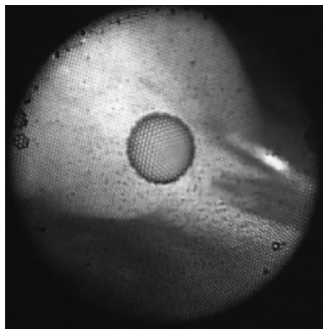
**Method**

After approval of the protocol by the Ethics and Human Research Committee (00232.1208-11) and after the signature of informed consent, patients of both genders between 18 and 60 years, ASA physical status I, II or III and body mass index greater than 35 kg m<sup>-2</sup> who underwent bariatric surgery under general anesthesia were included.

The sample consisted of patients undergoing open gastroplasty in a university hospital and of patients undergoing videolaparoscopic gastroplasty in a private institution, according to the routine surgical techniques in the respective institutions. Pregnant or lactating women, patients with tracheobronchial deformity, patients with impaired preoperative lung auscultation and patients with a history of hypersensitivity to the drugs as per protocol were excluded from the study.

Patients did not receive premedication. All were positioned with pillows in the chest, neck and head to align the sternal notch and the external auditory meatus.<sup>7</sup> Monitoring with pulse oximetry, noninvasive blood pressure, capnography and cardioscopy were used. All patients received 100% oxygen by face mask for 3 min. Induction of anesthesia consisted of remifentanyl 0.3 µg kg<sup>-1</sup> min<sup>-1</sup> (according to ideal weight) and propofol 2 mg kg<sup>-1</sup> (according to the actual weight). After loss of consciousness, succinylcholine was administered at a dose of 1 mg kg<sup>-1</sup> (according to the actual weight).

After 1 min, we proceeded to the orotracheal intubation with a tube of 7.5 mm in female patients and 8.5 mm in male patients. For confirmation of tracheal intubation, capnography was used. The patient was mechanically ventilated with positive pressure ventilation and volume-controlled positive end expiratory pressure (PEEP) of 5 cm H<sub>2</sub>O to maintain EtCO<sub>2</sub> between 30 and 35 mmHg. At this moment, auscultation was used in both anterior hemithoraxes. If the breath sounds were diminished or abolished on one side, we could suppose a diagnosis of selective intubation. The tube would be repositioned, if necessary, until the presence of normal auscultation in both hemithoraxes. Subsequently, a fiberoptic bronchoscopy was performed, with a flexible pediatric bronchoscope of 3.6 mm (Storz, Germany) lubricated with



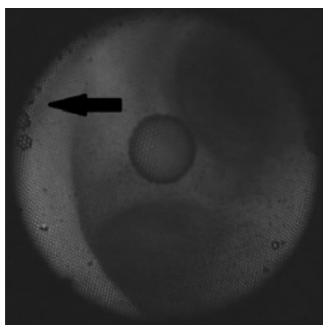
**Figure 1** Bronchoscope positioned adjacent to the tracheal carina.

lidocaine hydrochloride 2% gel by an anesthesiologist with more than two years of experience with the procedure. We used one valve connector, allowing that the fiberoptic bronchoscopy was done without interrupting patient's ventilation.

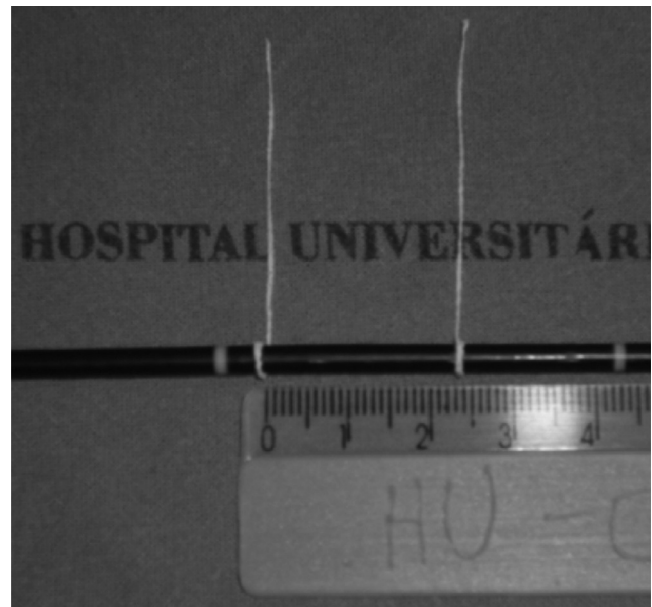
The correct position of the tube was confirmed by visualization of the tracheal carina and the introduction of fiber bronchoscope in both main bronchi. The upper lobe bronchus orifice of the right lung after the tracheal carina bifurcation was used as the primary anatomic repair. The distance from the tip of the endotracheal tube to the tracheal carina was estimated as follows: the fiber bronchoscope was placed on the carina (Fig. 1) and was marked with a strip of adhesive tape in the proximal portion near the proximal end of OTT. Then, the bronchoscope was pulled until the distal tip of OTT was visualized and the fiberscope was marked by the same method (Fig. 2). The OTT-CA distance was estimated as the distance between the two tapes (Fig. 3).

The lung auscultation and the estimated OTT-CA distance were repeated after the installation of orthostatic retractors in G1 patients or after pneumoperitoneum insufflation in G2 patients.

The sample size was estimated to be of at least 22 patients for each group, the number required for a alpha error of 5% and a beta error of 20%, according to an earlier study that found an OTT drive of  $0.7 \pm 1.4$  cm after insufflation of pneumoperitoneum and aiming to detect a reduction of 1 cm in OTT-CA distance.<sup>8</sup> The data were stored in a database in Microsoft Office Excel v. 7.0 (Microsoft, Seattle). Subsequently, the analyses were performed using IBM SPSS Statistics v. 17.0 software. Statistical significance was considered at  $p < 0.05$ .



**Figure 2** Endoscopic view of the distal end of the orotracheal tube into the trachea.



**Figure 3** Estimated distance between the orotracheal tube and the carina.

Data are shown as mean (standard deviation) or absolute frequency (relative frequency or percentage). To verify the association among qualitative variables between groups, the Fischer *t* test was used. To analyze the difference of quantitative variables by groups, Student's *t* test was performed. To study the difference between OTT-CA distance measurements before and after orthostatic retractors or pneumoperitoneum, the *t* test for paired measurements and Bland-Altman analysis were used.

## Results

Of the 60 enrolled patients, 38 underwent open gastroplasty and 22 underwent videolaparoscopic bariatric gastroplasty. No patient was excluded from analysis for orotracheal intubation (OTI) or fiberoptic bronchoscopy failure. The demographic characteristics of the sample are shown in Table 1. Significant differences were observed between groups in BMI and gender variables. The group of patients undergoing open surgery had higher mean BMI and a higher proportion of women in relation to the group of patients undergoing videolaparoscopic surgery, with a trend to older age.

In this study, no changes in lung auscultation or cases of selective intubation were observed at any time in both groups.

Table 2 shows data concerning measurements of OTT-CA distance shortly after OTI and after placement of orthostatic retractors or pneumoperitoneum insufflation.

The mean change was  $-0.03$  (95% CI,  $-0.13$  to  $0.06$ ) in the group of patients undergoing open bariatric gastroplasty and  $-0.42$  (95% CI,  $-0.56$  to  $-1.4$ ) in the group of patients undergoing videolaparoscopic gastroplasty. The extremes of variation in each group were  $-1.6$  cm to  $0.5$  cm in the group of patients undergoing open surgery and  $-2.2$  cm to  $0.1$  cm in the group of patients undergoing videolaparoscopic surgery. In Fig. 4, in the Bland-Altman analysis, the

**Table 1** Demographic characteristics of patients in both groups.

	Open surgery (n = 38)	Videolaparoscopic surgery (n = 22)	p-Value
Age (years)	35 ± 9.8	31.41 ± 5.9	0.12
Gender (M/F <sup>a</sup> )	6 (16%)/32 (84%)	8 (36%)/14 (64%)	0.001
BMI <sup>b</sup> (kg m <sup>-1</sup> )	46.9 ± 6.1	38.7 ± 4.7	<0.0001

<sup>a</sup> M/F, male/female.

<sup>b</sup> BMI, Body Mass Index.

**Table 2** Distance between the orotracheal tube and the carina in both groups immediately after intubation and after placement of orthostatic retractors or insufflation of pneumoperitoneum.

	After intubation	After retractor/pneumoperitoneum	p-Value
Open surgery (n = 38)	3.3 ± 1.3	3.2 ± 1.3	0.37
Videolaparoscopic surgery (n = 22)	2.8 ± 0.7	2.4 ± 0.6	<0.001

variations of OTT–CA distance after placement of orthostatic retractors and peritoneal insufflation, respectively, are arranged.

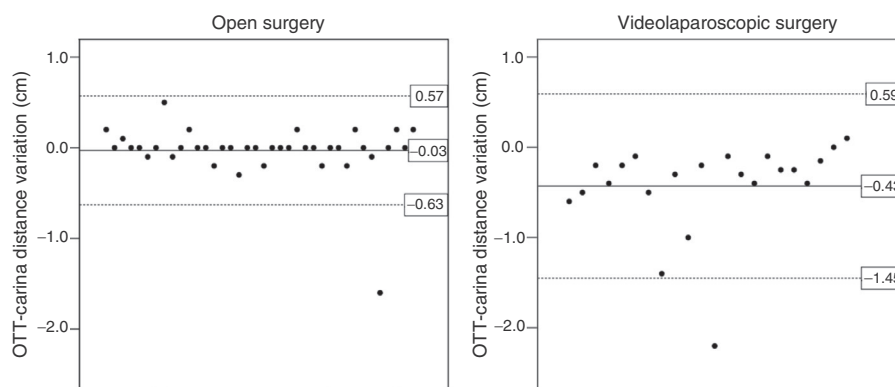
## Discussion

In this study, the most striking finding is the significantly greater reduction in the distance between the tip of OTT and the carina after insufflation of pneumoperitoneum in videolaparoscopic gastropasty, when compared to open gastropasty. As a consequence, one can speculate that there is a higher risk of endobronchial intubation in the transoperative phase of a videolaparoscopic surgery compared to patients undergoing open surgery.

Endobronchial intubation is an important problem in anaesthesiology and is closely associated with increases in morbidity.<sup>1–3</sup> This condition is the fourth most common incident of general anesthesia and the most common incident involving OTT.<sup>3</sup> Among the more severe consequences, hypoxemia, atelectasis of the non-ventilated lung and hyperinflation of the ventilated lung with the possibility of pneumothorax are observed;<sup>3</sup> tracheobronchial ruptures, unilateral lung edema and hemodynamic changes followed by brain damage and death have also been described.<sup>1,2</sup>

Although lung auscultation is the main clinical criterion for the diagnosis of endobronchial intubation, studies have suggested certain inaccuracy of the method.<sup>6,8–11</sup> OTT shifts without changes in the pattern of lung auscultation were observed in patients whose tip of the tube exceeded the carina up to 3.2 cm.<sup>9</sup> When compared to other diagnostic method, bilateral auscultation of the chest was able to detect only two cases of selective intubation in patients undergoing videolaparoscopic cholecystectomy among eight cases confirmed by chest radiography.<sup>11</sup> The low sensitivity of lung auscultation can be explained by the thoracic transmission of lung sounds when they become of a more bronchial quality during mechanical ventilation – a situation that may be exacerbated in the presence of anatomical abnormalities of the chest, such as large breasts, obesity and piriform chest.<sup>3</sup>

Signs of selective intubation include changes in peak inspiratory pressure, arterial desaturation and changes in concentrations of carbon dioxide in capnography.<sup>3,6,12</sup> These changes, however, are considered nonspecific and their first manifestations may be subtle, not causing alarm.<sup>3,13</sup> Only 11.5% of cases of selective intubation presented capnographic changes, without concomitant recording of changes in peak inspiratory pressure. The uncertainty of the symmetry of lung auscultation, the presumption of the possibility of

**Figure 4** Variations of the distance from the tip of the endotracheal tube (OTT) to the carina in patients undergoing open or videolaparoscopic surgery.



any device or instrument failure and the desire not to interrupt the surgery, as well as the difficulty of access to the thoracic region during surgery, contribute to a late diagnosis of the complication.<sup>3</sup>

During the transoperative, the migration of OTT may occur after its correct placement at the beginning of anesthesia, resulting from changes in the tilting of the operating table, peritoneal insufflation, flexion of the head and neck of the patient or repositioning in general. Neurological, gynecological and videolaparoscopic surgeries have higher rates of endobronchial intubation, and a third of cases are associated with surgeries involving the head and neck segment.<sup>3</sup>

The high incidence of selective intubation in neurosurgery is mainly related to the prone position and/or movement of the head and neck of the patient by the surgeon during surgery. On the other hand, gynecological videolaparoscopic surgeries have significant association with endobronchial intubation as a result of the pneumoperitoneum insufflation with the patient in head-down position. In these surgeries, a mean reduction of 1.6 cm of distance between OTT tip and the carina after installation of the pneumoperitoneum (from  $2.1 \pm 0.8$  cm to  $0.54 \pm 1.4$  cm) was reported, with eight cases of selective intubation in a sample of 30 patients undergoing videolaparoscopic gynaecologic surgery.<sup>14</sup> In the same line, in a study that examined chest radiographs before and after peritoneal insufflation at 10 mmHg, cephalic drives of OTT of  $1.1 \pm 0.4$  cm as a result of increased intra-abdominal pressure were measured.<sup>15</sup>

In our study, the use of pneumoperitoneum in obese patients undergoing videolaparoscopic gastroplasty was responsible for an OTT drive of  $-0.42 \pm 0.5$  cm in relation to the carina, with an extreme reduction of more than 2 cm. Besides the risk of selective intubation, pneumoperitoneum causes other important consequences on pulmonary function. Cephalic migration of the diaphragm is associated with both decreased functional residual capacity and the increased volume of closure of the small airways, which leads to a disturbance of ventilation/perfusion and to an increase of intrapulmonary shunt. Furthermore, ventilatory mechanisms are altered in view of the decrease in lung compliance, with consequent increase in airway resistance.<sup>16,17</sup> Obese patients during anesthesia constitute a risk group, since these people already have a reduced functional residual capacity, with airway closure and disturbance of ventilation/perfusion during normal tidal ventilation.<sup>7,18,19</sup> This situation is further aggravated in the presence of comorbidities associated with low pulmonary reserves or heart disease.<sup>18</sup>

Studies report that the tip of OTT come close to the carina after installation of the pneumoperitoneum, with a significant risk of causing endobronchial intubation.<sup>8,14,20-22</sup> Our results are consistent with other studies, in finding greater drive of the tip of OTT after insufflation of pneumoperitoneum, when compared to patients undergoing open surgery. Thus, it appears that the increase in intra-abdominal pressure is a major risk for accidental endobronchial intubation also in obese patients undergoing videolaparoscopic gastroplasty.

In our study, the use of orthostatic retractors in open gastroplasty was not associated with significant changes in the distance between the tip of OTT and the carina. However, our results should be evaluated with caution, since

videolaparoscopic surgery has been associated with several benefits in the postoperative period, such as less need for analgesics, better lung function, better cosmetic results,<sup>23</sup> lower rate of perioperative complications,<sup>24</sup> minor rate of abdominal wall complications and shorter hospital stay.<sup>25</sup> Adverse effects arising from the use of orthostatic retractors are peripheral nerve injury,<sup>26</sup> lesions of the colon,<sup>27</sup> liver injury<sup>28</sup> and chronic pain.<sup>29</sup>

In summary, in obese patients undergoing gastroplasty, insufflation of the pneumoperitoneum in videolaparoscopic procedures provides greater reduction of the distance between the tip of OTT and the carina compared with the placement of orthostatic retractors in open gastroplasty. The results point to the need for special attention to lung auscultation and to the signals of ventilation monitoring, as well as the reassessment of OTT position after peritoneal insufflation.

## Conflicts of interest

The authors declare no conflicts of interest.

## References

1. Goodman BT, Richardson MG. Case report: unilateral negative pressure pulmonary edema – a complication of endobronchial intubation. *Can J Anaesth.* 2008;55:691–5.
2. Engoren M, de St Victor P. Tension pneumothorax and contralateral presumed pneumothorax from endobronchial intubation via cricothyroidotomy. *Chest.* 2000;118:1833–5.
3. McCoy EP, Russell WJ, Webb RK. Accidental bronchial intubation. An analysis of AIMS incident reports from 1988 to 1994 inclusive. *Anaesthesia.* 1997;52:24–31.
4. Dronen S, Chadwick O, Nowak R. Endotracheal tip position in the arrested patient. *Ann Emerg Med.* 1982;11:116–7.
5. Pattnaik SK, Bodra R. Ballotability of cuff to confirm the correct intratracheal position of the endotracheal tube in the intensive care unit. *Eur J Anaesthesiol.* 2000;17:587–90.
6. Rudraraju P, Eisen LA. Confirmation of endotracheal tube position: a narrative review. *J Intensive Care Med.* 2009;24:283–92.
7. Ebert TJ, Shankar H, Haake RM. Perioperative considerations for patients with morbid obesity. *Anesthesiol Clin.* 2006;24:621–36.
8. Lobato EB, Paige GB, Brown MM, et al. Pneumoperitoneum as a risk factor for endobronchial intubation during laparoscopic gynecologic surgery. *Anesth Analg.* 1998;86:301–3.
9. Sugiyama K, Yokoyama K, Satoh K, et al. Does the Murphy eye reduce the reliability of chest auscultation in detecting endobronchial intubation? *Anesth Analg.* 1999;88:1380–3.
10. Sitzwohl C, Langheinrich A, Schober A, et al. Endobronchial intubation detected by insertion depth of endotracheal tube, bilateral auscultation, or observation of chest movements: randomized trial. *BMJ.* 2010;341:c5943.
11. Ezri T, Khazin V, Szmuk P, et al. Use of the Rapscope vs chest auscultation for detection of accidental bronchial intubation in non-obese patients undergoing laparoscopic cholecystectomy. *J Clin Anesth.* 2006;18:118–23.
12. Brunel W, Coleman DL, Schwartz DE, et al. Assessment of routine chest roentgenograms and the physical examination to confirm endotracheal tube position. *Chest.* 1989;96:1043–5.
13. Kato H, Suzuki A, Nakajima Y, et al. A visual stethoscope to detect the position of the tracheal tube. *Anesth Analg.* 2009;109:1836–42.

14. Kim JH, Hong DM, Oh AY, et al. Tracheal shortening during laparoscopic gynecologic surgery. *Acta Anaesthesiol Scand.* 2007;51:235–8.
15. Morimura N, Inoue K, Miwa T. Chest roentgenogram demonstrates cephalad movement of the carina during laparoscopic cholecystectomy. *Anesthesiology.* 1994;81:1301–2.
16. Joris J, Cigarini I, Legrand M, et al. Metabolic and respiratory changes after cholecystectomy performed via laparotomy or laparoscopy. *Br J Anaesth.* 1992;69:341–5.
17. Cunningham AJ. Anesthetic implications of laparoscopic surgery. *Yale J Biol Med.* 1998;71:551–78.
18. Lorentz MN, Albergaria VF, Lima FA. Anesthesia for morbid obesity. *Rev Bras Anesthesiol.* 2007;57:199–213.
19. Eichenberger A, Proietti S, Wicky S, et al. Morbid obesity and postoperative pulmonary atelectasis: an underestimated problem. *Anesth Analg.* 2002;95:1788–92.
20. Mendonca C, Baguley I, Kuipers AJ, et al. Movement of the endotracheal tube during laparoscopic hernia repair. *Acta Anaesthesiol Scand.* 2000;44:517–9.
21. Bottcher-Haberzeth S, Dullenkopf A, Gitzelmann CA, et al. Tracheal tube tip displacement during laparoscopy in children. *Anaesthesia.* 2007;62:131–4.
22. Hwang JY, Rhee KY, Kim JH, et al. Methods of endotracheal tube placement in patients undergoing pelviscopic surgery. *Anaesth Intensive Care.* 2007;35:953–6.
23. Davila-Cervantes A, Borunda D, Dominguez-Cherit G, et al. Open versus laparoscopic vertical banded gastroplasty: a randomized controlled double blind trial. *Obes Surg.* 2002;12:812–8.
24. Hutter MM, Randall S, Khuri SF, et al. Laparoscopic versus open gastric bypass for morbid obesity: a multicenter, prospective, risk-adjusted analysis from the National Surgical Quality Improvement Program. *Ann Surg.* 2006;243:657–62.
25. Lujan JA, Frutos MD, Hernandez Q, et al. Laparoscopic versus open gastric bypass in the treatment of morbid obesity: a randomized prospective study. *Ann Surg.* 2004;239:433–7.
26. Celebrezze Jr JP, Pidala MJ, Porter JA, et al. Femoral neuropathy: an infrequently reported postoperative complication: report of four cases. *Dis Colon Rectum.* 2000;43:419–22.
27. Noldus J, Graefen M, Huland H. Major postoperative complications secondary to use of the Bookwalter self-retaining retractor. *Urology.* 2002;60:964–7.
28. Saranita J, Soto RG, Paoli D. Elevated liver enzymes as an operative complication of gastric bypass surgery. *Obes Surg.* 2003;13:314–6.
29. Rogers ML, Henderson L, Mahajan RP, et al. Preliminary findings in the neurophysiological assessment of intercostal nerve injury during thoracotomy. *Eur J Cardiothorac Surg.* 2002;21:298–301.