



# REVISTA BRASILEIRA DE ANESTESIOLOGIA

Official Publication of the Brazilian Society of Anesthesiology  
[www.sba.com.br](http://www.sba.com.br)



## SCIENTIFIC ARTICLE

# Ultrasound guidance improves the success rate of axillary plexus block: a meta-analysis



Qin Qin<sup>a</sup>, Debao Yang<sup>b</sup>, Hong Xie<sup>a</sup>, Liyuan Zhang<sup>c</sup>, Chen Wang<sup>a,\*</sup>

<sup>a</sup> Department of Anesthesiology and Critical Care, The Second Affiliate Hospital of Soochow University, Suzhou, Jiangsu Province, People's Republic of China

<sup>b</sup> Department of Neurosurgery, Kowloon Hospital, Shanghai Jiaotong University School of Medicine, Suzhou, Jiangsu Province, People's Republic of China

<sup>c</sup> Department of Radiotherapy, The Second Affiliate Hospital of Soochow University, Suzhou, Jiangsu Province, People's Republic of China

Received 8 December 2014; accepted 27 January 2015

Available online 1 October 2015

### KEYWORDS

Meta-analysis;  
Brachial plexus block;  
Ultrasonography

### Abstract

**Objective:** To evaluate the value of real-time ultrasound (US) guidance for axillary brachial plexus block (AXB) through the success rate and the onset time.

**Methods:** The meta-analysis was carried out in the Anesthesiology Department of the Second Affiliated Hospital of Soochow University, Suzhou, Jiangsu Province, China. A literature search of Medline, EMBASE, Cochrane database from the years 2004 to 2014 was performed. The literature searches were carried out using medical subject headings and free-text word: "axilla", "axillary", "brachial plexus", "ultrasonography", "ultrasound", "ultrasonics". Two different reviewers carried out the search and evaluated studies independently.

**Results:** Seven randomized controlled trials, one cohort study and three retrospective studies were included. A total of 2042 patients were identified. 1157 patients underwent AXB using US guidance (US group) and the controlled group included 885 patients (246 patients using traditional approach (TRAD) and 639 patients using nerve stimulation (NS)). Our analysis showed that the success rate was higher in the US group compared to the controlled group (90.64% vs. 82.21%,  $p < 0.00001$ ). The average time to perform the block and the onset of sensory time were shorter in the US group than the controlled group.

**Conclusion:** The present study demonstrated that the real-time ultrasound guidance for axillary brachial plexus block improves the success rate and reduce the mean time to onset of anesthesia and the time of block performance.

© 2015 Sociedade Brasileira de Anestesiologia. Published by Elsevier Editora Ltda. All rights reserved.

\* Corresponding author.

E-mail: [double\\_qq@126.com](mailto:double_qq@126.com) (C. Wang).

**PALAVRAS-CHAVE**

Metanálise;  
Bloqueio do plexo  
braquial;  
Ultrassonografia

**Orientação por ultrassom melhora a taxa de sucesso do bloqueio do plexo axilar: uma metanálise****Resumo**

**Objetivo:** Avaliar o valor da orientação por ultrassonografia (US) em tempo real para bloqueio do plexo braquial por via axilar (BPBA) pela taxa de sucesso e tempo de latência.

**Métodos:** Uma metanálise foi realizada no Departamento de Anestesiologia do Segundo Hospital Afiliado da Universidade de Soochow, Suzhou, província de Jiangsu, China. Fizemos uma pesquisa bibliográfica nas bases de dados Medline, EMBASA e Cochrane de 2004 a 2014. A pesquisa foi realizada usando títulos de assuntos médicos e palavras de texto livre: *axilla*, *axillary*, *brachial plexus*, *ultrasonography*, *ultrasound*, *ultrasonics*. Dois revisores diferentes fizeram a pesquisa e avaliaram os estudos de forma independente.

**Resultados:** Sete estudos clínicos randômicos, um estudo de coorte e três estudos retrospectivos foram incluídos. Foi identificado um total de 2.042 pacientes, dos quais 1.157 foram submetidos ao BPBA guiado por ultrassom (grupo US); o grupo controle incluiu 885 pacientes, dos quais 246 foram submetidos à abordagem tradicional (TRAD) e 639 à estimulação do nervo (EN). Nossa análise mostrou que a taxa de sucesso foi maior no grupo US em comparação com o grupo controle (90,64% vs. 82,21%,  $p < 0,00001$ ). As médias do tempo necessário para realizar o bloqueio e do tempo de latência foram mais curtas no grupo US que no grupo controle.

**Conclusão:** O presente estudo demonstrou que a orientação por ultrassom em tempo real para o bloqueio do plexo braquial por via axilar melhora a taxa de sucesso e reduz a média do tempo de início da anestesia e do tempo de execução do bloqueio.

© 2015 Sociedade Brasileira de Anestesiologia. Publicado por Elsevier Editora Ltda. Todos os direitos reservados.

**Introduction**

In recent years, the people paid more and more attentions on the local anesthesia, especially on peripheral nerve block technique.<sup>1,2</sup> The traditional nerve block needs the help of anatomical landmarks, the arterial pulse, needling of abnormal sensation or nerve stimulator, but, with the rapid development of technology of ultrasound device, under the guidance of ultrasound nerve block anesthesia as a new field of an ultrasonic applications are gradually being retired by the attention, ultrasonic technology is a fundamental change in the way nerve block. Brachial plexus block are the most common methods used in peripheral nerve block. Peripheral nerve stimulation may have a high degree of accuracy and reliability for the axillary nerve block, but sometimes cause failure or incomplete block, even when took multiple stimulation and injection.<sup>3,4</sup>

Anesthesiologists have been able to observe the brachial plexus and the surrounding structures through the ultrasound guided puncture.<sup>5</sup> So anesthesiologists can puncture into the target peripheral nerve accurately with real-time ultrasound. The injection process and the diffusion range of local anesthetics can also be observed by ultrasonography. The technology ensured the local anesthetic evenly spread to peripheral nerve, make local anesthetics fully infiltrate the nerve, significantly improve the success rate and reduce the complications.

**Methods****Search strategy**

The meta-analysis was carried out in the Anesthesiology Department of the Second Affiliated Hospital of Soochow

University, Suzhou, Jiangsu Province, China. A literature search of Medline, EMBASE, Cochrane database from the years 2004 to 2014 was performed. The literature searches were carried out using medical subject headings and free-text word: "axilla", "axillary", "brachial plexus", "ultrasonography", "ultrasound", "ultrasonics". Two different reviewers carried out the search and evaluated studies independently.

**Inclusion criterion**

All randomized, non-randomized controlled clinical trials, which compared ultrasound-guided AXB with traditional approach or peripheral nerve stimulation included.

**Exclusion criterion**

Abstracts, letters, case reports, comments, and conference proceedings were not included in the review. We exclude studies with small-sized group (<40 patients).

**Date collection**

Two reviewers independently extracted the following from each study: first author, publication data, study design, inclusion criteria and exclusion criteria. All disagreements were resolved through discussion. Non-comparative studies, cases series, and case report were not included.

**Table 1** Summary of published information from controlled studies. RCT, randomized controlled trials.

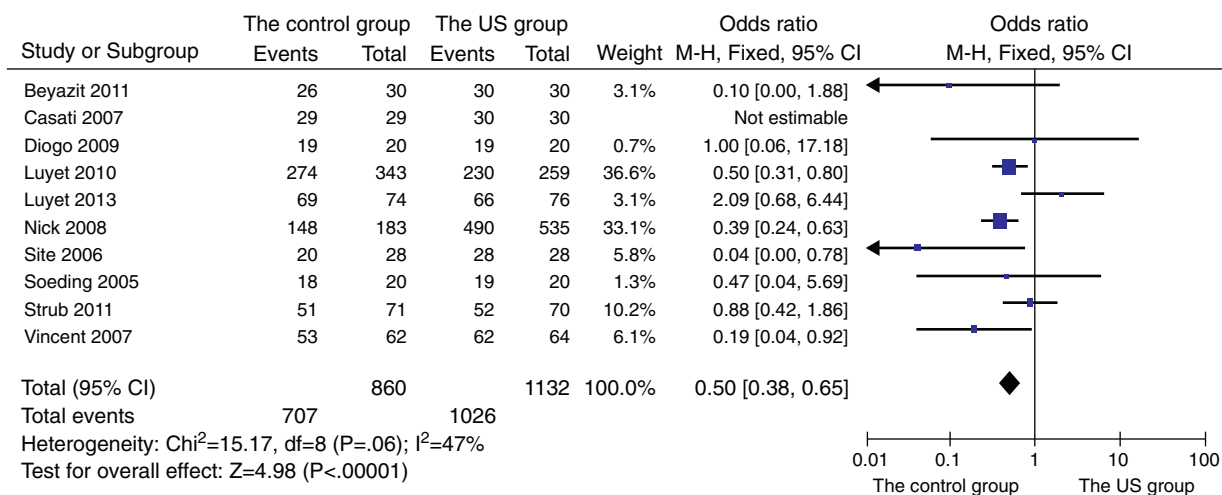
Study	Type	Patients	Age (mean ± SD)	Gender (M/F)	Height (mean ± SD)	Weight (mean ± SD) (kg)	ASA-1/ASA-2/ASA-3
Beyazit 2011	RCT	30 US	37.07 ± 16.04	13/17	167.01 ± 8.69 (cm)	77.41 ± 14.85	14/16/0
		30 NS	39.96 ± 11.27	18/12	163.56 ± 7.24 (cm)	74.49 ± 11.26	12/18/0
Casati 2007	RCT	30 US	57 ± 17	17/13			14/14/2
		29 NS	46 ± 19	16/13			15/11/3
Danelli 2012	RCT	25 US					
		25 NS					
Diogo 2009	Cohort study	20 US	39.75 ± 13.00	13/7	1.69 ± 7.96 (m)	78.1 ± 20.5	
		20 NS	45.15 ± 13.35	8/12	1.64 ± 79.51 (m)	72.9 ± 14.62	
Luyet 2010	Retrospective	259 US	47 ± 19.65				
		343 NS	46 ± 18.16				
Luyet 2013	Retrospective	76 US	47 ± 18	44/32			
		74 NS	48 ± 18	41/32			
Nick 2008	Retrospective	535 US	47.4 ± 14.9	297/238			
		127 T	44.6 ± 14.8	73/54			
		56 NS	45.2 ± 14.8	34/22			
Site 2006	RCT	28 US	47.5 ± 16.5	13/15	164.5 ± 7.2 (cm)	80.6 ± 22.3	14/13/1
		28 T	52.1 ± 19.1	16/12	169 ± 8.7 (cm)	83.8 ± 14.9	14/14/0
Soeding 2006	RCT	20 US					
		20 T					
Strub 2011	RCT	70 US		24/46			
		71 T		23/48			
Vincent 2007	RCT	64 US	44.3 ± 13.3	43/21	168.1 ± 23.8 (cm)	78.2 ± 18.9	
		62 NS	49.3 ± 14.6	30/32	167.0 ± 10.9 (cm)	74.9 ± 13.8	

**Statistical analysis**

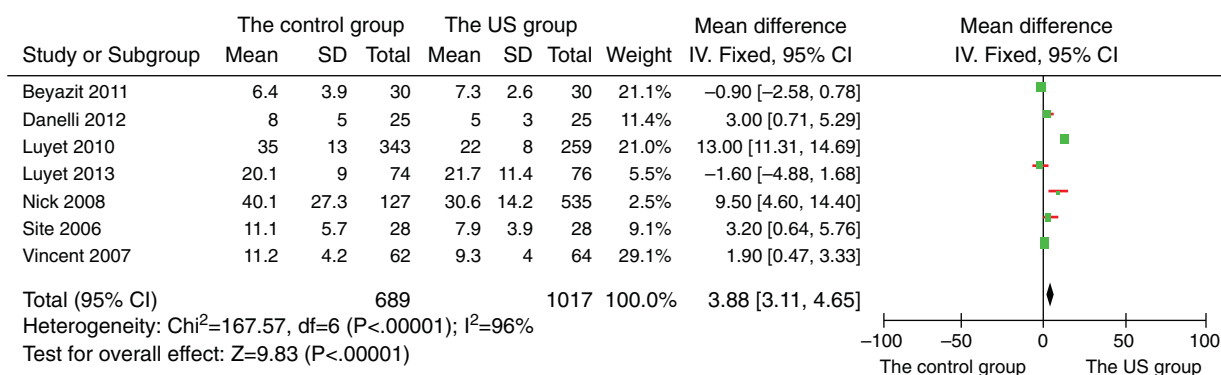
We used Review Manager 5.2 to conduct the review. The Mantel–Haenszel method was used for the statistical analysis of the success rate, the mean time to onset of anesthesia and the time of block performance. Dichotomous data were analyzed for odds ratio (OR) and 95% effectiveness confidence interval.  $p \leq 0.05$  was considered statistically significant.

**Results**

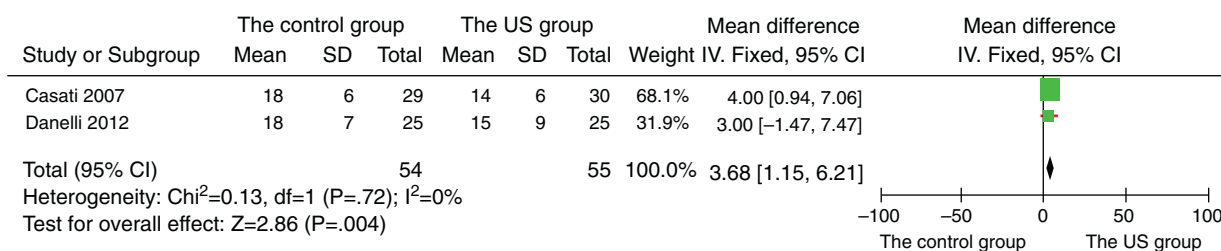
Seven randomized controlled trials, one cohort study and three retrospective studies were included (Table 1).<sup>4,6-15</sup> Our analysis showed that the success rate was higher in the US group compared to the controlled group (90.64% vs. 82.21%, total 1992 patients; Heterogeneity:  $\text{Chi}^2 = 15.17$ ;  $p < 0.00001$ ;  $I^2 = 47\%$ ; OR: 0.50; 95% CI [0.38, 0.65]) (Fig. 1). The average time to perform the block is shorter in the



**Figure 1** Analysis of controlled studies for success rate of AXB: without ultrasound guidance vs. ultrasound guidance in the patients with AXB. 95% CI, 95% confidence interval; M-H, Mantel–Haenszel; df, degrees of freedom; OR, odds ratio; US, ultrasound.



**Figure 2** Analysis of controlled studies for performance time of AXB: without ultrasound guidance vs. ultrasound guidance in the patients with AXB. 95% CI, 95% confidence interval; M-H, Mantel-Haenszel; df, degrees of freedom; OR, odds ratio; US, ultrasound.

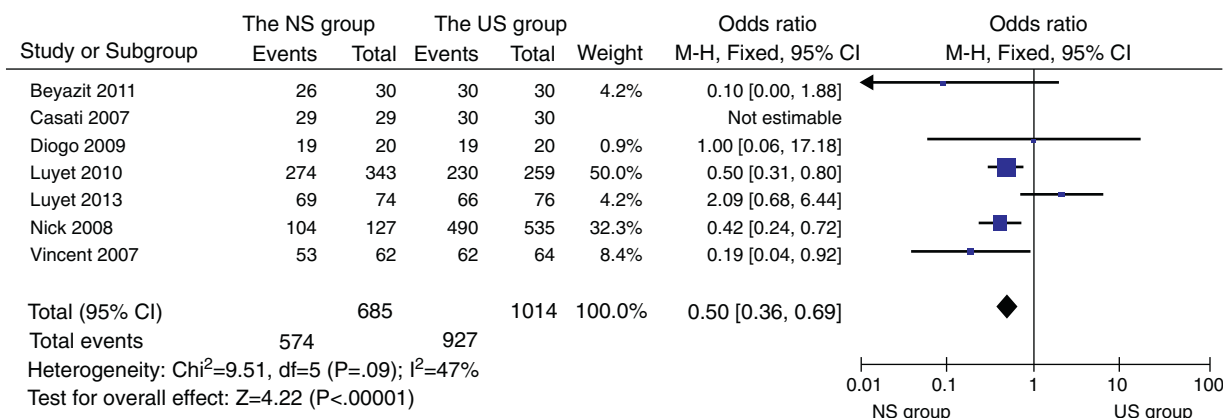


**Figure 3** Analysis of controlled studies for onset time of AXB: without ultrasound guidance vs. ultrasound guidance in the patients with AXB. 95% CI, 95% confidence interval; M-H, Mantel-Haenszel; df, degrees of freedom; OR, odds ratio; US, ultrasound.

US group than the controlled group (total 1706 patients; Heterogeneity:  $\text{Chi}^2 = 167.57$ ,  $p < 0.00001$ ;  $I^2 = 96\%$ ; OR: 3.88; 95% CI [3.11, 4.65]) (Fig. 2). The onset of sensory time is also shorter in the US group than the controlled group (total 109 patients; Heterogeneity:  $\text{Chi}^2 = 0.13$ ,  $p = 0.004$ ;  $I^2 = 0\%$ ; OR: 3.68; 95% CI [1.15, 6.21]) (Fig. 3). The data analysis of subgroup showed that the success rate was higher in the US group compared to the NS group (91.42% vs. 83.80%, total 1699 patients; Heterogeneity:  $\text{Chi}^2 = 9.51$ ,  $p < 0.0001$ ;  $I^2 = 47\%$ ; OR: 0.50; 95% CI [0.36, 0.69]) (Fig. 4).

## Discussion

Axillary brachial plexus block is applicable to operation of elbow and on the lower part of elbow, can prevent the tourniquet pain, also can increase the blood flow of upper limb.<sup>16-18</sup> Axillary brachial plexus can block including median nerve, ulnar nerve, musculocutaneous nerve, radial nerve and all terminal branch. Musculocutaneous nerve is usually issued from axillary Fasciculus lateralis, so the AXB is often incomplete. The nerve stimulator and ultrasound



**Figure 4** Analysis of controlled studies for performance time of AXB: nerve stimulate vs. ultrasound guidance in the patients with AXB. 95% CI, 95% confidence interval; M-H, Mantel-Haenszel; df, degrees of freedom; OR, odds ratio; US, ultrasound; NS, nerve stimulate.

guided axillary brachial plexus block significantly improve the success rate.

Although the nerve stimulator could be able to locate the target nerve, but because the injection of local anesthetic nerve had no idea to guarantee encased completely, so the nerve stimulator block has 10–15% failure rate.<sup>19,20</sup> Ultrasonic monitoring can ensure that after the injection of drug, the nerve bundle was surrounding and infiltrating, thereby improving the axillary brachial plexus block success rate. However, the different levels of anesthesia operator may not fully be able to distinguish each nerve in ultrasound images. Especially the radial nerve were difficult to locate, and is often confused with axillary artery of posterior wall.<sup>21</sup>

The depth of insertion of the needle and the duration of axillary block placement may affect the pain intensity.<sup>4,13,22,23</sup> Patients who get AXB with ultrasound (US) guidance were less painful and more comfortable than the patients get AXB with neurostimulation.<sup>24</sup> It was suggested that ultrasound requested less number of needle passes than neurostimulation.<sup>7</sup>

In conclusion, ultrasound guidance for axillary brachial plexus block improved the success rate and decreased the performance time and onset time. The visualization technology greatly reduced the possibility of occurrence of error, such as perforating vessels and local anesthetics poisoning and improved the safety. So it is the ideal option for upper limb operation.

## Conflicts of interest

The authors declare no conflicts of interest.

## Acknowledgements

This work is supported by Grant No. SZD0613 (to Dr. Wang) from the Technology Bureau of Suzhou, China. Dr. Wang also received support from the Revitalizing the Key Talent's Subsidy Project in Science and Education (Jiangsu Province, China).

## References

- Gritsenko K, Khelemsky Y, Kaye AD, et al. Multimodal therapy in perioperative analgesia. *Best Pract Res Clin Anaesthesiol.* 2014;28:59–79.
- Liu SS, Strodtbeck WM, Richman JM, et al. A comparison of regional versus general anesthesia for ambulatory anesthesia: a meta-analysis of randomized controlled trials. *Anesth Analg.* 2005;101:1634–42.
- Rodríguez J, Taboada M, Del Río S, et al. A comparison of four stimulation patterns in axillary block. *Reg Anesth Pain Med.* 2005;30:324–8.
- Chan VW, Perlas A, McCartney CJ, et al. Ultrasound guidance improves success rate of axillary brachial plexus block. *Can J Anaesth.* 2007;54:176–82.
- Ranganath A, Srinivasan KK, Iohom G. Ultrasound guided axillary brachial plexus block. *Med Ultrason.* 2014;16:246–51.
- Zencirci B. Comparison of nerve stimulator and ultrasonography as the techniques applied for brachial plexus anesthesia. *Int Arch Med.* 2011;21:1–4.
- Casati A, Danelli G, Baciarello M, et al. A prospective, randomized comparison between ultrasound and nerve stimulation guidance for multiple injection axillary brachial plexus block. *Anesthesiology.* 2007;106:992–6.
- Danelli G, Bonarelli S, Tognú A, et al. Prospective randomized comparison of ultrasound-guided and neurostimulation techniques for continuous interscalene brachial plexus block in patients undergoing coracoacromial ligament repair. *Br J Anaesth.* 2012;108:1006–10.
- Conceição DB, Helayel PE, de Oliveira Filho GR. A comparative study between ultrasound and neurostimulation guided axillary brachial plexus block. *Rev Bras Anesthesiol.* 2009;59:585–91.
- Luyet C, Schüpfer G, Wipfli M, et al. Different learning curves for axillary brachial plexus block: ultrasound guidance versus nerve stimulation. *Anesthesiol Res Pract.* 2010:1–7.
- Luyet C, Constantinescu M, Waltenspül M, et al. Transition from nerve stimulator to sonographically guided axillary brachial plexus anesthesia in hand surgery: block quality and patient satisfaction during the transition period. *J Ultrasound Med.* 2013;32:779–86.
- Lo N, Brull R, Perlas A, et al. Evolution of ultrasound guided axillary brachial plexus blockade: retrospective analysis of 662 blocks. *Can J Anaesth.* 2008;55:408–13.
- Sites BD, Beach ML, Spence BC, et al. Ultrasound guidance improves the success rate of a perivascular axillary plexus block. *Acta Anaesthesiol Scand.* 2006;50:678–84.
- Soeding PE, Sha S, Roysse CE, et al. A randomized trial of ultrasound guided brachial plexus anaesthesia in upper limb surgery. *Anaesth Intensive Care.* 2005;33:719–25.
- Strub B. What benefits does ultrasound-guided axillary block for brachial plexus anaesthesia offer over the conventional blind approach in hand surgery. *The Journal of Hand Surgery.* 2011;36:778–86.
- Lo Monte AI, Damiano G, Mularo A, et al. Comparison between local and regional anesthesia in arteriovenous fistula creation. *J Vase Access.* 2011;12:331–5.
- Iskandar H, Wakim N, Benard A, et al. The effects of interscalene brachial plexus block on humeral arterial blood flow: a Doppler Ultrasound study. *Anesth Analg.* 2005;101:279–81.
- Shemesh D, Olsha O, Orkin D, et al. Sympathectomy like effects of brachial plexus block in arteriovenous access surgery. *Ultrasound Med Biol.* 2006;32:817–22.
- Abrahams MS, Aziz MF, Fu RF, et al. Ultrasound guidance compared with electrical neurostimulation for peripheral nerve block: a systematic review and meta-analysis of randomized controlled trials. *Br J Anaesth.* 2009;102:408–17.
- Liu FC, Liou JT, Tsai YF. Efficacy of ultrasound guided axillary brachial plexus block: a comparative study with nerve stimulator-guided method. *Chang Gung Med.* 2005;28:396–402.
- Marhofer P, Chan VW. Ultrasound guided regional anesthesia: current concepts and future trends. *Pulesth Analg.* 2007;104:1265–9.
- Koscielniak-Nielsen ZJ, Rasmussen H, Nielsen PT. Patients' perception of pain during axillary and humeral blocks using multiple nerve stimulations. *Reg Anesth Pain Med.* 2004;29:328–32.
- Schwemmer U, Schleppers A, Markus C, et al. Operative management in axillary brachial plexus blocks: comparison of ultrasound and nerve stimulation. *Anaesthesist.* 2006;55:451–6.
- Bloc S, Mercadal L, Garnier T, et al. Comfort of the patient during axillary blocks placement: a randomized comparison of the neurostimulation and the ultrasound guidance techniques. *Eur J Anaesthesiol.* 2010;27:628–33.