



SYSTEMATIC REVIEW

Patent blue V dye anaphylaxis: a case report and literature review



Diogo Costa *, Mauro Mendonça, Michael Lopes, Ana Luísa Fernandes, Sara Nunes, Sofia Müller

Hospital Dr. Nélio Mendonça, Funchal, Portugal

Received 24 January 2019; accepted 31 May 2020
Available online 16 October 2020

KEYWORDS

Anaphylaxis;
Case reports;
Coloring agents;
Drug eruptions;
Review;
Sulfan Blue

Abstract

Background: Anaphylaxis is a constant perioperative concern due to the exposure to several agents capable of inducing hypersensitivity reactions. Patent blue V (PBV), also known as Sulfan Blue, a synthetic dye used in sentinel node research in breast surgery, is responsible for 0.6% of reported anaphylactic conditions. We present a case of a 49-year-old female patient who underwent left breast tumorectomy with sentinel lymph node staging using PBV and experienced an anaphylactic reaction.

Methods: We conducted a literature search through PubMed for case reports, case series, review and systematic reviews since 2005 with the keywords “anaphylaxis” and “patent blue”. We then included articles found in these publications’ reference sections.

Results: We found 12 relevant publications regarding this topic. The main findings are summarized, with information regarding the clinical presentation, management, and investigation protocol. Hypotension is the most common clinical manifestation. The presentation is usually delayed when compared with anaphylaxis from other agents and cutaneous manifestations are occasionally absent. Patients may have had previous exposure to the dye, used also as a food, clothes and drug colorant.

Conclusion: The diagnosis of anaphylaxis in patients under sedation or general anesthesia may be difficult due to particularities of the perioperative context. According to the published literature, the presentation of the reaction is similar in most cases and a heightened clinical sense is key to address the situation appropriately. Finding the agent responsible for the allergic reaction is of paramount importance to prevent future episodes.

© 2020 Sociedade Brasileira de Anestesiologia. Published by Elsevier Editora Ltda. This is an open access article under the CC BY-NC-ND license (<http://creativecommons.org/licenses/by-nc-nd/4.0/>).

* Corresponding author.

E-mail: abdiogocosta@gmail.com (D. Costa).

PALAVRAS-CHAVE

Anafilaxia;
Relato de caso;
Corantes;
Erupções
medicamentosas;
Revisão;
Azul Patente V

Anafilaxia por corante azul patente V: relato de caso e revisão da literatura**Resumo**

Introdução: A anafilaxia pode ocorrer durante o período perioperatório devido à exposição a diversos agentes capazes de induzir reações de hipersensibilidade. O corante Sintético Azul Patente V (APV), também conhecido como Sulfan Blue, é usado na pesquisa de linfonodo sentinela em cirurgia de mama, e é responsável por 0,6% dos eventos anafiláticos relatados. Descrevemos o caso de uma paciente de 49 anos de idade, submetida à tumorectomia de mama esquerda com estadiamento de linfonodo sentinela, em que se empregou o APV e que apresentou reação anafilática.

Método: Por meio do PubMed, pesquisamos publicações que documentavam relatos de casos, séries de casos, revisões e revisões sistemáticas desde 2005 usando as palavras-chave "anaphylaxis" e "patent blue". Em seguida, incluímos artigos encontrados na lista de referências dessas publicações.

Resultados: Encontramos 12 publicações relevantes sobre o tópico. Os principais achados estão resumidos, com informações do quadro clínico, tratamento e protocolo de investigação. A hipotensão foi a manifestação clínica mais frequente. De forma geral, o quadro clínico tem início tardio quando comparado à anafilaxia por outros agentes e, ocasionalmente, as manifestações cutâneas estão ausentes. Os pacientes podem ter tido exposição prévia ao APV, que também é usado como corante de alimentos, roupas e medicamentos.

Conclusão: O diagnóstico de anafilaxia em pacientes sob sedação ou anestesia geral pode ser difícil devido às peculiaridades do contexto perioperatório. Segundo a literatura publicada, a apresentação da reação é semelhante na maioria dos casos e um discernimento clínico aguçado é fundamental para enfrentar o evento adequadamente. Encontrar o agente responsável pela reação alérgica é essencial para a prevenção de futuros episódios.

© 2020 Sociedade Brasileira de Anestesiologia. Publicado por Elsevier Editora Ltda. Este é um artigo Open Access sob uma licença CC BY-NC-ND (<http://creativecommons.org/licenses/by-nc-nd/4.0/>).

Introduction

Perioperative anaphylaxis is a potentially fatal hypersensitivity reaction. It has an estimated incidence of 1 in 10,000 anesthetic procedures¹ and a mortality rate of less than 0.001%.² The main agents responsible for anaphylaxis during the perioperative period are antibiotics, latex and neuromuscular blocking drugs. Antiseptics and dyes, such as Patent blue V, also account for an important number of reactions.³

Patent blue V is a synthetic dye used for medical purposes, such as lymphatic mapping in the context of sentinel lymph node biopsy in breast cancer and melanoma, and coloring purposes in the textile, cosmetic and food industry (food additive no. E131). Other dyes of the same family are also used for breast cancer staging, such as isosulfan blue and methylene blue.

With the following case report, we intend to review the diagnosis and management of anaphylaxis to PBV in a patient under general anesthesia, the investigation and future implications. This case report was prepared following CARE Guidelines⁴ and was approved by the hospital's Ethics Committee for Health and Scientific Committee for Investigation.

Case report

A female patient, 49-years-old, with a weight of 80 kilograms and a height of 1.60 meters, classified as ASA

(American Society of Anesthesiologists) physical status II (obesity and dyslipidemia). No known drug or food allergies, nor previous surgeries.

The patient underwent left breast tumorectomy with sentinel lymph node staging under balanced general anesthesia and pectoralis nerve II block. A second-generation laryngeal mask was used. She was premedicated with 2 mg of midazolam, followed by the administration of antibiotic prophylaxis with 2 g of cefazolin, this being considered the minute zero. After ten minutes, for anesthetic induction, 0.1 mg of fentanyl, 150 mg of propofol and 4 mg of dexamethasone were administered. The nerve block was performed with 20 mL ropivacaine 0.2% after 15 minutes. The surgery started 30 minutes after the antibiotic's administration. After 45 minutes, the administration of patent blue dye took place. At minute 55, a sudden onset of hypotension and bradycardia occurred, followed by bronchospasm. The treatment started with 5 mg ephedrine, fluid challenge with 500 mL of Ringer's lactate (6.25 mL kg⁻¹), 400 mcg of inhaled salbutamol, administered with a metered dosed inhaler through an adapter between the laryngeal mask and ventilator tubing, and 200 mg of hydrocortisone, the maximum recommended dose for adults. After a new reassessment of pulmonary auscultation, a blue confluent maculopapular rash was found in the thoracic region (Fig. 1).

An anaphylactic reaction was suspected as the etiology of these manifestations and 0.5 mg of intramuscular adrenaline and 2 mg of clemastine, a histamine H1 antagonist, were administered with hemodynamic and respiratory

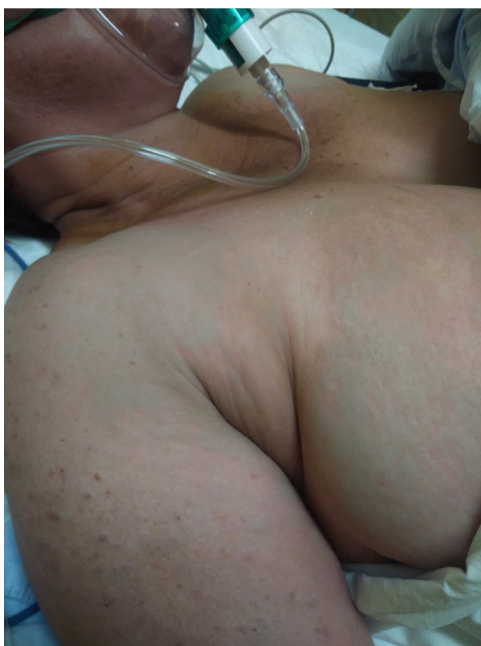

Figure 1 Blue maculopapular rash in the shoulder and right breast.

improvement. Other possible causes such as hemorrhagic complication, local anesthetic system toxicity or pulmonary embolism were considered, but excluded when the rash became evident.

Due to the clinical and hemodynamic stability, it was decided to finish the surgery and awake the patient. After the removal of surgical fields, the extension of the blue exanthema on the entire body surface became evident (Fig. 2). After urethral catheterization, greenish-colored urine output was observed (Fig. 3).

The patient was admitted to an intermediate care unit for clinical surveillance. With the improve of cutaneous manifestations, the patient was discharged from the intermediate care unit into the ward after 24 hours, and sent home after 2 days, without further complications. The patient was afterwards consulted in the immunoallergology department, where Skin Prick Test (SPT), Intradermal Test (IDT), and Drug Provocation Tests (DPT) were performed. The DPT were negative for dexamethasone, ropivacaine, and midazolam. The SPT and IDT were negative for propofol, fentanyl, cefazolin, and latex. PBV 2.5% was used for SPT and 0.00025% for IDT and both tested positive. SPT for methylene blue, another dye of the same family as PBV, also tested positive.

Discussion

This case illustrates a common situation that anesthesiologists are often faced with sudden onset of cardiovascular and/or respiratory distress that requires prompt supportive care while the diagnosis is investigated. A complete physical examination is not always possible in the intraoperative setting, but it is an important tool that should not be overlooked.

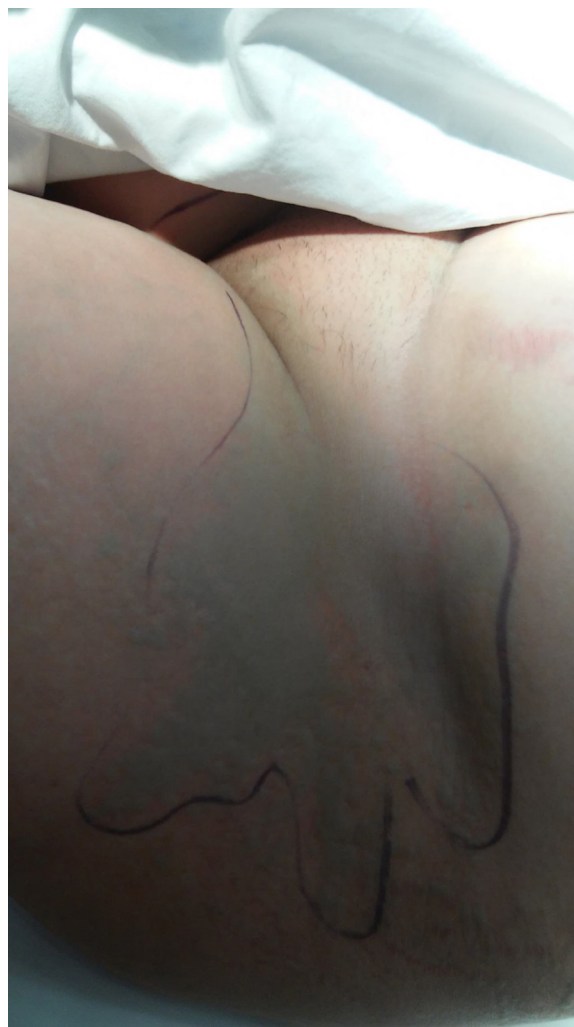


Figure 2 Blue maculopapular rash in the inguinal region, outlined with a marker.

Table 1 Severity grading of anaphylactic reactions according to Ring and Messmer.

Grade	Symptoms
I	Skin symptoms and/or mild fever reaction Measurable, but not life-threatening
II	Cardiovascular reaction (tachycardia, hypotension) Gastrointestinal disturbance (nausea) Respiratory disturbance
III	Shock, life-threatening spasm of smooth muscles (bronchi, uterus)
IV	Cardiac and/or respiratory arrest

Several case reports, case series, and retrospective studies of allergic reactions to PBV have been published over the last years.⁵⁻¹⁰ The 6th National Audit Project (NAP6) study³ analyzed the prevalence of grade 3-4 reactions (Ring and Messmer scale)¹¹ (Table 1) in the perioperative setting in the United Kingdom. After reviewing 266 reports, PBV was responsible for 9 cases. Based on their estimates, the inci-

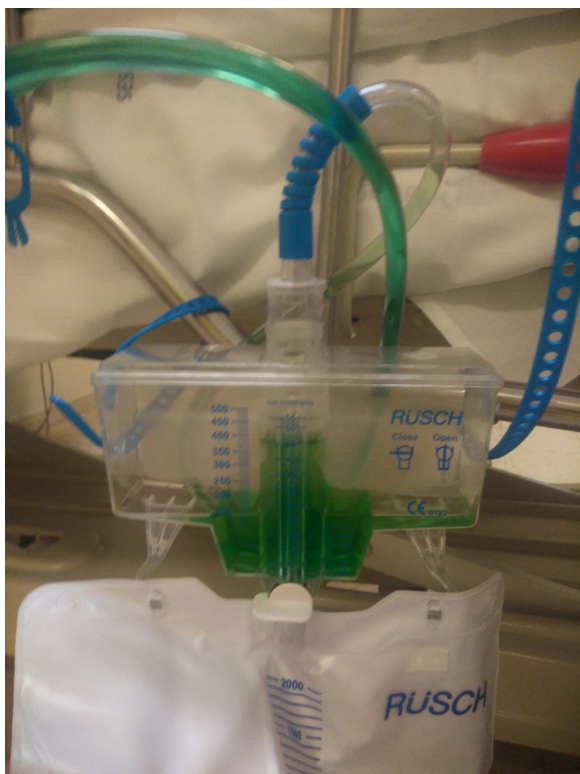


Figure 3 Greenish colored urine after urinary catheterization.

dence of grade 3–4 anaphylaxis to PBV was 14.6 per 100,000 administrations, higher than that of succinylcholine.

Johansson et al.⁵ and Barthemes et al.⁶ reported the clinical aspects of these reactions by analyzing the national registry for anaphylaxis and data from other ongoing studies, respectively. The former studied a pool of 7917 patients who were administered PBV and a total of 42 (0.5%) developed grade I–III allergic reactions. The latter identified 9 with anaphylaxis to PBV from the Norwegian national registry for anaphylactic reactions during anesthesia.

From these and other case reports, we managed to find common clinical manifestations of the reactions. The first symptoms usually start 5 to 25 minutes after the injection of the dye, depending on the time required for it to reach the central circulation.^{3,5,7} Some cases report more than 60 minutes. The most severe reactions tend to happen sooner after dye injection.⁵

In the anesthetized patient, a fall in arterial pressure and an increase in the heart rate usually mark the onset of the reaction.^{5,7,10} Cutaneous symptoms such as erythema and/or urticaria are characteristic but not always present.^{3,5} The blue-colored urticaria is more common in late reactions and is more vivid near the area of injection.⁵ The appearance of colored skin manifestations in other parts of the body might be explained by previous exposure to the allergen in clothes and cosmetics, for example.^{5,7,8,10}

Blue or green serum, urine and skin coloration usually lasts for 24 hours, but in some cases, it may persist.⁷ Prolonged skin staining after PBV use may last from one week up to 25 months, even if not associated with anaphylaxis.¹²

In the awake patient, when PBV is used preoperatively to dye nodules,⁹ pruritus, dyspnea, and gastrointestinal symptoms are the most common.

The response to fluid challenge, Trendelenburg position, and ephedrine is usually poor and most patients require adrenaline to reverse the shock.⁵ Cardiopulmonary arrest usually occurs as pulseless electric activity.³ No deaths have been reported in the literature as a result of PBV anaphylaxis.

Biphasic reactions have been described and are attributed to the slow release of the dye from the subcutaneous tissue where it was injected into the central circulation.⁸

The allergic reaction to PBV is considered to be IgE-mediated.^{5,8,10,13} Serum tryptase is usually increased in all patients, except in some cases with minor symptoms,⁵ indicating the degranulation from mast cells after exposure to the allergenic-IgE complex. The anaphylactic reaction usually occurs after previous exposure to the allergen, explained by the presence of this molecule in food, clothes and drugs.^{5,7,8,10} Even though methylene blue is structurally different from PBV, cross reactivity has been described¹⁰ and was present in this patient.

In the perioperative context, such as in the induction of general anesthesia, where several drugs are administered in a short period of time, identifying the culprit of the anaphylactic reaction requires several tests. The main diagnostic tools for the investigation are skin prick and intradermal test.

Haque et al.¹⁴ proposed an investigation protocol pending prospective validation that started with SPT to PBV 1:10 (2.5 mg mL^{-1}), followed by SPT to PBV 1:1 (25 mg mL^{-1}), if the first was negative, and IDT to PBV 1:100 if both were negative. Any positive result confirmed the diagnosis of PBV allergy. In this case report and in Viegas et al.¹⁰ IDT testing was made with PBV 1:10,000.

Some authors suggest avoiding PBV in patients with a history of allergy to foods containing E131 and that premedication with corticosteroids may decrease the severity of the anaphylactic reaction.⁶

Conclusions

The recognition and interpretation of the signs and symptoms of anaphylaxis, with the peculiarities inherent to the anesthetized patient are of vital importance. Early administration of adrenaline, maintenance of airway patency and oxygenation, and volume resuscitation are the main pillars of treatment. The different agents to which patients are exposed in a short period of time makes it difficult to identify the trigger, but some clinical features may suggest a particular one. The referral to an allergology consultation is essential for the investigation and to prevent future episodes.

Conflicts of interest

The authors declare no have conflicts of interest.

References

1. Mertes PM, Alla F, Trechot P, et al. Anaphylaxis during anesthesia in France: an 8-year national survey. *J Allergy Clin Immunol*. 2011;128:366–73.
2. Muraro A, Roberts G, Worm M, et al. Anaphylaxis: guidelines from the European Academy of Allergy and Clinical Immunology. *Allergy*. 2014;69:1026–45.
3. Harper NJN, Cook TM, Garcez T, et al. Anaesthesia, surgery, and life-threatening allergic reactions: epidemiology and clinical features of perioperative anaphylaxis in the 6th National Audit Project (NAP6). *Br J Anaesth*. 2018;121:159–71.
4. Gagnier JJ, Kienle G, Altman DG, et al. The CARE guidelines: consensus-based clinical case reporting guideline development. *J Clin Epidemiol*. 2014;67:46–51.
5. Hunting AS, Nopp A, Johansson SGO, et al. Anaphylaxis to patent blue V. I. Clinical aspects. *Allergy*. 2010;65:117–23.
6. Barthelmes L, Goyal A, Newcombe RG, et al. Adverse reactions to patent blue V dye – the NEW START and ALMANAC experience. *Eur J Surg Oncol*. 2010;36:399–403.
7. Maranhao MVM, Da Nobrega DKA, Anunciaçao CEC, et al. Allergic reaction to patent blue dye in breast surgery – case report. *Rev Bras Anesthesiol*. 2016;66:433–6.
8. Scherer K, Studer W, Figueiredo V, et al. Anaphylaxis to isosulfan blue and cross-reactivity to patent blue V: case report and review of the nomenclature of vital blue dyes. *Ann Allergy Asthma Immunol*. 2006;96:497–500.
9. Wu TT, Chang YC, Lee JM, et al. Anaphylactic reaction to patent blue V used in preoperative computed tomography-guided dye localization of small lung nodules. *J Formos Med Assoc*. 2016;115:288–9.
10. Viegas LP, Lopes A, Campos-Melo A, et al. Patent Blue anaphylaxis: case report. *J Allergy Clin Immunol Pract*. 2015;3:112–3.
11. Ring J, Messmer K. Incidence and severity of anaphylactoid reactions to colloid volume substitutes. *Lancet*. 1977;309:466–9.
12. Govaert GAM, Oostenbroek RJ, Plaisier PW. Prolonged skin staining after intradermal use of patent blue in sentinel lymph node biopsy for breast cancer. *Eur J Surg Oncol*. 2005;31:373–5.
13. Johansson SGO, Nopp A, Oman H, et al. Anaphylaxis to Patent Blue V. II. A unique IgE-mediated reaction. *Allergy*. 2010;65:124–9.
14. Haque RA, Wagner A, Whisken JA, et al. Anaphylaxis to patent blue V: a case series and proposed diagnostic protocol. *Allergy*. 2010;65:396–400.