



REVISTA BRASILEIRA DE ANESTESIOLOGIA

Official Publication of the Brazilian Society of Anesthesiology
www.sba.com.br



SCIENTIFIC ARTICLE

Sphenopalatine ganglion pulsed radiofrequency treatment in patients suffering from chronic face and head pain



Mert Akbas^{a,*}, Emel Gunduz^b, Suat Sanli^b, Arif Yegin^a

^a Department of Anaesthesiology, Division of Algology, Medical Faculty, Akdeniz University, Antalya, Turkey

^b Department of Anaesthesiology, Medical Faculty, Akdeniz University, Antalya, Turkey

Received 18 April 2014; accepted 2 June 2014

Available online 16 September 2014

KEYWORDS

Sphenopalatine ganglion;
Pulsed radiofrequency;
Chronic face and head pain

Abstract

Purpose: There are various facial pain syndromes including trigeminal neuralgia, trigeminal neuropathic pain and atypical facial pain syndromes. Effectiveness of the pulsed radiofrequency in managing various pain syndromes has been clearly demonstrated. There are a limited number of studies on the pulsed radiofrequency treatment for sphenopalatine ganglion in patients suffering from face and head pain. The purpose of this study is to evaluate the satisfaction of pulsed radiofrequency treatment at our patients retrospectively.

Methods: Infrazygomatic approach was used for the pulsed radiofrequency of the sphenopalatine ganglion under fluoroscopic guidance. After the tip of the needle reached the target point, 0.25–0.5 ms pulse width was applied for sensory stimulation at frequencies from 50 Hz to 1 V. Paraesthesias were exposed at the roof of the nose at 0.5–0.7 V. To rule out trigeminal contact that led to rhythmic mandibular contraction, motor stimulation at a frequency of 2 Hz was applied. Then, four cycles of pulsed radiofrequency lesioning were performed for 120 s at a temperature of 42 °C.

Results: Pain relief could not be achieved in 23% of the patients (unacceptable), whereas pain was completely relieved in 35% of the patients (excellent) and mild to moderate pain relief could be achieved in 42% of the patients (good) through sphenopalatine ganglion-pulsed radiofrequency treatment.

Conclusion: Pulsed radiofrequency of the sphenopalatine ganglion is effective in treating the patients suffering from intractable chronic facial and head pain as shown by our findings. There is a need for prospective, randomized, controlled trials in order to confirm the efficacy and safety of this new treatment modality in chronic head and face pain.

© 2014 Sociedade Brasileira de Anestesiologia. Published by Elsevier Editora Ltda. All rights reserved.

* Corresponding author.

E-mail: akbasmert@akdeniz.edu.tr (M. Akbas).

PALAVRAS-CHAVE

Gânglio
esfenopalatino;
Radiofrequência
pulsada;
Dor crônica facial e
de cabeça

Tratamento com radiofrequência pulsada para gânglio esfenopalatino em pacientes com dor crônica de face e cabeça

Resumo

Objetivo: Existem várias síndromes de dor facial, incluindo neuralgia trigeminal, dor neuropática trigeminal e síndromes atípicas de dor facial. A eficácia da radiofrequência pulsada (RFP) para o manejo de várias síndromes de dor foi claramente demonstrada. Há um número limitado de estudos sobre o tratamento com RFP para gânglio esfenopalatino (GEP) em pacientes que sofrem de dor facial e de cabeça. O objetivo deste estudo foi avaliar a satisfação do tratamento com PRF em nossos pacientes, retrospectivamente..

Métodos: A abordagem infrazigomática foi usada para a RFP do GEP sob orientação fluoroscópica. Depois de a ponta da agulha atingir o ponto alvo, pulsos de 0,25 a 0,5 ms foram aplicados para a estimulação sensorial em frequências de 50 Hz a 1 V. Parestesias foram expostas no teto do nariz em 0,5 a 0,7 V. Para excluir o contato trigeminal que levou à contração mandibular rítmica, a estimulação motora foi aplicada na frequência de 2 Hz. Em seguida, quatro ciclos de RFP foram realizados durante 120 segundos a uma temperatura de 42 °C.

Resultados: O alívio da dor não foi obtido em 23% dos pacientes (inaceitável); enquanto a dor foi totalmente aliviada em 35% dos pacientes (excelente) e o alívio de leve a moderado da dor foi obtido em 42% dos pacientes (bom), com o tratamento RFP-GEP.

Conclusão: RFP para GEP é eficaz no tratamento de pacientes que sofrem de dor crônica intratável, facial e de cabeça, como mostrado por nossas descobertas. Estudos prospectivos, randômicos e controlados são necessários para confirmar a eficácia e segurança dessa nova modalidade de tratamento para dor crônica facial e de cabeça.

© 2014 Sociedade Brasileira de Anestesiologia. Publicado por Elsevier Editora Ltda. Todos os direitos reservados.

Introduction

The etiologies of sphenopalatine ganglion (SPG) neuralgia include irritation of the ganglion caused by intranasal deformities such as deviated septum, septal spurs, and prominent turbinates.¹ There are studies reporting the use of SPG block to relieve various pain syndromes such as post-traumatic headache, postherpetic neuralgia, myofascial pain involving the head-neck-shoulders,² pain due to tongue cancer and cancer of the floor of the mouth, atypical odontalgia, post-temporomandibular joint (TMJ) surgery, angina, back pain, sciatica and dysmenorrhea; however, many of these reports are anecdotal. Therefore, there is a need for well-controlled studies on the above-mentioned indications. SPG neuralgia, trigeminal neuralgia (TN), migraine headaches, cluster headaches, postherpetic neuralgia and atypical facial pain are currently the most common indications for SPG block.³

Treatment protocols generally begin with oral medications, such as anticonvulsants, nonsteroidal anti-inflammatory drugs, antidepressants and may progress to invasive procedures such as percutaneous or open surgical procedures. Carbamazepine has been mainly used so far as an anticonvulsant for the treatment of chronic facial and head pain¹ although its efficacy decreases in time.² Other pharmacotherapies such as pregabalin, baclofen, oxcarbazepine, and lamotrigine have been used; however, they do not seem to be as effective as carbamazepine.³ Therefore, invasive treatments such as neurosurgical ablation and microvascular decompression are needed. The success rate of the surgical procedures is initially as high as 98%, whereas

that it falls down to 80% in the first 1–2 years and to 64% in 8–10 years as shown by many studies.⁴ Other less invasive options include chemical neurolysis (such as glycerol gangliolysis) and ablative or radiofrequency (RF) treatments. Radiofrequency thermocoagulation (RFTC) is a minimally invasive option to treat chronic facial and head pain. Following the sensory stimulation of nerves in awake patients under fluoroscopic guidance, thermal lesion is performed in cycles of 45–90 s at temperatures of 60–90 °C. The reports show that the success rate of RFTC is 83%, while the recurrence rate is 49% in 72 months. Dysesthesia has been observed in 25% of the cases undergoing this treatment modality.⁵

Pulsed radiofrequency (PRF) has been increasingly drawing attention because it is delivered in pulses; thus it gives time for heat and energy dissipation. As a result, surrounding structures are less damaged.⁶ Animal studies showed histomorphological changes in PRF treated sciatic nerves at temperatures of 40–80 °C under continuous RF. Studies found that changes such as edema, cell and myelin pathological changes did not differ significantly between the sham and PRF groups, whereas such changes were significantly different in the continuous RF treatment group. Moreover, more pathological changes were observed under continuous RF treatment at 80 °C in contrast to 40 °C.⁷ Although PRF has been successful, multiple interventional therapies are needed for a successful treatment that focuses on the lives of patients.

The purpose of this study is to evaluate the patients who had performed PRF to SPG because of chronic face and head pain retrospectively.

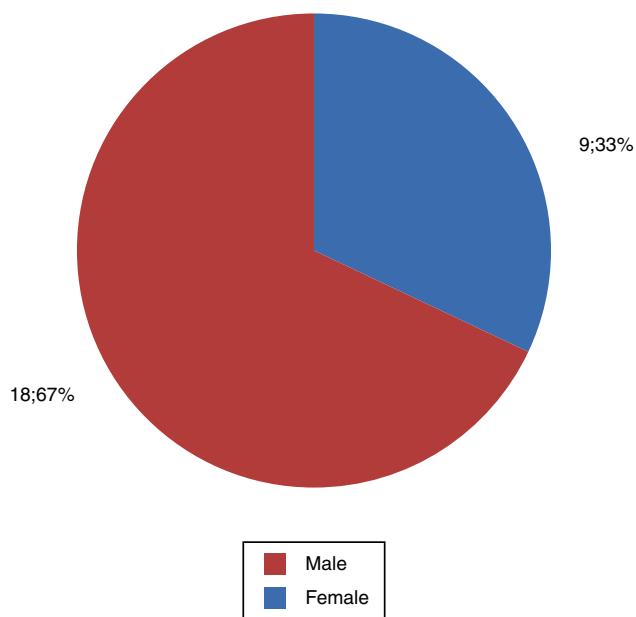


Figure 1 Patient demographics (sex) undergoing sphenopalatine ganglion pulsed radiofrequency treatment.

Patients and methods

27 patients suffering from head and face pain (9 male and 18 female) were evaluated underwent PRF treatment for SPG from January 2010 to December 2011 (Fig. 1). The study protocol was approved by the medical ethics committee of our hospital and a written informed consent was obtained from each patient. PRF was performed for the patients to manage chronic head and face pain caused by various etiologies such as atypical facial pain, SPG neuralgia due to Zona Zoster, atypical TN that did not respond to prior treatments and unilateral migraine headaches. All patients responded positively to diagnostic infrazygomatic local anesthetic and steroid block. The same pain management physician examined all patients and reviewed the imaging studies before the injection. We used the patient records retrospectively and clinical follow-up visits prospectively to collect data at

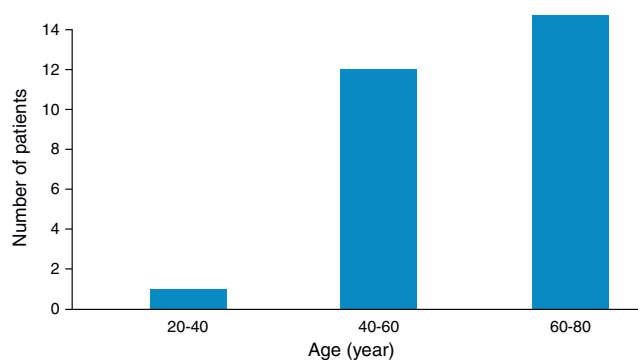


Figure 2 Patient demographics (age) undergoing sphenopalatine ganglion pulsed radiofrequency treatment.

the University Faculty of Medicine, Department of Anesthesiology, Division of Algology.

The age of our patients ranged from 27 to 78 years, with a mean age of 56 (Fig. 2). Symptoms were present for 3 months to 30 years. Infrazygomatic approach was used for the PRF of the SPG under fluoroscopic guidance (Fig. 3A). Patients were positioned in the supine position on the fluoroscopy table. Lateral view was obtained at mandibular level followed by the rotation of the head under continuous fluoroscopy to superimpose the two rami of the mandible. The angle of the C-arm was adjusted toward the head to see the pterygopalatine fossa in the shape of an “inverted vase”. Local anesthesia was administered to the skin and underlying tissue at the anterior ramus of the ipsilateral mandible below the zygoma. To facilitate the penetration of the 20-gauge PRF needle, a 16-gauge angiocath was inserted through the previously established skin entry point. Then, advancement of a 10-cm curved, blunt needle with a 10-mm active tip was realized under fluoroscopy. As described by Raj et al.,⁸ the needle was positioned medially, cephalad and slightly posteriorly toward the pterygopalatine fossa (Fig. 3B). The anterior–posterior fluoroscopic imaging confirmed that the needle lied adjacent to the lateral nasal mucosa at the superior-medial angle of the maxillary sinus.⁸ After the tip of the needle reached the target point, 0.25–0.5 ms pulse width was applied for sensory stimulation at frequencies

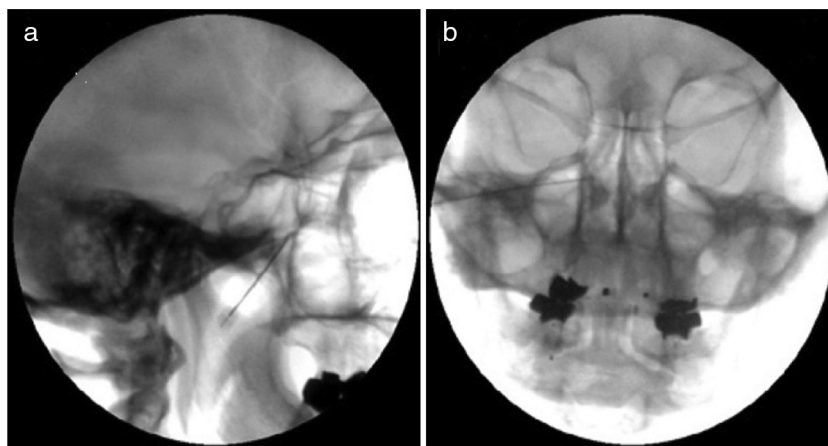


Figure 3 (A) Sphenopalatine ganglion pulsed radiofrequency treatment in pterygopalatine nerve. (B) Sphenopalatine ganglion pulsed radiofrequency treatment: lateral fluoroscopic imaging of the pterygopalatine fossa as an inverted vase.

Table 1 Satisfaction Scale after 3 months.

Unacceptable	7 (23%)
Excellent	9 (35%)
Good	11 (42%)

from 50 Hz to 1 V.⁹ Paraesthesias were exposed at the roof of the nose at 0.5–0.7 V. To rule out trigeminal contact that led to rhythmic mandibular contraction, motor stimulation at a frequency of 2 Hz was applied. Then, four cycles of PRF lesioning were performed for 120 s at a temperature of 42 °C.

A nurse who was not involved in the procedures asked the patients to rate their pain on Verbal Numerical Rating Scale (VNRS, 0–10) in 3 months after the procedure.

A subjective 3-point scale that was designed specifically for the culture of each patient was used to measure and understand the satisfaction of patients about the pain control procedure (unacceptable, good, excellent) (Table 1).

Results

The procedure was performed on the left side in sixty percent of the patients whereas it was performed on the right side in 29% and bilaterally in 11%.

Pain relief could not be achieved in 23% of the patients (unacceptable) (VNRS 7–10), whereas pain was completely relieved in 35% of the patients (excellent) (VNRS 0–2) and mild to moderate pain relief could be achieved in 42% of the patients (good) (VNRS 3–6) through SPG-PRF treatment (Fig. 1). Neither infection, epistaxis, hematoma, dysesthesia, numbness of the palate, maxilla or pharynx nor bradycardia were observed.

Mean and standard deviations in anthropometric and demographic data were given. Friedman test was applied for VNRS comparisons. Wilcoxon signed rank test was performed with Bonferroni correction. Significance was considered as 0.05.

Discussion

Chronic face-head pain imposes limitations for the patients and affects all family members. Patients present with anger and despair when they visit the pain clinic. Therefore, such pain should be managed immediately without any delay.

Percutaneous SPG-PRF treatment of head and facial pain was demonstrated to be surprisingly lengthy in this study. In Shah study,¹⁰ SPG-pulsed radiofrequency lesioning was performed on the patients for 19 months to relieve pain. 3 cycles of PRF was performed in that study while we performed 3 cycles. We had to repeat the procedure on the involved site in only 35% of our patients. No adverse effects including infection, epistaxis, hematoma, dysesthesia, numbness of palate, maxilla or pharynx or bradycardia were observed in our study. However, unexpected adverse effects were reported only in a few cases during RFTC of the SPG for headache.^{11,12}

The principle of radiofrequency (RF) is that it is in the form of alternating electrical current and the heat is generated around the tip of the electrode. Cell culture studies have shown that exposure creates a biological effect due to

the induction of early gene expression in the dorsal horn.¹³ RFTC has been used to destroy the tissue in TN, ablate tumor metastasis, perform lateral cordotomy in unilateral malignant pain, destroy dorsal root ganglion in spinal pain and treat discogenic back pain. But RF has a signal output which is typically a continuous wave of RF voltage, whereas PRF has a RF wave that is broken into short bursts of signal output. Between such bursts, there are some time periods with no signal. There is often no need to increase the average target tissue temperature above 42 °C for the PRF to be effective.¹⁴

Trigeminal radiosurgery has been recently claimed to be an alternative surgical procedure to treat chronic cluster headache.^{15,16} However, it does not help relieving the pain in a long-term and has an association with a high rate of toxicity.^{17,18}

Combination of sphenopalatine and trigeminal neurolytic block was reported to be successful in a case study to relieve facial pain due to a tumor that caused a large mid-facial defect.¹⁹ Sphenopalatine blocks have been successfully used to treat cluster headaches that typically occur in the peri-orbital region as described by the patient.²⁰

PRF of the SPG is effective in treating the patients suffering from intractable chronic facial and head pain as shown by our findings. But we must remember that there is a scarcity of studies about the PRF application of the SPG and more studies need to be performed. The incidence of adverse events may be reduced because the needle is inserted precisely to the target point under the real-time fluoroscopy and electrical stimulation before radiofrequency lesioning.

Conflicts of interest

The authors declare no conflicts of interest.

References

1. Eagle W. Sphenopalatine ganglion neuralgia. *Arch Otolaryngol.* 1942;35:66–84.
2. Ferrante FM, Kaufman AG, Dunbar SA, et al. Sphenopalatine ganglion block for the treatment of the head, neck, and shoulders. *Reg Anesth Pain Med.* 1998;23:30–6.
3. Klein RN, Burk DT, Chase PF. Anatomically and physiologically based guidelines for use of the sphenopalatine ganglion block versus the stellate ganglion block to reduce atypical facial pain. *Cranio.* 2001;19:48–55.
4. Sluijter M, Racz GB. Technical aspects of radiofrequency. *Pain Pract.* 2002;2:195–200.
5. Nurmikko TJ, Eldridge PR. Trigeminal neuralgia – pathophysiology, diagnosis and current treatment. *Br J Anaesth.* 2001;87:117–32.
6. Fields HL. Treatment of trigeminal neuralgia. *N Engl J Med.* 1996;334:1125–6.
7. Vatanserver D, Tekin I, Tuglu I, et al. A comparison of the neuroablative effects of conventional and pulsed radiofrequency techniques. *Clin J Pain.* 2008;24:717–24.
8. Raj P, Lou L, Erdine S, et al. Sphenopalatine ganglion block and neurolysis. Radiographic imaging for regional anesthesia and pain management. 1st ed. Philadelphia, PA: Churchill Livingstone; 2003.
9. Raj P, Rauck R, Racz G. Autonomic nerve blocks. In: Raj P, editor. *Pain medicine: a comprehensive review.* St. Louis, MO: Mosby; 1996. p. 227–56.

10. Shah RV, Racz GB. Long-term relief of posttraumatic headache by sphenopalatine ganglion pulsed radiofrequency lesioning: a case report. *Arch Phys Med Rehabil.* 2004;85:1013–6.
11. Goadsby PJ. Pathophysiology of cluster headache: a trigeminal autonomic cephalgia. *Lancet Neurol.* 2002;1:251–7.
12. Bayer E, Racz GB, Miles D, et al. Sphenopalatine ganglion pulsed radiofrequency treatment in 30 patients suffering from chronic face and head pain. *Pain Pract.* 2005;5:223–7.
13. Salar G, Ori C, Iob I, et al. Percutaneous thermocoagulation for sphenopalatine ganglion neuralgia. *Acta Neurochir.* 1987;84:24–8.
14. Erdine S, Bilir A, Cosman ER, et al. Ultrastructural changes in axons following exposure to pulsed radiofrequency fields. *Pain Pract.* 2009;9:407–17.
15. Donnet A, Valade D, Régis J. Gamma knife treatment for refractory cluster headache: prospective open trial. *J Neurol Neurosurg Psychiatry.* 2005;76:218–21.
16. Ford RG, Ford KT, Swaid S, et al. Gamma knife treatment of refractory cluster headache. *Headache.* 1998;38:3–9.
17. McClelland S, Barnett G, Neyman G, et al. Repeat trigeminal nerve radiosurgery for refractory cluster headache fails to provide long-term pain relief. *Headache.* 2007;47:298–300.
18. Donnet A, Tamura M, Valade D, et al. Trigeminal nerve radiosurgical treatment in intractable chronic cluster headache: unexpected high toxicity. *Neurosurgery.* 2006;59:1252–7.
19. Varghese BT, Koshy RC, Sebastian P, et al. Combined sphenopalatine ganglion and mandibular nerve, neurolytic block for pain due to advanced head and neck cancer. *Palliat Med.* 2002;16:447–8.
20. Sanders M, Zuurmond WW. Efficacy of sphenopalatine ganglion blockade in 66 patients suffering from cluster headache: a 12- to 70-month follow-up evaluation. *J Neurosurg.* 1997;87:876–80.