

SCIENTIFIC ARTICLE

The effect of thoracic paravertebral block on seroma reduction in breast surgery – a randomized controlled trial



Alparslan Kuş^a, Ufuk H. Yörükoğlu^{id a,*}, Can Aksu^a, Saffet Çınar^b,
Nuh Zafer Cantürk^b, Yavuz Gürkan^a

^a Kocaeli University Hospital, Department of Anesthesiology and Reanimation, Kocaeli, Turkey

^b Kocaeli University Hospital, Department of General Surgery, Kocaeli, Turkey

Received 25 May 2019; accepted 31 December 2019

Available online 3 May 2020

KEYWORDS

Paravertebral block;
Postoperative pain;
Seroma reduction;
Breast cancer

Abstract

Background: Increasing number of patients are being operated because of breast cancer. Seroma is the most common problem that occurs after surgery that increases morbidity. For postoperative pain management, Thoracic Paravertebral Block (TPVB) has long been considered the gold standard technique. With performing TPVB, sympathetic nerves are also blocked.

Objective: With this study, we aimed to search the effect of TPVB on seroma reduction in patients who undergo mastectomy and axillary node dissection surgery.

Methods: Forty ASA I–II female patients aged 18–65, who were scheduled to go under elective unilateral mastectomy and axillary lymph node resection were included to the study. Patients were randomized into two groups as TPVB and Control group. Ultrasound guided TPVB with 20 mL 0.25% bupivacaine was performed at T1 level preoperatively to the TPVB group patients. All patients were provided with i.v. patient-controlled analgesia device. Seroma formation amounts, morphine consumptions and Numeric Rating Scale (NRS) scores for pain were recorded 24th hour postoperatively.

Results and conclusions: Mean seroma formation at postoperative 24th hour was 112.5 ± 53.3 mL in the control group and 74.5 ± 47.4 mL in the TPVB group ($p=0.022$). NRS scores were similar between two groups ($p=0.367$) at postoperative 24th hour but mean morphine consumption at postoperative 24th hour was 5.6 ± 4 mg in the TPVB group, and 16.6 ± 6.9 mg in the control group ($p<0.001$). TPVB reduces the amount of seroma formation while providing effective analgesia in patients who undergo mastectomy and axillary lymph node removal surgery.

© 2020 Sociedade Brasileira de Anestesiologia. Published by Elsevier Editora Ltda. This is an open access article under the CC BY-NC-ND license (<http://creativecommons.org/licenses/by-nc-nd/4.0/>).

* Corresponding author.

E-mail: ufukyorukoglu@gmail.com (U.H. Yörükoğlu).

PALAVRAS-CHAVE

Bloqueio paravertebral;
Dor pós-operatória;
Redução de seroma;
Câncer de mama

Efeito do bloqueio paravertebral torácico na redução de seroma em cirurgia de mama – estudo randomizado controlado

Resumo

Introdução: Observa-se aumento do número de pacientes submetidos à cirurgia por neoplasia mamária. Seroma é a mais frequente complicação pós-operatória que aumenta a morbidade. Há muito tempo, considera-se o Bloqueio Paravertebral Torácico (BPVT) a técnica padrão ouro para o controle da dor pós-operatória. O BPVT provoca, igualmente, o bloqueio da inervação simpática.

Objetivo: Identificar o efeito do BPVT na redução de seroma em pacientes que realizaram mastectomia e dissecação dos linfonodos axilares.

Método: Foram incluídas no estudo 40 pacientes do sexo feminino ASA I–II, entre 18 e 65 anos de idade, submetidas a mastectomia eletiva unilateral com ressecção de linfonodos axilares. As pacientes foram randomizadas em grupo BPVT e grupo controle. As pacientes do grupo BPVT foram submetidas ao BPVT guiado por ultrassom no nível de T1 e 20 mL de bupivacaína 0,25% foram administrados antes da cirurgia. Bomba de infusão IV ACP foi prescrita para todas as pacientes. Na 24ª hora pós-operatória foram registradas a quantidade de produção de seroma, o consumo de morfina e a avaliação da dor pela escala de avaliação numérica (NRS – do inglês *Numeric Rating Scale*).

Resultados: A quantidade média de seroma na 24ª hora pós-operatória foi $112,5 \pm 53,3$ mL no grupo controle e $74,5 \pm 47,4$ mL no grupo BPVT ($p = 0,022$). Na 24ª hora pós-operatória a pontuação NRS foi semelhante nos dois grupos ($p = 0,367$), porém o consumo médio de morfina foi $5,6 \pm 4$ mg no grupo BPVT e $16,6 \pm 6,9$ mg no grupo controle ($p < 0,001$).

Conclusões: O BPVT reduz a quantidade de seroma enquanto proporciona analgesia efetiva em pacientes que se submetem a mastectomia e remoção dos linfonodos axilares.

© 2020 Sociedade Brasileira de Anestesiologia. Publicado por Elsevier Editora Ltda. Este é um artigo Open Access sob uma licença CC BY-NC-ND (<http://creativecommons.org/licenses/by-nc-nd/4.0/>).

Introduction

Breast cancer is the most commonly diagnosed malignant condition in females and is one of the leading causes of cancer-related deaths in the world. The number of patients undergoing operations due to breast cancer has been increasing.¹ Seroma is the most common problem that occurs after surgery, and it is considered as an unavoidable complication. Seroma is defined as a subcutaneous collection of serous fluid under the skin flap, after mastectomy, in the dead space of the axilla or the breast following breast-conserving surgery.^{2,3} Seroma is the leading cause of morbidity after breast surgery, leading to prolonged recovery times and hospital stays as well as increased health care costs.⁴ Although the underlying mechanism of seroma formation is unclear, several mechanisms are related to the development of seroma. These include blockage of the lymphatic flow, venous blockage, acute inflammatory response to surgical trauma, and thrombotic vasculitis or fibrosis combined with radiation therapy.^{5–7}

For postoperative pain management after breast surgery, Thoracic Paravertebral Block (TPVB) has been preferred for many years. The efficacy of this block has been observed in many studies.^{8,9} The TPVB technique has long been considered the gold standard in providing analgesia to patients undergoing breast surgery.¹⁰ In performing a TPVB, sympathetic nerves are also blocked.^{11,12} It is important that this blockage is effective in order to reduce seroma forma-

tion by vein relaxation and reduction in the post-capillary resistance.¹³ With this study, we aimed to explore the efficacy of TPVBs for seroma reduction in female patients who underwent elective mastectomy and axillary node dissection surgeries for breast cancer.

Methods

This double-blinded, prospective, randomized controlled trial was performed after obtaining approval from the Kocaeli City Clinical Trials Ethical Committee (KIA 2018/155) and written informed consent from the patients. This study was registered with clinicaltrials.gov (NCT03650868). The study was conducted between September 2018 and February 2019.

Female patients aged between 18 and 65 years with an American Society of Anesthesia (ASA) physical status I–II, who were scheduled for an elective mastectomy and axillary lymph node resection surgery, were included in the study. Our exclusion criteria included obesity (body mass index $> 35 \text{ kg.m}^{-2}$), hypoalbuminemia ($< 3.5 \text{ gr.dL}^{-1}$), renal or hepatic disease, coagulopathy, infection of the skin at the injection site, cognitive dysfunction, and known allergies to any of the drugs used in the study.

Patients were randomized into two groups according to computer-generated random number tables: TPVB group and control group. TPVB was performed preoperatively in the patients in the TPVB group. The patients in the control

group received no intervention. All blocks were performed by experienced anesthesiologists (A.K., H.U.Y.) who were blinded to the data collection. A blinded specialist collected the data for our study.

TPVB technique

The block was performed in the prone position after the appropriate skin disinfection had taken place. A linear ultrasound probe (EsaoteMy Lab 6, Florence, Italy) was placed parallel to the vertebral spine at T1 level and slid 2 cm laterally. The pleura, transverse process, and paravertebral space were visualized. The needle was inserted in a caudal to cranial direction using an in-plane approach. Bupivacaine 0.25% (20 mL) was administered in the paravertebral space at T1 level.

General anesthesia

All patients underwent standardized monitoring comprising SpO₂ evaluation, ECG, and underwent non-invasive blood pressure monitoring. General anesthesia was induced with propofol (2–3 mg.kg⁻¹), fentanyl (2 mg.kg⁻¹), and rocuronium (0.6 mg.kg⁻¹). Desflurane in combination with nitrous oxide in oxygen with a ratio of 2:1 was used for anesthesia maintenance. Tramadol 100 mg and paracetamol 1 g i.v. were administered for postoperative analgesia at the end of surgery. Patients were also provided with a patient-controlled analgesia device containing 0.5 mg.mL⁻¹ morphine, set to deliver a 1 mg bolus dose, with an 8 min lockout time and 1 h limit of 6 mg. Rescue analgesia using tenoxicam 20 mg i.v. was administered if the Numeric Rating Scale (NRS) was > 3. Postoperative pain was assessed 24 hours after the operation using the NRS, which ranges from 0 (no pain) to 10 (worst imaginable pain).

All patients underwent mastectomy with axillary dissection by the same surgeon (Z.C.). At the end of the surgical procedure, one closed suction catheter was inserted in the axilla wound.

The duration of the surgery, amount of perioperative bleeding, number of lymph nodes removed, morphine consumption, and NRS scores at 24 hours post-surgery were recorded. The amount of seroma drained was measured using the catheter in the wound. A blinded specialist collected the data for this study.

Statistical analysis

A preliminary study conducted in our clinic included 10 patients, which revealed a mean (\pm SD) seroma formation value of 128 (\pm 46) mL, 24 hours after the surgery. We calculated that for 80% power and an error of 0.05, the required sample size to detect a 25% difference in seroma formation 24 hours after the surgery was 18 patients per group. We included 20 patients in each group in case any patients dropped out of the study.

All statistical analyses were performed using the IBM SPSS for Windows version 20.0 (IBM Corp., Armonk, NY, USA) software. Kolmogorov-Smirnov tests were used to test the normality of data distribution. Continuous variables were

Table 1 Demographic data.

	TPVB group (n = 20)	Control group (n = 20)
Age (year)	52 \pm 6	51 \pm 7
Weight (kg)	80 \pm 12	72 \pm 14
Height (cm)	162 \pm 3	160 \pm 3
ASA status (I/II)	6/14	5/15
Duration of surgery (min)	82 \pm 20	90 \pm 27
Side (right/left)	8/12	7/13
Amount of bleeding (mL)	121 \pm 53	135 \pm 62
Number of removed LN	14 \pm 3	16 \pm 3

Data are presented as mean \pm SD and patient numbers.

Table 2 Amount of seroma formation, morphine consumptions and NRS scores at the postoperative 24th hour.

	TPVB group (n = 20)	Control group (n = 20)	<i>p</i>
Seroma (mL)	112.5 \pm 53.3	74.5 \pm 47.4	0.022*
Morphine consumption (mg)	5.6 \pm 4	16.6 \pm 6.9	<0.001*
NRS scores	1 \pm 1.3	0.7 \pm 1	0.367

Data are presented as mean \pm SD and patient numbers.

expressed as mean \pm standard deviation, and categorical variables were expressed as counts. Comparisons between the groups were made using a Chi-Squared test for categorical data, student *t*-test, and Mann-Whitney *U* test for continuous data. A value of *p* < 0.05 was considered to be statistically significant.

Results

A total of 40 patients were recruited for the study (Fig. 1). Demographic data, ASA physical status, duration of surgeries, number of lymph nodes removed, and the amount of preoperative bleeding were similar between the groups (Table 1).

Mean seroma formation 24 hours after the surgery was 112.5 \pm 53.3 mL in the Control Group and 74.5 \pm 47.4 mL in the TPVB Group (*p* = 0.022). NRS scores were similar between the two groups (*p* = 0.367) 24 hours after surgery, but the mean morphine consumption was 5.6 \pm 4 in the TPVB group and 16.6 \pm 6.9 in the Control Group (*p* < 0.001) (Table 2).

Two patients in the control group were administered tenoxicam intravenous during the initial 24 hours post-surgery.

No complications were observed related to the TPVB.

Discussion

This study shows that performing TPVB preoperatively reduces seroma formation by 34% compared with the control group (*p* < 0.05).

Seroma formation is one of the key adverse events that can occur after a mastectomy, particularly if axillary dissection is part of the procedure. Seroma increases

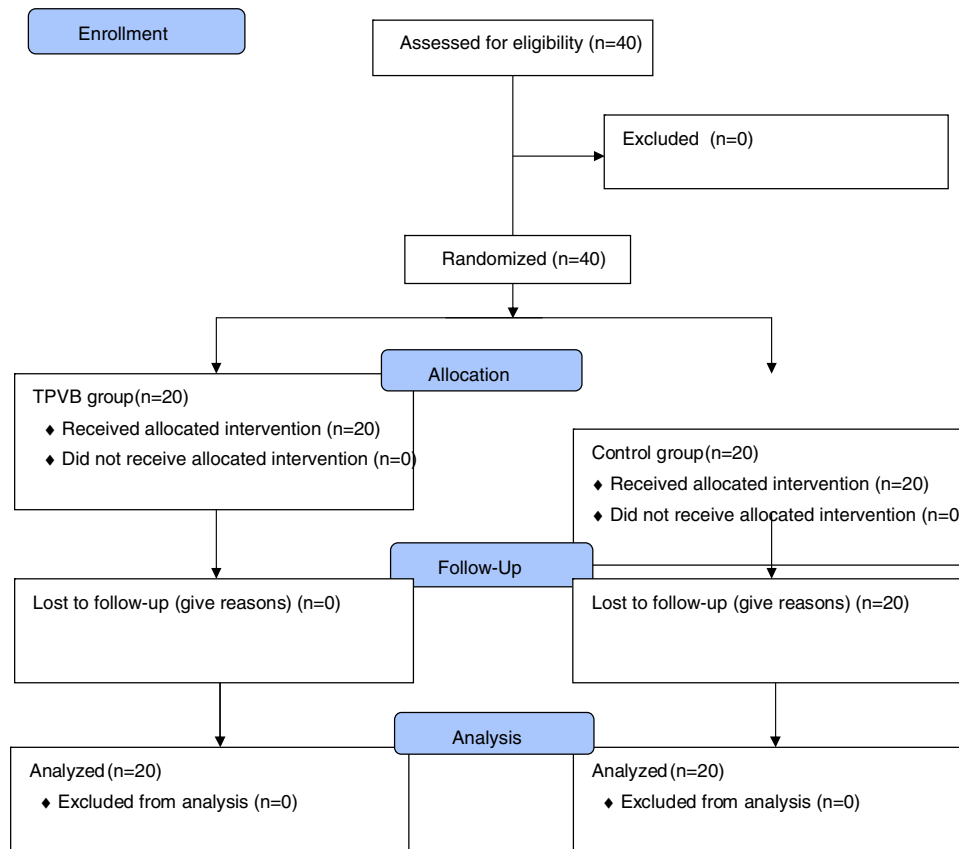


Figure 1 Consort Flow Diagram.

postoperative pain, prolongs the length of stay in hospital, increases the risk of infection, and delays wound healing. Therefore, it is associated with additional cost to the health system.²

Many surgical methods have been described that help to reduce seroma formation.¹⁴ Collagen sponges¹⁵ or surgical adhesives¹⁶ were found to be effective in reducing seroma aspirations and complications. However, none of these methods is a definitive solution because of the complex mechanism of seroma development. In this study, all patients underwent mastectomy and axillary lymph node dissection performed by the same surgeon, using the same surgical technique.

Besides the surgical methods mentioned, postoperative conservative treatments such as manual lymphatic drainage, physical therapy, use of pneumatic pumps, compression bandaging, and limb exercises have been discussed previously, but their long-term effects remain controversial.^{17,18} Swedborg et al.¹⁹ performed a stellate ganglion block in order to provide a sympathetic block of the arm for the treatment of postoperative lymphedema after mastectomy. Likewise, Park et al.¹³ performed a sympathetic ganglion block of the lumbar region for the treatment of lower limb lymphedema after gynecologic cancer surgery.

The breast and axillary area have a complex innervation, which includes intercostals nerves (T2–T6), lateral pectoral nerve (C5–C7), medial pectoral nerve (C8–T1), long thoracic nerve (C5–C7) and thoracodorsal nerve (C6–C8).²⁰ Due to this complex innervation, many regional anesthesia

techniques have been discussed in studies, so as to identify ways to provide adequate postoperative analgesia for breast surgeries. Among many other effective techniques, TPVB also provides a sympathetic block,¹² and injection of 20 mL of local anesthetic covers approximately four vertebral levels.²¹ In patients who undergo breast surgery, an injection at the T4 level provides effective postoperative analgesia.²² However, for a sympathetic block that covers the axillary area and arm, a higher level of local anesthetic is necessary. This may increase the risk of hemodynamic instability. An injection of 20 mL of local anesthetic into the paravertebral space at the T1 level theoretically provides analgesia at C6–T3 with a sympathetic block. In this study, we reduced the formation of seroma while providing efficient analgesia compared with the control group with an injection at the T1 level. No side effects related to the TPVB occurred.

Summary

This study shows that TPVB reduces the amount of seroma formation in the short term while providing effective analgesia in patients who undergo mastectomy and axillary dissection surgery. Further studies are needed that evaluate the long-term outcomes of this approach. Additionally, regional anesthesia techniques preferred for postoperative pain management may differ owing to many factors.

Funding

The authors have no sources of funding to declare for this manuscript.

Conflicts of interest

The authors declare no conflicts of interest.

References

1. Bray F, McCarron P, Parkin DM. The changing global patterns of female breast cancer incidence and mortality. *Breast Cancer Res.* 2004;6:229.
2. Aitken DR, Minton JP. Complications associated with mastectomy. *Surg Clin North Am.* 1983;63:1331–52.
3. Pogson C, Adwani A, Ebbs S. Seroma following breast cancer surgery. *Eur J Surg Oncol.* 2003;29:711–7.
4. Tadych K, Donegan WL. Postmastectomy seromas and wound drainage. *Surg Gynecol Obstet.* 1987;165:483–7.
5. Wtt-Boolsen S, Nielsen V, Jensen J, et al. Postmastectomy seroma. A study of the nature and origin of seroma after mastectomy. *Dan Med Bull.* 1989;36:487–9.
6. McCaul J, Aslaam A, Spooner R, et al. Aetiology of seroma formation in patients undergoing surgery for breast cancer. *Breast.* 2000;9:144–8.
7. Kim HG, Kim K, Seo HG, et al. Clinical outcomes of cervical stellate ganglion block in patients with secondary lymphedema: a pilot study. *J Korean Acad Rehabil Med.* 2009;33:297–303.
8. Coveney E, Weltz CR, Greengrass R, et al. Use of paravertebral block anesthesia in the surgical management of breast cancer: experience in 156 cases. *Ann Surg.* 1998;227:496.
9. Calì Cassi L, Biffoli F, Francesconi D, et al. Anesthesia and analgesia in breast surgery: the benefits of peripheral nerve block. *Eur Rev Med Pharmacol Sci.* 2017;21:1341–5.
10. Batra RK, Krishnan K, Agarwal A. Paravertebral block. *J Anaesthesiol Clin Pharmacol.* 2011;27:5.
11. Purcell-Jones G, Pither C, Justins D. Paravertebral somatic nerve block: a clinical, radiographic, and computed tomographic study in chronic pain patients. *Anesth Analg.* 1989;68:32–9.
12. Baig S, Moon JY, Shankar H. Review of sympathetic blocks: anatomy, sonoanatomy, evidence, and techniques. *Reg Anesth Pain Med.* 2017;42:377–91.
13. Park HS. The effect of lumbar sympathetic ganglion block on gynecologic cancer-related lymphedema. *Pain Physician.* 2013;16:345–52.
14. Ebner F, Friedl TW, de Gregorio A, et al. Seroma in breast surgery: all the surgeons fault? *Arc Gynecol Obstet.* 2018;298:951–9.
15. ten Wolde B, van den Wildenberg FJ, Polat F, et al. Can gentamicin-collagen sponges prevent seroma formation following mastectomy? *Clin Breast Cancer.* 2018;18:1023–6.
16. Ohlinger R, Gieron L, Rutkowski R, et al. The use of TissuGlu® surgical adhesive for mastectomy with or without lymphonodectomy. *In Vivo.* 2018;32:625–31.
17. Moseley AL, Carati CJ, Piller NB. A systematic review of common conservative therapies for arm lymphoedema secondary to breast cancer treatment. *Ann Oncol.* 2006;18:639–46.
18. Ancukiewicz M, Miller CL, Skolny MN, et al. Comparison of relative versus absolute arm size change as criteria for quantifying breast cancer-related lymphedema: the flaws in current studies and need for universal methodology. *Breast Cancer Res Treat.* 2012;135:145–52.
19. Swedborg I, Arnér S, Meyerson B. New approaches to sympathetic blocks as treatment of postmastectomy lymphedema (report of a successful case). *Lymphology.* 1983;16:157–63.
20. Woodworth GE, Ivie RM, Nelson SM, et al. Perioperative breast analgesia: a qualitative review of anatomy and regional techniques. *Reg Anesth Pain Med.* 2017;42:609–31.
21. Hida K, Murata H, Ichinomiya T, et al. Effects of programmed intermittent thoracic paravertebral bolus of levobupivacaine on the spread of sensory block: a randomized, controlled, double-blind study. *Reg Anesth Pain Med.* 2019, <http://dx.doi.org/10.1136/rapm-2018-100021> [Epub ahead of print].
22. Pusch F, Freitag H, Weinstabl C, et al. Single-injection paravertebral block compared to general anaesthesia in breast surgery. *Acta Anaesthesiol Scand.* 1999;43:770–4.