



# REVISTA BRASILEIRA DE ANESTESIOLOGIA

Publicação Oficial da Sociedade Brasileira de Anestesiologia  
www.sba.com.br



## LETTERS TO THE EDITOR

### Post-spinal hyperacute subdural hematoma



#### Hematoma subdural pós-espinal hiperagudo

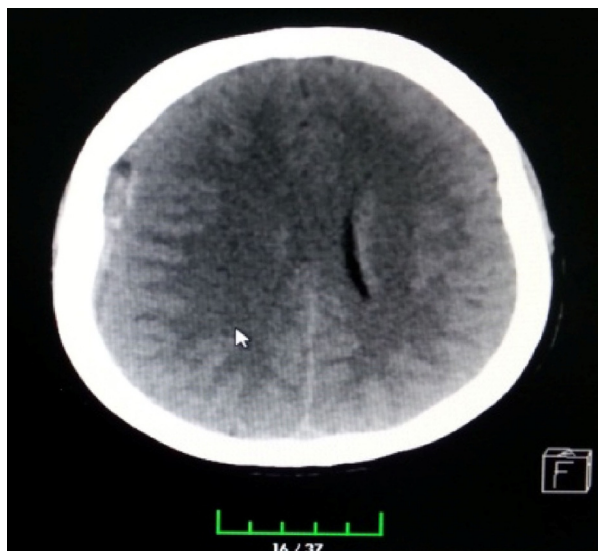Dear Editor,

The development of intracranial subdural hematoma following spinal anesthesia is a rare (1/1 mil–1/1.5 mil) and this serious complication can be fatal.<sup>1,2</sup> Continuous leakage of cerebrospinal fluid (CSF) due to dural injury during puncture can lead to stretching, tearing, and bleeding in meningeal vessels. The symptoms of intracranial subdural hematoma are predisposition to sleeping, disorientation, blurred vision, diplopia, cortical blindness, tinnitus, loss of hearing, scalp paresthesia, vertigo, vomiting, and epileptic convulsions.<sup>2,3</sup> However, the most common symptom is headache. The probability of headache following dural puncture makes the diagnosis of subdural hematoma more difficult.<sup>4,5</sup> Nevertheless, the presence of neurological symptoms is pathognomonic and helps establish the differential diagnosis.

A 50 year-old female patient scheduled for total knee prosthesis had been on methotrexate for 4 year with the diagnosis of rheumatoid arthritis. Hemogram, biochemistry, and coagulation parameters were normal without her positive hepatitis C marker. The operation was performed with ASA II risk. Standard monitorization (electrocardiogram, pulse oximeter, noninvasive blood pressure measurement) was carried out. A 25G spinal needle was used, and the intrathecal space was entered on the second attempt at the L4–L5 level, followed by administration of 12.5 mg of heavy bupivacaine. The operation was carried out under spinal anesthesia and lasted after 2 h. The patient was then transferred to the orthopedics ward. The patient developed sudden loss of consciousness approximately 10 h post operation. Upon physical examination, the patient was unconscious, her eyes were anisocoric, and spontaneous respiration was present. Glasgow Coma Score (GCS) was 7 (no response to verbal stimuli, localizes painful stimulus) and Babinski reflex was not present. BP was 170/100 mmHg, oxygen saturation was 94%, and pulse was 110 bp/m. The patient's relatives reported that she complained of headache and dizziness after the operation. Emergency brain CT scan showed a right subdural hematoma as well as

brain edema and shifting (Fig. 1). Emergency decompression was carried out by neurosurgery (Fig. 2). Hemodynamics were stable during the operation. The patient was awakened without any problems. She was then extubated and transferred to intensive care. On her postoperative day-1 examination, GCS was 15, but the right eye remained ptotic. The patient was discharged 1 week later. The development of subdural hematoma after spinal anesthesia is a rare but serious complication of anesthesia.<sup>1,2</sup> CSF leakage after dural injury can lead to low CSF pressure and intracranial hypotension, which can cause withdrawn on bridging veins and, rarely, bleeding associated the rupture of subdural veins via the compensatory vasodilatation of secondary veins.<sup>6,7</sup> Subdural veins rupture more easily due to the structure of the bridging vein walls, which are microscopically more fragile than other vein walls.

Factors such as the use of anticoagulants, cerebral atrophy, vascular anomalies, dehydration, pregnancy, multiple penetrations of the dura, and thickness of the needle used are associated with intracranial bleeding.<sup>8</sup> In a series of 35 cases with post-spinal subdural hematoma, no risk factor was determined in 15 cases.<sup>6</sup> However, the use of a 25G rather than a 27G spinal needle, the presence of cerebral vasculitis in rheumatoid arthritis patients rarely, and weak vein wall structure were associated.<sup>9</sup> One case where in the patient had no risk factors and developed subdural hematoma with the use of a 27G needle has been reported in the literature.<sup>6</sup> Although the most common symptom is headache, the patient may also develop vomiting, blurred vision, predisposition to sleep, vertigo, tinnitus, loss of hearing, diplopia, and blindness.<sup>10</sup> The most important factor in missed and delayed diagnoses of subdural hematoma is that its most common symptom is headache and the most common complication of spinal anesthesia is post-dural puncture headache (PDPH). Postural Headache is pathognomonic for PDPH.<sup>6</sup> According to the International Headache Society (2004, ICHD-II), the diagnostic criteria for PDPH are (1) onset/increase of pain within 15 min of the patient lying down or getting up, with pain improvement in the same period; (2) onset within 5 days of dural injury; (3) spontaneous disappearance within a week; or (4) disappearance within 48 h of epidural patch application (9). In 95% of the reviewed studies, PDPH symptoms improved within 5 days. In addition, unlike intracranial lesions, bleeding, or infections, PDPH could not be demonstrated in neuroimaging and CSF pressure was low. However, PDPH may last for

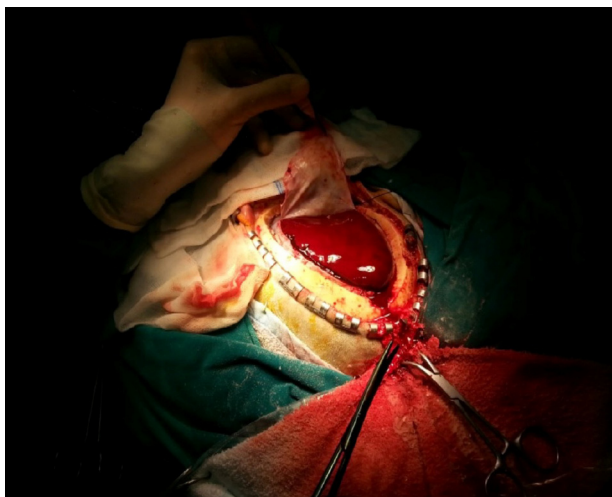


**Figure 1** CT scan showed a right subdural hematoma.

>5 d.<sup>6</sup> In a study including 640 patients, postural headache continued for 15 days in one patient, although no lesion was visible in brain MR and the headache improved after only two epidural patches.<sup>6</sup>

In cases where headache is atypical, lasts long, is not associated with posture, and is accompanied by neurological symptoms, subdural hematoma should be suspected and neuroimaging should be carried out for diagnosis.<sup>6</sup> Subdural hematomas appear as hyperdense crescents between bone and brain in CT imaging. As the duration of hematoma increases, its density decreases; when it reaches the same density as the brain, diagnosis can be made with MR. The duration of hematoma is divided into four groups: (1) hyperacute (first 24 h); (2) acute (2–3 d); (3) subacute (3–14 d); and (4) chronic ( $\geq 2$  weeks).<sup>11</sup> Our case had hyperacute subdural intracranial hematoma.

In a study by Amorim et al.,<sup>6</sup> the period between the onset of symptoms and diagnosis ranged 4 h to 29 weeks, and the most common symptoms were headache (74.3%),



**Figure 2** Emergency decompression by neurosurgery.

changes in consciousness (40%), vomiting (31%), hemiplegia or hemiparesis (22%), diplopia or n. abducens paresis (14%), and speech disorders. In the present case, diagnosis was made 10 h post-surgery, and the patient's symptoms were headache and loss of consciousness. In the work of Amorim et al.,<sup>6</sup> subdural hematoma developed in a hyperacute manner in only three cases, and loss of consciousness occurred in only one of these. Subacute hematoma with loss of consciousness developed in three cases. Subdural intracranial hematoma may spontaneously resorb or may require surgical decompression or burr-hole drainage.<sup>12</sup> Of 21 subdural hematoma cases reported by Kayacan et al.,<sup>13</sup> 15 required surgical decompression and two patients were lost. In a case reported by Ezri et al.,<sup>14</sup> chronic subdural hematoma was spontaneously resorbed. In the present case, surgical decompression was also carried out.

The most common complication of spinal anesthesia is PDPH. The development of intracranial subdural hematoma following spinal anesthesia, though rare, is a serious complication that can be fatal if left untreated. Both complications present with headache, rendering definitive diagnosis difficult.<sup>2,3</sup> In cases where the headache is long in duration, is not postural, and is accompanied by neurological symptoms, subdural hematoma should be suspected and neuroimaging should be carried out. CT or MRI should be ordered depending on the duration of the headache.<sup>10</sup> To avoid missed diagnosis of subdural hematoma in the 5–7 days period when post-spinal headache is present, headache should be investigated thoroughly and the patient should be monitored for neurological symptoms. Despite the very low incidence of subdural hematoma, headaches following spinal anesthesia should be fully examined and the possibility of subdural hematoma should not be underestimated.

## Conflicts of interest

The authors declare no conflicts of interest.

## References

1. Zeidan A, Farhat O, Maaliki H, et al. Does postdural puncture headache left untreated lead to subdural hematoma? Case report and review of the literature. *Int J Obstet Anesth.* 2006;15:50–8.
2. Turnbull DK, Shepherd DB. Post-dural puncture headache: pathogenesis, prevention and treatment. *Br J Anaesth.* 2003;91:718–29.
3. Kelsaka E, Sarihasan B, Baris S, et al. Subdural hematoma as a late complication of spinal anesthesia. *J Neurosurg Anesthesiol.* 2003;15:47–9.
4. Blake DW, Donnan G, Jensen D. Intracranial subdural haematoma after spinal anaesthesia. *Anaesth Intensive Care.* 1987;15:341–2.
5. Evans RW. Special report: complications of lumbar puncture and their prevention with a traumatic lumbar puncture needles 52nd Annual Meeting of the American Academy of Neurology; 2000.
6. Amorim JA, Remigio DS, Damázio Filho O, et al. Intracranial subdural hematoma post-spinal anesthesia: report of two cases and review of 33 cases in the literature. *Rev Bras Anesthesiol.* 2010;60(620–629):344–9.
7. Velarde CA, Zuniga RE, Leon RF, et al. Cranial nerve palsy and intracranial subdural hematoma following implantation

- of intrathecal drug delivery device. *Reg Anesth Pain Med.* 2000;25:76–8.
8. Scott DB, Hibbard BM. Serious non-fatal complications associated with extradural block in obstetric practice. *Br J Anaesth.* 1990;64:537–41.
  9. Watts RA, Mooney J, Lane SE, et al. Rheumatoid vasculitis: becoming extinct? *Rheumatology.* 2004;43:920–3.
  10. Srivastava U, Agrawal A, Gupta A, et al. Intracranial subdural hematoma after spinal anesthesia for cesarean section: case report and review of literature. *J Obstet Anaesth Crit Care.* 2014;4:45–7.
  11. Moss D, Jalaluddin M. Pediatric subdural hematoma. In: Batjer HH, Loftus CM, editors. *Textbook of neurological surgery.* Philadelphia: Lippincott Williams & Wilkins; 2003. p. 1095–102.
  12. Azzarelli B. Neuropathology of the central nervous system: trauma, cerebrovascular disease, infections, demyelinating, neurodegenerative, nutritional and metabolic disorders. In: Batjer HH, Loftus CM, editors. *Textbook of neurological surgery.* Philadelphia: Lippincott Williams & Wilkins; 2003. p. 207–33.
  13. Kayacan N, Arici G, Karsli B, et al. Acute subdural haematoma after accidental dural puncture during epidural anaesthesia. *Int J Obstet Anesth.* 2004;13:47–9.
  14. Ezri T, Abouleish E, Lee C, et al. Intracranial subdural hematoma following dural puncture in a parturient with HELLP syndrome. *Can J Anaesth.* 2002;49:820–3.
- Ozkan Onal<sup>a,\*</sup>, Emine Aslanlar<sup>a</sup>, Seza Apiliogullari<sup>a</sup>, Omer Faruk Erkocak<sup>b</sup>, Jale Bengi Celik<sup>a</sup>
- <sup>a</sup> *Selcuk University Medical Faculty, Department of Anesthesia and Intensive Care, Konya, Turkey*  
<sup>b</sup> *Selcuk University Medical Faculty, Department of Orthopedics and Traumatology, Konya, Turkey*
- \* Corresponding author.  
*E-mail:* drozkanonal@selcuk.edu.tr (O. Onal).
- Available online 18 March 2016
- <http://dx.doi.org/10.1016/j.bjane.2015.04.003>  
 0104-0014/  
 © 2016 Sociedade Brasileira de Anestesiologia. Published by Elsevier Editora Ltda. This is an open access article under the CC BY-NC-ND license (<http://creativecommons.org/licenses/by-nc-nd/4.0/>).

## Preventing atelectasia at robotic surgery



## Prevenir atelectasia em cirurgia robótica

Dear Editor,

We read the article “Robotic prostatectomy: the anesthesiologist’s view for robotic urological surgeries, a prospective study” written by Oksar and Ocal with a great interest.<sup>1</sup> They share the anesthetic management of the robotic prostatectomy. We would like to thank to the authors for their contribution with a successfully designed and documented study. We believe that these findings will enlighten about the anesthetic management of the robotic prostatectomy.

Robotic-assisted laparoscopic prostatectomy (RALP) is a technically difficult surgery requiring experience. The duration of the surgery is usually prolonged because of detailed preparation before surgery. The anesthetic management requires more attention than open surgery due to pneumo-peritoneum. Prolonged operation time, the trendelenburg position, and increased intra-abdominal pressure due to pneumo-peritoneum usually lead to severe atelectasis, increased level of PaCO<sub>2</sub> and acidosis.<sup>2–4</sup> However intermittent recruitment maneuver should be made to prevent and improve atelectasis due to pneumo-peritoneum and trendelenburg. Recruitment maneuver especially before extubation may improve postoperative lung functions.<sup>5</sup>

Consequently, effects due to excessive trendelenburg position in addition to classical complications of laparoscopic procedure at robotic-assisted laparoscopic prostate surgery should be considered. Increasing airway pressure

is inescapable. Increasing minute ventilation may not be enough to be maintained in the PaCO<sub>2</sub>’s normal range. Pressure-control mode forming lower peak pressure should be preferred and appropriate PEEP should be set to prevent atelectasis.<sup>5,6</sup> Also intermittent recruitment maneuver should be made as needed.

## Conflicts of interest

The authors declare no conflicts of interest.

## References

1. Oksar M, Akbulut Z, Ocal H, et al. Robotic prostatectomy: the anesthesiologist’s view for robotic urological surgeries, a prospective study. *Braz J Anesthesiol.* 2014;64(5):307–13.
2. Oksar M, Akbulut Z, Ocal H, et al. Anesthetic considerations for robotic cystectomy: a prospective study. *Braz J Anesthesiol.* 2014;64(2):109–15.
3. Hypolito O, Azevedo JL, Gama F, et al. Effects of elevated artificial pneumoperitoneum pressure on invasive blood pressure and levels of blood gases. *Braz J Anesthesiol.* 2014;64(2): 98–104.
4. Ozdemir M, Bakan N, Sahin OT, et al. The comparison of sevoflurane-remifentanyl and propofol-remifentanyl in robotic prostatectomies. *J Clin Anal Med.* 2013;4(4):313–7.
5. Talab HF, Zabani IA, Abdelrahman HS, et al. Intraoperative ventilatory strategies for prevention of pulmonary atelectasis in obese patients undergoing laparoscopic bariatric surgery. *Anesth Analg.* 2009;109(5):1511–6.
6. Baltieri L, Dos Santos LA, Rasera-Junior I, et al. Use of positive pressure in preoperative and intraoperative of bariatric surgery and its effect on the time of extubation. *Braz J Anesthesiol.* 2015;65(2):130–5.