



CLINICAL RESEARCH

New oropharyngeal double lumen cannula for sedation for transesophageal echocardiography: case series



Caetano Nigro Neto ^{a,*}, Francisco José Lucena Bezerra^b,
Rodrigo Bellio de Mattos Barreto^b, David Costa de Souza Le Bihan^b,
Vinicius Tadeu Nogueira da Silva do Nascimento^b, Ingrid Caroline Baia de Souza^b

^a Instituto Dante Pazzanese de Cardiologia, Departamento de Anestesia, São Paulo, SP, Brazil

^b Instituto Dante Pazzanese de Cardiologia, São Paulo, SP, Brazil

Received 27 November 2019; accepted 9 March 2020

Available online 11 May 2020

KEYWORDS

Double lumen
cannula;
Transesophageal
echocardiography;
Sedation;
Ambulatory
anesthesia;
Spontaneous
ventilation

Abstract

Introduction: Currently, transesophageal echodopplercardiography is frequently performed under sedation on an outpatient basis. Sedation is related with increase in incidents on airways. Bearing in mind this scenario, we developed a new double lumen oropharyngeal cannula aimed at keeping airway patency, in addition to reducing risks to patients during endoscopy procedures performed under sedation. The main objective of our study was to assess the incidence of oxygen desaturation in a series of cases of adult patients submitted to outpatient transesophageal echo exam, under sedation and using the oropharyngeal cannula.

Method: 30 patients under sedation with intravenous midazolam and propofol were assessed. After loss of consciousness, the cannula was placed and patients were maintained on spontaneous breathing. Oxygen saturation, capnometry, heart rate and non-invasive arterial blood pressure, in addition to subjective data: airway patency, handling of cannula insertion and, comfort of examiner were analyzed.

Results: The incidence of mild desaturation was 23.3%, and there was no severe desaturation in any of the cases. The insertion of the oropharyngeal cannula was considered easy for 29 patients (96.6%), and transesophageal echo probe handling was appropriate in 93.33% of exams performed.

Conclusions: Transesophageal echo exams under sedation aided by the double-lumen oropharyngeal cannula presented a low incidence of desaturation in patients assessed, and allowed analysis of expired CO₂ during the exams.

© 2020 Sociedade Brasileira de Anestesiologia. Published by Elsevier Editora Ltda. This is an open access article under the CC BY-NC-ND license (<http://creativecommons.org/licenses/by-nc-nd/4.0/>).

* Corresponding author.

E-mail: caenigro@uol.com.br (C. Nigro Neto).

PALAVRAS-CHAVE

Cânula de duplo lúmen;
Ecocardiografia transesofágica;
Sedação;
Anestesia ambulatorial;
Ventilação espontânea

Nova cânula orofaríngea de duplo lúmen para sedação em ecocardiografia transesofágica: série de casos**Resumo**

Introdução: Nos dias atuais, exames de ecocardiografia transesofágica (ETE) são realizados de forma frequente sob sedação em regime ambulatorial. A sedação está relacionada com aumento de intercorrências nas vias aéreas. Nesse contexto, desenvolvemos uma cânula orofaríngea de duplo-lúmen com finalidade de manutenção da via aérea pérvia, reduzindo riscos aos pacientes durante procedimentos endoscópicos sob sedação. O principal objetivo do nosso estudo foi avaliar a incidência de dessaturação em uma série de casos de pacientes adultos submetidos à ETE ambulatorial sob sedação com o uso da cânula orofaríngea.

Métodos: Foram avaliados 30 pacientes sedados com midazolam e propofol intravenoso. A cânula foi inserida após perda da consciência e os pacientes foram mantidos com ventilação espontânea. Analisados saturação de oxigênio, capnometria, frequência cardíaca e pressão arterial não invasiva, além de dados subjetivos: patência das vias aéreas, manuseio e inserção da cânula e conforto ao examinador.

Resultados: A incidência de dessaturação leve foi de 23,3% e não houve dessaturação grave em nenhum caso. A inserção da cânula orotraqueal foi considerada fácil em 29 pacientes (96,6%) e o manuseio da sonda de ETE foi adequada em 93,33% dos exames realizados.

Conclusões: A realização dos exames de ETE sob sedação com auxílio da cânula orofaríngea de duplo lúmen apresentou baixa incidência de dessaturação nos pacientes avaliados, além de permitir análise do CO₂ expirado durante a realização dos exames.

© 2020 Sociedade Brasileira de Anestesiologia. Publicado por Elsevier Editora Ltda. Este é um artigo Open Access sob uma licença CC BY-NC-ND (<http://creativecommons.org/licenses/by-nc-nd/4.0/>).

Introduction

Invasive exams such as Transesophageal Echodopplercardiography (TEE) are currently performed very frequently outside the surgical block, on an outpatient basis. TEE offers the advantage of improving the quality of images acquired; particularly, of posterior structures, such as interatrial septum, mitral valve, Left Atrium (LA) and pulmonary veins, when compared to Transthoracic Echocardiographic (TTE) images.^{1,2} However, assessment using TEE can present higher risks of complications than TTE, due to the presence of the TEE probe in the esophagus, and the need for deep sedation.³⁻⁷

Other endoscopic esophageal procedures are also performed usually under sedation. Sedation is related with the increase in incidents on unprotected airways, such as hypoxia, requiring unplanned endotracheal intubation (secondary to desaturation or broncho aspiration), accidental tracheal insertion of the gastroscope, bronchospasm and laryngospasm.⁸⁻¹⁰ A recent study showed that the incidence of hypoxia in outpatient endoscopy procedures ranges between 1.5% and 70%, and generally occurs 5 minutes after administration of sedative drugs, in that one third of apnea and ventilation changes lead to hypoxemia.¹¹

Other complications related to TEE probe insertion also should be observed, such as oral and esophageal soft tissue injuries.⁵ Therefore, in addition to the presence of a skilled professional for managing airway and performing sedation, strategies to prevent TEE use-related complications are required, enabling the exam to be performed with safety and comfort to the patient.

Bearing in mind this scenario, we developed a new double lumen oropharyngeal cannula (Orophar – Gabisa Medical International – Anvisa: 80423540061) that helps keep airway patency, in addition to preventing damage to the probe during TEE exams. The patent for the device was requested to the National Institute of Industrial Property (INPI – *Instituto Nacional da Propriedade Industrial*). The patent process is ongoing and has not yet been issued.

The main objective of our study was to assess the incidence of oxygen desaturation in a series of cases of adult patients submitted to outpatient TEE exam, under sedation and using the orotracheal cannula. The secondary objective was to assess the ease of cannula insertion; airway patency; and TEE probe handling. Other possible complications were also registered, such as dental, lip and gum injuries, bleeding, laryngospasm, bronchospasm or arrhythmias.

Method

The present study refers to an observational analysis of a case series with a qualitative and quantitative approach. The study was performed at Instituto Dante Pazzanese de Cardiologia, São Paulo – Brazil. After approval by the Ethics in Research committee and signatures of Informed Consents (TCLE), 30 adult patients, with ages above 18 years, scheduled for outpatient TEE under sedation provided by anesthesiologists, were included in the study.

Exclusion criteria: emergency procedures, cognitive disorders, hemodynamic instability, respiratory disorders and/or previous desaturation or contraindications for elective TEE, according to local institutional protocols in compliance with internationally accepted norms.¹²

Anesthesia

All patients were initially submitted to pre-anesthetic assessment to determine general physical status, using the American Society of Anesthesiologists (ASA) classification.

While preparing for the exam, patients were monitored with non-invasive arterial pressure, cardioscopy, and pulse oximetry.

Sedation protocol: after upper limb venous access, all patients were pre-medicated with 1.5 mg of intravenous midazolam and 3 L/min oxygen supplementation by nose catheter. After 2 minutes, with the patient in supine, sedation began with 1 mg/kg of intravenous propofol, administered slowly in up to 1 minute. Supplementary doses of 20 mg of propofol bolus were given for sedation maintenance, when required, until the end of the exam.

After the initial dose of propofol, patient loss of consciousness and mandibular relaxation, a double-lumen orotracheal cannula was placed. The cannula proximal end extensions were connected to the capnograph and oxygen supplementation (Fig. 1). Following, the TEE probe was passed through the cannula's largest diameter lumen, manually guided by maneuvers enabling smooth esophagus insertion (Fig. 2). Then, patients were positioned slightly in left lateral decubitus for the exam. Patients were kept on spontaneous breathing throughout the procedure.

At the end of the exam, with patients still unconscious, TEE probe and orotracheal cannula were removed. All patients were sent to the post anesthetic care unit and assessed for at least 60 minutes. Discharge criteria were: level of consciousness, SpO₂ oximetry, ambulation, hemodynamic stability, and satisfactory ability to eat (intact swallowing, with no nausea or vomiting).

Orotracheal cannula

The Double lumen orotracheal cannula consists of a single piece, with two different diameter lumina separated by an orthogonal wall. Air enters and exits during inspiration and expiration through the orifice of the smaller

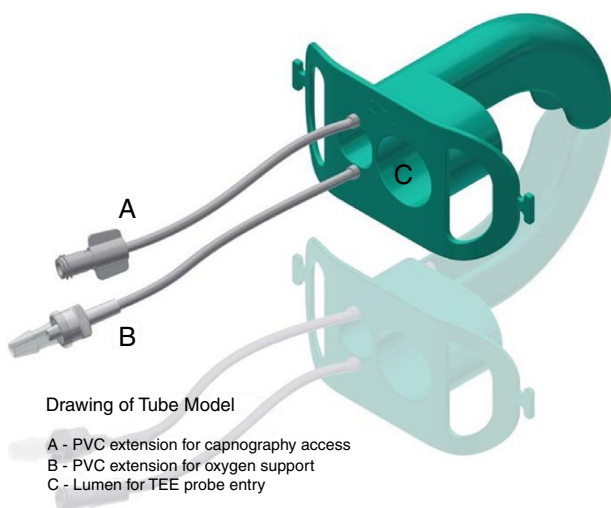


Figure 1 Drawing of tube model.

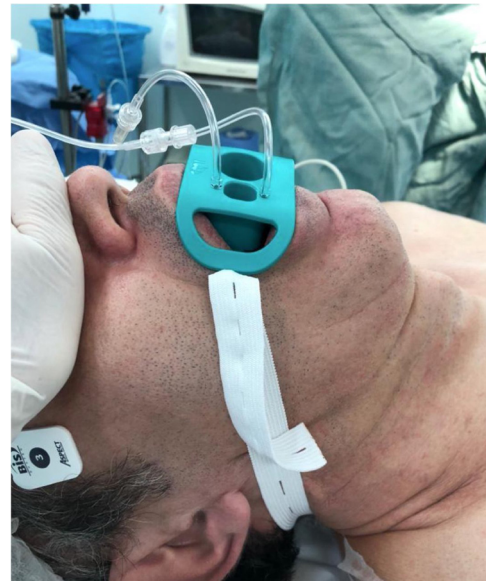

Figure 2 Patient sedated with the cannula correctly positioned.

lumen. Moreover, close to the upper and lower borders of the smaller lumen opening, there are two tube-shaped channels running along the orthogonal wall. The channels are designed to offer oxygen to the patient, and to enable the capnograph to measure the levels of carbon dioxide eliminated during expiration. The larger orifice allows the passage of the TEE probe (Fig. 1).

Fig. 3 presents all measurements of the 100 millimeter model cannula that was used for all patients during the study.

Data collecting

Initially, we registered all patient data: sex, age and Body Mass Index (BMI). Then, cannulas were assessed during the procedures according to the following criteria:

- Orotracheal cannula insertion was assessed as easy, difficult or not possible. Easy was defined as insertion on first attempt; difficult, as non-traumatic insertion after three or less attempts; and not possible, if we were unable to insert the cannula.
- Airway patency was assessed by the use of airway alignment techniques (hyperextension of the neck), assisted ventilation or sedation discontinuation, and interruption of exam and orotracheal intubation.
- Handling of TEE probe with the orotracheal cannula in situ was assessed by the echocardiographer as appropriate (easy handling and anchoring) or inappropriate.
- We also registered complications caused by passage of the tube, such as lip, soft tissue or teeth injuries, mild or severe oxygen desaturation and other complications related to the procedure.

Episodes of arterial saturation of oxygen below 90% for more than 15 seconds, easily corrected with assisted ventilation and 100% O₂ supplementation without removing the cannula and/or interrupting the exam were considered mild

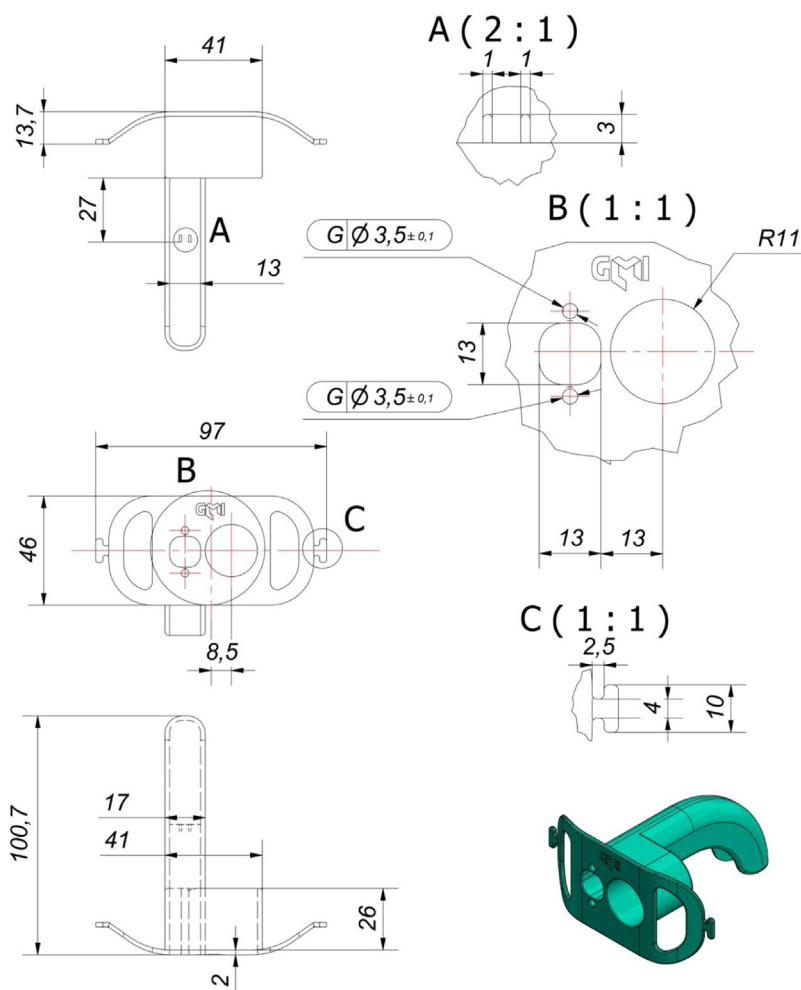


Figure 3 Details of tube model. A: PVC extension for capnography access; B: PVC extension for oxygen support; C: Lumen for TEE probe entry.

desaturation. If desaturation persisted and/or the exam was interrupted to perform Orotacheal Intubation (OTI), desaturation was considered severe.

MAP values obtained during the exams, below 20% of baseline values of each patient were considered episodes of hypotension. Correction of hypotension consisted of intravenous administration of 200 mL of saline solution and 5 μ g bolus of adrenaline, if persistent.

During examination, patients were monitored continuously and noninvasive Mean Arterial Pressure (MAP), Heart Rate (HR), Pulse Oximetry (SaO_2) and Capnography (ETCO_2) were registered on the assessment sheet every 5 minutes.

Statistics

Data were stored electronically and analyzed using STATA software, version 10.0 (StataCorp, College Station, TX). Quantitative data were analyzed and presented as median and Interquartile (IQR) or Mean and Standard Deviation (mean \pm SD). Qualitative data were analyzed and presented as numbers and percentages (n [%]).

Results

All patients were sedated and received an orotracheal cannula, without needing to interrupt the exam and/or remove cannula of any of the patients for any reason. Data collected of the 30 patients assessed were analyzed. Demographic and pre-operative data are presented in Table 1. HR, MAP, SaO_2 and ETCO_2 measurement data are presented in Table 2.

Insertion of orotracheal cannula was considered easy for 29 patients (96.6%) and difficult for only one.

Alignment maneuvers were required for 28 patients to improve patency of airways.

TEE probe handling was considered appropriate for 93.33% of exams performed, with appropriate anchoring for gentle handling of the TEE probe. The echocardiographer only considered two exams difficult to handle the TEE probe with the cannula in situ.

The incidence of mild desaturation was 23.3% and there was no severe desaturation in any of the cases.

The general incidence of complications is presented in Table 2. One patient presented laryngospasm easily

Table 1 Demographic data.

Pre-operative data	Patients (n = 30)
Sex	
Male	12 (40%)
Female	18 (60%)
ASA II	15 (50%)
ASA III	15 (50%)
Age	52 ± 18
BMI	29.25 ± 7.41

Continuous data presented as Mean ± Standard Deviation ($M \pm SD$); quantitative data presented as numbers and percentages; n (%).

BMI, Body Mass Index.

corrected. There were no cases of teeth or soft tissue injuries and/or bleeding (Table 3).

Discussion

The new double lumen orotracheal tube analyzed in the present study proved feasible for use during outpatient TEE. There was a low incidence of desaturation during the exam in patients assessed, in addition to enabling the measurement of end-tidal CO_2 during TEE exams.

The market has few options with the same objective of improving control of airways during endoscopic procedures with sedation. Terblanche et al. assessed the efficiency of a new laryngeal mask (LMA[®]GastroTM Airway, Teleflex Medical, Athlone, Ireland) in patients submitted to GI endoscopy. The authors emphasized that, in outpatient endoscopic procedures without using these devices and with sedated patients, the incidence of cardiorespiratory complications is higher, as there is no due concern with airway patency. Moreover, the adequate use of such devices can minimize complications during GI endoscopy procedures.¹³

Ramalingam et al.⁵ performed a prospective study at 28 centers in the United Kingdom and Ireland that included 22,314 patients submitted to transesophageal echocardiography exams, reporting the main complications related to the passage of the TEE probe. Among them, 17 patients had palate injury, an incidence of 0.08% (95% CI 0.05%–0.13%), or approximately 1:1300 exams. In addition, the authors suggested a revision in probe insertion guidelines, communicating to patients the possible risks and benefits of performing such procedures. The concomitant use of TEE probe with devices that can prevent the displacement of the probe in the oral cavity, acting as support and improving TEE anchorage, can avoid oral cavity injury. None of the

Table 3 Complications due to echotransesophageal probe passage.

Complications	Patients (n = 30)
Lip or soft tissue injury	0
Tooth injury	0
Bleeding	0
Mild hypoxemia	7 (23.3%)
Severe hypoxemia with OTI	0
Laryngospasm	1 (3.33%)
Bronchospasm	0
Hypotension	0

Quantitative data presented as numbers and percentages; n (%). OTI, Orotracheal Intubation.

patients included in our study had teeth and/or soft tissue injury.

Other authors consider that in patients submitted to endoscopic procedures with sedation, the incidence of hypoxia (arterial oxygen saturation below 90% for over 15 seconds) is 1.5–70%. Most of the time, the event is due to excessive use of hypnotic drugs and/or tongue airway obstruction, which makes maintenance of normal spontaneous breathing difficult, even with oxygen supplementation.¹¹ In our study we observed an incidence of 23.3% of mild desaturation without requiring removal of the cannula in any of the cases. The condition was easily corrected with oxygen supplementation and airway alignment maneuver, allowing for a smooth and comfortable exam for the examiner and the anesthesiologist. Moreover, the cannula allowed continuous monitoring of $ETCO_2$, which enabled better control of ventilation by the anesthesiologist.

In a recent study discussing strategies to prevent complications related to the appropriate use of perioperative echodopplercardiography, the authors recommended the insertion of the TEE probe to be gentle and by an experienced operator, to avoid soft tissue injury. The same study considered that the number of times of probe handling should be as limited as possible. In addition, appropriate anchorage of the probe avoids major soft tissue injury.¹⁴ Our results show that TEE probe handling and anchorage assessed by the echocardiographer, were considered appropriate in 93.33% of cases.

Among care procedures, the correct use of the TEE probe during examinations is equally necessary. The high cost of the equipment and the major frailty in the portion where the piezoelectric crystals are, require additional care and protection during the passage through the oral cavity. Damage to the equipment, such as scratches caused by patients'

Table 2 Patient vital signs (n = 30) during TEE exams.

Minutes	5	10	15	20	25	30	35	40	45
HR	80 ± 24	80 ± 20	79 ± 21	76 ± 17	76 ± 16	75 ± 16	76 ± 19	72 ± 20	80 ± 17
MAP	82 ± 14	80 ± 15	78 ± 13	88 ± 45	81 ± 13	81 ± 16	81 ± 13	83 ± 17	95 ± 21
SatO ₂	96 ± 4	94 ± 8	96 ± 4	96 ± 5	96 ± 4	98 ± 3	96 ± 5	95 ± 5	93 ± 4
ETCO ₂	34 ± 5	34 ± 5	34 ± 4	34 ± 7	32 ± 6	33 ± 6	30 ± 5	33 ± 2	33 ± 2

Quantitative data presented as Mean ± Standard Deviation ($M \pm SD$).

teeth, are not uncommon when care is not taken. Normally, appropriate mouthpieces are used toward that end.¹⁵ The cannula also proved to be appropriate for that goal, providing the same protection offered by mouthpieces. The TEE probe was passed through one of the cannula orifices, which avoided contact with teeth and possible biting.

Limitation of the study

Our study did not present a direct comparison with other devices that allow for better control of airways in cases of sedation for endoscopy procedures. However, during clinical trials with new devices, it is usual to perform initial assessment on the functionality and possible benefit they may bring to clinical practice. The assessment of TEE probe handling in the presence of the tube by echocardiographers was subjective and performed by several different ones.

Conclusions

Outpatient TEE examinations using orotracheal cannulas presented a low incidence of oxygen desaturation in patients assessed, and allowed analysis of expired CO₂ during the exams. However, more studies with more participants and including comparisons to similar devices should be performed to confirm the observations presented herein.

Conflicts of interest

The authors declare no conflicts of interest.

References

1. Flachskampf FA. The standard TEE examination: procedure, safety, typical cross-sections and anatomic correlations, and systematic analysis. *Semin Cardiothorac Vasc Anesth.* 2006;10:49–56.
2. Akaishi M, Asanuma T, Izumi C, et al. Guidelines for conducting transesophageal echocardiography. *J Echocardiography.* 2016;14:47–8.
3. José GM, Silva CE, Ferreira LD, et al. Effective dose of sedation in transesophageal echocardiography: relation to age, body surface area and left ventricle function. *Arq Bras Cardiol.* 2009;93:623–9.
4. Toman H, Erkilinc A, Kocak T, et al. Sedation for transesophageal echocardiography: comparison of propofol, midazolam and midazolam-alfentanil combination. *Med Glas (Zenica).* 2016;13:18–24.
5. Ramalingam G, Choi SW, Agarwal S, et al. Complications related to peri-operative transoesophageal echocardiography – a one-year prospective national audit by the Association of Cardiothoracic Anaesthesia and Critical Care. *Anaesthesia.* 2019 [Epub ahead of print].
6. Purza R, Ghosh SB, Walker C, et al. Transesophageal echocardiography complications in adult cardiac surgery: a retrospective cohort study. *Ann Thorac Surg.* 2017;103:795–802.
7. Hilberath JN, Oakes DA, Shernan SK, et al. Safety of transesophageal echocardiography. *J Am Soc Echocardiogr.* 2010;23:1115–27.
8. Leslie K, Allen ML, Hessian EC, et al. Safety of sedation for gastrointestinal endoscopy in a group of university-affiliated hospitals: a prospective cohort study. *Br J Anaesth.* 2017;118:90e9.
9. Friedrich K, Stremmel W, Sieg A. Endoscopist-administered propofol sedation is safe – a prospective evaluation of 10,000 patients in an outpatient practice. *J Gastrointest Liver Dis.* 2012;21:259e63.
10. Vargo JJ 2nd. Sedation-related complications in gastrointestinal endoscopy. *Gastrointest Endosc Clin N Am.* 2015;25:147–58.
11. Amornyotin S. Sedation-related complications in gastrointestinal endoscopy. *World J Gastrointest Endosc.* 2013;16:527–33.
12. Hillenbrand KD, Racine CL, McNeil JS, et al. Difficult TEE probe placement: the evidence, troubleshooting techniques, and a guide to alternative monitoring options for intraoperative physicians. *Semin Cardiothorac Vasc Anesth.* 2019;23:369–78.
13. Terblanche NCS, Middleton C, Choi-Lundberg DL, et al. Efficacy of a new dual channel laryngeal mask airway, the LMA[®]Gastro[™] Airway, for upper gastrointestinal endoscopy: a prospective observational study. *Br J Anaesth.* 2018;120:353–60.
14. Ashworth AD, Greenhalgh DL. Strategies for the prevention of peri-operative transoesophageal echocardiography-related complications. *Anaesthesia.* 2019 [Epub ahead of print].
15. Lira Filho E, Rodrigues AC, Camarozano AC, et al. Recomendações para Acreditação de Laboratórios de Ecocardiografia. *Arq Bras Cardiol: Imagem Cardiovasc.* 2018;31:82–8.