



Infectious Bursal Disease Virus: Case Report and Experimental Studies in Vaccinated and Unvaccinated SPF Chickens and Commercial Broiler Chicks

■ Author(s)

Scanavini Neto H¹
Ito NMK^{2,3}
Miyaji CI^{2,3}
Lima E de A³
Okabayashi S³
Corrêa ARA¹
Eleutério GC¹
Zuanaze MA¹

- ¹ Laboratório Biovet S/A, São Paulo, SP.
- ² Professor de Ornitopatologia da Faculdade de Medicina Veterinária da Universidade Santo Amaro (UNISA), São Paulo, SP.
- ³ SPAVE Laboratório, São Paulo, SP.

■ Mail Address

Nair Massako Katayama Ito
SPAVE Consultoria em Produção e Saúde Animal
Ltda.
Rua Alvarenga Peixoto, 466
Vila Anastácio
05.095-010 - São Paulo, SP, Brasil.
Tel.: (11) 3644-4429 / 3821-2984

E-mail: spave@uol.com.br

■ Keywords

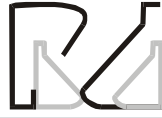Challenge, histopathology, IBD, pathogenicity, serology.

ABSTRACT

IBDV Gm 11 (Simbios eleven-molecular group) has been detected since 1997 in many farms of commercial broilers and layers causing high mortality (2 to 15%) and severe macro and microscopic damage in cloacal bursae, spleen, thymus, kidney and liver. Five serial passages of 2050/97-Gm 11 IBDV sample by CAM route in SPF chicken's embryonated eggs did not elicit increased embryo mortality. High mortality (100%) of 21 day-old SPF leghorn chickens and severe bursal and splenic lesions were seen from 24 up to 48 hours after eye-drop inoculation of 2050/97 strain (50 mL of 10⁻² dilution of 10% bursae homogenate). Mortality was not detected when vaccinated SPF and broiler chickens were inoculated. One dead bird was found among ten challenged unvaccinated broilers. Variations in the intensity of cloacal bursae injury and spleen response were found between unvaccinated and vaccinated broiler chickens. IBDV antibodies were detected by ELISA test in almost all vaccinated SPF chickens before challenge while low number of commercial vaccinated and unvaccinated broilers were serologically positive (0 to 3 birds in 18). Increasing IBDV antibody titers were detected after challenge with 2050/97 strain and highest GMTs were found in broilers. It was concluded that 2050/97 strain is a highly virulent IBDV and SPF leghorn chickens immunized with BV8 intermediate vaccine strain were resistant to the challenge. Increasing susceptibility was found from experimental groups of unvaccinated broilers to vaccinated broilers and to unvaccinated SPF birds. It is discussed that passive immunity was involved in the rate of protection of challenged unvaccinated broiler and in the immune response impairment after vaccination of broilers chicks. The use of a constant virus suspension with known potency to challenge the experimental birds was suitable to evaluate vaccination efficacy. Evaluation of bursal and splenic responses at early and delayed time after challenge were useful to estimate vaccination efficacy and field interactions.

INTRODUCTION

Gumboro disease or infectious bursal disease (IBD) was described at the first time in the early 1960. The occurrence of IBD was described in many countries after this report. Occurrence of many strains of IBD virus (IBDV) with low to moderate pathogenicity unable to cause mortality of Specific Pathogen Free (SPF) chickens was described in chickens until 1980's decade according to Lasher & Shane (1994). Virulent strains of IBDV (v.IBDV) considered as a classic type of IBDV (strain 52/70 or Fargher) which were able to induce 10 to 15% of mortality in experimentally inoculated SPF chickens appeared in UK in 1970. Occurrence of very virulent strains of IBDV (v.v.IBDV) causing high mortality of SPF chickens was reported in many European countries (DV 86, 89163, 849 VB, K 357/88, etc.) after 1986. Simultaneously, variant IBDV strains (var. IBDV)



with low to moderate pathogenicity appeared in USA. According to Sharma *et al.* (1989) var. IBDVs cause bursa of Fabricius atrophy in the absence of a clear inflammatory response, while classical IBDVs (v.IBDV and v.v.IBDV) induce an acute inflammatory reaction in the bursal tissue.

Nakano *et al.* (1972) were the first to report IBD occurrence in Brazil based in anatomo pathological findings. In 1978, Saukas reported the isolation of IBDV with moderate to low pathogenicity. Based on the agar gel immunodiffusion test, Ito *et al.* (1981) found in 40 flocks of commercial chickens sampled from 1979 to 1981, 80% of birds with less than 100 days of age, positive for IBDV-antibodies. Until 1990 (Ito *et al.*, 1990, 1992a) in Brazil, IBDV infection associated with immunosuppression and associated-syndroma were controlled by application of mild or intermediate vaccine strains in young broilers and layers. "Hot" type of vaccines were used in Brazil from 1990 to approximately 1996, despite the absence of any description of v. IBDV occurrence. One single record was made by some field veterinarians who found haemorrhagic bursa of Fabricius in chickens with presumptive immunosuppression. According to Lunge *et al.* (1997), in the past, the most prevalent IBDV were from genomic groups 15 and 16, named Brazilian variants by Ikuta *et al.* (1998, 2001). These strains of IBDV did not induce chicken mortality, caused mild to moderate bursal lesions and presented antigenic expression of classical type of IBDV according to ELISA test of antigen capture (ELISA-AC-KPL). The first cases of v.v. IBDV were described in Brazil (Di Fabio *et al.*, 1999 a,b) in the late 1990's decade. Simon & Ishizuka (2000) reported that high mortality due v.v.IBDV was suspected since 1995 in the Jacutinga town of Minas Gerais province.

This paper describes a practical method to study the mechanisms of protection elicited by an active immunization of SPF leghorn type birds and commercial broiler chickens with intermediate IBDV-vaccine strain (BV8® Biovet Laboratory) and the host response after challenge with 2050/97 v.v.IBDV strain.

MATERIAL AND METHODS

Clinical case

One broiler flock of 20.000 birds with 46 days of age presented in October 1997, a peak of increased mortality (approximately 1% per day) of chickens presenting prostration, ruffled feathers and dehydrated legs for three-consecutive days. Bursa of Fabricius covered with yellowish serous-fibrinous exsudate and

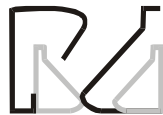swollen pale kidneys were seen in dead birds. After a short course of high mortality (3 to 4 days), clinically recovered birds presented atrophied cloacal bursae. This flock had been immunized at one day of age with intermediate strain of IBDV associated with HVT-Marek's disease virus injected by subcutaneous route. At 2 day-peak of mortality, ten birds taken at random were submitted to necropsy and blood sampling. This case received a protocol's number of 2050/97.

Virus isolation

Bursae of Fabricius harvested from sick birds were grinded in a mortar, resuspended at 10% in tryptose phosphate broth (TPB, Difco) and centrifuged at 1500 g for 30 minutes. Clarified suspension diluted at 10^{-2} in TPB and filtered (0,22µ Millipore filters) was inoculated in Specific Pathogen Free (SPF) chicken embryos (Granja Rezende, Uberlândia, MG) and 20-day-old SPF leghorn type chicks (Biovet Laboratory). Chicken embryos were inoculated by allantoic cavity (AC) and by chorioallantoic membrane (CAM) routes. Five serial passages were performed in SPF chicken embryos. SPF chicks inoculated with bursae tissue suspension (50µL/bird) by oral route were kept in isolation units (Biovet Research Center, Ibiuna, SP).

PCR (Polimerase chain reaction)

IBDVs were searched by PCR/RFLP (polimerase chain reaction/reverse transcriptase-polymerase chain reaction restriction fragment length polymorphisms) method described by Ikuta *et al.* (2001) (Simbios, Canoas, RS) in bursa of Fabricius and in CAM homogenates and allantoic fluid harvested from SPF chicken embryos inoculated with 2050/97 sample. RNA extracted from samples was reverse transcribed into c-DNA and the 248 bp IBDV – VP₂ fragments were digested with restriction enzymes submitted to aminoacids length and position analysis and classified in different genomic groups in comparison with standard Gen Bank and Brazilian field and vaccines strains of IBDV. Chicken anaemia virus (CAV) were searched in the same samples by PCR (Simbios, Canoas, RS). Total viral DNA from samples was isolated by the phenol: chloroform procedure (Sambrook *et al.*, 1989). Briefly, the samples were homogenized in phosphate buffered saline, harvested (15,000 x g; 2 min.), and suspended in distilled water. The aqueous layer was collected and sodium dodecyl sulfate (Sigma-Aldrich, St. Louis, MO) was added to a final concentration of 0.5%. The samples were incubated for 1 h at 37°C with 1.0 mg proteinase K/mL (Sigma-Aldrich) and extracted with an



equal volume of phenol and then chloroform: isoamyl alcohol (24:1). The RNA was precipitated using ethanol and resuspended in 50 mL of distilled water. DNA extracted from vaccine and field isolates was amplified in a 50 mL reaction volume according to the manufacturer's recommended procedure (CENBIOT Enzimas, Centro de Biotecnologia, RS, Brazil). Briefly, a 1 mL volume of DNA was mixed in a total volume of 50 mL consisting of 1 x PCR buffer, 1.5 mM MgCl₂, 0.25 mM each of dATP, dTTP, dGTP and dCTP, 0.5 mM of each primer (CAV-1F & CAV 2R) and 1.5 U *Taq* DNA polymerase in sterile filtered autoclaved water. After denaturation at 94°C for 3 min, the DNA was amplified using a thermocycler (Perkin-Elmer Cetus, Norwalk, CT) programmed for 40 cycles of denaturation at 94°C for 20s, annealing at 60°C for 40s, extension at 72°C for 60s, and a final extension at 72°C for 5 minutes. The amplified products were visualized after separation by electrophoresis on a 12.5% polyacrylamide gel and visualized by rapid silver staining (Sanguinetti *et al.*, 1994).

Histopathology

Spleen and bursae of Fabricius diameters were measured using a micrometer (Mitutoyo) before processing for histopathology. Formalin-fixed tissues were processed, stained with haematoxylin-eosin (HE) and examined in light microscopy (Ceti, Belgium). Microscopic alterations were scored in values from 0 to 6 according to the type of lesion and time-course for IBDV-induced alterations in the bursae of Fabricius based on descriptions of Cheville (1967), McFerran (1993) and Lukert & Saif (1997). Zero was given to normal bursae of Fabricius; 1 to mild loss of lymphoid cells or focal central epithelization in the medulla of follicles; 2 to cortex and medulla with lymphoepithelial cell degeneration or low number of lymphoid cells and when medullary-cortical boundary of epithelial cells was shrunken; 3 to cortex and medulla depleted of lymphoid cells and when lymphoepithelial cell predominate in the medullary region. Cell degeneration can be seen associated with mild infiltration of mononuclear cells

plus shrunken epithelium covering mucosal folds; 4 to increased number of mononuclear cells and heterophils in the follicle, interfollicular septum and mucosae lamina propria and hyperaemia are found the early infection. Recovered birds present invaginated mucosal epithelium, follicular lymphoid cell depletion and fibroplasy; 5 to medullar necrosis, marked lymphoid cell degeneration or depletion, intrafollicular cystic structures, severe infiltration of heterophils and mononuclear cells, petechial haemorrhage, edema as described for early infection with IBDV. Athrofied folds, cystic cavities in the follicle, loss of follicles and fibroplasy in the intrafollicular connective tissue as described for clinically recovered birds; 6 to serous transudate on the bursae serous surface, haemorrhagic necrosis at early time post infection or atrofied or fibrosed bursa of Fabricius in recovered chickens. The quantification of altered lymphoid follicles in the bursa of Fabricius was adopted based on the Sharma *et al.* (1989) criteria. Decimal values of 0,2 (5 to 25% of altered follicles); 0,4 (=26 to 50% of altered follicles); 0,6 (51 to 80% of altered follicles) and 0,8 (80% to 90% of altered follicles) were added to the 1 to 5 microscopic scores.

Thymus lesions were not scored. The presence of focal lymphocytolysis or lymphoid cells depletion in the cortex were recorded as positive for IBVD infection (Cheville, 1967).

Spleen IBDV-induced lesions found at early stage of infection related to the lymphoid tissue damage are not sustained after this period (Lukert & Saif, 1997). Following early injury, reactive white pulp is found as a consequence of IBDV infection (Cheville, 1997; Riddel, 1987). Thus, microscopic analysis of spleen was made considering IBDV-related necrosis on the periarteriolar sheath (PAS) and periellipsoidal white pulp (PWP) and immune response characterized by reticuloendothelial cells hyperplasy in the periarterial lymphatic sheath (PALS) and increased numbers of germinative centers (GC). The following criteria was adopted:

Score	IBDV-lesion	Immune response
0	PAS and PWP without reticuloendothelial cells hyperplasy.	Absence of PALS and GC.
1	Hyperplastic PAS, and increased number of mononuclear like cells in the PWP.	As score 1 to IBDV- infection.
2	Hyperplastic PAS, increased number of mononuclear cells around central vein and PWP and reactive PALS. Heterophils are seen in the sinusoids.	As score 2 to IBDV-infection.
3	Ellipsoid cells (EC) and PAS reticuloendothelial cells are degenerated. Heterophils and mononuclear cells increase in the PWP.	Increased number of PALS and some GC are seen in the parenquima.
4	Score 3 plus infiltration of heterophils in the PAS and PWP. Erythrocytes and haemossiderin deposition is found in the sinusoid.	One to two GC are found in each quarter of transverse section of spleen.
5	PAS necrosis associated with massive heterophil infiltration. in each quarter of transverse section of spleen.	GC number is increased and non-enumerable



Serology

IBDV and CAV antibodies were searched by ELISA test using, respectively, KPL and Guildhay commercial kits.

Challenge virus

Bursae of Fabricius homogenate obtained from infected SPF chickens were used to challenge experimentally vaccinated chicks. The inocula was searched for the presence of Gm11 of IBDV and respiratory virus growth by AC inoculation in chicken embryos. Bursa of Fabricius harvested 48 hours after inoculation of 2050/97 tissue homogenate in SPF chickens were grinded, resuspended at 10% in TPB, clarified by centrifuging at 1500g (Fanen), diluted at 1:10, fractionated in one mL vials and stored at -20°C until use for challenge tests. Stock virus was diluted at 10^{-1} and inoculated in 20 day-old SPF chicks as well as in the vaccinated birds.

Experimental groups

One day-old-SPF leghorn type chicks (48 birds) from Biovet Laboratory (Vargem Grande Paulista, SP) and commercial broiler birds (72 birds) were housed in isolation units (Biovet Research Center, Ibiúna, SP). Four experimental groups (A1, A2, A3 and A4) of 12 SPF chicks taken at random were housed in different isolation units. The experimental groups B1, B2, B3 and B4 were composed by 18 broiler chicks taken at random and housed in separate units. All birds received "ad libitum" sterilized water and fumigated feed during all experimental period. Serum samples were taken at one day of age from 10 SPF and commercial chicks.

Vaccination schedule

An intermediate strain of IBD vaccine (BV8-GumborVet® Biovet Laboratory) was used to immunize the birds. The A4 and B4 groups were not vaccinated. The first dosis of vaccine was given by eye-drop route and the other ones by oral route. A1 and B1 groups were vaccinated at one and seven days of age; A2 and B2 at one, seven and fourteen days and A3 and B3 at four and ten days of life. At twenty days of age, blood samples were taken for serological testing before challenge with 2050/97 inoculum (50µL by oral route for each bird). Chicks from each experimental groups were necropsied at 4, 15 and 22 days after challenge. Spleen, thymus and bursa of Fabricius were collected and fixed in formaline 10% for histopathology. Blood samples were taken at the same period from all alive birds for serum separation and IBDV-antibody titration.

Statistical analysis

Mean arithmetic values from different experimental groups were analysed using "T" Students test at 5% of significance ($p < 0,05$).

RESULTS AND DISCUSSION

2050/97 clinical and pathological report

Ten sick commercial chickens were taken in the second day after the beginning of increased mortality in a flock suffering IBD-like symptoms to make anatomopathologic, virologic and serologic investigations. Enlarged and serous fibrinous exudate deposition on the surface of cloacal bursae and bronzing liver and spleen were found at the necropsy. Macroscopic alteration was not found in the thymus. Histologic examination of bursa of Fabricius revealed extensive lymphoid follicles necrosis and heavy plasma and inflammatory cells exudation (Figure 1). Distended sinusoidal space, Küpffer cell degeneration and scattered degenerated hepatocytes were seen in the liver (9/10 birds). Lymphoid cell degeneration in the cortical region of thymus was found in 5/10 broilers (Table 1). All of ten microscopically examined spleens presented reactive ellipsoidal cells (EC) around the periarteriolar sheath (PA) but only 5/10 chickens presented PWP necrosis in the spleen (Figure 2) as described for early IBDV's replication (Cheville, 1967; Riddell, 1987; McFerran, 1993). Germinative centers (GC) were found in 3/10 broilers. Liver and cloacal bursae are target organs of early virus replication in the host. Primary virus spread into the gut and Küpffer cells arouse early viraemia, kidney infection and reinforced virus replication in the bursae of Fabricius which happens at 11 hpi (McFerran, 1993). So, it can be drawn that the clinical symptoms seen in the field outbreak are related with rapid and strong early viraemia. Massive virus replication in the bursae of Fabricius elicits a second pronounced viraemia which arose secondary virus replication in the spleen, thymus, cecal tonsils and kidneys at 2 to 8 dpi (McFerran, 1993). So, it can be concluded that five out of ten sick broilers were suffering secondary viraemia and virus replication once they presented spleen and thymus microscopic lesions. The presence of three birds with spleen reactive white pulp suggests that secondary virus replication could be attenuated by previous immunological system sensibilization due to vaccine application at one day of age since actively sensitized chickens at early age were protected in some degree against IBDV challenge (McFerran, 1993; Lukert & Saif, 1997; Knoblich *et al.*,

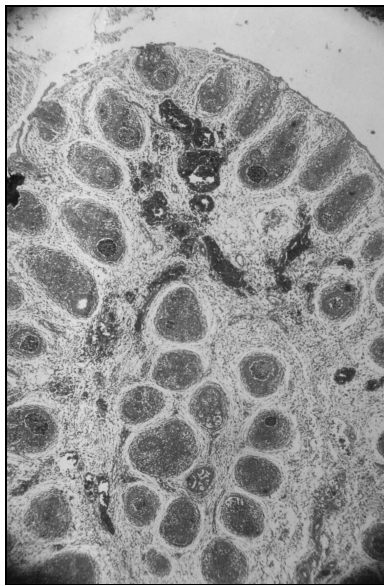


Figure 1 - Bursa of Fabricius from broiler naturally infected with Gm 11-IBDV. (40x magnification, H & E stain). Lymphoid follicles necrosis and focal haemorrhages can be seen in the figure. Edema is present in the interstitial conjunctive tissue.

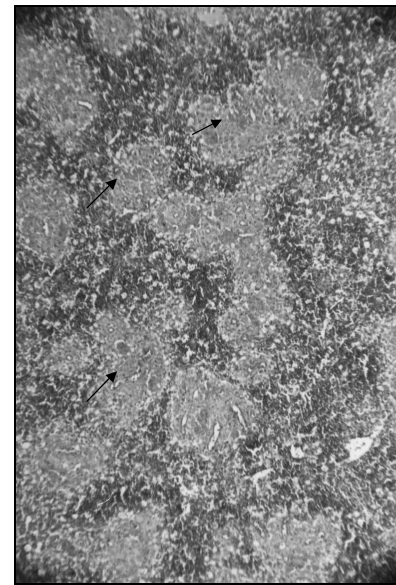


Figure 2 - Histopathology of spleen from field infected broiler (100X magnification, H & E stain). Extensive necrosis of periarteriolar sheath (arrow) is seen in white pulp. Red pulp is strongly blue-stained due to the presence of mononuclear cells.

Table 1 - Anatomopathological, virological and serological findings at the beginning of IBDV-induced mortality in a commercial broiler flock (case 2050/97, São Paulo, Brazil).

Material	Macroscopic alterations		Microscopic alterations			Virus detection by PCR ⁽¹⁾	
Bursa of Fabricius	10/10 ⁽²⁾		10/10			Positive for Gm 11	
Liver	3/10		9/10			Not done	
Spleen	3/10		5/10			Not done	
Thymus	0		5/10			Not done	
Serum samples	Titer ⁽³⁾	0	702	801	1217	1514	4197MT = 940 GMT = 55
Number of birds	4	1	1	1	1	1	Total = 9 CV% = 105,6

1 - PCR according Simbios, Canoas, RGS; 2 - positive on total; 3 - titers of antibody, ELISA test, KPL; MT = mean titer; GMT = geometric mean titer, CV% = coefficient variation.

2000). Reactive spleen white pulp is a common feature in convalescent birds onwards five days post-infection when bursa of Fabricius has shrunken to one quarter to one-eighth of its original size (Cheville, 1987; Riddel, 1987). Three out of ten broilers presenting oedematous bursae of Fabricius presented GC and reactive EC around PA; thus, suggesting that massive virus replication and PWP damage was impaired by the presence of circulating antibodies. According to data of Table 1, five birds presented antibodies when tested by ELISA test. Virulent strains of IBDV overcome VN antibodies titers less than 1: 500 (Lukert & Saif, 1997);

so, it is probable that three broilers with reactive white pulp were the same which also presented antibody titer higher than 1:1000. These findings suggest that mortality caused by v.v.IBDV field infection in broiler vaccinated with one dosis of intermediate vaccine can be reduced by the impairment of secondary viraemia influenced by the presence of circulating antibodies and reactive white pulp.

Virus isolation

Virus isolation in the altered bursae of Fabricius was performed by inoculation of tissue homogenate in SPF embryonated chicken eggs. Haemmaglutinating virus growth was not found in embryonated eggs inoculated by CA and CAM routes. In spite of IBDV positivity for GM11 by PCR-RFLP, bursa homogenate inoculated by CAM route didn't result in increasing embryo mortality even after five serial and successive passage in chicken embryos but caused 100% of mortality when inoculated in SPF leghorn chickens with 21 days of age. It is known that IBDV isolation in tissue cultures and chicken embryos is not a sensitive method for recovering virulent and very-virulent field strains (McFerran, 1993). Very virulent IBDVs should be passed in susceptible chickens to keep its virulence (McFerran, 1993) since blind passages of virulent strains in embryonated chicken eggs can induce virus attenuation or clonal selection of less pathogenic strains which easily grow in this



experimental host system (Yamagushi *et al.*, 1996). Some chicken embryo-low passaged virulent IBDVs (Malaysian strains) are able to induce high embryo mortality without showing genomic markers for virus attenuation (Hoque *et al.*, 2001). Very virulent strains like 2050/97-GM11-IBDV seem not to grow in embryonated chicken eggs in the same rate of some virulent strains because massive virus replication was not achieved due to low number of bursal cells in the development embryos. The major target cells for IBDV replication is actively dividing surface immunoglobulin M-bearing B cells (McFerran, 1993; Lukert & Saif, 1997) which are not found in chicken embryos. Bursal cells in chicken embryos are represented by progenitor cells in the epithelial bud which only turn to medullar B cells bearing IgM on its surface after hatching (Rattcliffe *et al.*, 1996). IBDV virulence expression for embryos, as well as in growing chickens, seems to need a massive replication in target cells for full expression of its virulence or pathogenicity. So less attenuated strains of IBDV should not induce high embryo mortality. Differences in chicken embryo lethality can be seen between intermediate and "hot" type of vaccine strains of IBDV inoculated in embryonated chicken eggs (Ito *et al.*, 1992b). Based on these findings, 2050/97 inocula for challenge tests were prepared with bursa of Fabricius harvested from experimentally inoculated SPF growing chickens. Bursal tissue homogenate were searched by PCR for the presence of CAV and IBDV before use throughout the experiments. CAV genome was not detected and GM11-IBDV was found in the inocula.

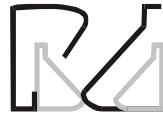Virus inocula for challenge tests

Cloacal bursae harvested from experimentally infected SPF chickens were used as a source of virus suspension at a constant dilution (with ability to cause 100% of mortality of 20-day-old SPF chickens) to challenge vaccinated chickens instead of using a known titer of virus (DI50 or DL50). Experimental studies with IBDVs are currently done using 100 ID50 or 100 DL50 to establish pathogenicity differences between field strains (Sharma *et al.*, 1989; Hoque *et al.*, 2001) and for challenge tests in actively immunized chickens (Maas *et al.*, 2001). The use of a constant fractionated virus suspension with a known potency for causing death and bursal damage in SPF chickens could be useful to substitute the labour and high costing virus titration in susceptible chickens using many isolation units. This method is also suitable for studying highly lethal virus

like v.v. IBDVs because these types of viruses cause different pattern of mortality and histologic bursal damage according to chicken age (McFerran, 1993; Lukert & Saif, 1997) even when 4-week-old SPF chickens are infected with 100 DL50 (Van der Berg *et al.*, 1991). Age dependent-susceptibility of chickens to the clinical disease induced by v. IBDVs and v.v.IBDVs does not seem to be related with virus-dosis-dependent response. Age susceptibility of chickens for clinical IBD may lie with the factors related to the host such as blood clotting time, immunological injury (Lukert & Saif, 1997) or maximum development of bursa and B cells distribution in the peripheral lymphoid tissues (McFerran, 1993). According to Vervelde & Davidson (1997), lack of clinical signs of IBD in neonate chicks was neither due to failure to respond to the virus, to recruit leukocytes to the infected tissues nor to a lack of virus replication. Immunological factors or the bystander effects due to cytokine release or blood factors of the host seem to play an important role in the age related susceptibility (Vervelde & Davidson, 1997). So, the use of a constant virus suspension with known potency for a known chicken's age can be considered when assaying IBDV's in the natural host. It was found that vaccinated SPF birds and commercial broilers did not present mortality and an extensive bursa and spleen damage as seen in non vaccinated SPF leghorn chicks infected with the same inocula. It was also seen that antibody titers and spleen reactions before and after challenge with a constant highly lethal virus suspension of v.v.IBDV showed a distinct pattern of response and can have an important role in the protection of birds.

Challenge test in vaccinated and non vaccinated chickens

Experimental findings in vaccinated and unvaccinated chickens challenged with 2050/97 strain of IBDV will be exposed and discussed considering: (1) early phase of v.v.IBDV infection characterized by occurrence of mortality and degenerative and acute inflammatory responses in tissues caused by virus replication in non vaccinated SPF chickens, actively immunized SPF and commercial broilers with maternal antibodies and in commercial chickens with passive immunity against IBDV; (2) antibody response induced by challenge of actively immunized and non-immunized chickens; (3) bursa and spleen size after challenge and; (4) delayed or atrophic phase of v.v.IBDV infection related to loss of lymphoid tissue and/or stimulus of splenic immune response caused by challenge at 21 day of age in non vaccinated and vaccinated chickens.



Early findings after 2050/97 challenge in vaccinated and unvaccinated chickens

Dead birds were found in A4-experimental group of unvaccinated SPF chickens (12/12), B4-unvaccinated commercial broiler experimental group (1/18) and in the B3-vaccinated broiler group (1/18), 3 to 4 days after 2050/97 virus challenge (Table 2). Dead birds presented haemorrhagic and oedematous bursae of Fabricius and pale kidney as were found in the field diseased chickens. The inability of 2050/97 inocula to express its response of 100% lethality for SPF chickens when inoculated in 21 day-old-commercial broilers should be discussed considering genetically mediated resistance, host related-responses after challenge and passively acquired immunity interfering with virulence expression of challenge virus. Leghorn chickens and their crosses were thought to be more sensitive than heavier meat breeds, but this was not confirmed when mortality figures caused by v.IBDV from natural outbreaks were compared (McFerran, 1993; Lukert & Saif, 1997). Field outbreaks involving Gm 11 v.v.IBDV infection has been related to occurrence of higher mortality in growing layer type birds than in broiler chickens. Higher mortality of Leghorn type birds could be related with their low resistance to dehydration or fluid imbalance found during early phase of IBDV infection. It is known that reduced water consumption, severe prostration or fever and

dehydration are found before death. Swollen, pale kidneys and nephrosis are common findings only in dead birds. Residual passive immunity found in 21 day-old broiler (Table 1) does not seem to be the unique factor which prevented the early mortality induced by v.v.IBDV since in the B2 experimental group of vaccinated heavy birds, circulating antibody was not detected in 18 challenged chickens and mortality was not found. Commercial broiler chickens as compared to Leghorn type birds seem to have a genetically-mediated-resistance if considered that no unvaccinated heavy-birds without detectable humoral antibodies died after challenge as did SPF chicks. Cellular responses mediated by the major histocompatibility complex (MHC) found in B allele of chickens can modify the intensity of thymus and liver damage and the level of erythrocyte sedimentation coefficient found during early viraemia without interfering with occurrence of bursae damage (Nielsen *et al.*, 1998). Even considering that v.v.IBDV-induced mortality was prevented by active immunization of SPF leghorn and broiler chickens with an intermediate vaccine strain, the elicited antibody response seems to have a minor role in death protection because vaccinated broiler without detectable antibodies did not die. It can be discussed that cellular responses induced by active vaccination could have an important role in death prevention.

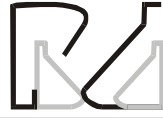Table 2 - Antibody response at 21 days of age in chickens submitted to distinct early vaccination schedules using intermediate strain of IBDV-vaccin (BV8® Biovet).

Experimental Group	Antibodies (ELISA test) ¹			Titer distribution				Mortality after challenge
	MT ± sd	GMT	CV (%)	Neg	≤1000	1000 to 2000	>2000	
A1	2231 ± 1583(a)	1083	62,3	1	1	5	5	0/12
B1	31 ± 133,4(b)	1	226,5	17	1	-	-	0/18
A2	2203 ± 1395(a)	985	60,6	1	2	3	6	0/12
B2	0 ± 0,00(b)	1	0,0	18	-	-	-	0/18
A3	1883 ± 1245(a)	565	60,7	2	2	1	7	0/12
B3	123 ± 357,2(b)	2	151,4	16	-	2	-	1/18
A4	0,0 ± 0,00(b)	0	0	12	-	-	-	12/12
B4	127 ± 295,0(b)	3	150,5	15	3	-	-	1/18

¹ - MT ± sd = mean titer ± standart deviation; GMT = geometric mean titer; CV = coefficient variation; Neg = negative; similar letter in parenthesis represent non-significant differences (p > 0,05).

It is known that very early vaccination in neonate chicks can elicit an antibody response (Lukert & Saif, 1997) lower and slower than in 3-week-old birds (Vervelde & Davidson, 1997) and maternally derived antibodies interfere with early IBDV infections (McFerran, 1993; Lukert & Saif, 1997) and IBDV live vaccine immunization (Van der Berg & Meulemans, 1991). So, the differences in distribution of antibody

titers found between SPF leghorn type birds and commercial broiler chickens experimental groups are expected. Lowest antibodies titers were found in the vaccinated commercial broiler chickens as compared to the SPF birds (p<0,05) (Table 2). Maternal antibodies detected at one day of age only in broiler chicks (MT = 4808; GMT = 4642 and CV (%) = 26,6) can have influenced on the antigen presentation thus on the



humoral response found in broilers actively immunized with BV-8 intermediate vaccine strain of IBDV. Also, as the vaccinated SPF chickens did not show mortality after 2050/97 challenge it can be drawn that immune response elicited by BV-8 vaccine strain is able to confer good protection against Gm 11 v.v.IBDV.

Early time, 4th day-post-challenge (dpc) bursal responses after challenge with 2050/97 strain in vaccinated SPF Leghorn birds were significantly different ($p < 0,05$) from those found in unvaccinated SPF chickens and commercial broilers and vaccinated broiler from B1 and B3 experimental groups (Table 3). Occurrence of bursal-microscopic lesions is related to very early massive virus replication in the lymphocytes and resident-macrophages which elicits a local inflammatory response (Riddel, 1987; McFerran, 1993; Adair, 1996; Randall & Reece, 1996; Lukert & Saif, 1997; Vervelde & Davidson, 1997). The pattern and/or extension of bursal inflammatory response vary according to the type of IBDV and extension from local virus replication. The finding of low bursal scores in vaccinated SPF birds can

be related to reduced early viraemia after primary replication in the liver due to the presence of high titers of circulating antibodies induced by active immunization. The slight decrease of bursa score in B2 experimental group of broilers (in which antibody was not detected) when compared to the unvaccinated birds suggests that cellular response found in vaccinated chickens is able to reduce local virus-induced-injury and thus secondary viraemia which elicits spleen damage. In fact IBDV induced injury in the spleen of vaccinated birds was significantly lower than that found in non vaccinated birds (Table 3). The improvement of the rate of protection of the spleen against IBDV replication in splenic lymphocytes and ellipsoidal cells around PWP can be due to the impairment of secondary viraemia by interferon release and CD4⁺ and CD8⁺ T lymphocytes stimulation in bursa of Fabricius by active immunization as well as during early viral replication. According to Vervelde & Davidson (1997) T lymphocytes can be present in bursal interfollicular tissue and cortex when VP2 – IBDV protein is found in bursal B and mononuclear cells.

Table 3 - Bursa of Fabricius and spleen microscopic evaluation at 4th day post inoculation of 2050/97-v.v.IBDV in vaccinated and unvaccinated chickens.

Experimental group	Bursa of Fabricius		Spleen mean score		Lesioned thymus (number/total)
	Mean score	Birds with Score > 5	IBDV type	Immune response	
A1	2,00 ± 1,73a ¹	0/3*	3,00 ± 0,00a	0,00 ± 0,00a	1/3
A2	3,33 ± 2,89a	2/3	1,67 ± 0,58b	3,67 ± 0,58b	0/3
A3	1,67 ± 2,89a	1/3	1,00 ± 0,00c	5,00 ± 0,00c	0/3
A4	6,00 ± 0,00b	12/12	5,00 ± 0,00d	0,00 ± 0,00a	ND
B1	4,93 ± 1,33b	2/3	2,33 ± 1,15a	1,33 ± 1,15d	2/3
B2	3,80 ± 3,29ab	2/3	1,67 ± 0,58b	0,33 ± 0,58a	2/3
B3	5,60 ± 0,20b	3/3	1,33 ± 0,58b	3,67 ± 1,15b	0/3
B4	5,50 ± 0,20b	4/4	4,50 ± 1,0d	0,00 ± 0,00a	0/4

1- Small letter represent comparison between groups in the same column and differences are represented by different letters ($p < 0,05$). Mean score values are represented by mean ± s.d; (*) = number/total.

Increased IBDV-type spleen necrosis found in non vaccinated chickens was inversely related to the presence of GC and PAS. So the high score for immune response or reactive white pulp found in vaccinated SPF chickens from A3 and, in a lesser grade, for A2 and B3 experimental groups at 4th dpc can have some role in the spleen protection against v.v.IBDV. Concluding, early microscopic changes in bursae of Fabricius and spleen can be useful for evaluation of rate of protection induced by active immunization. Otherwise thymus microscopic alteration in the cortex was not a consistent finding. Only one bird from A1 experimental group and 2 birds from B1 and B2 groups presented lesioned thymus at 4th dpc. Mild multifocal lymphoid or

lymphoepithelial cell degeneration was found in the cortex as described for 5/10 naturally infected broilers. The type and extension of thymus lesion found after 2050/97 infection seems to be distinct and milder than that described for IM pathogenic strain of IBDV for Sharma *et al.* (1989). It is known that IBDV-induced thymus injury varies according to the IBDV strain (Sharma *et al.*, 1989) and can be related to cytokinins and or nitric oxid release which triggers lymphoid cell apoptosis or MHC expression (Nielsen *et al.*, 1998).

Antibody response in vaccinated and unvaccinated chickens after 2050/97 challenge

According to Table 4, active immunization with BV8



intermediate vaccine strain of IBDV was able to elicit an antibody response in the majority of SPF Leghorn birds submitted to distinct vaccination schedules before challenge. Small number of serologically positive and non-significant ($p > 0,05$) difference of antibody titers when compared to unvaccinated broilers and SPF chickens was found before challenge in the vaccinated commercial broiler experimental groups. This finding is in agreement with the discussion above, that passive immunity could impair antibody response elicited by active immunization. The absence of a significant increase of antibody titers following 2050/97 challenge in immune SPF chickens (A1, A2 and A3 groups) is in agreement with the previous discussion that v.v.IBDV infection was arrested by active vaccination with BV8 vaccine strain. Thus it can be concluded that BV8 strain could share common antigens with 2050/97 v.v.IBDV which can stimulate an active protective immune response. Otherwise, the significant increase of antibody titer in the 15th day after 2050/97 inoculation in the experimental groups of commercial broilers can be due to virus challenge-induced humoral response since high microscopic scores were found in the bursa of Fabricius at early time post-infection (Table 3). The continuous increase of antibody titer from 15 to 22 dpc in B1, B3 and B4 experimental groups as compared to the B2 response at the same period suggest that in this group, virus challenge was arrested earlier than in the other ones. It seems that vaccination schedule can have an important role in inducing protection in commercial broilers with maternal antibodies. The fact that in the B2 experimental group of chickens vaccinated at 1,7 and 14 days of age antibodies were not detected in none of the chickens at the time of challenge as compared to B1 and B3 groups and unvaccinated B4 experimental group, suggests that cellular immunity induced by active immunization could play an important role in the protection against challenge. It is important to consider that low titer of antibodies found before challenge should be carefully interpreted. ELISA test performed with KPL commercial kit could give false positive results due to its low specificity and high sensitivity (Witt *et al.*, 2001).

Bursa and spleen sizes

SPF Leghorn type of chickens from vaccinated experimental groups did not show increased size of bursa of Fabricius and macroscopic alterations at 4 dpc with 2050/97 strain of v.v.IBDV. At this time bursae of Fabricius were larger than spleen in A1 group ($p < 0,05$) and at non-significant level in A2 group. Following this

Table 4 - Effect of 2050/97 challenge on the antibody response in 21 day-old vaccinated and unvaccinated chickens.

Experimental groups	Days after challenge ¹		
	0	15	22
A1	2231 ± 1583a,A	3165 ± 1181a,A	3059 ± 1389a,A
A2	2023 ± 1395a,A	4524 ± 2054a,A	3853 ± 1949a,A
A3	1883 ± 1245a,A	2891 ± 1045a,A	3281 ± 893a,A
A4	0 ± 0b,B	-	-
B1	31 ± 133b,B	3065 ± 987a,C	5835 ± 1576a,D
B2	0 ± 0b,B	2638 ± 763a,C	4665 ± 1642a,C
B3	123 ± 357b,B	2481 ± 814a,C	6279 ± 1928a,D
B4	127 ± 295 b,B	2763 ± 852a,C	6448 ± 2043a,D

1 - Antibody titers are represented as mean titer ± s.d detected by ELISA test (KPL); small letter represent comparison between column data, similar letters mean no difference ($p > 0,05$); capital letters represent comparison between days after challenge, similar letter mean no difference ($p > 0,05$).

period (15 and 22 dpc), bursae of Fabricius were significantly larger than spleen ($p < 0,05$) in all experimental groups. Otherwise, vaccinated and unvaccinated commercial broiler chickens presented at 4 dpc bursae of Fabricius larger than spleen ($p < 0,05$). In the following period of 15 and 22 dpc, decreased size of bursae of Fabricius in relation to the 4dpc was found in all experimental groups. Significantly smaller bursae of Fabricius in relation to spleen was found at 15 dpc in B3 and B4 groups and at 22 dpc in B1 and B3 groups (Table 5). Bursa of Fabricius of healthy chickens increases in size after hatching up to sexual maturity while spleen do not show significant size increase during all life (Getty, 1981; Riddel, 1987). Larger bursae of Fabricius in relation to spleen found in vaccinated SPF chickens inoculated with 2050/97 v.v.IBDV are in agreement with normal and non-injured lymphoid tissue, thus it means good protection against challenge. However, significantly increased size of bursae of Fabricius in relation to spleen found at 4 dpc in commercial broilers can be related to IBDV-induced injury in both organs. Between the 3rd to 4th day post-infection with IBDV, bursae of Fabricius increase in size and weight due to the presence of edema and hyperemia (Lukert & Saif, 1997) and spleen can show reduced size due to germinal centers and perivascular sheaths necrosis (McFerran, 1993). Following 5 to 7 days post-infection, bursal atrophy is found in chickens without protection or in the case of infection with pathogenic IBDV. Spleen may be slightly enlarged and with small gray foci (Lukert & Saif, 1997) due to antigenic stimulus (Riddel, 1987). So decreased size of bursa of Fabricius at 15 and 22 dpc in relation to the 4th dpc can be related to loss of lymphoid tissue due 2050/97 virus infection. The enlargement of spleen from



15 to 22 dpc found in some experimental groups (A1, A3, B1) can be related to reactive white pulp induced by contact with virus present in the isolation units microenvironment.

Table 5 - Bursa of Fabricius and spleen sizes in vaccinated and unvaccinated chickens of different experimental groups challenged with 2050/97 strain of IBDV.

Experimental group	Organ	Days after challenge		
		4	15	22
A1	Bursa ¹	3,0 ± 0,00a,b	4,67 ± 0,29a,b	4,50 ± 0,77b
	Spleen	2,5 ± 0,00	2,83 ± 0,58	3,25 ± 0,27
A2	Bursa	3,33 ± 0,29	4,17 ± 0,76b	4,42 ± 0,66b
	Spleen	3,17 ± 0,29	3,00 ± 0,00	3,17 ± 0,26
A3	Bursa	ND	4,25 ± 0,35b	4,90 ± 0,55b
	Spleen	2,50 ± 0,00	2,50 ± 0,00	3,30 ± 0,27
B1	Bursa	4,50 ± 0,00a,b	3,00 ± 0,50a	3,11 ± 0,33a,b
	Spleen	3,83 ± 0,29	3,33 ± 0,58	4,00 ± 0,00
B2	Bursa	4,00 ± 0,00a,b	3,67 ± 0,29a	3,40 ± 0,47a
	Spleen	3,33 ± 0,58	3,83 ± 0,29	4,21 ± 0,45
B3	Bursa	4,33 ± 0,58a,b	3,00 ± 0,00a,b	3,04 ± 0,25a,b
	Spleen	3,17 ± 0,29	4,00 ± 0,00	4,15 ± 0,32
B4	Bursa	4,25 ± 0,29b	3,17 ± 0,29a,b	3,23 ± 0,60a
	Spleen	3,38 ± 0,48	4,00 ± 0,00	4,00 ± 0,41

1 - statistical differences between bursae of Fabricius at 4dpc and 15th and 22th dpc in the same group (p<0,05); (b) = statistical differences between bursae of Fabricius and spleen at the same period of time in the same groups (p<0,05).

Delayed microscopic changes in bursa of Fabricius

Bursa of Fabricius scores at 4th day-post-2050/97 virus inoculation were based in the observation of acute inflammatory response caused by virus injury. At this period it is expected that non-immune chickens challenged with pathogenic strains of IBDV present extensive cortex and medulla damage and massive infiltration of mononuclear phagocytes and/or heterophils (score ≥5,0) (Lukert & Saif, 1997). According to data of Table 3, acute lesioned bursa was found in 100% of challenged birds from A4, B3 and B4 experimental groups, in 2/3 birds from A2, B1 and B3 groups, 1/3 from A3 group and none from A1. This finding is in agreement with 2050/97 challenge-virus colonized bursal tissue in larger or lesser extent between experimentally infected chickens of each group and some extent of protection was elicited by active immunization. It is expected that surviving infected birds will exhibit an increasing number of T lymphocytes in the bursa interfollicular tissue and cortex. From 8 dpc onwards bursae from chickens infected with F-52/70-v.IBDV-strain began to recover and B cells repopulate the follicles with preserved medulla microenvironment

or lymphoreticular cells, T cells can be increased in number and mononuclear cells and granulocytes decreased in number (Vervelde & Davidson, 1997). Increase of interfollicular fibrous tissue, atrophied follicles, cyst-like structures and reduced number of follicles are found when extensive follicle destruction is induced at early phase of infection (Riddel, 1987; McFerran, 1993; Lukert & Saif, 1997). As all SPF vaccinated Leghorn type birds from A3 presented normal bursae at 15th and 22th dpc with 2050/97-v.v.IBDV while in the A1 experimental group, 1/6 birds was found at 22th dpc and in the A2, one bird at 15th and 22th dpc (Table 6), we can conclude that bursal damage was well prevented by vaccination in the majority of SPF birds and that the presence of the same birds with intense bursal damage at delayed time could be related to contact with virus shedded by subclinically infected chickens present in the isolation units. It was expected that birds with extensive damage of bursal tissue after challenge with 2050/97-v.v.IBDV strain (score 6,0) would not restore the bursal tissue, but according to Vervelde & Davidson (1997) at 21 dpc, differences in the extent of the bursal morphology between F52/70 infected SPF birds are enormous, in that some birds had almost fully restored follicles while other birds had follicles with only a few B-cells. This pattern of bursal tissue recovery was found when commercial broilers were challenged with 2050/97 strain of IBDV after active immunization and non-immunization with BV8-intermediate vaccine strain. Similar findings were described by Bolis *et al.*, (2003) in broilers vaccinated with Moulthrop "hot" type vaccine strain of IBDV and challenged with 2050/97 strain. Variation in the number of commercial broiler birds with atrophied bursae (score≥5), in spite of non-significant differences detected in bursal size (Table 5) and microscopic mean scores (Table 6) from 15th to 22th dpc, suggests that morphologic restoration was not only influenced by the vaccination schedule. According to the results found in SPF vaccinated birds, fully protection of bursa of Fabricius was found in A3 experimental group vaccinated at 4 and 10 days of age and lower number of unrecovered bursal tissue was found in the B3 commercial broilers and non-vaccinated B4 experimental group of broilers. In the experimental groups vaccinated at 1 and 7 days (A1, B1) and 1,7 and 14 days, atrophied bursae were found at 22th dpc. So virus recycling or low rate of reexposition should be considered in the closed microenvironment of isolation units since bursa with score lesion 5 was found in SPF vaccinated birds at 22th dpc in the absence of spleen



Table 6 - Bursa of Fabricius and spleen microscopic observation at 15 and 22 days after challenge with 2050/97 v.v.IBDV in SPF and commercial broiler chickens vaccinated with BV8 intermediate vaccine strain.

Experimental group	Time (days) after challenge	Bursar of Fabricius ¹	Spleen mean score			Lesioned thymus Immune response
			Mean score	Birds of score ≥ 5 on total	IBDV-type	
A1	15	0,00 \pm 0,00	0/3 (0,0%)	0,00 \pm 0,00a	1,33 \pm 1,15a	0/3
	22	1,00 \pm 2,00a	1/6 (16,6%)	0,00 \pm 0,00a	2,00 \pm 1,79	1/6
A2	15	1,67 \pm 0,29	1/3 (33,3%)	0,00 \pm 0,00a	3,67 \pm 1,15	1/3
	22	1,00 \pm 2,00a	1/6 (16,6%)	0,00 \pm 0,00a	3,00 \pm 2,45	1/6
A3	15	0,00 \pm 0,00	0/3 (0,0%)	0,00 \pm 0,00a	3,67 \pm 1,15b	0/3
	22	0,00 \pm 0,00	0/6 (0,0%)	0,00 \pm 0,00a	0,50 \pm 1,22 b	0/6
B1	15	3,91 \pm 0,98	1/3 (33,3%)	0,00 \pm 0,00a	3,00 \pm 0,00	0/3
	22	4,77 \pm 1,01	8/11 (72,7%)	0,78 \pm 0,48	2,22 \pm 1,79a	0/6
B2	15	4,47 \pm 1,53	1/3 (33,3%)	1,00 \pm 1,00a	1,75 \pm 2,21a	0/3
	22	4,20 \pm 1,47	7/13 (53,84%)	0,85 \pm 0,38	1,31 \pm 1,38a	1/8
B3	15	5,57 \pm 0,40	3/3 (100,0%)	1,67 \pm 0,58b	4,33 \pm 1,15	0/3
	22	4,10 \pm 1,28	2/10 (20,0%)	0,00 \pm 0,00a,b	3,73 \pm 1,38	1/6
B4	15	3,90 \pm 1,52a	1/4 (25,0%)	1,33 \pm 0,58	2,67 \pm 1,15a	0/3
	22	4,11 \pm 1,35	2/9 (22,2%)	1,10 \pm 0,32	3,40 \pm 0,84	1/6

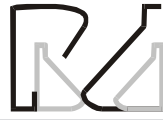1- without statistical difference between SPF and broiler ($p > 0,05$); 2- difference in the same group between 15 and 22 day ($p < 0,05$).

injury and lesioned thymus. Vervelde & Davidson (1997) reported that VP2 fraction of IBDVs are rarely found in bursa and spleen cells at 10 days after infection of SPF chickens, so an absence or low acute microscopic score in the bursa should be expected at 15th dpc in commercial vaccinated broilers and represent an overview of vaccination efficacy in the field. Increased rate of virus shedding and/or infection of birds with marginal immunity causing delayed bursa atrophy could be expected in challenged flocks which present low number of birds showing atrophied bursae or low microscopic score at 15th dpc. Broiler's experimental group with high microscopic score at 15th day (B3 group), showed lower number of atrophied bursae at 22th day and significant increase of antibody titer (Table 4) at this period. This finding suggests that 2050/97 virus challenge at 21 days of age was able to colonize bursal tissue of many if not all birds and stimulate spleen immune response and thus antibody increased response. In the same way B4 unvaccinated commercial broilers exhibit severe bursal damage at 4th dpc (Table 3). The early bursal injury could induce early bursa restoration and thus protection for microenvironment shedded virus. A rapid increase of CD4⁺ and CD8⁺ T cells in the bursal tissue during the first week after IBDV infection in chickens (Vervelde & Davidson, 1997; Poonia & Charan, 2001) can be involved in bursal tissue restoration. Bursal tissue restoration was found after inoculation of a vaccine strain (Geo) and a field isolate of IBDV (FIV) which were able to cause heterophils infiltration and lymphocytes necrosis along with vesicles formation in bursa follicles at early time post-infection (3rd to 7th dpi) (Poonia & Charan, 2001), and also after administration of Moulthrop "hot" strain of IBDV vaccine (Bolis *et al.*,

2003) in chickens. It should be discussed that the presence of some birds with very low titers of humoral antibodies (B3 = 2/18 and B4 = 3/18) could have attenuated the extension of bursa damage caused by 2050/93 v.v.IBDV. The role of passive acquired immunity on the immune response induced by early vaccination in commercial chickens has been extensively discussed (McFerran, 1993; Van der Berg & Meulemans, 1991). Maas *et al.*, (2001) described that maternal antibodies found in day-old Leghorn chicks hatched from dams vaccinated with different vaccine-strains of IBDV presented distinct pattern of mortality and bursal damage when challenged with 52/70 v. IBDV strain and D6948 v.v.IBDV strain. They concluded that protection against IBDVs depends on titer of antibody, virulence of IBDV-challenge strain and the IBDV-vaccine strain.

Spleen response after challenge

IBDV-induced spleen necrosis is related to secondary viraemia elicited after massive virus replication in the bursa of Fabricius (McFerran, 1993). As described in Table 3, at the 4th day-post-challenge, 2050/97-v.v.IBDV was able to cause extensive splenic damage in the absence of a reactive white pulp in unvaccinated SPF Leghorn chickens and commercial broilers. Otherwise lowest microscopic score related to IBDV injury was found in vaccinated birds, as compared to the unvaccinated ones. The finding of reactive white pulp at 4th day-post-challenge in A2, A3, B3 experimental birds which presented low IBDV-type score can be attributed to the effect of vaccine-induced immune sensitization. GC were formed only after PAS restoration and at 5 to 8 day onwards IBDV infection (Vervelde &



Davidson, 1997). As the reactive white pulp characterized by increased PALS and GC were found mainly in vaccinated SPF chickens and in a lower number of vaccinated broilers, it can be supposed that the vaccine application could have had elicited this response and induced some protection for secondary viraemia and death of birds. At delayed period (15th and 22th dpc) after 2050/97 v.vIBDV challenge, IBDV-type mean score was decreased in the spleen of birds from all experimental groups and immune response was predominating (Table 6). This fact is in agreement with the fact that in some way, virus-challenge antigen was trapped by macrophages from red and white pulp and triggered PALS and CG proliferation. Spleen is the most important site of antigen processing by mononuclear phagocytic cells and initiation of an immune response (Tizard, 1979; Olah & Glick, 1982) so microscopic analysis could be a good method to evaluate IBDV infections as well as vaccination efficacy. Values of 1 and 2 described for microscopic score of spleen is related to antigen trapping by mononuclear cells from PAS and antigen presentation, thus it can be found after IBDV vaccine administration or when the bird is exposed to immunogenic substances (Olah & Glick, 1982; Riddel, 1987). Score 3, 4 and 5 IBDV-type lesion is found only at early period after virulent IBDV infection. Based on literature data it is expected that after early injury caused by virulent IBDV or vaccine immunologic stimulus of spleen white pulp there is an increase of PALS (T-cell site response) and/or GC (B-cell site response). It is known that some lines of chickens exhibit differences in B-cell distribution in the spleen after Marek disease virus challenge. Marek's susceptible line of chickens present higher number of B cells after infection than the resistant lines which have more T lymphocytes, but in general, spleen response can vary according to the type of antigenic stimulus or injury (Tizard, 1979; Olah & Glick, 1982; Riddel, 1987). Based on this approach, spleen-immune response microscopic evaluation on 4th day-after-challenge indicates the occurrence of a different pattern of response for SPF and commercial broilers submitted to the same vaccination schedule. In spite of the fact that SPF experimental chickens submitted to the distinct schedules of vaccination did not show any differences in antibody titers before challenge (Table 4), higher spleen-immune response was found respectively in A3 (4-10 day) and A2 (1, 7, 14 day) experimental groups as compared to A1 (1, 7 day) at 4th dpc. The increased rate of splenic immune reaction in SPF vaccinated birds in the following period after challenge (Figure 3) can be related to occurrence

of an early bursal tissue injury and further restoration and/or slight variation in antibody response. Commercial broiler chickens from B3 experimental group presented best spleen immune response at the 4th day-post-challenge when compared to B1, B2 and B4 experimental groups, and was similar to that found in A2 SPF experimental chickens. Differences in spleen white pulp response found in commercial broiler chickens could be related to passive immunity influence on the vaccinal virus replication. Otherwise, low spleen immune response found in birds vaccinated at 1 and 7 days of age (A1 and B1), seems to be related to early vaccination and the low rate of antigen trapping by PAS. Vervelde & Davidson (1997) described that a low number of cells with IBD-VP2 is seen in immature spleens of newly hatched chickens when compared to the 21 day-old infected birds but in neonate birds, low and delayed increase of VP2 positive cells persisted for 10 to 14 dpc while it occurred for 5 to 10 dpc in older chickens. The absence of spleen immune response in both groups of experimental birds vaccinated at 1 and 7 days of age can be related to the 18 day-interval-

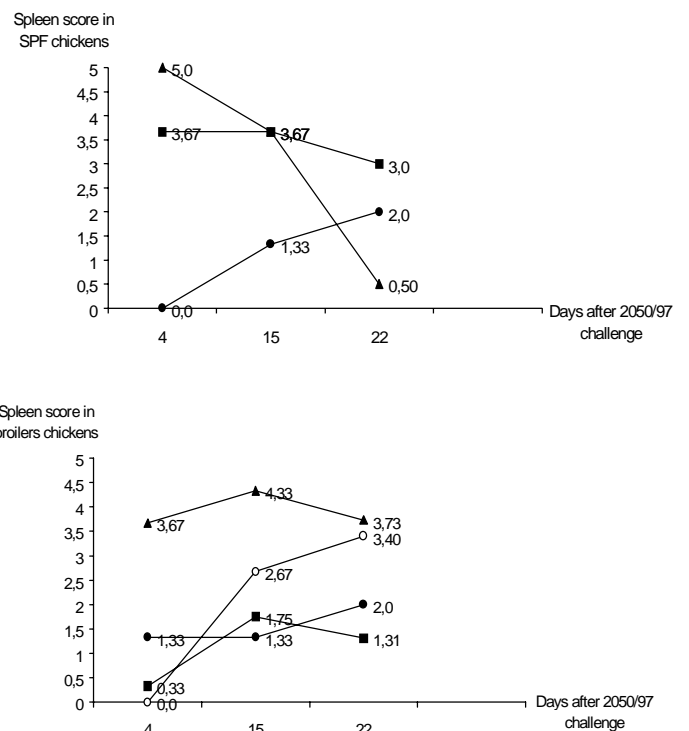
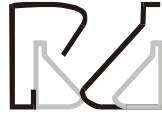

Figure 3 - Spleen immune response microscopic score in BV8-vaccinated and non-vaccinated birds after 2050/97 challenge in chickens. ● = vaccinated at 1 and 7 day; ■ = vaccinated at 1,7 and 14 days; ▲ = vaccinated at 4 and 10 day; ○ = non-vaccinated commercial broilers.



time from last vaccine stimulus and spleen analysis. According to Riddel (1987), GC are seen in the chicken spleen 6 days after the primary injection of an antigen. The number of GC peaks at 8 days post injection and then decreases. Following a secondary injection of an antigen, there is a temporary decrease in number of GC followed by an increase in number by 4 days and a peak at 6 days post-injection. So, the 15th and 22th dpc splenic response could be related to clearance of VP2-spleen positive cells in well sensitized birds (A3 group) or persistence of continuous trapping of VP2-spleen positive cells after challenge. According to Vervelde & Davidson (1997) the entrance of VP2 positive cells in the PAS doesn't mean local virus replication. Thus, the absence of IBDV-type lesion in SPF vaccinated chickens is expected if we consider a good rate of protection for bursal damage. Otherwise in broiler chickens which did not present significant increase of antibody titers before challenge, IBDV type response compatible with antigen presentation and CG hyperplasy were present resulting in increase of antibody titers. Increase of spleen response and antibody titers can be related to good immune sensitization due to vaccination.

CONCLUSION

Field 2050/97 sample was characterized as a highly virulent strain of IBDV with ability to cause 100% of mortality of SPF Leghorn type of chickens, but unable to induce high mortality of experimentally infected commercial broiler chickens as was found in the field case. This strain of IBDV doesn't cause high embryo mortality when inoculated by CAM route in chicken embryos. The inoculation of a constant virus suspension with known potency to cause mortality of SPF chickens is useful to study host responses of vaccinated chickens and commercial broiler chickens with passive immunity. Vaccination schedules based on the administration of BV8 intermediate vaccine strain in SPF leghorn chickens induced antibody response and full protection for 2050/97 v.v. IBDV induced mortality and bursal tissue damage. BV8 vaccine administration in commercial broilers with passive immunity did not induce increase in antibody titers, but gave protection against extensive bursal damage and death. Vaccination schedule, passive immunity, time of challenge and spleen IBD-type lesion or immune response should be considered to interpret the rate of protection or restoration of bursal tissue. Evaluation of IBDV early-induced bursal lesions, bursal restoration and spleen responses are useful to estimate vaccination efficacy and field interactions.

REFERENCES

- Adair BM. Virus-induced immunosuppression, chapter 14 In Poultry Immunology edited by Davidson TF, Morris TR & Payne LN, Carfax Publishing Company, 1996, 301-315.
- Bolis DA, Paganini FJ, Leffer EVB, Zuanaze MAF, Scanavini Neto H, Correa ARA, Ito NMK. Doença de Gumboro: avaliação das respostas sorológicas e anatomopatológicas observadas em frangos de corte vacinados e não desafiados com vírus muito virulento. *Brazilian Journal of Poultry Science* 2003; 5(2):137-146.
- Cheville NF. Studies on the pathogenesis of Gumboro disease in the bursa of Fabricius, spleen and thymus of the chicken. *American Journal Pathology* 1967; 51:527.
- Di Fabio J, Rossini LI, Eterradosi N, Toquin MD, Gardin Y. European-like infectious bursal disease viruses in Brasil, *Veterinary Record* 1999a; 145(7):203-204.
- Di Fabio J, Castro AG, Gardin Y, Rossini LI, Toquin D, Eterradosi N.. Very virulent IBD spreads to South America. *World Poultry* 1999a; 15(9):88-91.
- Getty R. Sisson/Grossman-anatomia dos animais domésticos, 5ª edição, volume 2, Editora Inter-Americana, 1981.
- Hoque MM, Omar AR, Chong LK, Hair-Bejo M, Aini I. Pathogenicity of Sspl-positive infectious bursal disease virus and molecular characterization of the VP2 hypervariable region. *Avian Pathology* 2001; 30:369-380.
- Ikuta N, Fonseca ASK, Lunge VR, Garcia M, Marques EK, Villegas P. Estudo da composição antigênica de variantes do vírus da doença de Gumboro (IBDV), In Conferência Apinco 1998 de Ciência e Tecnologia Avícola, Trabalho de Pesquisa, pp. 48.
- Ikuta N, El-Atrache J, Villegas P, Garcia M Lunge VR, Fonseca AS, Oliveira C, Marques EK. Molecular Characterization of Brazilian infectious bursal disease virus. *Avian Diseases* 2001; 45(2):297-306.
- Ito NMK, Yochida LT, Silva EM, Jorge MA. Doença de Gumboro: um problema ainda sem definição. *Anais do 7º Congresso Brasileiro de Avicultura*, volume II, 4 a 8 de outubro de 1981, Recife, Pernambuco pp 260-264.
- Ito NMK, Noronha AMB, Dagli MLZ, Gaviolle MC, Rossini LI, Matsuguma LK. Infectious Bursal Disease: a case report. *Brazilian Journal Veterinary Research Animal Science* 1990; 27(1):99-110.
- Ito NMK, Miyaji CI, Candal ACR Estudo comparativo do vírus da doença de Gumboro em diferentes sistemas experimentais. In *Anais da Conferência APINCO*, 1992, Santos, SP. pp. 252(a).
- Ito NMK, Miyaji CI, Lima EA. Síndrome da ave pálada: vírus isolado de pâncreas é semelhante ao vírus da doença de Gumboro. In *Anais da Conferência APINCO*, 1992, p. 254 (b).
- Knoblich HV, Sommer SE, Jackwood DJ. Antibody titers of Infectious Bursal Disease Virus in broiler chicks after vaccination at one day of age with infectious bursal disease virus and Marek's disease virus. *Avian Diseases* 2000; 44:874-884.



- Lasher HN, Shane SM. Infectious bursal disease. *World's Poultry Science Journal* 1994; 50:133-166.
- Lukert PD, Saif YM. Infectious Bursal Disease. In *Diseases of Poultry*, 10th Edition, Edited by Calnek BW *et al.*, Iowa State, University Press, 1997, pp. 721-738.
- Lunge VR, Fonseca ASK, Verdi Filho R, Oliveira C, Chiaramonte V, Ikuta N. Caracterização de genótipos de campo do vírus da doença de Gumboro (IBDV) no Brasil. In *Conferência APINCO de Ciência e Tecnologia Avícolas-Trabalhos de pesquisa*, pp 46. 1997.
- Maas RA, Venema S, Oei HL, Pol JMA, Claassen IJTM, ter Huurne AAHM. Efficacy of inactivated infectious bursal disease (IBD) vaccines: comparison of serology with protection of progeny chickens against IBD virus strains of varying virulence. *Avian Pathology* 2001; 30:345-354.
- McFerran JB Infectious Bursal Disease. In *Virus Infections of Birds*, edited by McFerran JB, McNulty, MS. Elsevier Science Publishers B.V, pp. 213-228, 1993.
- Nakano M, Portugal MASC, Saliba AM, Nobre D, Narimatsu MN. Ocorrência da "Doença de Gumboro" no Brasil. *Diagnóstico anátomo-patológico*, *Biológico* 1972; 38:60-61.
- Nielsen OI, Sørensen P, Hedemand JE, Laursen SB, Jørgensen PH. Inflammatory response of different chickens lines and B haplotypes to infection with infectious bursal disease virus. *Avian Pathology* 1998; 27(2):181-189.
- Oláh I, Glick B. Splenic white pulp and associated vascular channels in chicken spleen. *The American Journal of Anatomy* 1982; 165: 445-448.
- Poonia B, Charan S. T-cell suppression by cyclosporin-A enhances infectious bursal disease virus infection in experimentally infected chickens. *Avian Pathology* 2001; 30(4):311-319.
- Randall CJ, Reece RL. *Colour Atlas of Avian histopathology*, Mosby-Wolfe, 1996.
- Rattcliffe MJH, Paramithiotis E, Coumidis A, Sayegh C, Demaries S, Martinez O, Jacobsen KA. The bursa of Fabricius and its role in avian B lymphocyte development, chapter 2 In *Poultry Immunology* edited by Davidson TF, Morris TR & Payne LN, Carfax Publishing Company, 1996, pp 11-29.
- Riddel C. *Avian Histopathology published by American Association of Avian Pathologists*, 1987.
- Saukas TN. Caracterização de amostra do vírus da doença infecciosa bursal (doença de Gumboro) isolada no Brasil - Dissertação de mestrado pela Universidade Rural do Rio de Janeiro, 1978. 88pp.
- Sharma JM, Dohms JE, Metz AL. Comparative pathogenesis of serotype 1 and variant serotype 1 isolates of infectious bursal disease virus and their effect on humoral and cellular immune competence of specific-pathogen-free chickens. *Avian Diseases* 1989; 33:12 – 124.
- Sambrook J, Fritsch EF, Maniatis T. *Molecular Cloning: A laboratory Manual-2nd Ed.*, Cold Spring Harbor, Cold Spring Harbor Laboratory, 1989.
- Sanguinetti CJ, Dias-Neto E, Simpson AJG. Rapid silver staining and recovery of PCR products separated on polyacrylamide gels. *Biotechniques* 1994; 17:915-919.
- Simon VA, Ishizuka MM Doença Infecciosa da Bolsa de Fabricius-DIB, In *Doenças das Aves*, edited by Berchieri AJ & Macari M, FACTA, pp. 351, 2000.
- Tizard I. Avian Immune responses: a brief review. *Avian Diseases* 1979; 23(2):290-298.
- Van der Berg TP, Gonze M, Meulemans G. Acute infectious bursal disease in poultry: isolation and characterization of a highly virulent strain. *Avian Pathology* 1991; 20:133-143.
- Van der Berg TP, Meulemans G. Acute infectious bursal disease in poultry: protection afforded by maternally deviated antibodies and interference with live vaccination. *Avian Pathology* 1991; 20:409-421.
- Vervelde L, Davidson TF. Comparison of the in situ changes in lymphoid cells during infection with infectious bursal disease virus in chickens of different ages. *Avian Pathology* 1997; 26:803-821.
- Yamaguchi T, Kondo T, Inishima Y, Ogawa M, Miyoshi M, Yanai T, Masegi T, Fukushi H, Hirai K. In vitro attenuation of highly virulent infectious bursal disease virus. Some characteristics of attenuated strains. *Avian Diseases* 1996; 40:501-509.
- Witt JJ, Heijmans JF, Mekkes DR, van Loon AAWM. Validation of five commercially available ELISAs for the detection of antibodies against infectious bursal disease virus (serotype 1). *Avian Pathology* 2001; 30:543-549.