



## Effect of Broiler Breeder Age and Glutamine Supplementation on the Development of the Intestinal Mucosa of 7-Day-Old Chicks

### ■ Author(s)

Maiorka A<sup>I</sup>  
Silva AVF<sup>I</sup>  
Santin E<sup>I</sup>  
Dahlke F<sup>I</sup>  
Bruno LDG<sup>II</sup>  
Boleli IC<sup>III</sup>  
Macari M<sup>III</sup>  
Trautenmuller H<sup>II</sup>

<sup>I</sup> Universidade Federal do Paraná – CEP 80035-050 Curitiba – PR – Brasil

<sup>II</sup> Universidade Estadual do Oeste do Paraná – CCA – CEP 85960-000 – Marechal Cândido Rondon – PR – Brasil

<sup>III</sup> Faculdade de Ciências Agrárias e Veterinárias – Unesp – CEP 14884-900 – Jaboticabal – SP – Brasil

### ■ Mail Address

Corresponding author e-mail address  
Alex Maiorka  
Universidade Federal do Paraná/Setor de Ciências Agrárias  
Departamento de Zootecnia  
Rua dos Funcionários, 1540  
CEP 80035-050 Curitiba PR  
Phone: +55 41 33505732  
Fax: +55 41 3252 4149  
E-mail: [amaiorka@ufpr.br](mailto:amaiorka@ufpr.br)

### ■ Keywords

Broiler breeder age, glutamine, intestinal mucosa, morphology.

### ABSTRACT

The aim of this study was to evaluate the possible effects of glutamine and broiler breeder age on the development of intestinal mucosa in broiler chicks during first week of age. For this purpose, 32 one-day-old broiler chicks were distributed according to a completely randomized experimental design in a 2 x 2 factorial arrangement. Treatments consisted of two broiler breeder ages (30 and 60 weeks) and two dietary glutamine supplementation levels (0% and 1%). The morphological development of intestinal mucosa, particularly villus height and crypt depth, was evaluated. The results showed that the supplementation with 1% of glutamine influenced the development of villus height in the duodenum ( $p=0.009$ ), jejunum ( $p = 0.006$ ), and ileum ( $p = 0.001$ ), as well as crypt depth in the jejunum ( $p = 0.037$ ) of 7-day-old broilers. These results suggest that the presence of glutamine influenced the development of intestinal mucosa during the first week of age, when these tissues are highly influenced by dietary components, especially by trophic agents. The results show that broiler breeder age (30 or 60 weeks) did not influence the evaluated parameters.

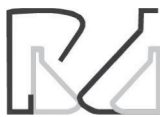### INTRODUCTION

Literature studies have demonstrated the importance of maintaining the health of the intestinal mucosa of poultry to achieve good productivity. This is especially true for broilers, which have a short lifespan. Very good intestinal health status is required because intestinal epithelium cells are responsible for nutrient absorption and for defense against pathogens (Maiorka *et al.*, 2000).

At hatching, despite anatomically complete, the gastrointestinal tract (GIT) is still physiologically immature (Maiorka *et al.*, 2000; Murakami *et al.*, 2007), resulting in inefficient dietary nutrient utilization, and consequently, preventing chicks to achieve their genetic growth potential.

Some compounds are supplemented in pre-starter and starter broiler diets with the aim to stimulate the development of the intestinal mucosa. One of these substances is glutamine, which is a trophic agent. It supplies optimal enterocyte nutrition and it is known for maintaining enterocyte development rate and, in some cases, for stimulating the proliferation of enterocytes after damages of the intestinal mucosa (Rhoads *et al.*, 1997). Well-developed and functional enterocytes are required for proper dietary nutrient absorption.

It was reported that glutamine increases gene transcription by increasing the mitogenic activity of the enzyme protein kinase (Blikslarger & Roberts, 1997), leading to more effective synthesis or turnover of the involved tissues. However, the mechanism by which glutamine stimulates the proliferation of enterocytes is not fully elucidated. Two



mechanisms have been proposed: glutamine may increase  $\text{Na}^+/\text{H}^+$  exchange on the cell membrane, as well as enhance the specific activity of the enzyme ornithine-decarboxylase, essential for cell proliferation (Rhoads *et al.*, 1997). Moreover, glutamine is a precursor of the synthesis of amino acids, nucleotides, and nucleic acids (Souba, 1993; Murakami *et al.*, 2007). However, endogenous glutamine production is not sufficient to supply the body requirements (Lobley *et al.*, 2001). Therefore, the supply of an exogenous glutamine source may be useful to promote the development of the GIT, particularly of the intestinal mucosa.

There is positive correlation between broiler breeder age and egg size and, consequently, between broiler breeder age and chick size. Chicks from young broiler breeders are lighter when compared with chicks of the same age from older broiler breeders (Dalanezi *et al.*, 2005). This difference may be maintained during the entire broiler life. The study of Wilson (1991), for instance, showed that a difference of one gram in egg weight results in 2-13 gram differences in the body weight of 6-wk-old broilers. Eggs laid by young broiler breeders present lower yolk and albumen contents, and therefore lower nutrient levels available to the developing embryo (Noy & Pinchasov, 1993).

Therefore, the objective of this experiment was to evaluate the effects of the dietary supplementation of glutamine during the first week after hatching on the development of the intestinal mucosa (villus height, crypt depth, number of the villi/segment, surface area of the tip of the enterocytes and length of the small intestine) of broiler chicks derived from breeders of different ages (30 and 60 weeks old).

## MATERIAL AND METHODS

A total of 32 one-day-old male Cobb-500™ chicks (16 hatched from 30-wk-old breeders and 16 hatched from 60-wk-old breeders) were placed immediately after hatching in battery cages located in an environmentally controlled chamber at thermoneutral temperature (33°C). Chicks were distributed according to a completely randomized experimental design in a 2 x 2 factorial arrangement, consisting of two broiler breeder ages (30 and 60 weeks) and two dietary glutamine supplementation levels (0% and 1%), with four treatments of eight birds each. The following treatments were applied:

- T1: chicks from 30-wk-old breeders and fed a diet supplemented with 1% glutamine;
- T2: chicks from 60-wk-old breeders and fed a diet supplemented with 1% glutamine,

- T3: chicks from 30-wk-old breeders and fed a diet not supplemented with glutamine;
- T4: chicks from 60-wk-old breeders and fed a diet not supplemented with glutamine.

The diets were based on corn and soybean meal. Diet composition is shown in Table 1. Glutamine was supplemented at 1% of the diet as L-glutamine. Chicks are fed *ad libitum* during the entire experimental period (7 days).

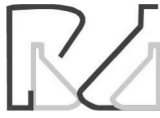At the end of the experimental period or seven days after hatching, eight birds per treatment were sacrificed by cervical dislocation. The small intestine was removed for morphological evaluation and its length measured ( $\text{cm} \pm 0.01$ ). Tissue samples (approximately 2 cm) were collected from each segment of the small intestine: duodenum - from the pylorus to the distal duodenal loop; jejunum - from the distal duodenal loop to Meckel's diverticulum, and ileum - between Meckel's diverticulum and the opening of the ceca. Samples were evaluated by light microscopy, scanning electron microscopy, and transmission electron microscopy.

**Table 1** – Composition of experimental diets.

Ingredient	Experimental diets	
	With Glutamine	Without Glutamine
Yellow corn, %	51.74	51.74
Soybean meal, %	27.82	27.82
Corn gluten-60, %*	9.94	9.94
Soybean oil, %	1.59	1.59
Dicalcium phosphate, %	1.71	1.71
Limestone, %	1.44	1.44
Vitamin supplement <sup>A</sup> , %	0.45	0.45
Trace mineral supplement <sup>B</sup> , %	0.25	0.25
Salt (NaCl), %	0.45	0.45
DL-Methionine, %	0.13	0.13
L-Lysine, %	0.12	0.12
L-Glutamine, %**	1.00	0.00
Sand, %	3.41	4.41
	Calculated analysis	
ME, kcal/kg	2,900	2,900
Crude protein, %	23.00	22.00
Calcium, %	1.00	1.00
Available phosphorus, %	0.45	0.45
Sodium, %	0.20	0.20
Methionine, %	0.51	0.51
Methionine + Cystine, %	0.88	0.88
Lysine (%)***	1.10	1.10

<sup>A</sup> Supplied per kilogram of diet: vitamin A (11,925 IU); vitamin D<sub>3</sub> (2,250 IU); vitamin E (9 IU); vitamin K<sub>3</sub> (1.8 mg); vitamin B<sub>12</sub> (0.02 mg); thiamin (1.1 mg); riboflavin (9 mg); pyridoxine (1.8 mg); biotin (0.1 mg); pantothenic acid (9.9 mg); niacin (38.25 mg); folic acid (0.9 mg); choline (680 mg).

<sup>B</sup> Supplied per kilogram of diet: iodine (1.2 mg); selenium (0.18 mg); iron (70 mg); copper (10 mg); zinc (60 mg); manganese (70 mg).



### Light microscopy

Tissue samples were fixed in Bouin's solution, dehydrated in standard alcohol-toluene series (50, 60, 70, 80, 90, and 100% for 15 minutes each), and embedded in paraffin. Five-micrometer slices were prepared and stained with hematoxylin-eosin. Villus height ( $\mu\text{m}$ ) and crypt depth ( $\mu\text{m}$ ) were measured in 60 random microscopic fields in each segment using an image analysis system (Video Plan, Carl Zeiss, Germany).

### Sample preparation for electron microscopy

The intestinal content was removed with saline solution buffered with 0.1 M phosphate (pH 7.4), and tissue samples were fixed in 2% glutaraldehyde in phosphate buffer for 24 h at 4° C. Subsequently, samples were washed in phosphate buffer and post-fixed for two hours in 1% osmium tetroxide. The material was washed again with the same buffer solution and dehydrated in increasing ethanol series (50, 60, 70, 80, 90, and 100% for 15 minutes each).

### Scanning electron microscopy

Samples were dried in a critical point drier with liquid carbon dioxide. The material was then placed in an appropriate specimen tray, covered with a layer of gold (30 nm), and observed under a scanning electron microscope (model JSM 25SI<sup>®</sup>, Jeol Ltd, Japan). The average number of villi/segment was obtained by counting the number of villi in six areas measuring 103,269  $\mu\text{m}^2$  each.

### Transmission electron microscopy

Segments of approximately 1 mm<sup>2</sup> were infiltrated with 1:1 ethanol-Epon 812 resin at room temperature for 2 hours and embedded in Epon 812 resin at 60° C for 72 hours. The samples were then sectioned, contrasted with lead citrate and uranyl acetate and electron-microphotographed by transmission electron microscopy.

Longitudinal sections of the cells were evaluated using an image analyzer (Jeol 1010<sup>®</sup>, Japan) in order to measure enterocyte diameter (tip,  $\mu\text{m}$ ), microvillus height and width ( $\mu\text{m}$ ), and microvillus density (microvillus number/ $1\mu^2\text{m}$ ). The average of each measurement corresponds to the measurements of 10 samples per bird.

The surface area of the tip of the enterocytes was calculated based on the tip diameter ( $C_d$ ) of the cell and the extension factor of the microvillus (EFM),

according (Ferrer *et al.*, 1995), using the equation:  $S = \pi \times C_d^{2/4} \times \text{EFM}$ , where  $\text{EFM} = \pi \times H \times d \times D + 1$  (L = microvillus height; d = microvillus width and D = microvillus number/ $\mu\text{m}^2$ ).

### Statistical Analysis

Data were analyzed according to a completely randomized experimental design adopted in a 2 x 2 factorial arrangement (broiler breeder age x glutamine supplementation) with eight replicates per treatment, using the General Linear Model procedure of SAS 8.0 software (2000).

## RESULTS AND DISCUSSION

Applegate *et al.* (1999) reported the influence of breeder age on the intestinal development of their progeny in turkeys. Turkey poults from older breeders presented higher villi than those from younger breeder after hatch, but this difference was not maintained when poults were one week old. Accordingly, in the present study, no differences in the morphology of the intestinal mucosa of 7-d-old broilers derived from broiler breeders of different ages were detected. This suggests that the diet supplied immediately after hatch may minimize the influence of broiler breeder on the initial development of the intestinal mucosa. Applegate *et al.* (1999) demonstrated that animal metabolism has the ability to shown a rapid response when stimulated.

Table 2 shows the results of the supplementation of diets with 1% glutamine on the morphology of the intestinal mucosa of 7-d-old broiler chicks. The chicks fed diets with 1% glutamine presented taller longer villi in the duodenum ( $p = 0.009$ ), jejunum ( $p = 0.006$ ), and ileum ( $p = 0.001$ ) compared with those fed the non-supplemented diet. In addition, glutamine-fed chicks presented deeper crypts in the jejunum ( $p = 0.037$ ), while no statistical differences were detected in the duodenum and the ileum. Table 2 also shows that broiler breeder age (30 or 60 weeks) did not influence the evaluated parameters.

Therefore, the addition of glutamine to the diet influenced villus height in the duodenum, jejunum and ileum, but not crypt depth. This suggests that the glutamine, despite being a trophic agent, did not affect the number of villi, because these originate from the bottom of the crypt.

Glutamine is known as a trophic agent that stimulates the development and proliferation of developing and regenerating tissues. Because the



**Table 2** – Villus height and crypt depth ( $\mu\text{m}$ ) in the duodenum, jejunum and ileum of 7-d-old broiler chicks.

Broiler breeder age (weeks)	Glutamine supplementation	Duodenum ( $\mu\text{m}$ )		Jejunum ( $\mu\text{m}$ )		Ileum ( $\mu\text{m}$ )	
		Villus	Crypt	Villus	Crypt	Villus	Crypt
30	(+)	1131 $\pm$ 39	170 $\pm$ 26	595 $\pm$ 70	96 $\pm$ 26	505 $\pm$ 31	91 $\pm$ 12
30	(-)	1076 $\pm$ 28	168 $\pm$ 34	535 $\pm$ 87	85 $\pm$ 20	450 $\pm$ 42	92 $\pm$ 13
60	(+)	1119 $\pm$ 57	171 $\pm$ 28	598 $\pm$ 71	96 $\pm$ 24	508 $\pm$ 30	89 $\pm$ 14
60	(-)	1103 $\pm$ 71	165 $\pm$ 36	531 $\pm$ 85	85 $\pm$ 19	449 $\pm$ 36	90 $\pm$ 13
Main effects							
Broiler breeder age (weeks)	30	1104	168	566	90	476	90
	60	1111	169	565	91	479	90
Glutamine	(+)	1125	170	597	95	506	91
	(-)	1090	167	534	85	449	90
Probability							
Broiler breeder age (A)		0.573	0.852	0.966	0.952	0.869	0.518
Glutamine (B)		0.009	0.644	0.006	0.037	0.001	0.892
AxB		0.127	0.756	0.841	0.920	0.830	0.957

gastrointestinal tract (GIT) the main absorption site of dietary nutrients required for metabolic functions, adequate GIT development is required (Maiorka, 2002), particularly during the first week of broilers' lives (Uni *et al.* 1998a; Maiorka, 2002), when most of the intestinal mucosa development occurs.

The effects of glutamine and broiler breeder age on microvillus height are presented on Table 3. The three segments showed different responses to the treatments. The segment where microvilli tended to be more influenced both by broiler breeder age and glutamine supplementation was the duodenum ( $P = 0.262$  and  $0.162$ , respectively), while the jejunum ( $P = 0.123$  and  $0.739$ ) and the ileum ( $P = 0.561$  and  $0.115$ ) tended to be less affected. Because duodenal villus height was more sensitive to the action of glutamine, duodenal microvillus height was also expected to be affected.

Small intestine length and surface area of the tip of enterocytes ( $\mu\text{m}^2$ ) results are shown in Table 4. The only parameter that tended to be affected by the dietary addition of 1% glutamine was small intestine

**Table 3** – Microvillus height ( $\mu\text{m}$ ) in the duodenum, jejunum, and ileum of 7-d-old broiler chicks.

Broiler breeder age (weeks)	Glutamine supplementation	Microvillus height		
		Duodenum ( $\mu\text{m}$ )	Jejunum ( $\mu\text{m}$ )	Ileum ( $\mu\text{m}$ )
30	(+)	2.41 $\pm$ 0.61	2.27 $\pm$ 0.41	2.28 $\pm$ 0.53
30	(-)	2.00 $\pm$ 0.25	1.96 $\pm$ 0.19	1.96 $\pm$ 0.52
60	(+)	2.26 $\pm$ 0.31	2.25 $\pm$ 0.46	2.12 $\pm$ 0.37
60	(-)	1.79 $\pm$ 0.51	2.46 $\pm$ 0.41	1.95 $\pm$ 0.20
Principal effects				
Broiler breeder age (weeks)	30	2.21	2.12	2.13
	60	2.02	2.36	2.04
Glutamine	(+)	2.34	2.26	2.21
	(-)	1.89	2.21	1.96
Probability				
Broiler breeder age (A)		0.262	0.123	0.561
Glutamine (B)		0.162	0.739	0.115
AxB		0.858	0.101	0.612

length ( $p = 0.068$ ). The surface area of the tips of the duodenum, jejunum, and ileum was not influenced by dietary glutamine supplementation or broiler breeder age.

**Table 4** – Small intestinal length (cm) and surface area of the tip of the enterocytes ( $\mu\text{m}^2$ ) of the duodenum, jejunum, and ileum of 7-d-old broiler chicks.

Broiler breeder age (weeks)	Glutamine supplementation	Intestine (cm)	Duodenum ( $\mu\text{m}^2$ )	Jejunum ( $\mu\text{m}^2$ )	Ileum ( $\mu\text{m}^2$ )
30	(-)	71 $\pm$ 11	715 $\pm$ 136	592 $\pm$ 101	523 $\pm$ 125
60	(+)	74 $\pm$ 5	748 $\pm$ 142	596 $\pm$ 137	553 $\pm$ 77
60	(-)	73 $\pm$ 10	719 $\pm$ 144	597 $\pm$ 85	516 $\pm$ 93
Principal effects					
Broiler breeder age (weeks)	30	74	711	580	526
	60	74	733	596	534
Glutamine	(+)	76	727	582	542
	(-)	72	717	594	519
Probability					
Broiler breeder age (A)		0.962	0.652	0.783	0.691
Glutamine (B)		0.068	0.798	0.836	0.431
AxB		0.208	0.361	0.562	0.415



Table 5 shows the number of villi/segment determined in the duodenum, jejunum, and ileum of 7-d-old broiler chicks. The number of villi/segment ( $103.269 \mu\text{m}^2$ ) were not influenced by dietary glutamine addition or broiler breeder age.

**Table 5** – Number of the villi/segment ( $103.269 \mu\text{m}^2$ ), in the duodenum, jejunum and ileum on broiler chicks with 7 days of age.

Broiler breeder age (weeks)	Glut	Villi/segment		
		Duodenum	Jejunum	Ileum
30	(+)	80±12	122±23	190±17
30	(-)	78±14	128±25	194±14
60	(+)	77±12	120±20	188±8
60	(-)	83±10	123±30	191±16
Main effects				
Broiler breeder age (weeks)	30	79	125	192
60	80	121	189	
Glutamine	(+)	78	121	188
(-)	81	125	192	
Probability				
Broiler breeder age (A)		0.533	0.594	0.596
Glutamine (B)		0.912	0.511	0.470
AxB		0.835	0.730	0.914

The results shown in Tables 3, 4, and 5 suggest that some parameters (surface of the tip of the enterocytes and number of villi/segment) presented very low susceptibility to the factors evaluated in this experiment.

Figure 1 shows some villi of the duodenum, jejunum, and ileum of broiler chickens fed diets with and without glutamine. The villi of in the evaluated segments are clearly more developed in the broilers fed glutamine compared with those fed the basal diet.

Literature reports (Lacey & Wilmore, 1990; Murakami *et al.*, 2007) have shown that glutamine is the most important nutrient for the development of enterocytes and has positive effects on the regeneration of intestinal mucosa after damage. Two mechanisms have been proposed for these actions: glutamine may increase  $\text{Na}^+/\text{H}^+$  exchange on the cell membrane, as well as enhance the specific activity of the enzyme ornithine-decarboxylase (Rhoads *et al.*, 1997). That author also described an increase of gene transcription by glutamine probably due to an increase of protein kinase activity. In addition, the supplementation of broiler diets with glutamine increases the villus height in the duodenum and jejunum (Yi *et al.*, 2005), weight gain, feed efficiency, and livability (Applegate *et al.*, 1999). Therefore, the supplementation of glutamine in broiler diets as early as possible enhances intestinal mucosa development.

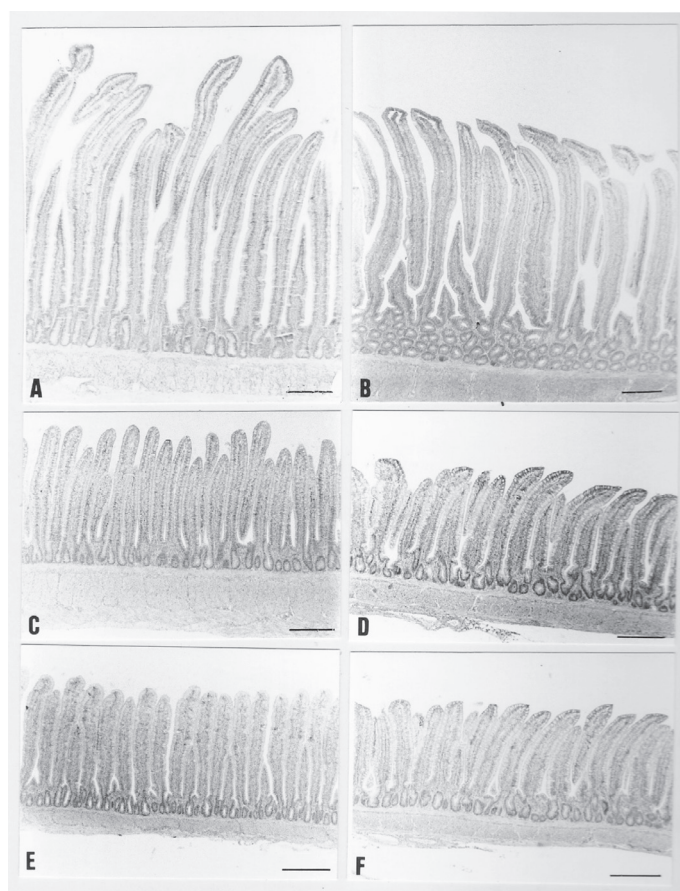


Figure 1 – Microphotographs of intestinal mucosa villi of 7-d-old broiler chicks. Duodenum of chicks fed 1% of glutamine (A) and no glutamine (B); jejunum of chicks fed 1% of glutamine (C) and no glutamine (D), ileum of chicks fed 1% of glutamine (E) and no glutamine (F).

## CONCLUSIONS

The dietary supplementation of 1% glutamine influenced villus development in the intestinal mucosa of 7-day-old broiler chicks. In particular, glutamine effectively increased villus height in all segments of the small intestine and crypt depth in the jejunum. However, broiler breeder age did not influence the evaluated parameters.

## REFERENCES

- Applegate TJ, Dibner JJ, Kitchell ML, Uni Z, Lilburn MS. Effect of turkey (*Meleagris gallopavo*) breeder hen age and egg size on poult development. 2. Intestinal villus growth, enterocyte migration and proliferation of the turkey poult. *Comparative Biochemistry and Physiology* 1999;124B:381-389.
- Blikslarger AT, Roberts C. Mechanisms of intestinal mucosal repair. *JAVMA* 1997;211:1437-1441.
- Dalanezi JA, Mendes AA, Garcia EA, Garcia RG, Moreira J, Paz ICLA. Efeito da idade da matriz sobre o desempenho e rendimento de carcaça de frangos de corte. *Arquivos Brasileiros de Medicina Veterinária e Zootecnia* 2005;57(2):250-260.



- Ferrer R, Planas JM, Moretó M. Cell apical surface area in enterocytes from chicken small and large intestine during development. *Poultry Science* 1995;74:1995-2002.
- Lacey JM, Wilmore DW. Is glutamine a conditionally essential amino acid. *Nutrition Research* 1990;48:297-309.
- Lobley GE, Hoskin SO, McNei, CJ. Glutamine in animal science and production. *Proceedings of the International Symposium of Glutamine* 2001;2525S-2531S.
- Maiorka A. Efeito da idade da matriz, do jejum, da energia da ração e da glutamina sobre o desenvolvimento da mucosa intestinal e atividade enzimática do pâncreas de pintos de corte [tese]. Jaboticabal (SP): Universidade Estadual Paulista; 2002.
- Maiorka A, Fischer da Silva AV, Santin E, Borges AS, Boleli IC, Macari M. Influência da suplementação de glutamina sobre o desempenho e o desenvolvimento de vilos e criptas do intestino delgado de frangos. *Arquivos Brasileiros de Medicina Veterinária e Zootecnia* 2000;52:487-490.
- Maiorka A, Santin E, Fischer da Silva AV, Bruno LDG, Boleli IC, Macari M. Influence of broiler breeder age (30 and 60 weeks) on embryonic gastrointestinal development. *Brazilian Journal of Poultry Science* 2000;2(2):141-148.
- Murakami AE, Sakamoto MI, Natali MRM, Souza LMG, Franco JRG. Supplementation of glutamine and vitamin E on the morphometry of the intestinal mucosa in broiler chickens. *Poultry Science* 2007;86:488-495.
- Noy Y, Pinchasov Y. Effect of a single posthatch intubation of nutrients on subsequent early performance of broiler chicks and turkey poults. *Poultry Science* 1993;72:1861-1866.
- Rhoads JM, Argenzio RA, Chen W. L-glutamine stimulates intestinal cell proliferation and activates mitogen-activated protein kinases. *American Journal of Physiology* 1997;272:G943-G953.
- SAS Institute. SAS<sup>®</sup> user's guide: statistics. Cary; 2000.
- Souba WW. Intestinal glutamine metabolism and nutrition. *The Journal of Nutritional Biochemistry* 1993;4:2-9
- Wilson HR. Interrelations of egg size, chick size, posthatching growth and hatchability. *World's Poultry Science Journal* 1991;47:5-20.
- Yi GF, Allee GL, Knight CD, Dibner JJ. Impact of glutamine and omeprazole supplement on growth performance, small intestinal morphology, and immune response of broilers vaccinated and challenged with *Eimeria maxima*. *Poultry Science* 2005;84:283-293.