



Biochemical Parameters and Histopathological Findings in the Forced Molt Laying Hens

■ Author(s)

Mert Nⁱ
Yildirim BAⁱⁱ

ⁱ Department of Biochemistry, Faculty of Veterinary Medicine, University of Yuzuncu Yil, 65080, Van, Turkey

ⁱⁱ Department of Biochemistry, Faculty of Veterinary Medicine, University of Ataturk, 25200, ERZURUM, Turkey

■ Mail Address

Corresponding author e-mail address
Betul Apaydin Yildirim
Department of Biochemistry, Faculty of Veterinary Medicine, University of Ataturk, 25200, ERZURUM-TURKEY
Tel: +90 535 2729293
Email: betul_apaydin@hotmail.com

■ Keywords

Antioxidant, lipid peroxidation, molting, ovary, thyroid.

ABSTRACT

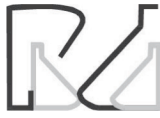The aim of this study was to evaluate the effects of forced molting using biochemical parameters and histopathological findings in laying hens. 36 Hyline W36 strain laying hens, 90 weeks old were chosen for this research. Eight of these chickens were randomly selected and placed in a cage as the control group before the molting program began. All the others 28 chickens were used for the forced molting program. Eight laying hens were slaughtered at the end of the molting program named as molting group. The remaining 20 hens were fed for 37 days, weighted and slaughtered when they reached the maximum egg production (80%) as postmolting group. Then, blood was analyzed for malondialdehyde, glutathione, catalase, glucose, calcium, phosphorus, albumin, globulin, total protein, triiodothyronine, thyroxine and Vitamin C. The malondialdehyde and glutathione levels of the thyroid and liver tissues were also analyzed along with an examination of the histopathological changes of the liver, ovary and thyroid glands; and live body, liver, ovary, thyroid weights and thyroid lengths. In conclusion, it was found that forced molting produces stress and notable side effects in hens, like the oxidant and antioxidant status of the organs, tissue weights and sizes, hormone profiles, blood biochemical and histopathological parameter changes. The activities of thyroid malondialdehyde ($p < 0.05$), liver glutathione ($p < 0.01$), plasma catalase ($p < 0.001$) were significantly decreased in molting group compared to control values, while liver malondialdehyde levels were significantly increased ($p < 0.001$) and thyroid glutathione levels had nonsignificant effect. These levels in molting hens were the first study for veterinary science.

INTRODUCTION

Molting is a natural process that occurs in all adult birds for renewing feathers, resulting in weight loss, regression of the reproductive organs and cutting of egg production (Park *et al.* 2004).

Forced molting is a procedure that when egg production falls below economical levels, hens are forced to stop laying eggs and molt using environmental modifications. This application causes some physiological changes and resting of the reproductive organs. At the end of molting, egg production returns close to its former level (Brake *et al.* 1984; Gildersleeve *et al.* 1982). During molting, the reproductive system of birds undergoes complete remodeling regression and regeneration (Sundaresan *et al.* 2006).

Molting and renewal of feathers is a physiological event seen in all birds. In some animals molting can be seen twice a year or once in two years. Without artificial intervention, chickens can take up to 4 months to molt and usually egg production can be stopped at this time (Özen, 1986).



Free radicals are responsible for the irreversible damage of membrane lipids and proteins. In protein metabolism sulfhydryl groups the focus is on the effect of free radicals and changes to the S-S band formation. Reactive oxygen species (ROS) can easily affect the membrane lipids and cause the formation of unsaturated aldehydes which are more resistant than free radicals, directly disturbing the structure of the cellular biomolecules and causing the modification of protein and other molecules, lipid peroxidation, erythrocyte hemolysis; and inhibition of protein synthesis (Halliwell & Gutteridge, 1985).

Glucose is the main sugar in the body and is used for energy production and formation of different substances using the carbohydrate metabolism in the body (Martin, 1981).

Calcium (Ca) and phosphorus (P), organic substances in an organism, were examined together in terms of nutrition and metabolism and are closely associated with each other (Mert, 1996; Kramer, 1980). Ca and P play an important role in the formation of the laying hens where Ca is the most abundant cation in the chicken's body. This amount is approximately 20 g and daily 10% of what the body stores is released for the formation of the egg shell (Hudson *et al.* 1971). Egg formation begins with ovulation and approximately 8 days later the ovum falls into the infundibulum in the form of a follicle, then finds its way to the uterus for calcification which takes 19 hours in the uterus. Ca comes from the intestine and is transferred to the egg shell region by blood and calcium binding protein (CaBP), which facilitates the transfer of Ca in the intestinal wall and uterus (Hudson *et al.* 1971; Gilbert, 1971; Guyer *et al.* 1980).

It is known that more than 20 proteins are found in serum and each one has a different function in the body. They have different physical and biochemical properties and serum proteins change in various physiological and pathological conditions. They fulfill numerous physiological functions like regulation of cellular transport, cellular activity, osmotic pressure, homeostasis, the immune system hormone; and enzymatic mechanisms (Beseoglu, 2002).

The thyroid follicular cells secrete triiodothyronine (T_3) and thyroxine (T_4) hormones; and in addition calcitonin is secreted from the parafollicular cells which is effective to the calcium metabolism. In general T_3 and T_4 hormones regulate the basal metabolism. Their binding to a receptor regulates protein production within the cell, accelerates oxidation in the mitochondria and controls the activity of the structure of the enzyme membrane (Tezelman & Siperstein, 1997).

Vitamins are necessary to maintain the normal metabolic events in the body and must be taken in small quantities in food and participate in the structure and functions of many many enzymes and hormones, which play an important role in the growth, development, reproductive, and immune systems because of their distinctive structures (Brown, 1997; Akkan, 1999).

The histological process of oviducal regression during the molting period and regeneration of reproductive organs has been examined. During the molting period a reduction in cell size of regression during atresia is accompanied by autolysis of follicular cells (Yoshimura & Tamura, 1985; Yoshimura *et al.*, 1989) and apoptosis (Johnson *et al.*, 1996).

The aim of this study was to evaluate the effects of forced molting using biochemical and histopathological parameters in laying hens.

MATERIAL AND METHODS

Animals

In this study, 90 week old Hyline W36 strain laying hens were chosen as research material from a Commercial Egg Production Farm (BAY-TAV), in Van, TURKEY. The experiments were conducted according to the ethical norms approved by the Ethic Committee of Experimental Animal Teaching and Researcher Center (No: 26.02.2009 2009-YYU-02). All hens were placed in cages of 40x80 cm and their feet numbered. Eight randomly selected hens were weighed, placed in a cage; and labeled as the control (C). The other 28 hens were weighted and placed in cages for the molting procedure. Eight days later; the hens were slaughtered and labeled as the food deprived group or molting (M). The remaining 20 hens were fed for 37 days, reached their maximum egg production, were weighed hormonal slaughtered and labeled as the post-molting group (PM).

Chemicals

All chemicals were purchased from Sigma Chemical Company (St. Louis, MO, USA).

Forced Molting Procedure

Except for the control group (C: control group), feed was not given to all animals in the first two days and a 24 hour light application was introduced. Their live weights were recorded, then they were given marble powder with their feed and 10 hours of light per day. Later for five days, 5 hours of light (10AM-3PM) was given to the animals without water. On the 8th day



of the molting program, when they had lost 25% of their live weight, we stopped giving them marble powder. These eight chickens that were starved, were slaughtered and blood and tissue samples were taken (M: molting group). The other 20 hens were feed respectively with cracked wheat from the first to the fourth days as 25-50-75-100 g/per hen. In the fifth day all hens were feed with chicken growing feed until reaching 5% of egg production or the 25th day of the molting program with 14 hours of light per day. Egg starting feed was begun and given to all the animals until the 36th day or when 50% of egg production was reached and in the meantime vitamins A, D, E, C and K were added to their water. Hens were fed with laying feed with 17 hours of light per day until they reached maximum egg production at the 45th day of the trails, then all hens (PM: post molting group) were slaughtered and blood and tissue samples were taken for biochemical analysis.

Biochemical Analysis

Blood samples were taken by head cutting, collected into heparinized tubes and immediately an MDA (Slater 1984; Sushil *et al.* 1989) and GSH (Beutler *et al.* 1963; Rizzi *et al.* 1988) analysis was done from all the blood. The remaining blood samples were centrifuged at 200 x g for 10 minutes, plasma was separated and kept in a deep-freezer until the analysis (-24°C). At the time of analysis the plasma was thawed and glucose, Ca, P, albumin, globulin, total protein, T₃ and T₄ analysis was done by an autoanalyzer (Roche, Abbott). Plasma vitamin C (Omaye *et al.* 1979) and CAT (Goth, 1991) analysis was also done with the appropriate techniques as cited. After slaughtering the hens, their livers and ovariums were weighed, and thyroid weight and thyroid length were recorded. The liver and thyroid tissue samples were analyzed for MDA (Xia, 1994; Marklund, 1990) and GSH (Ball, 1966; Fernandez & Videla, 1981).

Histopathological Analysis

The middle portion of the liver, ovarium and thyroid tissues were removed and immediately half of them were embedded into a 10% formalin solution for 48h. After dehydration in a graded ethanol series and clearing with xylene, the sample material was embedded in paraffin. Paraffin blocks were prepared and 5 µm-thin sections were sliced using microtome (LEICA RM2255), then the sections were stained with a Hematoxylin-Eosin (HXE) stain for observation under the light microscope and were examined and photographed using an Olympus BX51 light microscope.

Statistical Analysis

Statistical analysis was done by one-way analysis of variance (ANOVA) using SPSS software package, version 20.00. Post-hoc Tukey's test was used to compare the studied parameters between the groups, p values <0.05 were considered as significant.

RESULTS

The body, liver, ovarium, thyroid weight and thyroid length changes in the three groups are shown in Table 1.

Table 1 – The body weight, liver, ovarium, thyroid weight and thyroid length of hens in the control (C), molting (M) and post molting (PM) groups

Parameter	Control Group (C) (X±Sx) n=8	Molting Group (M)(X±Sx) n=8	Post Molting Group (PM)(X±Sx) n=20	p-value
Body Weight (g)	1687±22.70 ^a	1262±20.26 ^c	1453±17.79 ^b	***
Liver Weight (g)	32.95±0.85 ^a	17.84±0.15 ^c	26.31±0.25 ^b	***
Ovarium Weight (g)	14.68±0.16 ^a	5.79±0.23 ^b	14.28±0.15 ^a	***
Thyroid Weight (g)	0.10±0.01 ^b	0.14±0.02 ^a	0.15±0.01 ^a	*
Thyroid Length (cm)	0.56±0.03 ^c	1.14±0.07 ^a	0.87±0.03 ^b	***

Different letters in the same line are important (*p<0.05, **p<0.01, ***p<0.001), ^{a,b,c} superscripts in the same row indicate significant differences between groups.

Weight and feather loss were observed in the forced molting hens. The liver and ovarium weights decreased, but the thyroid was enlarged when the macroscopic and absolute examination of organs was performed. Thyroid weight and length increased significantly in the molting and post molting group, but not in the control group.

In the Table 2-3 the blood, liver and thyroid tissues levels of MDA, GSH, plasma glucose, Ca, P, albumin,

Table 2 – Blood, liver and thyroid tissues levels of MDA and GSH of hens in the control (C), molting (M) and post molting (PM) groups.

Parameter	Control Group (C) (X±Sx) n=8	Molting Group (X±Sx) (M) n=8	Post Molting Group (PM)(X±Sx) n=20	p-value
Blood MDA (nmol/L)	0.94±0.13 ^a	2.10±0.27 ^b	2.01±0.27 ^a	*
Liver MDA (nmol/g)	1.29±0.02 ^a	1.39±0.03 ^a	1.22±0.02 ^b	***
Thyroid MDA (nmol/g)	393.17±8.08 ^a	371.99±14.40 ^b	408.82±7.49 ^a	*
Blood GSH (mg/dL)	324.29±17.09 ^a	354.53±16.57 ^a	27.58±4.79 ^b	***
Liver GSH (µmol/g)	0.18±0.05 ^b	0.16±0.02 ^b	0.66±0.13 ^a	**
Thyroid GSH (µmol/g)	4.59±0.59 ^a	3.52±0.63 ^a	4.04±0.46 ^a	NS

Different letters in the same line are important (*p<0.05, ** p<0.01, *** p<0.001), NS: Nonsignificant. a,b,c superscripts in the same row indicate significant differences between groups.



globulin, total protein (TP), T_3 , T_4 , Vitamin C and CAT are shown.

Table 3 – Plasma glucose, Ca, P, albumin, globulin, TP, T_3 , T_4 , Vitamin C and catalase of hens in the control (C), molting (M) and post molting (PM) groups.

Parameter	Control Group (C) ($X \pm Sx$) n=8	Molting Group (M) ($X \pm Sx$) n=8	Post Molting Group (PM)($X \pm Sx$) n=20	p-value
Glucose (mg/dL)	265 \pm 7.97 ^a	233.88 \pm 7.76 ^b	253.15 \pm 4.00 ^a	**
Ca (mg/dL)	23.95 \pm 0.89 ^b	11.85 \pm 0.27 ^c	26.94 \pm 0.38 ^a	***
P (mg/dL)	5.49 \pm 0.30 ^b	4.45 \pm 0.14 ^c	7.65 \pm 0.30 ^a	***
Albumin (mg/dL)	1.58 \pm 0.14 ^b	1.70 \pm 0.07 ^b	2.40 \pm 0.07 ^a	***
Globulin (mg/dL)	3.25 \pm 0.14 ^b	3.19 \pm 0.15 ^b	3.86 \pm 0.12 ^a	**
TP (mg/dL)	4.90 \pm 0.18 ^b	5.00 \pm 0.17 ^b	6.09 \pm 0.11 ^a	***
T_3 (pg/mL)	5.85 \pm 0.11 ^b	3.52 \pm 0.06 ^c	8.53 \pm 0.43 ^a	***
T_4 (ng/dL)	0.43 \pm 0.01 ^b	0.53 \pm 0.007 ^a	0.43 \pm 0.008 ^b	***
Vitamin C (mg/dL)	1.40 \pm 0.13 ^a	0.92 \pm 0.07 ^b	1.64 \pm 0.06 ^a	***
Catalase (kU/L)	133.15 \pm 25.15 ^b	58.94 \pm 5.85 ^a	214.90 \pm 25.32 ^a	***

Different letters in the same line are important (* $p < 0.05$, ** $p < 0.01$, *** $p < 0.001$).
^{a,b,c} superscripts in the same row indicate significant differences between groups.

Macroscopically findings (Fig. 1) and microscopically examined sections (Fig. 2) showed the histopathological architecture of the liver, ovarium and thyroid tissues in hens. The liver had a normal appearance in the C and PM group (Fig. 1-A,C) but liver looked pale, roundness in the edges of liver lobes were observed and there was a slightly growth in the molting group (Fig. 1. B). The ovarium had a lot of mature follicles in the C and PM group (Fig. 1- D, F), but we didn't find any follicles in the molting group (Fig. 1-E). The thyroid was enlarged when the macroscopic and absolute examination in the molting and post molting group compared with the control group (Fig. 1-H,I).

The liver had a normal histological appearance in the control group (Fig. 2-A). The liver tissue of molting group had hyperemia, sinusoidal dilatation and severe degeneration (hydropic degeneration) (Fig. 2-B). The liver tissue of post molting group had slightly hyperemia and a few degeneration of hepatocytes (Fig. 2-C).

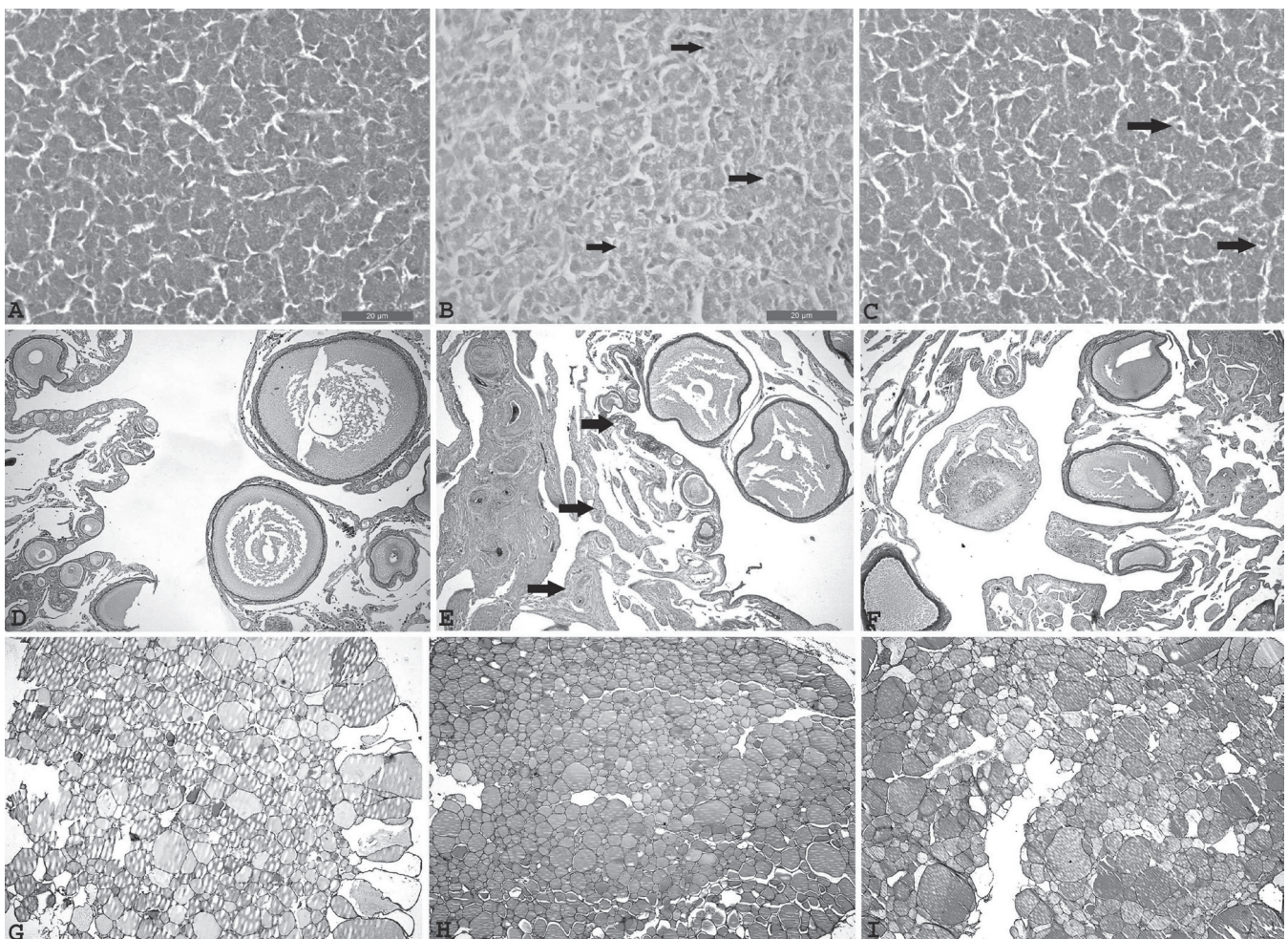


Figure 1 – Macroscopically findings showed the liver, ovarium and thyroid tissues in all groups. Normal macroscopic of liver in control group (A). Liver looked pale, roundness in the edges of liver lobes and slightly growth in the molting group (B). Normal macroscopic of liver in post molting group (C). Ovarium had a lot of mature follicles in the control (D) and post molting group (F). Ovarium had a lot of primary follicle (black arrow heads), didn't find mature follicle in the molting group (E). Normal macroscopic of thyroid (black arrow heads) in control group (G). The thyroid (black arrow heads) was enlarged in the molting (H) and post molting group (black arrow heads) (I).



The ovarium (Fig. 2-D,F) and thyroid (Fig. 2-G,I) had a normal histological appearance in the control group and post molting group. The ovarium had the lower primer, seconder and tertier follicles; and connective tissue increased in the interstitium are shown in the molting group (Fig. 2-E). In the molting group the concentration of colloidal secretion increased and lumen dilatation formed (Fig. 2-H).

DISCUSSION

At the end of 12–15 months of egg production, commercial egg laying hens lost their economical values, then new hens or hens after a forced molting

program can be used to extend the economical life of the herd (North & Bell, 1990). Low egg prices, the prices of large eggs and high costs of chicken growth are the main advantages of forced molting. Forced molting reduces the share of chicken cost in the total chicken egg production expenditure (Erensayin, 1992; Senkoylu, 1995).

The weight loss and then regaining of the lost weight during the forced molting program is called regeneration and rejuvenation (Decuyper & Verheyen, 1986; Decuyper *et al.* 2005). In the fasting period, up to a 30% increase in weight loss causes a decrease in egg production and egg shell quality (Baker, 1981; Hazan & Yalçın, 1985). Complete cessation of egg

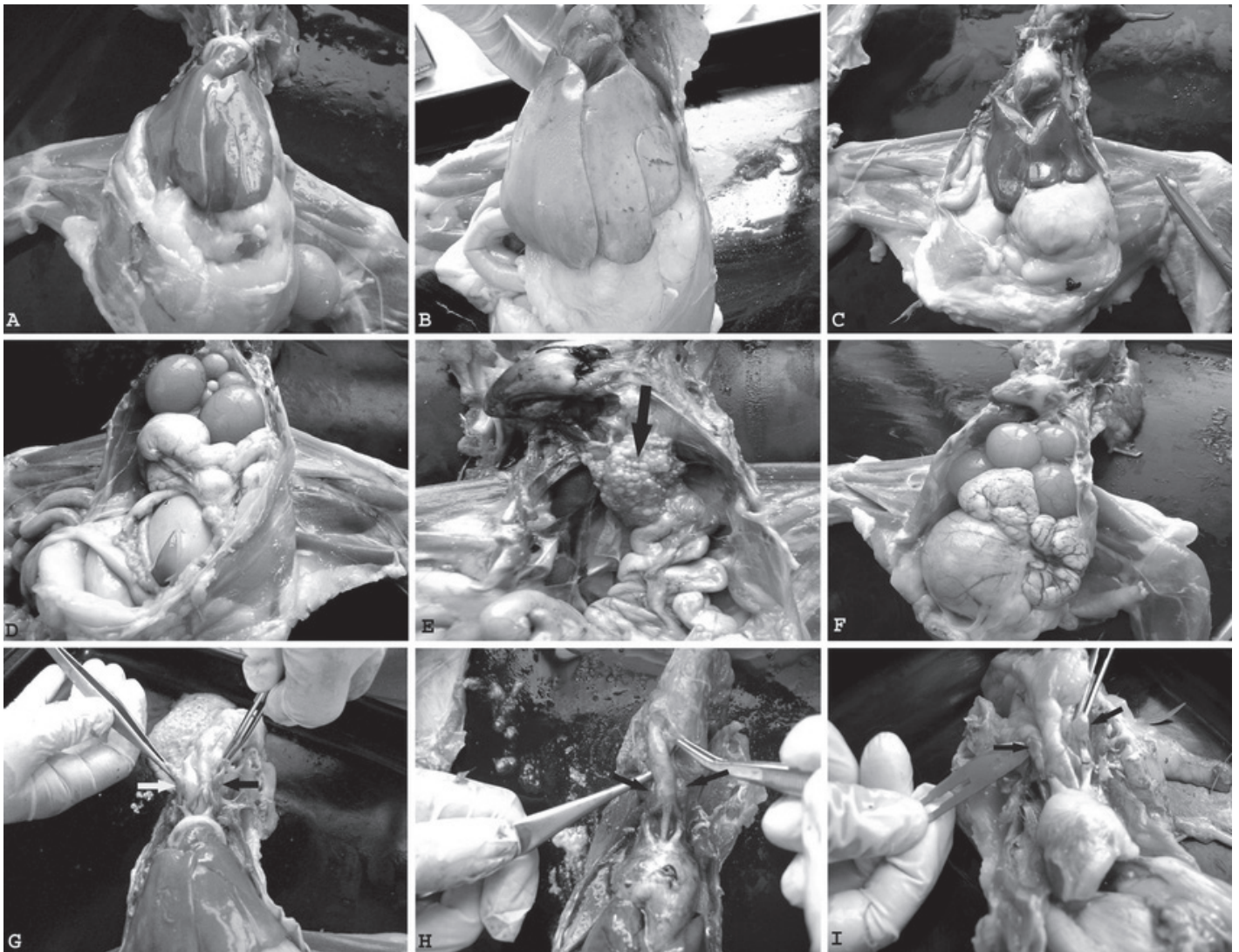


Figure 2 – Histopathological appearance in all groups. H&E stained laying hen's liver, ovarium and thyroid sections. Normal histopathological appearance of liver in control (A) (H.E Bar:20µm). Liver had hyperemia, necrosis (green arrow heads), sinusoidal dilatation and severe hydropic degeneration (black arrow heads) in molting group (B) (H.E Bar:20µm). Liver had slightly hyperemia and a few degeneration (black arrow heads) of hepatocytes in post molting group (C) (H.E Bar:20µm). Normal histopathological appearance of ovarium in control group (D) (H.E Bar:20µm). The ovarium had the lower primer, seconder and tertier follicles; and connective tissue (black arrow heads) increased in the interstitium are shown in the molting group (E) (H.E Bar:20µm). Normal histopathological appearance of ovarium in post molting group (F) (H.E Bar:20µm). Normal macroscopic of thyroid in control group (G) (H.E Bar:20µm). The thyroid had colloidal secretion diffuse increased, lumen dilatation formed in molting group (H) (H.E Bar:20µm). Normal histopathological appearance of thyroid in post molting group (I) (H.E Bar:20µm).



production at the end of the fasting period proves the stopping of ovarial activity (Garlich, 1984).

One of the negative effects of forced molting is body weight loss. The average live weight of laying hens, decreased 25% at the 8th day of the molting program but after normal feed and water were given to the hen's average weights approached the previous levels. The liver and ovarium also decreased during molting and the size of the thyroid was enlarged. The weight of the thyroid gland was higher in the molting and post molting group than in the control group ($p < 0.05$). The lengths of the thyroid increased during molting but decreased in the post- molting period. These changes are due to an increase of colloidal liquid in the thyroid (Bostanci, 1979; Brake *et al.* 1979).

In chickens, ovarian and oviductal regression was achieved through apoptosis (Heryanto *et al.*, 1997). Increased expression of these two proinflammatory cytokines, from the first day of molting suggests their role in the initiation of apoptosis. Yoshimura *et al.* (1997) and Sundaresan *et al.* (2006) reported similarly findings, stained sections of ovarium were also analyzed histologically for atrophic changes in the regressing ovarium of chickens during molting.

Stress factors like starvation, low and high heat hormon increase the lipid peroxidation in animals. Here, the MDA values of the 3 groups are shown in Table 4 and significant increases were determined during molting and then slightly decreased in the egg laying period. These changes are statistically important ($p < 0.05$). Szabo *et al.* (2005) found a significant decrease of liver weight and crude fat during absolute and relative long term starvation. The amount of MDA increased by membrane lipid degradation.

Decrease in antioxidant levels in living organisms cause an increase in lipid peroxidation septic shock, organ function disorders, malnutrition and food deficiencies result with decreased tissue GSH levels. In these cases tissue damage was increased by lipid peroxidation or oxidants (Robinson *et al.* 1997).

The liver plays an important role in GSH homeostasis and the stress hormon stimulates the secretion of GSH from liver. During stress conditions, depending on the release, the hepatic GSH level decreases and the blood GSH level increases (Mahmoud & Edens, 2003). This was also observed in the presented study. The liver GSH levels decreased but blood GSH level increased during the molting program. Song *et al.* (2000) evaluated that GSH mobilization from the liver pool causes an increase of blood GSH.

The level of thyroidal GSH decreased like the extra and hepatic amount when stress factors were

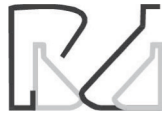introduced. However, it reached normal values when the hen began egg production.

The catalase activity reaches high levels during regular feeding but during the food restriction of starvation program CAT levels decreased (Pascual *et al.* 2003). Indeed, in this study the CAT levels were low during molting (food restriction-thirsty) as the result of the elimination of H_2O_2 produced stress, in the post molting or egg laying period it began to rise again to normal levels ($p < 0.001$).

Brake *et al.* (1981) reported decreased serum glucose concentration during the molting period. Brake and Thaxton (1979) applied two different heat programs to hens in molting at different ages and found no significant changes in plasma glucose levels which suggest that a complex hormonal mechanism may be involved in the regulations. Differences in glucose between the three groups were found statistically important ($p < 0.01$).

Glucose and catalase protect cells against oxidative changes. Because glycolytic and pentose phosphate pathways use glucose, it leads to redox imbalances, an accumulation of endogen peroxides cells which are sensitive to peroxides. It is well known that their increased oxidant substances cause cell death. As a result, glucose indirectly regulates pentose phosphate activity and GSH/GSSG ratios and is a good metabolite for cellular antioxidant defense.

Brake and Thaxton (1979) found that plasma, Ca and P levels in the premolting period as 22mg/dL and 3.8 mg/dL respectively. Ca levels decreased to 7 mg/dL during molting. Garlich *et al.* (1984), also determined Ca and P levels in pre molting as 27.5–6.04 mg/dL. They found significant decreases in the levels of Ca and P to be 6.9–4.43 mg/dL respectively. Gildersleeve *et al.* (1983) found the Ca and P levels in the control and molting groups as 26.6–5.1 mg/dL and 6.9– 4.43 mg/dL respectively. Roland and Brake (1982) also determined the serum, Ca and P levels in the control and molting groups to be 23–4.6 mg/dL and 14– 4.4 mg/dL respectively. Hens in a long term fasting program (10 days) had lower Ca and P levels than the short term fasting Ca-P levels (Yalçın, 1998). In the presented study similar result were found. Ca and P levels decreased significantly during molting. Then, after molting these values increased to normal values again. These findings are in agreement with literature data. The main reason for the decline in plasma, Ca and P levels could be due to sexual inactivity and a decrease in the intestinal CaBP levels which had negative effects on the Ca absorption.



Albumin levels in 2-8 week old chickens were determined as 12.3-13.9 g/L (Sreemannarayana *et al.* 1989), in 42 days old chickens 14.2 g/L (Bowes *et al.* 1989) and Gildersleeve *et al.* (1983) found serum albumin levels as 2.5 mg/dL. Some other reports also supported the high albumin levels. Egg production and genetic variations could affect these differences (Poyraz *et al.* 1988). In this study the average concentration of albumin increased in the molting and post molting groups, more than in the control group. These differences are statistically important ($p < 0.001$).

The globulin levels were significantly affected by the fasting program but increased significantly after molting ($p < 0.01$) Table 2. Total protein levels also increased ($p < 0.001$) and this could be due to increased protein synthesis and this finding was in accordance with Gildersleeve *et al.* (1983).

The increase of T_4 is not dependable on the increases of TSH secretion during fasting (Van Der Geyten *et al.* 1999). Hoshino *et al.* (1988) reported increased T_4 levels during the beginning of the 8 days starvation and 2 days thirst program and then reached normal levels when laying. In the presented study T_3 and T_4 levels were measured at every stage and discussed. The decreased T_3 and increased T_4 levels were found during molting. The growth of feather, regression of ovarium and increased metabolic activity during molting could be the main causes for thyroidal changes.

The Vitamin C levels were affected by various factors such as stress, disease, feed, consumption and season. In the present study the plasma Vitamin C levels decreased during molting and increased when the hens began normal feeding. Changes between the 3 groups were found statistically important $p < 0.001$.

As a result, the molting process causes stress in laying hens, affects the oxidant/antioxidant status; changes the sizes of the organs and their weights; changes the hormone's profile of the thyroid as T_3 decrease and T_4 increase; decreases the concentration of plasma, Ca and P, protein fractions, tissue and blood antioxidant levels; decreases blood glucose and increases lipid peroxidation. The activities of thyroid MDA, liver GSH and plasma CAT were significantly decreased in the molting group compared to the control values, while liver MDA levels were significantly increased and thyroid GSH levels had non-significant effects. It was presented here, that the liver and thyroid tissue levels of MDA, GSH and plasma CAT were the first reports in scientific literature of the forced molting processes. Molting has economical profitability for enterprizes but has side-effects too. Despite all the disadvantages,

regeneration of organs, quality increases of the egg shell and egg, increased economical income and contributions to public health diets, the adverse effects of molting can be ignored.

ACKNOWLEDGEMENTS

The authors wish to thank the Department of Phatology (YYU Veterinary Faculty, VAN) and BAYTAV Egg Production and Marketing Limited Company (VAN) for supporting this study.

REFERENCES

- Akkan AG. Vitaminler, İÜ. Cerrahpaşa tıp fakültesi sürekli tıp eğitim etkinlikleri. İstanbul: Cerrahpaşa Tıp Fakültesi;1999.
- Baker M, Brake J, Krista M. Total body lipid and uterine lipid changes during a forced molt of caged layers. *Poultry Science* 1981;60:1593.
- Ball CR. Estimation and identification of thiols in rat spleen after cysteine or glutathione treatment: relevance to protection against nitrogen mustards. *Biochemical Pharmacology* 1966;15:809-816.
- Beşeoğlu N. Serum proteinlerinin iki boyutlu elektroforez ile ayrılması. İstanbul: Sağlık Bilimleri Enstitüsü Biyofizik Anabilim Dalı Yüksek Lisans Tezi; 2002.
- Beutler E, Duran O, Kelly BM. Improved method for the determination of blood glutathione. *Journal of Laboratory and Clinical Medicine* 1963;61(5):882-888.
- Bostancı AN. Tiroid ve Paratiroid Hastalıkları, Endokrinoloji-11. Bozak Matbaası 1979;(1):249.
- Bowes VA, Julian RJ, Stirtzinger T. Comparison of serum biochemical profiles of male broilers with female broilers and White Leghorn chickens. *Canadian Journal of Veterinary Research* 1989;53:711.
- Brake J, Garlich JD, Carter JA. Relationship of dietary calcium level during the prelay phase of an induced molt to postmolt performance. *Poultry Science* 1984;63:2497-2588.
- Brake J, Garlich JD, Parkhurst CR, Thaxton P, Morgan GW. Physiological profile of caged layers during one production season, molt and postmolt: Organ weights and blood constituents. *Poultry Science* 1981;60:2157-2160.
- Brake J, Thaxton P. Physiological changes in caged layers during a forced molt. 1-Body temperature and selected blood constituents. *Poultry Science* 1979;58:699-706.
- Brake J, Thaxton P, Benton EH. Physiological changes in caged layers during a forced molt. 3- Plasma thyroxine, plasma triiodothyronine, adrenal cholesterol and total adrenal steroids. *Poultry Science* 1979;58:1345-1350.
- Brown RE. Infection of nutrition and infection in clinical practice. *Pediatric Clinics of North America* 1997;24:241-251.
- Decuypere E, Van As P, Van Der Geyten S, Darras VM. Thyroid hormone availability and activity in avian species: a review. *Domestic Animal Endocrinology* 2005;29:63-77.
- Decuypere E, Verheyen G. Physiological basis of induced moulting and tissue regeneration in fowls. *World's Poultry Science Journal* 1986;42(1):56-68.
- Erensayın C. Bilimsel teknik pratik tavukçuluk. Ankara: TDFO; 1992. p.431-461.



- Fernandez V, Videla LA. Effect of acute and chronic ethanol ingestion on the content of reduced glutathione of various tissues of the rat. *Experientia* 1981;37:392-394.
- Garlich JD, Brake J, Parkhurst CR, Thaxton JP, Morgan GW. Physiological profile of caged layers during one production year molt and postmolt: Egg production, egg shell quality, liver, femur and blood parameters. *Poultry Science* 1984;63:339-343.
- Gilbert AB. Transport of the egg through the oviduct and oviposition. In: Bill DJ, Freeman BM. *Physiology and biochemistry of the domestic fowl*. London: Academic Press; 1971. p.1345-1350.
- Gildersleeve RP, Satterlee DG, Johnson WA, Scott TR. The effect of forced molt treatment on selected steroids in hens. *Poultry Science* 1982;6:2362-2369.
- Gildersleeve RP, Satterlee DG, Johnson WA, Scott TR. The effects of forced molt treatment on blood biochemicals in hens. *Poultry Science* 1983;62:755-762.
- Goth L. A simple method for determination of serum catalase activity and revision of serum catalase activity and revision of reference range. *Clinica Chimica Acta* 1991;196:143-152.
- Guyer RB, Grunder AA, Buss EG, Clagett CO. Calcium-binding proteins in serum of chickens: Vitellogenin and albumin. *Poultry Science* 1980;59:874-879.
- Halliwell B, Gutteridge JMC. The important of free radicals and catalytic metal ions in human disease. *Molecular Aspects of Medicine* 1985;8:89-91.
- Hazan A, Yalçın S. Effect of body weight loss and feeding regimen on the performance of molted breeder layers. *British Poultry Science* 1988;29:513-520.
- Heryanto B, Yoshimura Y, Tamura T, Okamoto T. Involvement of apoptosis and lysosomal hydrolase activity in the oviducal regression during induced molting in chickens: a cytochemical study for end labeling of fragmented DNA and acid phosphatase. *Poultry Science* 1997;76:67-72.
- Hoshino S, Suzuki M, Kakegawa T, Imai K, Wakita M, Kobayashi Y, et al. Changes in plasma thyroid hormones, luteinizing hormone (LH), estradiol, progesterone and corticosterone of laying hens during a forced molt. *Comparative Biochemistry and Physiology* 1988;90(2):355-359.
- Hudson DA, Levin RJ, Smith DH. Absorption from the alimentary tract. In: Bell DJ, Freeman BM. *Physiology and biochemistry of the domestic fowl*. New York: Academic Press; 1971. p.52-71.
- Johnson AL, Bridgman JT, Witty JP, Tilly JL. Susceptibility of avian ovarian granulosa cells to apoptosis is dependent upon stage of follicle development and is related to endogenous levels of bc1-xlong gene expression. *Endocrinology* 1996;137:2059-2066.
- Kramer JW. Clinical enzymology. In: Kaneko JJ. *Clinical biochemistry of domestic animals*. 3rd ed. New York: Academic Press; 1980. p.183-186.
- Mahmoud ZK, Edens FW. Influence of selenium sources on age-related and mild heat stress-related changes of blood and liver glutathione redox cycle in broiler chickens (*Gallus domesticus*). *Comparative Biochemistry and Physiology* 2003;136(4):921-934.
- Marklund SL. Analysis of extracellular superoxide dismutase in tissue homogenates and extracellular fluids. *Methods in Enzymology* 1990;186:260-265.
- Martin DW, Mayes PA, Rothbell VW. Harper's review of biochemistry. 18th ed. Tokyo: Maruzen; 1981.
- Mert N. Veteriner klinik biyokimya. Bursa: U.Ü. Vet Fak; 1996. p.151-153.
- North MO, Bell DD. Commercial chicken production manual. 4th ed. New York: Chapman & Hall; 1990.
- Omaye ST, Turbul JD, Savberlich HE. Ascorbic acid analyses. II. determination after derivation with 2,2 dinitrophenylhydrazine, selected methods for determination of ascorbic acid in animal cell, tissues and fluids. *Methods Enzymology* 1979;62:7-8.
- Ozen N. Tavukçuluk. Samsun: 19 Mayıs Üniversitesi Yayınları; 1986.
- Park SY, Birhold SG, Kubena LF, Nisbet, DJ, Ricke, SC. Effects of high zinc diets using zinc propionate on molt induction, organs and postmolt egg production and quality in laying hens. *Poultry Science* 2004;83:24-33.
- Pascual P, Pedrajas JR, Toribio F, López-Barea J, Peinado J. Effect of food deprivation on oxidative stress biomarkers in fish (*Sparus aurata*). *Chemical Biological Interactions* 2003;145:191-199.
- Poyraz O, Iscan K, Ozcan I. Etçi damızlıklarda zorlamalı tüy dökümü yöntemleri üzerine bir araştırma. *Lalahan Hay Arast Enst Derg* 1988;28:13-23.
- Rizzi R, Caroli A, Bolla P, Acciaioi A, Pagnacco G. Variability of reduced glutathione levels in massese ewes and its effect on daily milk 55. *Production. Journal of Dairy Research* 1988;345-353.
- Robinson MK, Rustum RR, Chambers EA, Rounds JD, Wilmore DW, Jacobs DO. Starvation enhances hepatic free radical release following endotoxemia. *Journal Surgical Research* 1997;69: 325-330.
- Roland DA, Brake J. Influence of premolt production on postmolt performance with explanation for improvement in egg production due to force moulting. *Poultry Science* 1982;61:2473-2481.
- Slater TF. Overview of methods used for detecting lipid peroxidation. *Methods in Enzymology* 1984;105:283-305.
- Song Z, Cawthon D, Beers K, Bottje WG. Hepatic and extra-hepatic stimulation of glutathione release into plasma by norepinephrine in vivo. *Poultry Science* 2000;79:1632-1639.
- Sreemannarayana O, Marquardt RR, Frohlich AA, Guenter W. Enzyme activities, protein, metabolites and electrolyte concentrations in the serum of single comb white leghorn chickens. *Indian Veterinary Journal* 1989;66:435-440.
- Sundaresan NR, Anish D, Sastry KVV, Saxena VK, Mohan J, Ahmed KA. Cytokines in reproductive remodeling of molting White Leghorn hens. *Journal of Reproductive Immunology* 2006;73:39-50.
- Sushil JK, Mcvie R, Duett J, Herbst JJ. Erythrocyte membrane lipid peroxidation and glycosylated hemoglobin in diabetes. *Diabetes* 1989;38:1539-1543.
- Szabo A, Fébel M, Mézes M, Horn P, Balogh K, Romvári R. Differential utilization of hepatic and myocardial fatty acids during forced molt of laying hens. *Poultry Science* 2005;84:106-112.
- Senkoğlu N. Modern tavuk üretimi. İstanbul: Anadolu Matbaa; 1995. p.247-257.
- Tezeman ST, Siperstein AE. Signal transduction in thyroid neoplasms. In: Clark OH, Duh QY. *Textbook of endocrine surgery*. Philadelphia: WB Saunders; 1997. v.28, p.214-227.
- Van Der Geyten S, Van Rompaey E, Sanders JP, Visser TJ, Kühn ER, Darras VM. Regulation of thyroid hormone metabolism during fasting and refeeding in chicken. *General and Comparative Endocrinology* 1999;116:272-280.
- Xia E, Rao G, Remmen HV, Heydari AR, Richardson A. Activities of antioxidant enzymes in various tissues of male Fischer 344 Rats are altered by food restriction. *Journal of Nutrition* 1994;125:195-201.
- Yalçın SA. Antioksidanlar. *Klinik Gelisim* 1998;11:342-346.
- Yoshimura Y, Heryanto B, Tamura T. Changes in the population of proliferating cells in chicken anterior pituitary during induced molting: an immunocytochemical analysis for proliferating cell nuclear antigen. *Poultry Science* 1997;76:1569-1573.
- Yoshimura Y, Tamura T. Histological and histochemical observation on the atretic follicles induced by adenohipophysectomy in the hen. *Japanese Poultry Science* 1985;22:134-141.
- Yoshimura Y, Okamoto T, Tamura T. Enzyme histochemical observations on the ovarian small follicles in relation to the mechanism of atresia in laying hens (*Gallus domesticus*). *Japanese Poultry Science* 1989;46:10-16.