

# Use of ethanol in preventing calcification of porcine pulmonary heterograft: experimental study in sheep

*Utilização do etanol na prevenção da calcificação em heteroenxerto valvar pulmonar porcino: estudo experimental em ovinos*

George Ronald SONCINI DA ROSA<sup>1</sup>, Francisco Diniz Affonso da COSTA<sup>2</sup>, Ricardo Guilherme D'Otaviano de Castro VILANI<sup>3</sup>, Felipe Phol de SOUZA<sup>3</sup>, Lorena REICHERT<sup>4</sup>, Iseu de Santo Elias Affonso da COSTA<sup>5</sup>

RBCCV 44205-833

## Abstract

**Objective:** The objective of this work was to comparatively evaluate of the use of ethanol (E) with glutaraldehyde (GDA) to inhibit the calcification of porcine pulmonary valvar heterografts (PPVH) implanted in the right ventricle outflow tract of young sheep.

**Method:** Ten young sheep were used, divided into two similar groups: the GDA (Control) Group and the Ethanol Group (in which the PPVH were pre-treated with ethanol-80). The surgery consisted of implanting the PPVH in the right ventricle outflow tract using a cardiopulmonary bypass. Echocardiography was performed to measure the transvalvar gradient and macroscopic analyses of the PPVH wall and microscopic analysis for calcification were performed. The amount of calcium was measured in the valve cusp at 210 days.

**Results:** The quantity of calcium in the PPVH of the GDA

Group was  $7.98 \pm 6.82\mu\text{g}$  calcium/mg tissue and of the E Group it was  $0.31 \pm 0.33\mu\text{g}$  calcium/ mg tissue. In respect to the maximum transvalvar gradient at 30 days, there was no significant difference between the groups. At 90, 180 and 210 days however, the GDA Group showed a greater transvalvar gradient than the E Group. The macroscopic analyses of the heterograft wall evidenced calcification in both groups but it was more pronounced in the GDA Group. The microscopic analysis of the cusp valve revealed the presence of calcification in all animals of the GDA Group, while in the E Group no calcification was seen.

**Conclusion:** In conclusion ethanol-80 inhibits calcification on the cusps during the period of the analysis but does not inhibit the calcification of the PPVH.

**Descriptors:** Ethanol. Sheep. Calcinosis. Transplantation heterologous. Glutaral.

1 - PhD. Cardiovascular surgeon

2 - PhD Professor of Clinical Surgery Department of PUCPR.

3 - PhD. Professor of Veterinary Medicine of PUCPR.

4 - MSc. Cardiologist and Echocardiographist

5 - Head of Cardiovascular Surgery Service of Hospital Santa Casa de Curitiba - PUCPR.

Work carried out in the Experimental Surgery Department of the Operative technique Section (PUCPR). Veterinary Hospital of Catholic Pontifical University in Paraná (PUCPR). Clinical Surgery Department of the Federal University in Paraná (UFPR) -Curitiba, PR, Brazil.

Correspondence address:

George Ronald Soncini da Rosa. Av. Silva Jardim 2939, Apto 111

Água Verde - Curitiba, PR, Brazil - CEP: 80240-020

Phone/fax: (41) 3342-4505;

E-mail: soncini@bsi.com.br

Article received in January, 2006

Article accepted in August, 2006

### Resumo

**Objetivo:** Analisar comparativamente o uso do etanol (E) com o glutaraldeído (GDA), como método de inibição da calcificação dos heteroenxertos valvares pulmonares porcinos (HVPP) implantados na via de saída do ventrículo direito (VD) de ovinos jovens.

**Método:** Foram utilizados dez ovinos jovens, em dois grupos contendo cinco animais cada. A operação consistiu na implantação do HVPP na via de saída do VD com circulação extracorpórea, divididos em dois grupos; o grupo do GDA (controle) e o grupo E (grupo em que os HVPP foram pré-tratados com etanol a 80%). Realizou-se estudo ecocardiográfico para medida do gradiente transvalvar pulmonar, análise macroscópica da parede do HVPP e microscópica quanto à presença de calcificação; e mensuração do cálcio na cúspide valvar após 210 dias.

**Resultados:** Na mensuração do cálcio do HVPP encontrou-

se no grupo GDA ( $7,98 \pm 6,82 \mu\text{g}$  cálcio/mg tecido), no grupo E ( $0,31 \pm 0,33 \mu\text{g}$  cálcio/mg tecido). Em relação ao gradiente transvalvar máximo em 30 dias, não houve diferença significativa entre os grupos, já aos 90, 180 e 210 dias, o grupo GDA apresentou maior gradiente transvalvar do que o grupo do etanol. Na análise macroscópica da parede do HVPP, observou-se calcificação em ambos os grupos, sendo mais intensa no grupo do GDA. Na avaliação microscópica das cúspides do HVPP em relação à presença de calcificação, observou-se que no grupo GDA esteve presente em todos os animais, enquanto no grupo E, esteve ausente em todos.

**Conclusão:** Conclui-se que etanol a 80% inibe a calcificação das cúspides no período analisado, mas não inibe a calcificação da parede do HVPP.

**Descritores:** Etanol. Ovinos. Calcinose. Transplante heterólogo. Glutaral.

## INTRODUCTION

Calcification is the most frequent cause of functional failure of porcine and bovine pericardium heart valve bioprotheses fixed in GDA [1,2]. This calcification consists of a deposit of calcium phosphate associated to the minerals in the tissue of the bioprosthesis [2].

The durability of these tissues is limited by structural deterioration, which, in part, is attributed to dystrophic calcification of the collagen matrix [3].

Researchers have been trying to develop an ideal heart valve substitute for many years. Generally, heart valve substitutes are divided into two types: mechanical and biological prostheses. Biological tissue prostheses are manufactured using bovine pericardium or porcine cusps with or without the inclusion of segments of the aortic wall [4].

In spite of the advances in valve reconstruction techniques, many patients submitted to surgical procedures receive prostheses. The advantage of the greater durability of mechanical valves is offset by the necessity of anticoagulants to avoid thromboembolic events. Patients with implanted biological prostheses do not require life-long anticoagulation, but these prostheses are prone to calcification and degeneration with the necessity of reoperations to replace them [5,6].

Biological tissues have been used for replacement valves since 1962, when a fresh human aortic valve was transplanted [7]. Later, prostheses manufactured from bovine pericardium [8,9], autogenous fascia lata [10] and human dura mater [11] were introduced.

The use of glutaraldehyde (GDA) to fix porcine prostheses was considered a significant step in the conservation process of biological tissues [12]. Apart from a reduction in the antigenicity of the heterologous tissue, the fixation obtained by covalent binding was considered beneficial [12]. In the following years, fixation using GDA was widely used in the manufacture of porcine and bovine pericardium prostheses [13,14].

Currently, valve prostheses are utilized in approximately 40% of all valve replacement procedures worldwide [4]. There are differences between developed and underdeveloped countries, with more biological tissue being utilized in the latter [4,7,15].

The incidence of bioprosthetic valve failure is around 10% to 20% over 10 years in adult patients and 40% to 50% over four years in children [16].

Mechanical stress and lipid deposits in the cells of porcine aortic cusps resulting from fixation with GDA have been indicated as the main factors that influence calcification [17,18].

The supposition that calcification can be related to GDA use awakened interest to study changes in the fixation process, such as the addition of mineralization inhibiting substances or even substitution of GDA for other fixing agents.

Among the treatments investigated is the use of ethanol which has proved to be efficient as an anticalcifying agent in porcine aortic valve bioprostheses. This result was observed in segments of tissue subcutaneously implanted in rats and mitral prostheses implanted in sheep [2,14,19].

Several studies have demonstrated the efficacy of ethanol as a calcification inhibitor in porcine bioprostheses with its main effect being the extraction of lipids [4,14,19,20].

Keeping the necessity of an efficient anticalcifying treatment for heart valve bioprostheses in mind, we proposed a comparative study between the use of ethanol and GDA to prevent calcification of porcine pulmonary valve heterografts implanted in the right ventricle outflow tract of young sheep, with the perspective of minimizing or inhibiting calcification and increasing the durability of bioprostheses in young patients.

#### OBJECTIVE

The objective of this study was to comparatively analyze the use of ethanol and GDA, as calcification inhibitors in porcine pulmonary valve heterografts implanted in the right ventricle outflow tract of young sheep over an observation period of 210 days.

#### METHOD

This work was performed in the Veterinary Hospital and the Histology Laboratory of the Experimental Surgery Section of the Catholic Pontifical University of Paraná (PUCPR), the Heart Prosthesis Laboratory and Lactec (Technology Institute Laboratory for Development).

Veterinary Anatomical naming was adopted [21]. The research was approved by the Research Ethics Commissions from UFPR and PUCPR, according to the Helsinki Declaration and the regulations established in "Guide for the Care and Use of Laboratory Animals" (Institute of Laboratory Animal Resources, National Academy of Sciences, Washington, DC., 1996) and the ethical principles of animal experimentation, in compliance with the recommendations of the Brazilian College of Animal Experimentation (COBEA 2000).

#### Experimental model

Ten clinically healthy crossbred sheep (*Ovis aries*) with ages varying from three to five months and weights between 23 and 32 kg from the animal house of the Catholic Pontifical University in Paraná were utilized. The animals were received

30 days before the experiment for due parasitological control and to check sanitary conditions. The surgery consisted in valve and porcine pulmonary trunk (heterograft) implantation in the right ventricle outflow tract of the sheep's heart using cardiopulmonary bypass (CPB). The animals were divided into two groups:

- **GDA Group (n=5)** – (Control Group) porcine pulmonary valve heterografts treated with GDA and stored in 0.5% GDA.
- **Ethanol Group (n=5)** – porcine pulmonary valve heterografts pre-treated with GDA and after treated in a solution of 80% ethanol and stored in PBS.

#### Procurement of porcine pulmonary valve heterografts

Porcine pulmonary valve heterografts were obtained in the Laboratory of Cardiac Valves (Cardioprostheses®) (Figure 1), where they were prepared according to the necessities of the researcher. After accessing the porcine heart, the pulmonary valve was removed together with the pulmonary trunk. On separating the pulmonary valve conduit, the chemical preparation was performed as followed:

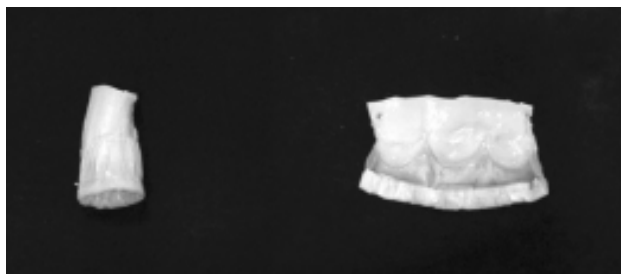

Fig. 1 - porcine pulmonary valve Heterograft after treatment

#### Chemical procedure

All the porcine pulmonary valve heterografts were fixed in a solution of 0.6% GDA (Urcacid®) with 50 mmol/L HEPES (buffer solution) at pH 7.4 for two hours. After two hours, they were fixed in 0.2% GDA solution (Urcacid®) with HEPES solution for three days. After this, they were fixed in 0.5% GDA with HEPES solution for another seven days.

Subsequently the 0.5% GDA solution was replaced and the heterografts of the Control Group (GDA) were stored in 0.5% GDA solution.

On completing the preparation with GDA, the heterografts of the Ethanol Group were rinsed in 1000mL 0.9% isotonic saline solution and placed in 80% ethanol solution (Labsynth®) with HEPES buffered at 25°C under continuous stirring for 24 hours. Following this, they were stored in PBS solution (Paraben solution).

All porcine pulmonary valve heterografts were rinsed in 1000mL 0.9% isotonic saline solution before being implanted.

The diagram of the chemical processes is shown in Figure 2.

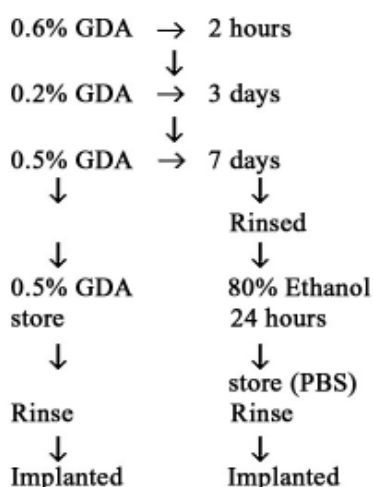


Fig. 2 - Design of the chemical process

### Preoperative preparation

The sheep were maintained in the animal house of PUCPR, where they received balanced feed for sheep during the entire period of confinement.

Before anesthesia for implantation surgery, the animals fasted for 30 hours without food and the last 12 hours without water.

One the day before surgery, the animals were medicated with sodium Ceftiofur and gentamicin antibiotics, shaved in the left thoracic region using an electrical shaver and monitored by electrocardiography, pulse oximetry and invasive arterial pressure.

### Anesthesia

The animals were placed in the right lateral decubitus position on the operation table. Pre-anesthetic medication composed of the association of 0.5 mg/kg diazepam and 0.4 mg/kg butorphanol tartarate administrated endovenously 15 minutes before anesthesia induction. Subsequently, infusions of sodium ceftiofur and gentamicin antibiotics were made. In this period, intercostal anesthetic blocks was performed in the third, fourth and fifth left intercostal spaces using 0.5% bupivacaine hydrochloride and the two cephalic veins were cannulated with one exclusively for the infusion of propofol (Diprivan®). Simultaneously, the right radial artery was punctured and cannulated to measure the arterial pressure.

A 4 mg/kg dose of propofol (Diprivan®) was infused over 60 seconds, thereby enabling tracheal intubation; immediate infusion of the pharmacological agent at a dose of 0.6 mg/kg/min was initiated which continued until 20 minutes after the removal of CPB.

Mechanical ventilation was started using a fixed flow volume of 15 mL/kg at a frequency of 16 cycles per minute.

### Anesthesia monitoring

The systolic (SAP), mean (MAP) and diastolic (DAP) arterial pressures were monitored by the cannulation of the right radial artery using a 22-G catheter connected to a DTX Plus 4812 pressure transducer (Bencton, Dickinson Medical) and a Datascope 3000 monitor. Blood samples for arterial gasometry were collected 5 and 40 minutes after propofol (Diprivan®) administration, 5 and 20 minutes after establishing CPB and 40 minutes after removing CPB. The blood was immediately processed after collection using a DRAKE AGS system.

### Surgical protocol

With the animals in the right lateral decubitus position, antisepsis was performed using iodized alcohol over the entire left hemithorax, followed by the placement of surgical drapes in the conventional manner. Thoracic access was achieved through the fourth left intercostal space using a Finochietto's retractor. The pericardium was opened and the right atrium, thoracic aorta and right ventricle were accessed.

To establish CPB, two purse-string sutures using 4-0 polypropylene thread (Prolene 4.0®, Ethicon) on the ascending aorta and one purse-string suture in the right atrium using the same surgical thread were performed.

Anticoagulation was achieved using a dose of 200U/kg heparin.

After cannulation, CPB at normothermia was initiated, which lasted for from 20 to 25 minutes. CPB was performed using a roller pump and pediatric membrane oxygenator

(Braile Biomedica®). The tube system and the cardiotomy reservoir were filled with 900 mL 0.9% isotonic saline solution with oxygenation at 100%.

The valve and the pulmonary trunk were removed. The porcine pulmonary valve heterograft (porcine pulmonary valve with a bovine pericardium frame) was implanted, using 4-0 polypropylene thread for both proximal and distal anastomoses. Protamine was not used to reverse the effects of heparin at the end of CPB.

After this, hemostasis was checked and a continuous suction thoracic drain placed, which was removed only after recovery from the effects of anesthesia. The ribs were drawn together using 2-0 polypropylene thread (Prolene 2®, Ethicon), subcutaneous suturing was achieved with 910 poliglactin (Vicryl 1®, Ethicon) and the skin sutures using 3-0 mononylon (Mononylon 3.0®, Ethicon).

#### Postoperative observation

All animals, at the end of surgical procedure, were kept under observation by monitoring the invasive arterial blood pressure and pulse oximetry in the intensive care unit for an average time of two hours. Animals remained in this unit until they were able to walk and were then taken to a paddock with food and water. Antibiotics were maintained for seven days.

After 12 hours of observation, the animals were returned to the field and they were placed in duly prepared cages, where they received an association of 4 mg/kg gentamicin and 1 mg/kg ceftiofur for seven days and 2 mg/kg flunixin meglumine for three days. In the postoperative observation period the animals were again submitted to parasitological examinations, hematocrit measurement and weighed every week. They remained under observation for 210 days.

In this period, echocardiograms were performed on the 30th, 90th, 180th and 210th postoperative days in the Experimental Surgery Laboratory of Operative Technique of PUCPR.

Scarification of the sheep was performed using 2 mg/kg xylazine hydrochloride and 5 mg/kg ketamine hydrochloride. After the sheep were unconscious, they received 20 mL of 19.1% potassium chloride.

In order to take samples, a transversal incision in the hemithorax was performed and the fourth rib was removed. The heart was displaced for macroscopic and microscopic analysis and measurement of the calcium on the porcine pulmonary valve cusps.

#### Echocardiographic assessment

All animals were submitted to echocardiograms on the 30th, 90th, 180th and 210th postoperative days to measure the pulmonary transvalvar gradient, to assess possible

ruptures and calcification of cusps. Examinations were performed in a HP Sonus Doppler echocardiograph with 7.5 Hertz transducer.

#### Morphological analysis

##### Macroscopic analysis

The aim of the macroscopic analysis was to evaluate calcification of the wall of the heterograft and valve cusps.

##### Microscopic analysis

The cusps were fixed in 10% formaldehyde solution and microscopically analyzed.

Histological examinations were performed by the same observer without knowledge of the group to which the sheep belonged.

Preparation of the histological material followed the technical methods adopted by the Histology and Pathological Anatomy Laboratory of PUCPR. After fixation in a 10% formaldehyde solution, the sample was dehydrated in progressive concentrations of ethylic alcohol of from 70% to 100%, diaphanized by impregnation using xylol and embedded in 60% paraffin for form blocks.

Two to four  $\mu\text{m}$  thick sections were made and stained with hematoxylin-eosin (H&E) and von Kossa stain (specific method to identify calcification). A Tetraocular Microscope (American Optical) was used for analysis.

To analyze the histopathological findings the following classification was adopted:

#### Pulmonary cuspid

##### 1) Calcification presence

###### I\* Location

- I 1a – focal;
- I 1b - multifocal;
- I 1c – diffuse;
- I 1d - absent.

###### II\* Intensity

- II 1a - slight;
- II 1b - moderate;
- II 1c - accentuated

##### 2) Presence of inflammatory infiltrate

###### I\* Location

- I 2a – focal;
- I 2b - diffuse;
- I 2c – absent

###### II\* Type

- II 2a – acute;
- II 2b – chronic slight;
- II 2c – chronic moderate.

**Calcium measurement**

The pulmonary cusps were dissolved in hydrochloric acid and sent to the Institute of Technology Development Laboratory (Lactec®, Federal University of Paraná, Brazil), where the calcium content was measured by atomic absorption spectroscopy using a Perkin Elmer 4100 spectrometer.

The total amount of calcium is expressed in mg per sample and calculated as µg/mg of pre-implanted dry tissue. Thus, it is possible to estimate the quantity of incorporated calcium per milligram of implanted dry tissue and not of the explanted dry tissue, whose weigh reflects not only the quantity of incorporated calcium, but also the infiltration of host cells.

**Statistical analysis**

The data are presented as tables, figures and graphs. For statistical analysis variance analysis for repeated measures (ANOVA), the paired student t-test, the non-parametrical Mann-Whitney, Wilcoxon (paired data) and Friedman for paired data tests were utilized in the Primer Biostatistics computer program. The adopted level of significance was an  $\alpha$  error of less than 5% (p-value < 0.05).

**RESULTS**

There were two deaths after the surgical procedure; the first one resulted from complications of a pneumothorax within the first six postoperative hours and the second on the fifteenth postoperative day due to intestinal complications. As two deaths occurred, another two animals were included in the study to maintain two groups with five sheep.

**Macroscopic analysis**

By macroscopic analysis, a greater calcification of the heterograft wall in the GDA Group was observed compared to the Ethanol Group. However, calcification occurred in both groups; in the Ethanol Group it was more concentrated and in the GDA Group it was more intense and more diffuse. Macroscopic analysis of the cusps of the heterograft showed that there was no calcification in the Ethanol Group but the GDA Group presented with significant calcification (Figures 3 and 4).

**Microscopic analysis**

**Calcification**

**Pulmonary valve cuspid**

There were focal points of calcification in all heterografts of the GDA Group but no calcification was observed in the heterografts of the Ethanol Group (Table 1, Figures 5 and 6).

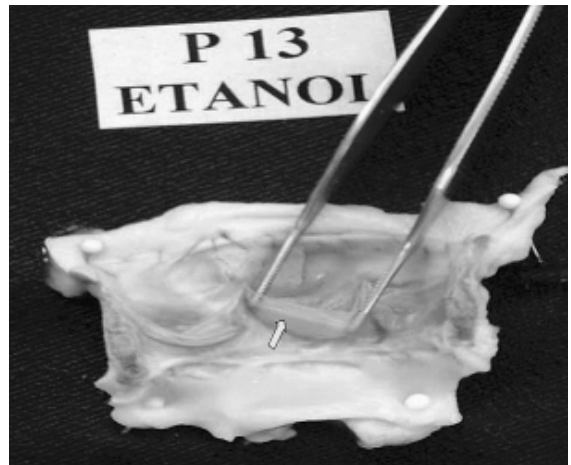


Fig. 3 – porcine pulmonary valve Heterograft treated with ethanol after removal where the cusps do not have signs of calcification




Fig. 4 – porcine pulmonary valve Heterograft treated with GDA after removal where the cusps have signs of significant calcification

Table 1. Presence of calcification related to the location and intensity, in the study groups

CALCIFICATION	GDA (n = 05)		ETHANOL (n = 05)	
	Nº	%	Nº	%
<b>LOCATION</b>				
• Absent	-	-	05	100.0
• Present	05	100.0	-	-
• Focal	04	80.0	-	-
• Diffuse	01	20.0	-	-
<b>Intensity</b>				
• Absent	-	-	05	100.0
• Present	05	100.0	-	-
• Slight	03	60.0	-	-
• Accentuated	02	40.0	-	-

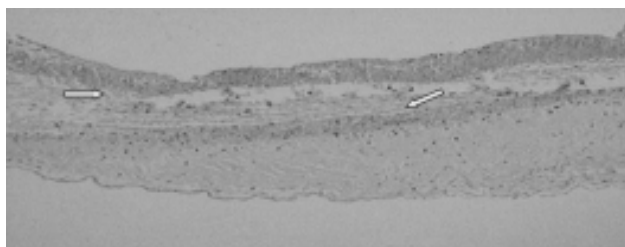


Fig. 5 – Microphotography showing transversal section of the cuspid of the porcine pulmonary valve Heterograft treated with ethanol without signs of calcification 210 days after implant (von Kossa 40X)



Fig. 6 – Microphotography showing transversal section of the cuspid of the porcine pulmonary valve Heterograft treated with glutaraldehyde with signs of significant calcification 210 days after implant (von Kossa 40X)

**Presence of Inflammatory infiltration**

Inflammatory infiltration was observed in all heterografts of both groups, mainly diffuse (type I 2a) and chronic slight (type II 2b).

**Measurement of the calcium**

Comparing the two groups it was observed that the GDA Group presented with a larger amount of calcium at 210 days than the Ethanol Group (p-value = 0.036) – Figure 7;

**Echocardiographic assessment**

**Transvalvar gradient**

- **30 days:** there was no significative difference between the two groups (p=0.082);
- **90 days:** GDA Group presented with a greater maximum transvalvar gradient than the Ethanol Group (p-value = 0.030);
- **180 days:** GDA Group presented with a greater maximum transvalvar gradient than the Ethanol Group (p-value = 0.036);
- **210 days:** GDA Group presented with a greater maximum transvalvar gradient than the Ethanol Group (p-value = 0.033)

This is demonstrated in a single graph (Figure 8).

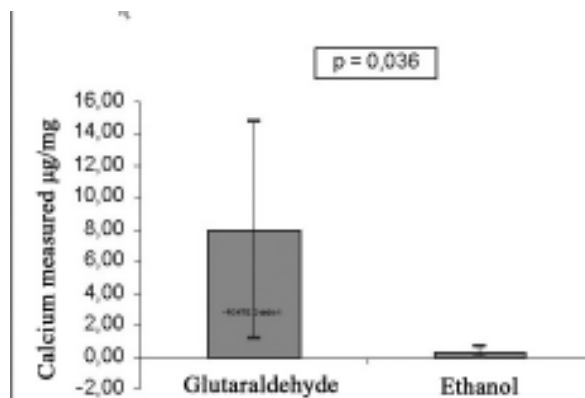


Fig. 7 – Measurement of the calcium in the porcine pulmonary valve Heterograft in the studied groups 210 days after implant

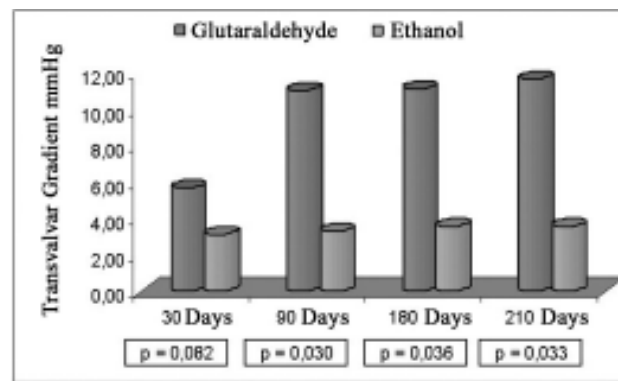


Fig. 8 - transvalvar gradient in the studied groups

**DISCUSSION**

Since the first implantations of porcine valves treated using GDA, several techniques have been used o minimize calcification [22].

The risk of structural failure of porcine bioprostheses is directly dependent on the age of the recipient. In under 35-year-old patients, there is failure almost exactly five years after implantation. In over 65-year-olds, only around 10% have dysfunction in the 10 years that follow implantation [23,24].

With the intention of reducing calcification to the minimum, Schoen et al. [25] used single cations, di- or trivalent during fixation in GDA, but this did not prove to be satisfactory. Hydroxy- and amino-diphosphonates and metallic cations were also tested, but the high levels required interfered in bone growth [22,25].

Pretreatment with detergents (SDS Tween 80) may inhibit calcification by removing the phospholipids from the substrate. However, detergents affect the surface of the membrane and collagen fibers sometimes resulting in a marked reduction in the durability of the bioprostheses [14].

Recently, oleic amino acid used as a detergent was shown to prevent calcification of porcine bioprostheses [26]. The results showed that oleic amino acid significantly reduces calcification of bioprosthesis leaflets implanted in the aortic position in sheep. However, results referring to its stability *in vivo* and the possibility of degradation of the oleic amino acid that remains in the tissue need to be resolved [14,26].

Another studied alternative is bisphosphonates, which act by blocking the growth of hydroxyapatite crystals in the bioprosthetic tissue. However, its systemic use causes adverse effects in calcium metabolism of the bones making them weak [27].

It has been demonstrated that, when bisphosphonates are subcutaneously implanted in rats together with porcine valve leaflets, the slow and local release inhibits calcification, without the adverse effects observed with systemic use [27].

Ethano-hydroxy-bisphosphonates and  $\text{FeCl}_3$  demonstrated synergic effects in inhibiting calcification of segments of rats' aortic wall implanted in animals of the same species.

However, the use of controlled systemic release of these agents was less effective to prevent calcium deposits in porcine aortic prostheses [14].

Aluminum is associated to osteomalacia in patients maintained on renal dialysis. Thus, studies have been performed using metallic salts containing  $\text{Al}^{3+}$  and  $\text{Fe}^{3+}$ , with the aim of preventing calcification.

Porcine aortic cusps were incubated in these trivalent metallic ions and marked anticalcification action was observed in implantations, even at low concentrations [28]. Morphological studies of the bioprosthetic tissues pretreated with aluminum and iron hydrochloride revealed that  $\text{Al}^{3+}$  and  $\text{Fe}^{3+}$  are responsible for cellular revitalization [28].

Even with differences between the profile of human lipoproteins and those of rats and sheep, which demonstrate diversity in the calcium metabolism, valve and cardiovascular diseases are seen in these species. However, microscopy and ultrastructural pathologic studies indicate that the clinical material and animal model are comparable [29].

Vyavahare et al. [14] studied the effects of several concentrations of ethanol and showed that at 80% it inhibits calcification of aortic cusps implanted in the subcutaneous tissue of rats or as a mitral valve replacement in the circulation system of sheep.

They believe that extraction of cholesterol and

phospholipids is the main mechanism of its anticalcification action, although there are other factors that can influence mineralization of the bioprosthetic tissue.

Yoshioka et al. [30] demonstrated that the reaction of reticulation of collagen matrixes by means of diacetals of GDA leads to a greater biological stability of the tissues and less post-implantation toxicity.

The aim of the current study was to see if ethanol – that had been so efficient as an anticalcification agent in porcine cusps and subcutaneous implants in rats – presented with a similar action in the circulatory system of young sheep. With this in mind, the findings of this study using 80% ethanol were compared with the results of Vyavahare et al. [14] obtained using other concentrations with porcine aortic cusps.

The data of this work, with the amount of the calcium found in porcine pulmonary cusps treated with 80% ethanol implanted over 210 days in the right ventricle outflow tract of young sheep, demonstrated significant inhibition of calcification. The measured values were similar to those of Vyavahare et al. [14, 19].

On macroscopically investigating the calcification of pulmonary heterograft walls, there was less calcification in porcine pulmonary valve heterografts treated with ethanol.

As to the echocardiographic analysis, we cannot compare with other works because we did not find any similar studies.

With these findings we see a future possibility, after a longer period of observation and analysis, of using these heterografts in humans, specifically in young patients, with the goal of reducing the number of reoperations due to valve failure caused by calcification of heterografts.

Ethanol, which is cheap and easy to find, may provide an alternative in the manufacture of biological prostheses, in particular in underdeveloped countries, where there is the higher rate of young patients with valve diseases requiring replacement.

Another great advantage in relation to hemodynamics, would be the utilization of stentless porcine pulmonary heterografts, as, apart from giving close to normal transvalvar gradients, they would have a greater durability as the stress would be reduced with the removal of the rings and frames of “stented” bioprostheses from the vessel lumen.

But, even with all the advantages that this treatment can provide, further studies over longer observational periods and with larger samples are necessary to establish this treatment definitely.

## CONCLUSION

From an analysis of the calcification prevention method (80% ethanol) in cusps of the porcine pulmonary valve



heterograft implanted in the right ventricle outflow tract of young sheep over 210 days, it was concluded that:

80% Ethanol inhibits calcification of the cusps over this period, but does not inhibit calcification of the wall of the porcine pulmonary valve heterograft, when compared with GDA.

#### REFERENCES

1. Schoen FJ, Levy RJ, Piehler HR. Pathological considerations in replacement cardiac valves. *Cardiovasc Pathol.* 1992;1:29-52.
2. Lee CH, Vyavahare N, Zand R, Kruth H, Schoen FJ, Bianco R et al. Inhibition of aortic wall calcification in bioprosthetic heart valves by ethanol pretreatment: biochemical and biophysical mechanisms. *J Biomed Mater Res.* 1998;42(1):30-7.
3. Pathak CP, Adams AK, Simpson T, Phillips RE Jr, Moore MA. Treatment of bioprosthetic heart valve tissue with long chain alcohol solution to lower calcification potential. *J Biomed Mater Res.* 2004;69(1):140-4.
4. Schoen FJ, Levy RJ. Founder's Award, 25th Annual Meeting of the Society for Biomaterials, perspectives. Providence, RI, April 28-May 2, 1999. Tissue heart valves: current challenges and future research perspectives. *J Biomed Mater Res.* 1999;47(4):439-65.
5. Cosgrove DM. Valve reconstruction versus valve replacement: current heart valve prostheses. In: Crawford FA, editor. *Cardiac surgery.* 1987.
6. Gott JP, Pan-Chic, Dorsey LM, Jay JL, Jett GK, Schoen FJ et al. Calcification of porcine valves: a successful new method of antiminerallization. *Ann Thorac Surg.* 1992;53(2):207-16.
7. Ross DN. Homograft replacement of the aortic valve. *Lancet.* 1962;2:487.
8. Ionescu MI, Wooler GH, Smith DR, Grinshaw VA. Mitral valve replacement with aortic heterografts in humans. *Thorax.* 1967;22(4):305-13.
9. Braile DM et al. Experiência inicial com emprego das próteses de LILLEHEI-KASTER. *Arq Bras Cardiol.* 1974;27(supl.1):14.
10. Moraes CR, Arruda MB, Cavalcanti IL, Victor EG, Lira V. Substituição das válvulas do coração por fascia lata autógena. Técnica e resultados preliminares. *Arq Bras Cardiol.* 1970;23(6):401-6.
11. Puig LB, Verginelli G. Válvulas cardíacas de dura-máter homóloga. Nota prévia. *Rev Paul Med.* 1971;78(1):33-5.
12. Carpentier A, Blondeau P, Laurens P, Mancel P, Laurent D, Dubost C. Remplacement des valvules mitrales et des cuspidés par le tégument homogéne. *Ann Chir Thorac Cardiovasc.* 1968;7(1):33-8.
13. Potkin BN, McIntosh CL, Cannon RO 3rd, Roberts WC. Bioprostheses in tricuspid and mitral valve positions for 100 months with heavier calcific deposits on the left-sided valve followed by new bioprostheses in both positions for 95 months with heavier calcific deposits on the right-sided valve. *Am J Cardiol.* 1988;61(11):947-9.
14. Vyavahare N, Hirsch D, Lerner E, Baskin JZ, Schoen FJ, Bianco R et al. Prevention of bioprosthetic heart valve calcification by ethanol preincubation: efficacy and mechanisms. *Circulation.* 1997;95(2):479-88.
15. Barratt-Boyes BG. Homograft aortic valve replacement in aortic incompetence and stenosis. *Thorax.* 1964;19:131-50.
16. Carpentier A, Nashef A, Carpentier S, Ahmed A, Goussef N. Techniques for prevention of calcification of valvular bioprostheses. *Circulation.* 1984;70(3 pt 2):I165-8.
17. Aupart MR, Sirinelli AL, Diemont FF, Meurisse YA, Dreyfus XB, Marchand MA. The last generation of pericardial valves in the aortic position: ten years follow up in 589 patients. *Ann Thorac Surg.* 1996;61(2):615-20.
18. Grunkemeier GL, Bodnar E. Comparative assessment of bioprosthesis durability in the aortic position. *J Heart Valve Dis.* 1995;4(1):49-55.
19. Vyavahare NR, Jones PL, Hirsch D, Schoen FJ, Levy RJ. Prevention of glutaraldehyde - fixed bioprosthetic heart valve calcification by alcohol pretreatment: further mechanistic studies. *J Heart Valve Dis.* 2000;9(4):561-6.
20. Soncini da Rosa GR, Costa FDA, Mesquita L, Costa ISEA. Estudo comparativo da eficácia do etanol e ácido L-glutâmico na prevenção da calcificação das cúspides e parede aórtica porcina: estudo experimental em ratos. *Rev Bras Cir Cardiovasc.* 2002;17(2):40-51.
21. International Committee on Veterinary Gross Anatomical Nomenclature. *Nomina anatomica veterinaria.* 3rd ed. New York: ITHACA; 1983.
22. Shen M, Kara-Mostefa A, Chen L, Daudon M, Thevenin M, Lacour B et al. Effect of ethanol and ether in the prevention of calcification of bioprostheses. *Ann Thorac Surg.* 2001;71(5 suppl):S413-6.
23. Grunkemeier GL, Jamieson WR, Miller DC, Starr A. Actuarial versus actual risk of porcine structural valve deterioration. *J Thorac Cardiovasc Surg.* 1994;108(4):709-18.

- 
24. Milano A, Guglielmi C, De Carlo M, Di Gregorio O, Borzoni G, Verunelli F et al. Valve-related complications in elderly patients with biological and mechanical aortic valves. *Ann Thorac Surg.* 1998;66(6 suppl):S82-7.
  25. Schoen FJ, Harasaki H, Kim KM, Anderson HC, Levy RJ. Biomaterial-associated calcification: pathology, mechanisms, and strategies for prevention. *J Biomed Mater Res.* 1988;22(A1 suppl):11-36.
  26. Chen W, Schoen FJ, Levy RJ. Mechanism of efficacy of 2-amino oleic acid for inhibition of calcification of glutaraldehyde-pretreated porcine bioprosthetic heart valves. *Circulation.* 1994;90(1):323-9.
  27. Levy RJ, Schoen FJ, Lund SA, Smith MS. Prevention of leaflet calcification of bioprosthetic heart valves with diphosphonate injection therapy: experimental studies of optimal dosages and therapeutic durations. *J Thorac Cardiovasc Surg.* 1987;94(4):551-7.
  28. Golomb G, Ezra V. Prevention of bioprosthetic heart valve tissue calcification by charge modification: effects of protamine binding by formaldehyde. *J Biomed Mater Res.* 1991;25(1):85-98.
  29. Schoen FJ, Hirsch D, Bianco RW, Levy RJ. Onset and progression of calcification in porcine aortic bioprosthetic valves implanted as orthotopic mitral valve replacements in juvenile sheep. *J Thorac Cardiovasc Surg.* 1994;108(5):880-7.
  30. Yoshioka SA, Braile DM, Ramirez V, Goissis G. Reticulação de matrizes colagênicas com diacetais de glutaraldeído para a preparação de novos biomateriais. *Polímeros: Ciência e Tecnologia.* 1995;Out/Dez :39-47.