

Giant pericardial cyst: case report

Cisto pericárdico gigante: relato de caso

Vinicius José da Silva NINA¹, Norman Colina Eduardo MANZANO², Vinícius Giuliano Gonçalves MENDES³, Natalino SALGADO FILHO⁴

RBCCV 44205-912

Abstract

Pericardial cysts are uncommon congenital abnormalities. Most are asymptomatic and are found incidentally on chest roentgenograms. Giant cysts are an even more uncommon finding, and reports of their natural history, presentation and management are few. In this report the authors describe a case of a giant pericardial cyst with symptoms of mediastinal compression for which the surgical excision guaranteed a 12-month follow-up of complete remission of the symptomatology.

Descriptors: Pericardium, pathology. Mediastinal cyst, surgery. Constriction, pathologic, complications.

Resumo

Os cistos pericárdicos são anomalias congênitas incomuns, sendo a maioria assintomática e diagnosticadas incidentalmente na radiografia de tórax. Os cistos gigantes são raros, havendo poucos relatos concernentes à sua história natural, apresentação clínica e tratamento. No presente relato, os autores descrevem um caso de cisto pericárdico gigante, com sintomatologia compressiva importante, cuja excisão cirúrgica garantiu completa remissão sintomatológica no seguimento de 12 meses.

Descritores: Pericárdio, patologia. Cisto mediastínico, cirurgia. Constrição patológica, cirurgia.

1. PhD; Chief of Heart Surgery Service University Hospital – Federal University of Maranhão.

2. Heart Surgery Resident.

3. Medicine scholar.

4. PhD; General Manager of Hospital Universitário da UFMA.

Work performed at the Heart Surgery Service - University Hospital – Federal University of Maranhão – São Luiz, MA, Brazil

Corresponding author:

Vinicius José da Silva. Nina Rua Matos Carvalho, 28 - Olho D'Água - São Luís – MA - CEP: 65065-270

Tel:(5598) 3226-1099 Fax: (5598) 3232-8700.

E-mail: rvnina@terra.com.br

Article received in May 12th, 2007

Article accepted in July 20th, 2007

INTRODUCTION

Pericardial cysts are caused by an incomplete coalescence of fetal lacunae during the development of the pericardium [1]. The estimated incidence of pericardial cyst is 1:100,000 and it is responsible for 6% to 7% of mediastinal masses reported in the literature [2]. They are typically unilocular, are lined by endothelium or mesothelium, contain clear serous fluid. These cysts do not communicate with the pericardial space and they are asymptomatic in more than 50% of the cases. Usually, they are more likely to occur in middle-aged adults, most frequently in the third or fourth decade of life, and equally among men and women. The occurrence of pericardial cysts in children is rare. Chest pain, Dyspnea, or paroxysmal tachypnea, are symptoms found in 25% to 30% of the patients [1, 2]. The most common finding on roentgenograms is a round homogeneous radiodense lesion at the cardiophrenic angle, two thirds being found on the right [3]. These finds are enough to the diagnostic but confirmation may be obtained by two-dimensional echocardiography, computed tomography, or nuclear magnetic resonance (NMR) [1-3]. The aim of the present case report is to describe a case of a successful surgical excision of a giant pericardial cyst.

CASE REPORT

A 46-year-old female presented with a 6-month history of progressive exertional dyspnea, right-sided chest pain, and dry cough was admitted to our service in a good general condition, conscious, eupneic breathing, acyanotic, normal colored, anicteric, and afebrile. Cardiovascular examinations showed a regular heartbeat with normal heart sounds and without murmurs. The heart frequency was 82 bpm and the blood pressure was 110/70 mmHg. The vesicular murmur was absent on the lower two thirds of the right hemithorax on pulmonary auscultation.

Chest roentgenography showed atelectasis of the middle and inferior lobes of the right lung.

The results of the echocardiogram suggested pericardial cyst which was confirmed by both CT scan of the thorax and the nuclear magnetic resonance, which showed a cyst formation measuring 13 x 9.5 cm (Figure 1).

In view of the clinical picture of the patient and the complementary exams, a surgical treatment was indicated.

After free, written informed consent was obtained, a right-sided thoracotomy was performed with a complete excision of the mediastinal mass measuring 14 x 10 x 0.3 cm (Figure 2). The cyst was filled by a straw-colored fluid (golden yellow fluid), and adherent to the lung, phrenic and anterior vagus nerves laterally, and to the esophagus, posteriorly. The procedure was concluded in the usual manner after a closed drainage (water-sealed drainage) of

the thoracic cavity was performed. There were not any postoperative events. The patient was discharged on the fifth postoperative day.

In a 12-month outpatient follow-up, the patient evolved with complete remission of the symptoms in functional class I (NYHA) and without imaging evidence of the recurrence of the mediastinal mass.

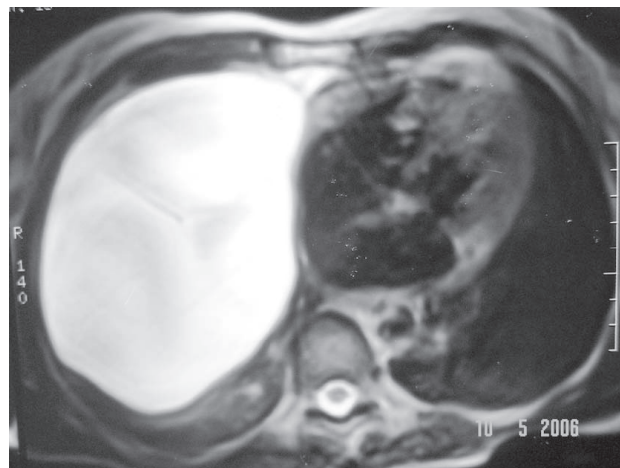


Fig. 1 – Nuclear Magnetic Resonance: thin-walled enlarged cyst abutting the right border of heart

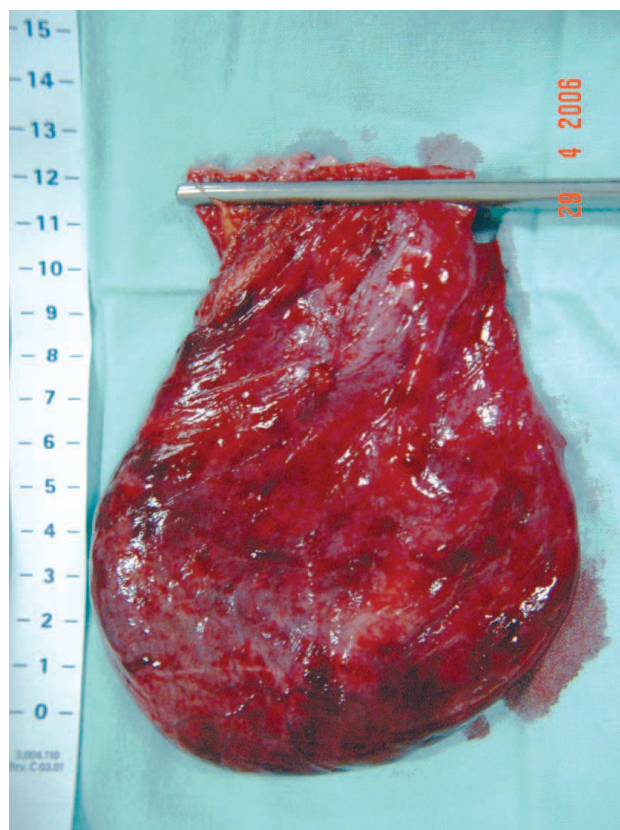


Fig. 2 – Macroscopic appearance of a giant pericardial cyst

Biochemistry and histopathologic analysis

The diagnosis of transudate was confirmed by biochemistry examination. The histopathologic examination was consistent with the diagnosis of pericardial cyst evidenced by the presence of a single layer of cuboidal/column cells interspersed by fibrous tissue, fat, and vessels.

DISCUSSION

Congenital pericardial cysts are uncommon; they may be unilocular or multilocular, with the diameter from 1 to 5 cm [4]. In the present case, the pericardial cyst was multilocular, with the diameter of 10 cm, making it a yet more rare entity.

The differential diagnosis should take into consideration solid tumors, which includes angioma, lipoma, neurogenic tumor, sarcoma, lymphoma, bronchogenic carcinoma, metastasis, granulomatous lesion, and abscess. Other cysts should be differentiated, such as interstitial bronchogenic cyst and lymphangiomas, besides other diseases, such as diaphragmatic hernia, and aneurysms of the heart or great vessels aneurysms [2, 3].

The most usual radiographic appearance of the pericardial cysts is a well-defined, smooth-walled round mass located along the right border of heart. However, the diagnosis can be especially difficult when the lesion occur outside their typical location at the right cardiophrenic angle; or more rarely, as in the case reported here, in which the lesion was extensive and confluent with mediastinal structures, and followed by symptomatology [1, 3].

Echocardiography is useful to establish the diagnosis, however, computed tomography and nuclear magnetic resonance are often needed to differentiate the pericardial cyst from the solid mediastinal mass [2, 4]. However, the definite diagnosis is only consolidated through the anatomopathologic exam as described by the authors in this case.

The majority of the pericardial cysts are often asymptomatic. Occasionally, they can alter the cardiovascular hemodynamics and/or the pulmonary

expansion producing signs and symptoms that can mimic tricuspid stenosis, pulmonary stenosis, or constrictive pericarditis [3, 4]. In the present case report, the compression of the mediastinal structures typically caused the symptoms of dyspnea, thoracic pain, and cough due to the unusual large size of the cyst.

The treatment for congenital and inflammatory cysts is percutaneous aspiration and ethanol sclerosis. Is this is not feasible, video assisted thoracotomy or surgical resection may be necessary, especially in the symptomatic patients with cardiorespiratory repercussions, as described in the present case [4].

Therefore, surgical excision becomes mandatory when pericardial cysts with compressive characteristics cause ventilatory and/or hemodynamic impairment. Asymptomatic patients with pericardial cysts should be managed conservatively; once the periodic long-term follow-up has been shown that these patients remained symptom-free [1, 4].

REFERENCES

1. Satur CM, Hsin MK, Dussek JE. Giant pericardial cysts. *Ann Thorac Surg.* 1996;61(1):208-10.
2. Caramori JE, Miozzo L, Formigheri M, Barcellos C, Grando M, Trentin T. Dispneia por compressão de estruturas mediastinais por cisto pericárdico. *Arq Bras Cardiol.* 2005;84(6):486-7.
3. Carvalho ACP, Beze RS, Neves Filho AF. Cisto pericárdico: uma apresentação incomum. *Radiol Bras.* 2001;34(1):57-8.
4. Maisch B, Seferovic PM, Ristic AD, Erbel R, Rienmüller R, Adler Y, et al. Guidelines on the diagnosis and management of pericardial diseases executive summary. The Task force on the diagnosis and management of pericardial diseases of the European Society of Cardiology. *Eur Heart J.* 2004;25(7):587-610.