

# Cardiac surgery of emergency for resection of left atrial myxoma

## *Cirurgia cardíaca de emergência para ressecção de mixoma atrial esquerdo*

Antônio Augusto Ramalho MOTTA<sup>1</sup>, Eloi COLEN FILHO<sup>2</sup>, Márcio Fernando BORGES<sup>3</sup>, Eloizio Aparecido COLEN<sup>4</sup>

RBCCV 44205-988

### **Abstract**

We report case of a female patient who, over a series of months, presented pulmonary manifestation associated with nonspecific systemic symptoms and resulting in several hospitalizations with the diagnostic hypothesis of pulmonary fibrosis until the completion of an echocardiographic study that showed a large pedunculated left atrial myxoma prolapsing through the mitral valve for the left ventricle. In quite unfavorable clinical conditions, the patient was sent to our Service for surgical treatment, evolving during the preparation for surgery with acute pulmonary edema and hemodynamic instability and being submitted to a successfully surgery of emergency for resection of the tumor. The patient is asymptomatic.

**Descriptors:** Myxoma. Heart neoplasms. Heart atria.

### **Resumo**

É descrito caso de paciente do sexo feminino que apresentava manifestações pulmonares e sistêmicas inespecíficas há vários meses, as quais resultaram em várias internações hospitalares com a hipótese diagnóstica de fibrose pulmonar. Estudo ecocardiográfico evidenciou a presença de grande mixoma pediculado no átrio esquerdo, que prolapsava, através da valva mitral, para o ventrículo esquerdo. Em condições clínicas bastante desfavoráveis, a paciente foi encaminhada ao nosso Serviço para tratamento cirúrgico, evoluindo durante o preparo pré-operatório com edema agudo pulmonar e instabilidade hemodinâmica, sendo submetida a cirurgia de emergência, com sucesso, para ressecção da tumorção. A paciente encontra-se assintomática.

**Descritores:** Mixoma. Neoplasias cardíacas. Átrios do coração.

1. Cardiovascular surgery specialist
2. Cardiovascular surgeon
3. Cardiologist
4. Cardiovascular surgeon

This study was carried out at the Albert Sabin Hospital – Juiz de Fora - MG

Correspondence address:

Antônio Augusto Ramalho Motta Av. Rio Branco, 2900 / 1101 - Centro CEP: 36016 - 311 - Juiz de Fora - MG - Brazil. Phone: (32) 32116001 / Fax: (32) 32143100.  
E-mail: ramalho@terra.com.br

Article received on December 28<sup>th</sup>, 2007

Article accepted on May 9<sup>th</sup>, 2007

## INTRODUCTION

Primary pericardium and heart tumors are somewhat frequent, presenting in a series of autopsies, with incidence between 0,001% to 0,2%, and with histological benign characteristics in 75% of the cases, corresponding to myxomas in approximately 50% of these neoplasms [1]. Cardiac myxoma is predominately located in the left atrium, developing into cardiovascular repercussion associated with nonspecific systemic manifestations that may make the diagnosis of this neoplasm difficult, resulting in its evolution and increasing the risk of serious complications, including embolic accidents and death [2]. Early diagnosis and surgical treatment improve the prognosis of the patients with these tumors [1,3].

In this study, we present a case of a patient who has undergone emergency surgery for resection of the left atrial myxoma after developed with acute pulmonary edema and hemodynamic instability, showing the unfavorable development of this tumor and the importance of its early diagnosis and treatment.

## CASE REPORT

48-year female patient, Caucasian, presenting general uneasiness, adynamia, anorexia, weight loss, fatigue, nonproductive cough and progressive dyspnea, with approximately 8 months of development. The patient had already been hospitalized several times. The chest teleradiography and computed tomography suggested diffuse interstitial pneumopathy that correlated with the pulmonary manifestations that led to the diagnosis of pulmonary fibrosis, and that were also the reason for the patient's use of corticosteroid and bronchodilators.

After a lack of response to the recommended treatment and the acute worsening of the general health of the patient, a cardiological evaluation was requested, and a two-dimensional echocardiogram was performed, which showed the presence of large pediculated tumor in the left atrial cavity - likely myxoma - that was prolapsed through the mitral valve towards the left ventricle. There were also signs of mild pulmonary arterial hypertension (Figure 1).

The patient was hospitalized again presenting heart failure, was unresponsive to clinical treatment, and was referred to the Cardiac Surgery Service 30 days after the diagnosis of intracardiac myxoma. Upon admission, the patient presented a significantly compromised general health, as well as adynamia, anorexia, dyspnea during efforts (or, sometimes at rest) and epigastric pain with nausea, vomiting and heartburn for weeks. During physical examination, the patient was afebrile, pale, and with an acute weight deficit (weighing 43kg); mildly dyspneic and with

slight edema of the lower limbs. Heartbeat was 96bpm and blood pressure was 100 x 70mmHg. At cardiac auscultation a "tumor plop" was found: pulmonary auscultation with crepitant rales in both pulmonary bases. The electrocardiogram presented regular sinus rhythm and the chest teleradiography showed diffuse infiltration in both lungs (Figure 2).

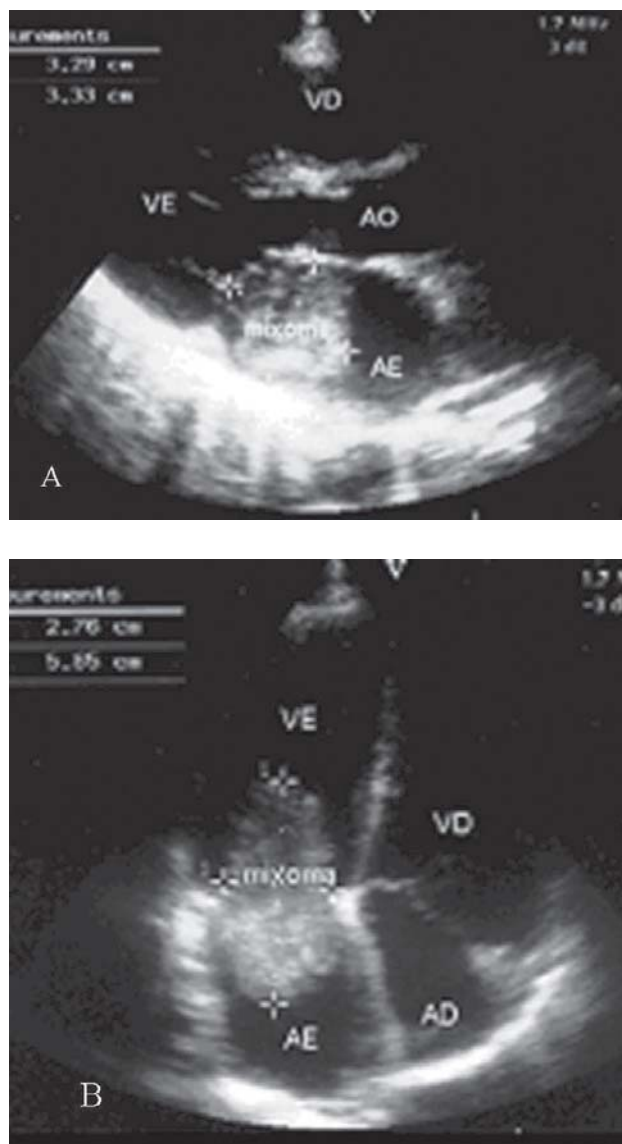


Fig. 1 - Transthoracic echocardiogram. A - Preoperative. B - Atrial tumor prolapse through the mitral valve toward the left ventricle during ventricular diastole

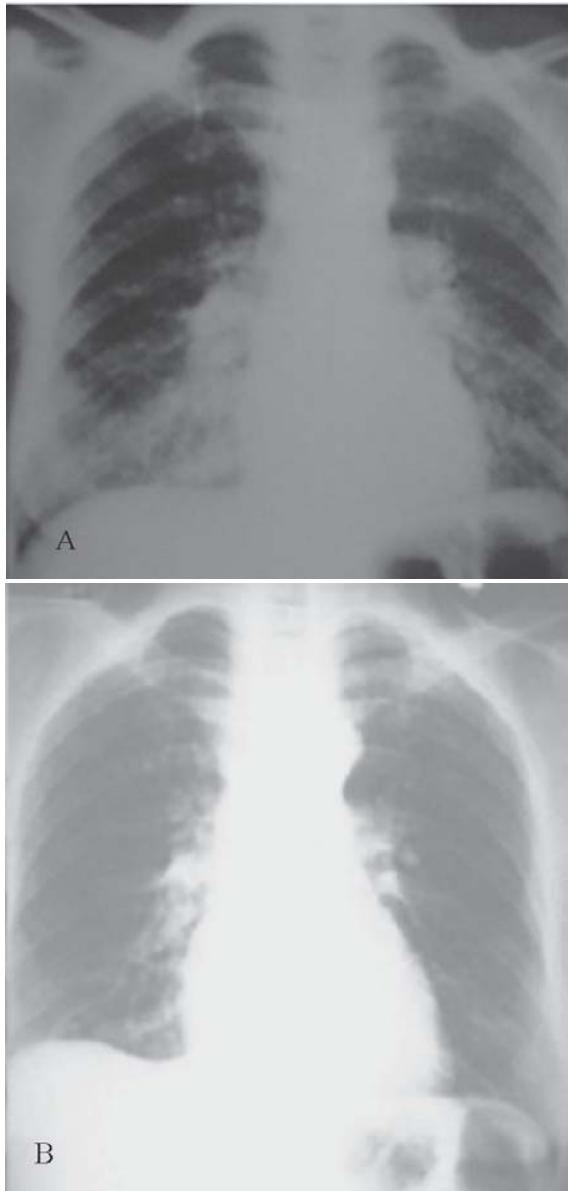

Fig. 2 – Chest teleradiography. A - Preoperative: bilateral pulmonary infiltrates. B – Postoperative control: normal radiological pattern

The routine laboratory examinations showed anemia (hemoglobin: 9.9 g% and hematocrit: 30%), hypoproteinemia (albumin: 2.3g/dl), urea: 51 mg/dl and prothrombin activity of 55%. The patient improved with the use of clinical treatment, therefore allowing for a more adequate preparation for clinical conditions, with the goal of a surgical procedure. However, on the day before the surgery (the third postoperative day), the patient developed

acute pulmonary edema and hemodynamic instability, and needed imperative emergency surgery.

The surgery was performed using median longitudinal sternotomy with installation of cardiopulmonary bypass circuit after heparinization (4mg/kg), equipped with membrane oxygenator (Braile Biomédica S/A, São José do Rio Preto-SP), through the cannulation of the ascending aorta and superior and inferior vena cavae. In this study, we used mild systemic hypothermia (32°C) and a hyperkalemic and hypothermic intermittent cardioplegic blood solution using antegrade infusion to protect the myocardium. The tumor was accessed bilaterally.

After the large pediculated tumor in the left atrium attached to the posterior wall and together with the left pulmonary veins was visible, it was removed en bloc from its base through the left atrium with large margin of safety. This was followed by the reconstruction of the atrial wall and exploration of atrial and ventricular cavities. Left pleurotomy and a lung biopsy were performed. After the heartbeat was stabilized, cardiopulmonary bypass was interrupted, and protamine chloride was used for the neutralization of heparin. After hemostasis review and placement of mediastinal and left pleural drains, the incision was closed by anatomical planes. The surgery was successfully performed. In macroscopic analysis in the operating room, the tumor was lobulated, with a smooth surface and a brownish color, and measuring approximately 7.0 x 5.0 x 3.0cm (Figure 3).

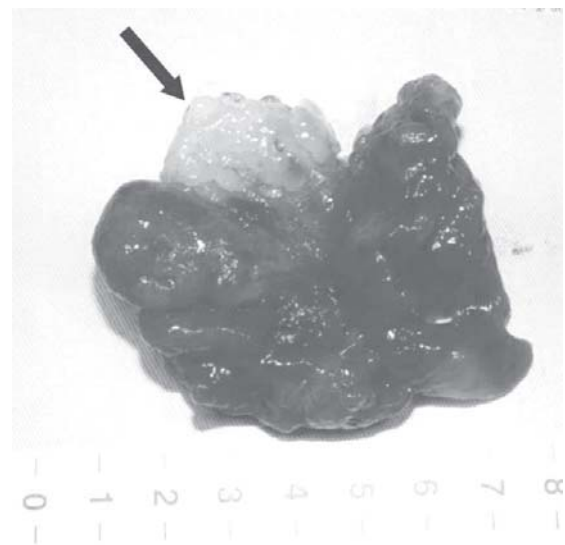


Fig. 3 - Macroscopic aspect of the left atrial myxoma. The more whitish region (arrow) corresponds to the tumor pedicle

The histopathological study of the tumor confirmed the diagnosis of myxoma; the lung biopsy showed aspects of very slight interstitial fibrosis and mild pulmonary hypertension. There were no complications in the postoperative period. The patient was discharged from hospital asymptomatic, and remained under clinical observation for a 93-month follow-up. The controlled echocardiographic studies in that same period showed no abnormalities or suggestive signs of tumor recurrence (Figure 4).

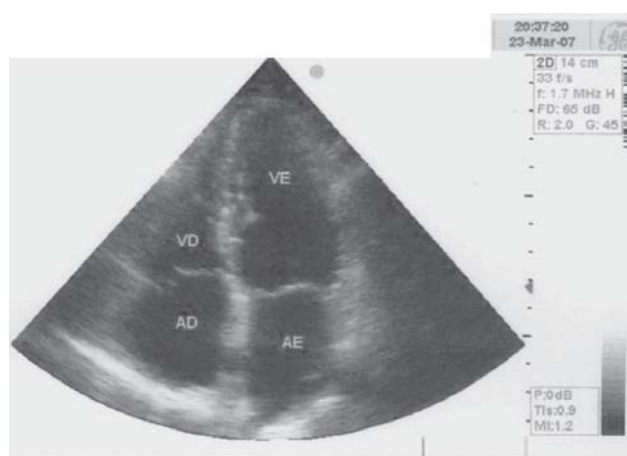


Fig. 4 – Control echocardiographic study performed 93 months after the tumor resection. Absence of suggestive signs of recurrence

## DISCUSSION

The myxomas correspond to approximately 50% of primary benign heart neoplasms and are often located in the left atrium (in the region of the oval fossa), and may also be found in the right atrium and in both ventricles. Despite their histological character, these tumors correspond with disabling complications and even death [1.4]. Myxomas have a higher occurrence in the 30-60 age group, are mainly in women, and are generally pediculated, sporadic and solitary.

In approximately 7% of cases, these tumors have common characteristics, whether or not they are part of syndromes such as NAME (nevi, atrial myxoma, myxoid neurofibroma, ephelides) LAMB (lentigo, atrial myxoma, blue nevi) or Carney's complex (skin pigmentation, fibromyxoid tumor of the skin, heart myxoma, high endocrine activity, autosomal dominant inheritance) [2,5]. The event

of recurrence of these tumors is at a rate of 3%; however, it may reach 12% in common cases and 22% in the Carney's complex [3.6].

The clinical manifestations of these tumors differ in terms of form and intensity, and are determined by their location, size and mobility [6]. These manifestations are part of a triad that includes intracardiac obstruction, embolic accidents and constitutional or unspecific systemic symptoms [3.6]. Thus, the cardiac obstruction may cause symptoms such as dyspnea, arrhythmias, precordial uneasiness, dizziness and syncope episodes, heart failure and acute pulmonary edema; the level of atrioventricular valve obstruction depends on the size of the tumor. It may change depending on the position of the body, and it may cause sudden death [3.6].

Embolic events are serious complications caused by myxomas, with occurrence ranging between 25% and 50% when located in the left atrium due to formation of thrombi or tumor fragmentation. They may involve the brain, coronary, kidney, visceral and peripheral tumors and even the abdominal aorta [3.7]. Martínez et al. also reported emergency heart surgery for myxoma resection in the left atrium, showing the diversity in clinical presentation of these tumors, which makes early diagnosis and treatment difficult [8]. Constitutional or systemic manifestations are found in more than 90% of cases and include fatigue, adynamia, myalgia, arthralgia, fever, weight loss and general uneasiness [1,6,7].

A routine laboratory evaluation may show non-specific alterations such as anaemia, increased erythrocyte sedimentation rate, increase of globulin and C-reactive protein levels, leukocytosis, thrombocytopenia and polycythemia [1.6]. Cardiac auscultation in the atrial myxomas may range in size, location, mobility, tumor prolapse (through the atrioventricular valves) and even with the position of the body (which may prevent detection of a murmur). The typical auscultation of the myxoma is known as the "tumor plop", which occurs in 15% of cases [6]. The differential diagnosis mainly involves mitral valve disease, intrinsic pneumopathy, pulmonary arterial hypertension, cerebrovascular disease, rheumatic fever, endocarditis, myocarditis and vasculitis.

Echocardiogram have a high level of success in diagnosing cardiac myxomas, with sensitivity of up to 100% when combined with transthoracic and transesophageal methods; cardiac catheterization, computed tomography and magnetic resonance also detected these tumors [2.4]. The electrocardiogram and chest telerradiography are unspecific.

Bilateral resection of left atrial myxoma has been favored for the removal (en block) of the tumor and for exploration of the cardiac cavities [7]. In a series of 11 cases of left

atrial myxoma operated in our Service -including the ones reported in this study- the tumors were large, suggesting an advanced stage of the disease.

In this study, we want to emphasize the uniquely unfavorable development of the patient. She presented constitutional or systemic manifestations for months with progressive dyspnea, which led to the diagnosis of interstitial pneumopathy until there was a detection of an atrial tumor using an echocardiogram. After the surgical removal of the tumor, and even in the postoperative period, there was regression of clinical manifestations, and the patient was discharged from the hospital asymptomatic, requiring 93 months follow-up, and confirming the relationship between the described clinical implications and the presence of tumor.

Due the fact that the cardiac myxoma presents low incidence and usually develops with cardiovascular and constitutional manifestations (generally nonspecific), it makes diagnosis difficult and postpones surgical treatment, causing a greater risk for patients. The attention to the possibility of occurrence of this disease and the performance of echocardiograms in cardiological evaluations may make the diagnosis of cardiac benign neoplasm easier. In general analysis, we can conclude, according to the results presented herein, that early diagnosis and surgical treatment (with good outcomes), improve the prognosis of patients with cardiac myxoma, and avoid serious complications and even death.

#### REFERENCES

1. Motta AAR, Colen Filho E, Colen EA, Viera JAS, Alves MAP, Borges MF, et al. Mixoma do átrio esquerdo: relato de 3 casos. *Rev Bras Cir Cardiovasc*. 1997;12(4):377-83.
2. Peters PJ, Reinhardt S. The echocardiographic evaluation of intracardiac masses: a review. *J Am Soc Echocardiogr*. 2006;19(2):230-40.
3. Reynen K. Cardiac myxomas. *N Engl J Med*. 1995;333(24):1610-7.
4. Lobo Filho JG, Sales DLS, Borges AEPP, Leitão MC. Mixoma de átrio direito com prolapso para o ventrículo direito. *Rev Bras Cir Cardiovasc*. 2006;21(2):217-20.
5. Mahilmaran A, Seshadri M, Nayar PG, Sudarsana G, Abraham KA. Familial cardiac myxoma: Carney's complex. *Tex Heart Inst J*. 2003;30(1):80-2.
6. Pinede L, Duhaut P, Loire R. Clinical presentation of left atrial cardiac myxoma. A series of 112 consecutive cases. *Medicine (Baltimore)*. 2001;80(3):159-72.
7. Ipek G, Erentug V, Bozbuga N, Polat A, Guler M, Kirali K, et al. Surgical management of cardiac myxoma. *J Card Surg*. 2005;20(3):300-4.
8. Ulecia Martínez MA, Torres Ruiz JM, Chamorro Santos CE, Moreo Herrero T. Cirugía emergente por mixoma auricular izquierdo. *Rev Esp Cardiol*. 2000;53(9):1279-80.