

Case 5/2006

Rastelli procedure with decellularized pulmonary homograft

Operação de Rastelli com homoenxerto pulmonar decelularizado

Ulisses Alexandre CROTI, Domingo Marcolino BRAILE, Ana Carolina Leiroz Ferreiro Botelho Maisano KOZAK, Lilian BEANI

RBCCV 44205-841

CLINICAL DATA

The case of a three-year 11-month white female patient, 97 cm tall and weighing 12 kg is reported. She was diagnosed as having *truncus arteriosus* at 4 months when she underwent a total correction using the Rastelli procedure with a valved cryopreserved homograft tube and closure of the interventricular shunt in another service. Six months after the correction, the infant presented with signs of congestive heart failure including dyspnea on effort, which gradually deteriorated. On this occasion the patient was in a good general state, ruddy, hydrated, dyspneic and acyanotic. Her thorax was symmetrical with *ictus cordis* at the 5th left intercostal space on the hemiclavicular line. The cardiac rhythm was regular with two clicks and systolic and diastolic murmurs of 2+/4+ at a pulmonary focus. Pulmonary auscultation was symmetrical without adventitious noises. The abdomen was flaccid at 1 cm from the right costal edge. The extremities had symmetrical palpable pulses without pressure differences among the four limbs (90/40 mmHg). The patient was taking furosemide and spiro lactone.

ELECTROCARDIOGRAM AND HOLTER MONITORING

An electrocardiogram demonstrated sinus rhythm with a heartbeat of 136 bpm. The $\hat{A}P$ was +30 and the $\hat{A}QRS$ was +120 without direct signs of atrial overload. A complete block

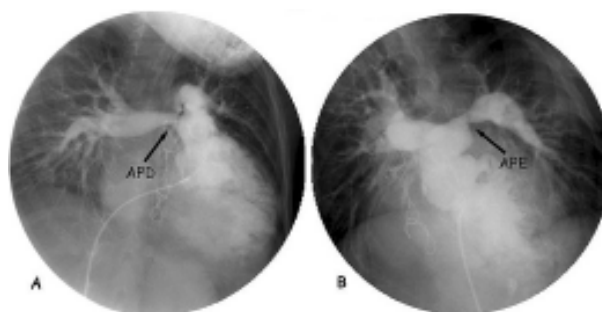


Fig. 1 - Cineangiographic study. A: stenosis at the origin of the right pulmonary artery (RPA), B: stenosis at the origin of the left pulmonary artery (LPA)

of the right branch was identified. There were ventricular repolarization alterations secondary to the block. Holter monitoring demonstrated sinus rhythm with a right branch block, a maximum heartbeat of 155 and a minimum of 73 bpm. Ventricular and supraventricular ectopias were not recorded as no symptoms were identified on the log.

Pediatric Cardiovascular Surgery Service – Hospital de Base – Medicine School in São José do Rio Preto

Correspondence address:
Ulisses Alexandre Croti
Hospital de Base – FAMERP – Avenida Brigadeiro Faria Lima, 5544
CEP 15090-000 – São José do Rio Preto – São Paulo
Phone (fax): 17 - 3201 5025 / 9772 6560
E-mail: uacroti@uol.com.br

Article received in June, 2006
Article accepted in July, 2006

RADIOGRAM

The radiogram showed visceral *Situs solitus* and a cardiothoracic index of 0.54. The middle arch was slightly bulging; there was slight peripheral hypovolemia, free diaphragmatic domes and the presence of steel threads in the sternum.

ECHOCARDIOGRAM

In the postoperative period of the Rastelli procedure and ventriculoseptoplasty. Slight tricuspid insufficiency was evidenced with significant pulmonary insufficiency, hypoplasia of the pulmonary trunk (PT) and pulmonary arteries with the right pulmonary artery (RPA) 7 mm and the left pulmonary artery (LPA) 6 mm. The gradient between the right ventricle (RV) and the pulmonary arteries was 44 mmHg.

DIAGNOSIS

The echocardiogram demonstrated dysfunction of the RV-PT homograft tube, but with overall functioning of the RV normal, an unfavorable fact for the clinical presentation. A cineangiographic study was requested which confirmed insufficiency of the tube with significant stenosis at the connection of the tube with the RPA and LPA (Figure 1). It also showed that there was no pulmonary hypertension, which was considered important for the new correction of the RV-PT connection.

OPERATION

Median transsternal thoracotomy was performed with dissection of adhesences and establishment of cardiopulmonary bypass at 25 °C. Intermittent hypothermic antegrade sanguineous cardioplegia was utilized at 20-minute intervals. Regions of significant stenosis at the origin of the RPA and LPA (Figure 2) were identified and resected. A decellularized homograft tube (Figure 3) was inserted between the pulmonary arteries and the RV using 5-0 polypropylene thread for the anastomoses. The operation was completed using a bovine pericardium patch between the homograft and the incision in the RV (Figure 4). Perfusion time was 154 minutes and the myocardial ischemia time was 125 minutes. We stress that the choice of the decellularized homograft as replacement is directly related to the possibility of better long-term results [1]. An echocardiogram performed eight months following the intervention showed slight to moderate pulmonary valve regurgitation similar to in the immediate postoperative period, without stenosis of the valve or the origin of the pulmonary arteries.

REFERENCE

1. Costa FD, Dohmen PM, Duarte D, von Glenn C, Lopes SV, Haggi Filho H et al. Immunological and echocardiographic evaluation of decellularized versus cryopreserved allografts during the Ross operation. *Eur J Cardiothorac Surg.* 2005;27(4):572-8.

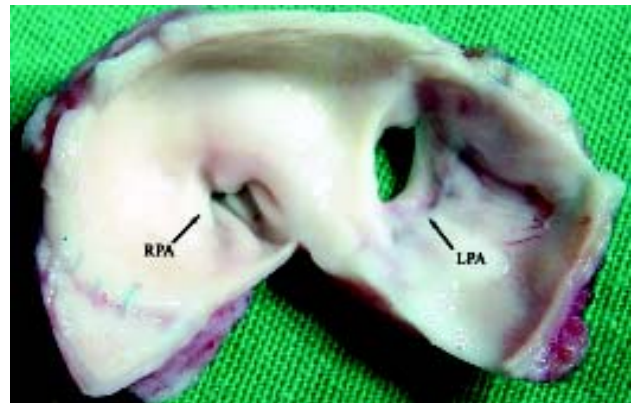


Fig. 2 – Resected tissue from the origin of the pulmonary arteries
RPA: right pulmonary artery; LPA: left pulmonary artery

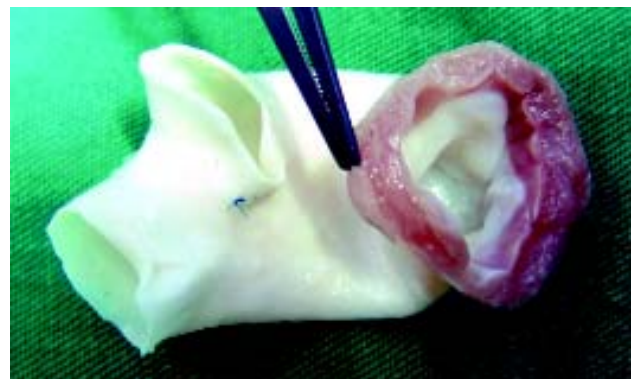


Fig. 3 – Decellularized homograft: Note the thinner and more delicate walls normally seen with cryopreserved homografts

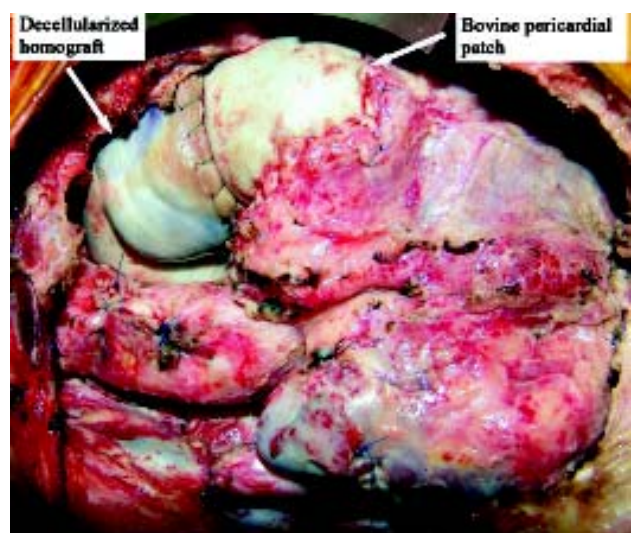


Fig. 4 – Final appearance of the implantation of the decellularized homograft completed with a bovine pericardial patch