

In vivo study of lyophilized bioprostheses: 3 month follow-up in young sheep

Estudo in vivo do comportamento de bioprótese liofilizada: seguimento de 3 meses em carneiros jovens

Fábio Papa Taniguchi¹, Marina Junko Shiotsu Maizato², Rafael Fávero Ambar³, Ronaldo Nogueira de Moraes Pitombo⁴, Adolfo Alberto Leiner⁵, Luiz Felipe Pinho Moreira⁵, Idágene Aparecida Cestari⁶, Noedir Antônio Groppo Stolf⁷

DOI: 10.5935/1678-9741.20120101

RBCCV 44205-1426

Abstract

Objective: Glutaraldehyde is currently used in bovine pericardium bioprosthesis to improve mechanical and immunogenic properties. Lyophilization is a process that may decrease aldehyde residues in the glutaraldehyde treated pericardium decreasing cytotoxicity and enhancing resistance to calcification. The aim of this study is to evaluate bioprosthetic heart valves calcification in adolescent sheep and to study the potential of lyophilization as a mechanism to protect calcification.

Methods: Two groups were evaluated: a control group in which a bovine pericardium prosthetic valve was implanted in pulmonary position and a lyophilized group in which the bovine pericardium prosthetic valve was lyophilized and further implanted. Sixteen sheeps 6 months old were submitted to the operation procedure. After 3 months the sheeps were euthanized under full anesthesia.

Results: Six animals of the control group reached 95.16 ± 3.55 days and six animals in the lyophilized group reached

91.66 ± 0.81 days of postoperative evolution. Two animals had endocarditis. Right ventricle/pulmonary artery (RV/PA) mean gradient, in the control group, at the implantation was 2.04 ± 1.56 mmHg, in the lyophilization group, the RV/PA mean gradient, at the implantation was 6.61 ± 4.03 mmHg. At the explantation it increased to 7.71 ± 3.92 mmHg and 8.24 ± 6.25 mmHg, respectively, in control and lyophilization group. The average calcium content, after 3 months, in the control group was 21.6 ± 39.12 $\mu\text{g Ca}^{+2}/\text{mg}$ dry weight, compared with an average content of 41.19 ± 46.85 $\mu\text{g Ca}^{+2}/\text{mg}$ dry weight in the lyophilization group ($P=0.662$).

Conclusion: Freeze drying of the bovine pericardium prosthesis in the pulmonary position could not demonstrate calcification mitigation over a 3 month period although decreased inflammatory infiltration over the tissue.

Descriptors: Animal experimentation. Bioprosthesis. Cardiac surgical procedures. Freeze drying.

1. State Civil Servants Hospital - IAMSPE; Postgraduate Doctor of Thoracic and Cardiovascular Surgery - USP, São Paulo, SP, Brazil.

2. Heart Institute - HCFMUSP; PhD in Engineering - UNICAMP, São Paulo, SP, Brazil.

3. State Civil Servants Hospital - IAMSPE; Resident in General Surgery, São Paulo, SP, Brazil.

4. School of Chemistry - University of São Paulo; Professor, São Paulo, SP, Brazil.

5. Heart Institute - HCFMUSP; Tenured Professor, São Paulo, SP, Brazil.

6. Heart Institute - HCFMUSP; PhD in Biological Sciences from UNIFESP, São Paulo, SP, Brazil.

7. Heart Institute - HCFMUSP; Emeritus Professor of Cardiovascular Surgery, São Paulo, SP, Brazil.

Work performed at the Heart Institute - HCFMUSP, São Paulo, SP, Brazil.

Correspondence address

Fábio P. Taniguchi

202 Itapeva Street - Block 91 - Sao Paulo, SP, Brazil - Zip code: 01332-001

E-mail: taniguchi@sbccv.org.br

Support: FAPESP (process no 04/0566-8)

Article received on May 8th, 2012

Article approved on August 27th, 2012

Abbreviations, acronyms and symbols	
LBPB	Lyophilized bovine pericardial bioprosthesis
ECC	Extracorporeal circulation
IC	Interatrial communication
SPSS	Statistical Package for the Social Sciences
ACT	Activated clotting time
RV	Right ventricle
RV/PA	Right ventricle / Pulmonary artery

Resumo

Objetivo: Para melhorar as propriedades mecânicas e imunogênicas, o glutaraldeído é utilizado no tratamento do pericárdio bovino que é utilizado em biopróteses. A liofilização do pericárdio bovino tratado com glutaraldeído diminui os radicais aldeído, com provável redução do potencial para calcificação. O objetivo deste estudo é avaliar os efeitos da liofilização em biopróteses valvares de pericárdio bovino como mecanismo protetor na diminuição da disfunção estrutural valvar.

Métodos: Foi realizado o implante de biopróteses de pericárdio bovino tratado com glutaraldeído, liofilizadas

ou não, em carneiros de 6 meses de idade, sendo os animais eutanasiados com 3 meses de seguimento. As biopróteses foram implantadas em posição pulmonar, com auxílio de circulação extracorpórea. Um grupo controle e outro grupo liofilizado foram avaliados quanto ao gradiente ventrículo direito/artéria pulmonar (VD/AP) no implante e explante; análise quantitativa de cálcio; inflamação; trombose e pannus. O nível de significância estabelecido foi de 5%.

Resultados: O gradiente médio VD/AP, no grupo controle, no implante, foi $2,04 \pm 1,56$ mmHg e, no grupo de liofilização, foi $6,61 \pm 4,03$ mmHg. No explante, esse gradiente aumentou para $7,71 \pm 3,92$ mmHg e $8,24 \pm 6,2$ mmHg, respectivamente, nos grupos controle e liofilização. O teor de cálcio médio, após 3 meses, nas biopróteses do grupo controle foi $21,6 \pm 39,12$ $\mu\text{g Ca}^{+2}/\text{mg}$ de peso seco, em comparação com um teor médio de $41,19 \pm 46,85$ $\mu\text{g Ca}^{+2}/\text{mg}$ de peso seco no grupo liofilizado ($P = 0,662$).

Conclusão: A liofilização de próteses valvares com pericárdio bovino tratado com glutaraldeído não demonstrou diminuição da calcificação neste experimento.

Descritores: Experimentação animal. Bioprótese. Procedimentos cirúrgicos cardíacos. Liofilização.

INTRODUCTION

The prostheses are used in cardiovascular surgery for being viable alternatives in the treatment of heart valve dysfunction when they present significant functional and morphological dysfunction. Bioprostheses must provide long-lasting performance in the role, but the structural valvular dysfunction can occur precociously due to the calcification of the biological tissues [1-3].

The need for reoperation for structural valve dysfunction has been less than 5% in 5 years; less than 10% in 10 years and over 70% in 15 years. When this structural dysfunction occurs, it is necessary to replace the bioprosthesis, with increased surgical morbimortality [1,4,5].

Lyophilization is a process of drying a previously frozen product where the solvent is removed by sublimation. Through this process high quality dehydrated products can be obtained, preserving their structure and minimizing loss of volatiles products that are not observed during drying by conventional means.

Lyophilized biological tissues for implantation in animals and humans have already been used. In the 1960s, lyophilized aortic valve heterografts were used, but the results were unfavorable [6,7].

Previous works from our group with the annealing protocol showed that the lyophilization process does not significantly alter the mechanical characteristics of bovine pericardium treated with glutaraldehyde [8], but significantly decreases the amount of residual aldehydes that the cytotoxicity relate to inflammatory processes and tissue calcification [9].

We designed a protocol in which bovine pericardial bioprostheses treated with glutaraldehyde were lyophilized and implanted in chronic animal model. The implant was performed in young sheeps, because it is known that this model allows the study of biological processes inherent to calcification and consequent structural valve dysfunction after some months after implantation [10].

The objective of this study is to evaluate the effects of annealing lyophilized in bovine pericardial bioprostheses treated with glutaraldehyde in chronic animal model.

METHODS

All animals used in this study were treated according to the "Guide for the Care and Use of Laboratory Animals" published by the National Institute of Health (NIH publication 85-23, revised 1996). Ethics Committee Heart Institute, University of São Paulo approved the study (protocol 994/05).

Definition of groups

Two groups were formed. The first one was called control group, in which a bovine pericardial bioprosthesis (Braile Biomédica, São José do Rio Preto, Brazil) was implemented, and the other group was called lyophilized bovine pericardial bioprosthesis (LBPB), in which a bovine pericardial bioprosthesis (Braile Biomédica, São José do Rio Preto, Brazil) was lyophilized and subsequently implanted.

Lyophilized bovine pericardial bioprosthesis (LBPB)

Initially, the biological prosthesis was rinsed in saline solution to remove all the aldehyde. The bioprosthesis was lyophilized in a FTS Systems TDS-00209-A Model (Dura-Stop, Dura-Dry-MP, FTS Systems, Stone Ridge, NY, USA). The freezing process was initiated by placing the bioprosthesis in a ultrafreezer for 2 hours at -50°C . After that, it was heated back to 20°C for 1 hour.

Finally, the prostheses were cooled to -50°C and lyophilized. The primary drying was performed at -5°C at atmospheric pressure of 160 mTorr. For the secondary drying, the temperature was raised to 25°C in the same atmospheric pressure.

Surgical implant

We used Santa Inês sheep in this study. Sixteen lambs with 6 months of age and an average weight of 36.53 ± 3.42 kg (ranging from 28.5 kg to 42 kg) underwent the procedure successfully.

Anesthesia

The animals were fasted for 36 hours. Anesthesia was induced with ketamine (8 mg / kg) and Midazolam (0.5 mg / kg). Isoflurane and fentanyl (5 mg / kg) were used for maintenance of anesthesia. In induction, cefuroxime (750 mg) was administered intravenously as antibiotic prophylaxis.

Extracorporeal Circulation (ECC)

The ECC circuit was filled with 400 ml of Lactated Ringer's solution, 50 ml of 20% mannitol, 10 mL of 10% calcium gluconate, 10 mL of 10% magnesium sulfate, 500 mg of hydrocortisone, 750 mg of cefuroxime and 5000 IU heparin.

Normothermia at 36°C was used during circulation with non-pulsatile blood flow of 2.4 L/min/m² with a centrifugal pump (FlowPump 6000S, IBC, Austin, Texas, USA) to maintain perfusion pressure 60 to 80 mmHg. A set of tubes, a venous blood reservoir and arterial filter (Braile Biomédica, São José do Rio Preto, Brazil) were used.

Surgical Procedure

We performed left anterolateral thoracotomy in the fourth intercostal space to expose the heart after pericardiectomy. Heparin sodium was administered (4 mg / kg) to achieve an activated clotting time (ACT) greater than 480 seconds. To perform the circulatory bypass of the right atrium to the pulmonary artery, a 20F arterial cannula was placed in the pulmonary artery, 1 cm below the left branch, and a 34F venous cannula was placed in the right atrium. Cardiac arrest did not occur and the pulmonary ventilation was maintained.

The pulmonary artery was clamped, proceeding to the longitudinal arteriotomy in the pulmonary trunk section of the annulus and the right ventricle outflow tract. Pulmonary cusps were removed. A bioprosthetic valve-in-ring implantation was performed with a 5-0 polypropylene continuous suture. A bovine pericardial patch was treated with non-lyophilized glutaraldehyde which was used to enlarge the right ventricle outflow and pulmonary artery. All animals were implanted with bovine pericardial prosthetic valve No 23 (Braile Biomédica, São José do Rio Preto, Brazil). Prior to implantation in the control group and LBPB, the bioprostheses were washed with saline solution for 30 minutes. The ECC was stopped and the entire volume was infused to achieve mean arterial pressure of 80 mmHg. Protamine sulfate was not administered to any animal.

Pressure Gradient

While evaluating the transvalvular gradient, we punctured the pulmonary trunk and the right ventricle (RV) outflow tract with a 0.9 mm needle connected to a multiparameter analyzer (5900 CAGE Signal Conditioner, Gould Inc., Valley View, Ohio, USA). Ten cycles were analyzed with a software system (v.2.19 Windaq, Dataq Instruments, Inc., Akron, OH, USA), which used the average systolic pressures in 10 cycles for analysis. The same procedure was performed at the time of euthanasia.

Prosthesis Excision

After three months, the animals were euthanized under general anesthesia. The heart was dissected through the right atrium and all the blood was drained. The excision of the prosthesis was performed with a segment of the pulmonary artery, the anterior wall of the right ventricle and non-lyophilized bovine pericardial patch.

Each prosthetic cusp was named according to the anatomical relationship with the aorta, the left atrium and the non-lyophilized patch. Subsequently, the prosthetic cusps were removed, divided into two symmetrical parts for performing histological staining with hematoxylin and eosin, von Kossa staining and determining the amount of calcium by atomic absorption spectrophotometry. The non-lyophilized bovine pericardial patch was also analyzed by the methods described.

Macroscopic evaluation

Each bioprosthesis was carefully post mortem examined for morphological evaluation after implantation. We evaluated the cusp mobility, lacerations, pannus, calcification, vegetations and thrombus formation.

Microscopic evaluation

Anatomopathological examinations were performed with hematoxylin-eosin and von Kossa staining for specific analysis of calcium. In the segments examined, we evaluated inflammation, thrombus and pannus presence and intensity of calcification. Intensity was used as the criterion, being classified as absent; (-) rare detection; (+) dispersed but consistent, (+++) present with uniformity and (++++) generalized distribution.

Quantification of calcium

The determination of calcium amount was performed after acid hydrolysis in a flame atomic absorption spectrophotometer (Analytik Jena, AAS Vario 6, Jena, Germany).

Statistical Analysis

Data from atomic absorption spectroscopy were expressed as mean \pm standard deviation. Groups were compared using the Mann-Whitney test. Scores for calcium, thrombus, inflammation and pannus were evaluated by means of a continuous scale. The significance level was set at 5%. We used the Statistical Package for the Social Sciences v.11.0 (SPSS, Chicago, IL, USA).

RESULTS

Among the 16 animals that underwent surgery, 12 had the expected survival of 90 days. Six animals in the control group reached 95.1 ± 3.5 days (91 to 99 days) of postoperative outcome. Two animals died on the 37th and 48th days, both from pneumonia. An animal that survived for 91 days was not considered in the analysis for measurement of calcium, due to the presence of endocarditis.

In the LBPB group, six animals reached 91.6 ± 0.8 days (91 to 93 days), two animals in this group died within 51 and 68 days, due to pneumonia and endocarditis.

Clinically, all animals that completed the study had normal physical activity from the first day after surgery. The animals did neither show any symptoms of heart failure nor general health problems during the study.

Right ventricle gradient / pulmonary artery (RV / PA)

In the control group, the mean gradient RV / PA in implantation was 2.04 ± 1.56 mmHg, ranging from 0 to 4.38 mmHg, while in explants there was an increase to 7.71 ± 3.92 mmHg, ranging from 3.25 to 11.95 mmHg.

In the LBPB group, the mean gradient RV / PA in implantation was 6.61 ± 4.03 mmHg, ranging from 4.55 to 11.84 mmHg, while in explant there was an increase to 8.24 ± 6.25 mmHg, ranging from 3.78 to 17.48 mmHg.

Figure 1 shows the evolution of the gradient for each animal in the control group and LBPB group. In this chart, the excluded animals were not shown.

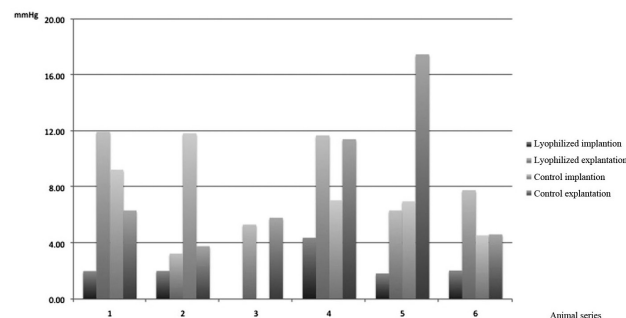


Fig. 1 - Analysis of the transvalvular gradient RV / PA

Post mortem observations

At euthanasia, all animals had dense adhesions among the pleura, the pericardium and heart. The bovine pericardial patch was flexible, with scattered sites of calcification.

Macroscopic evaluation

Presence of thrombi or lacerations was not found in any implanted bioprosthesis. The cusps of the two groups had their mobility partially impaired, with non-homogeneous sites of calcification. All prostheses in the control group and the LBPB group developed pannus.

Microscopic evaluation

There has been significant development of pannus in the bioprostheses in both groups. It was observed that, descriptively, more intense inflammation in bioprostheses in the control group compared to LBPB group (Figure 2), which showed lower inflammatory infiltrate (Table 1).

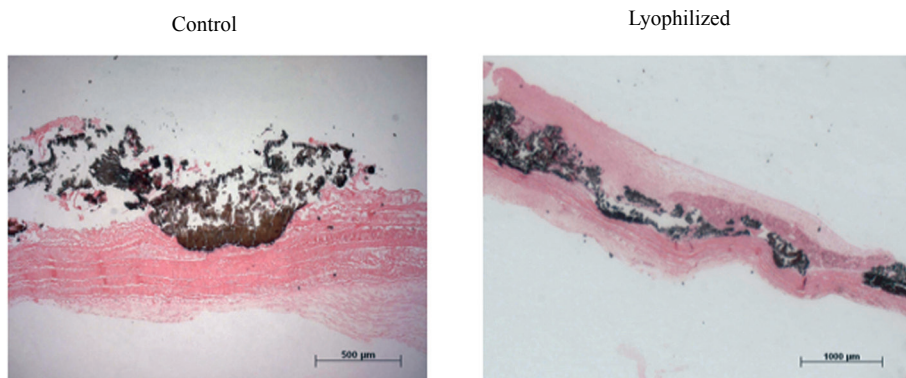


Fig. 2 - Valve prostheses calcification evidenced by Von Kossa method

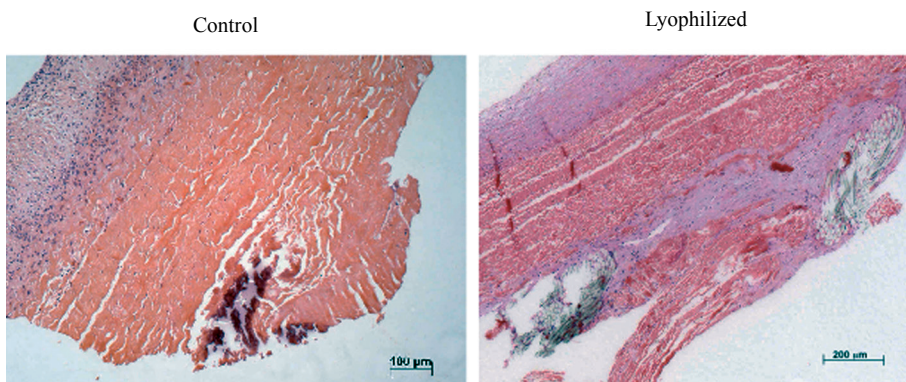


Fig. 3 - Inflammatory infiltrate in bioprostheses

Table 1. Histological changes after bioprostheses implantation.

Implanted bioprostheses	Pannus formation	Prosthesis inflammation	Inflammation intensity of pericardial patch
Control 1	++++	+++	++++
Control 2	++++	+++	++++
Control 3	++++	+++	++++
Control 4	++++	+	++++
Control 5	+++++	+	++++
Control 6	++++	-	-
Lyophilized 1	+++++	-	+
Lyophilized 2	++	-	+
Lyophilized 3	+++	+	+
Lyophilized 4	++++	-	+
Lyophilized 5	++++	-	++
Lyophilized 6	+++	+	+++

(-) = absent; (+) = rare, (+ +) = dispersed, (+ + +) = uniform; (+ + + +) = generalized

The presence of calcification was seen in the control group and in the LBPB group (Figure 3).

Quantitative analysis of calcium

The average amount of calcium in the cusps of the control group was 21.60 ± 39.12 mg Ca^{+2} / mg dry weight, compared with an average amount of 41.19 ± 46.85 mg Ca^{+2} / mg dry weight in the LBPB group ($P = 0.818$). The animal excluded from the control group due to endocarditis had an average amount of calcium in the cusps of 11.63 ± 6.45 mg Ca^{+2} / mg dry weight and 0.63 ± 0.01 mg Ca^{+2} / mg dry weight in the pericardial patch.

In the control group, the average amount of calcium in the patch was 1.52 ± 0.98 mg Ca^{+2} / mg dry weight, and 1.14 ± 0.51 mg Ca^{+2} / mg dry weight in the LBPB group. There was no statistical difference between groups ($P = 0.662$).

Table 2 shows the average amount of calcium (Ca^{+2} mg / mg dry weight) in the cusps and in the pericardial patch, as well as the control groups and LBPB group.

Table 2. Determination of calcium by atomic absorption spectrophotometry.

	Determination of calcium ($\mu\text{gCa}^{+2}/\text{mg}$ dry weight)	
	Cusps	Pericardial patch
Control Group		
1	91.43 \pm 55.77	0.67 \pm 0.04
2	1.72 \pm 0.79	1.66 \pm 0.01
3	0.92 \pm 0.35	2.83 \pm 0.02
4	5.37 \pm 8.34	2.00 \pm 0.20
5	8.87 \pm 7.32	0.44 \pm 0.01
LBPB Group		
1	1.93 \pm 0.71	0.75 \pm 0.03
2	114.60 \pm 38.63	1.34 \pm 0.09
3	65.60 \pm 69.64	0.70 \pm 0.03
4	60.9 \pm 75.46	1.92 \pm 0.03
5	1.23 \pm 0.28	0.67 \pm 0.01
6	2.89 \pm 0.75	1.47 \pm 0.03

DISCUSSION

Bioprostheses are viable alternatives in the treatment of cardiac valves in patients with significant morphological and functional valvular dysfunction [1,2]. Even with the technological advances in the technical processing and handling of biological tissues, clinical studies continue to demonstrate that patients also suffer from structural bioprosthesis deterioration [11-14].

Previous studies from our group demonstrated that lyophilized bovine pericardium treated with glutaraldehyde promotes reduction of aldehyde residuals, from the treatment with glutaraldehyde tissue [9]. As it is known, glutaraldehyde is used in the pericardium as an alternative treatment of biological tissues in order to improve mechanical and immunogenic properties and because it stabilizes the structure of collagen, increase resistance to enzymatic degradation, reduces thrombogenicity and antigenicity [15,16]. The disadvantage of this method is that during the process of fixation with glutaraldehyde there is a loss of endothelial cells, interstitial cell viability and also loss of inhibitors of calcification process because the fragmentation of cellular membranes progresses with the release of phospholipids which allow the deposition of phosphates calcium.

Unfortunately, these processes increase the biological tissue calcification [15,16]. Furthermore, the free aldehyde groups and the phospholipids in combination with calcium ions circulation can induce calcification [11,17]. Different strategies to prevent calcification have been reported, including use of inhibitors of calcification in fixed tissue, removal or modification of calcifying components, modification in the process of fixing and using other

fixing agents [18-20]. The development of methods for the extraction of derivatives of glutaraldehyde showed that the calcification process rests on dialdehydes and their polymerization products [20,21]. Our group evaluated the possibility of a bovine pericardial valve bioprosthesis, chemically treated with glutaraldehyde, which when subjected to freeze-drying process by annealing could present less calcification in the follow-up period, since glutaraldehyde residual is considered as a calcification factor.

Although there are works from the 1960s regarding the lyophilization of homografts with unfavorable results [6,7], the present study differs by using bovine pericardial bioprosthesis treated with glutaraldehyde and subsequently lyophilized by a technique which incorporates the annealing process.

In the interatrial septum, after the creation of an interatrial communication (IC) in dogs, and implantation of a bovine pericardial patch treated with lyophilized glutaraldehyde, a slight pannus formation was reported [22]. In our study, the formation of pannus was relevant in both lyophilized and non- lyophilized bioprostheses. Although we have used bioprostheses while Santibáñez-Salgado et al. interatrial septal patch, we believe that the formation of pannus in our study may be related to low pressure in the right atrium and the pulmonary artery. In bovine pericardial bioprostheses, the presence of inflammatory cells is related to increased structural valve degeneration, resulting in cusp lacerations [23]. In this study, we found that the control group showed greater inflammatory response when compared to the LBPB group, indicating a possible protective mechanism of the lyophilization process for the inflammatory response.

In an experiment with a 5-month postoperative period after implantation in the mitral prosthesis with bovine pericardium (Arbor Surgical Technologies Inc, Irvine, CA), there was an average of 1.05 mg Ca^{+2} / mg dry weight (ranging from 0, 65 to 2.58 mg Ca^{+2} / mg dry weight), and the Carpenier-Edwards Perimount prosthesis (Edwards Lifesciences, Irvine, CA, USA) the average was 3.23 mg Ca^{+2} / mg dry weight (ranging from 1.52 to 23.8 mg Ca^{+2} / mg dry weight) [10]. In our experiment with implantation during three months in the pulmonary position, there was a higher average amount of calcium with 21.60 \pm 39.12 mg Ca^{+2} / mg dry weight (ranging from 0.92 to 91.43 mg Ca^{+2} / mg dry weight) in the control group. It was not observed in this experiment that lyophilization decreases calcification, because the average amount of calcium was 41.19 \pm 46.85 mg Ca^{+2} / mg dry weight in LBPB group (ranging from 1.93 to 114.60 mg Ca^{+2} / mg dry weight).

It is also important to mention that the final gradient through the bioprosthesis during the period of three months showed similar results between groups (7.71 \pm 3.92 versus

8.24 ± 6.25 mmHg) despite the difference in the implant (2.04 ± 1.56 mmHg vs. 6.61 ± 4.03 mmHg). We believe that this result is due to the LBPB group not has been fully hydrated during the 30 minutes wash with saline solution, causing greater rigidity in their cusps in the initial phase.

There are some limiting factors in this study. This is an experimental study which was conducted with a reduced initial sample of animals. Late survival involved multiple variables in the treatment of the animals that were under strict veterinary supervision, however it was not standardized. The postoperative follow-up for the assessment of bioprostheses calcification, although debatable, could include more time for observation. The implantation in pulmonary position evaluated the system with bioprostheses in lower pressure, which reduced the processes of structural valve degeneration. Although this study failed to show that lyophilization was a protection for calcification, it signaled an improvement in the inflammatory aspect, which in our view is an advantage in the aspect of bioprostheses structural degeneration.

In addition to that, it has the advantage of easy handling and preservation, since the bioprosthesis can be stored dry and sterilized by conventional means such as gamma radiation. We should also improve the bioprostheses hydration by changing some parameters of lyophilization with annealing, so that complete hydration occurs in less time. The fact that there was no statistical difference in calcification in the control group and in the LBPB group may also mean that the calcification factor in bovine pericardial bioprostheses due to residual glutaraldehyde from the treatment of pericardial membranes is not a major cause for either calcifying the bioprostheses or not.

CONCLUSION

Finally, we conclude that this study failed to demonstrate the protective mechanism of freeze drying as an anticalcification agent of bovine pericardium treated with glutaraldehyde. Histologic evaluation showed a smaller inflammatory process of the lyophilized tissue, but it requires further studies.

ACKNOWLEDGMENTS

This project received financial assistance from FAPESP (process no 04/0566-8).

REFERENCES

1. Rahimtoola SH. Choice of prosthetic heart valve in adults an update. *J Am Coll Cardiol*. 2010;55(22):2413-26.
2. David TE, Armstrong S, Maganti M. Hancock II bioprosthesis for aortic valve replacement: the gold standard of bioprosthetic valves durability? *Ann Thorac Surg*. 2010;90(3):775-81.
3. Clark JN, Ogle MF, Ashworth P, Bianco RW, Levy RJ. Prevention of calcification of bioprosthetic heart valve cusp and aortic wall with ethanol and aluminum chloride. *Ann Thorac Surg*. 2005;79(3):897-904.
4. Ruel M, Kulik A, Rubens FD, Bédard P, Masters RG, Pipe AL, et al. Late incidence and determinants of reoperation in patients with prosthetic heart valves. *Eur J Cardiothorac Surg*. 2004;25(3):364-70.
5. Poirer NC, Pelletier LC, Pellerin M, Carrier M. 15-year experience with the Carpentier-Edwards pericardial bioprosthesis. *Ann Thorac Surg*. 1998;66(6Suppl):S57-61.
6. Duran CG, Gunning AJ, Whitehead R. Experimental aortic valve heterotransplantation. *Thorax*. 1967;22(6):510-8.
7. Duran CM, Whitehead R, Gunning AJ. Implantation of homologous and heterologous aortic valves in prosthetic vascular tubes. *Thorax*. 1969;24(2):142-7.
8. Borgognoni CF, Maizato MJ, Leirner AA, Polakiewicz B, Beppu MM, Higa OZ, et al. Effect of freeze-drying on the mechanical, physical and morphological properties of glutaraldehyde-treated bovine pericardium: evaluation of freeze-dried treated bovine pericardium properties. *J Appl Biomater Biomech*. 2010;8(3):186-90.
9. Maizato MJ, Higa OZ, Mathor MB, Camillo MA, Spencer PJ, Pitombo RN, et al. Glutaraldehyde-treated bovine pericardium: effects of lyophilization on cytotoxicity and residual aldehydes. *Artif Organs*. 2003;27(8):692-4.
10. Flameng W, Meuris B, Yperman J, De Visscher G, Herijgers P, Verbeken E. Factors influencing calcification of cardiac bioprostheses in adolescent sheep. *J Thorac Cardiovasc Surg*. 2006;132(1):89-98.
11. Schoen FJ, Levy RJ. Calcification of tissue heart valve substitutes: progress toward understanding and prevention. *Ann Thorac Surg*. 2005;79(3):1072-80.
12. McClure RS, Narayanasamy N, Wiegerinck E, Lipsitz S, Maloney A, Byrne JG, et al. Late outcomes for aortic valve replacement with the Carpentier-Edwards pericardial bioprosthesis: up to 17-year follow-up in 1,000 patients. *Ann Thorac Surg*. 2010;89(5):1410-6.
13. Jamieson WR, Lewis CT, Sakwa MP, Cooley DA, Kshetry VR, Jones KW, et al. St Jude Medical Epic porcine bioprosthesis: results of the regulatory evaluation. *J Thorac Cardiovasc Surg*. 2011;141(6):1449-54.e2.
14. ISTHMUS Investigators. The Italian study on the Mitroflow postoperative results (ISTHMUS): a 20-year, multicentre

-
- evaluation of Mitroflow pericardial bioprosthesis. *Eur J Cardiothorac Surg*. 2011;39(1):18-26.
15. Beauchamp RO Jr, St Clair MB, Fennell TR, Clarke DO, Morgan KT, Kari FW. A critical review of the toxicology of glutaraldehyde. *Crit Rev Toxicol*. 1992;22(3-4):143-74.
 16. Golomb G, Schoen FJ, Smith MS, Linden J, Dixon M, Levy RJ. The role of glutaraldehyde-induced cross-links in calcification of bovine pericardium used in cardiac valve bioprostheses. *Am J Pathol*. 1987;127(1):122-30.
 17. Guldner NW, Jasmund I, Zimmermann H, Heinlein M, Girndt B, Meier V, et al. Detoxification and endothelialization of glutaraldehyde-fixed bovine pericardium with titanium coating: a new technology for cardiovascular tissue engineering. *Circulation*. 2009;119(12):1653-60.
 18. Clark JN, Ogle MF, Ashworth P, Bianco RW, Levy RJ. Prevention of calcification of bioprosthetic heart valve cusp and aortic wall with ethanol and aluminum chloride. *Ann Thorac Surg*. 2005;79(3):897-904.
 19. Hahn SK, Ohri R, Giachelli CM. Anti-calcification of bovine pericardium for bioprosthetic heart valves after surface modification with hyaluronic acid derivatives. *Biotechnol Bioprocess Eng*. 2005;10:218-24.
 20. Zilla P, Fullard L, Trescony P, Meinhardt J, Bezuidenhout D, Gorlitzer M, et al. Glutaraldehyde detoxification of aortic wall tissue: a promising perspective for emerging bioprosthetic valve concepts. *J Heart Valve Dis*. 1997;6(5):510-20.
 21. Weissenstein C, Human P, Bezuidenhout D, Zilla P. Glutaraldehyde detoxification in addition to enhanced amine cross-linking dramatically reduces bioprosthetic tissue calcification in the rat model. *J Heart Valve Dis*. 2000;9(2):230-40.
 22. Santibáñez-Salgado JA, Olmos-Zúñiga JR, Pérez-López M, Aboitiz-Rivera C, Gaxiola-Gaxiola M, Jasso-Victoria R, et al. Lyophilized glutaraldehyde-preserved bovine pericardium for experimental atrial septal defect closure. *Eur Cell Mater*. 2010;19:158-65.
 23. Zilla P, Brink J, Human P, Bezuidenhout D. Prosthetic heart valves: catering for the few. *Biomaterials*. 2008;29(4):385-406.