

## Case 7/2007

# A child with transposition of the great arteries submitted to surgical correction at preschool age

## Portadora de transposição das grandes artérias operada em idade pré-escolar

Ulisses Alexandre CROTI<sup>1</sup>, Domingo Marcolino BRAILE<sup>1</sup>, Ana Carolina Leiroz Ferreira Botelho MAISANO KOZAK<sup>1</sup>, André Luis de Andrade BODINI<sup>1</sup>

RBCCV 44205-918

### CLINICAL DATA

On the 4<sup>th</sup> day of life, an Afro-Brazilian female child born in Paulínia, São Paulo, presented cyanosis of extremities. The patient was given prostaglandin. She was referred to our Pediatric Cardiovascular Surgery Service after congenital heart disease was diagnosed. At this moment, the radiography resembled to both an oval-shaped cardiac area and an electrocardiogram with left ventricle overload. The echocardiogram suggested a transposition of the great arteries [TGA], perimembranous interventricular communication (IVC), ostium secundum interatrial communication (IAC), severe preductal aortic coarctation, and patent ductus arteriosus with a greater diameter. As the team was in both structural and learning phases, it was chosen to perform a staged surgical repair (correction) with terminoterminal (end-to-end) aortoplasty, ligation, and resection of ductus arteriosus. Additionally, a balloon catheter atrioseptostomy (Rashkind) was performed during the hemodynamic study carried out two days prior to the surgery. Both parents were given instructions to keep the outpatient clinic follow-up. However, they were absent until the aggravation of the cyanosis when they have brought the child back to our service. The child was 4 years old, weighting 14.6 kg, in REG, hydrated, eupneic, and with cyanosis ++++/4+. The lungs were free; heart rhythm was regular with two clicks, with a hypophonetic second heart sound; effective systolic murmur ++/4+ in medium-below left sternal border. There is no abdominal tenderness on

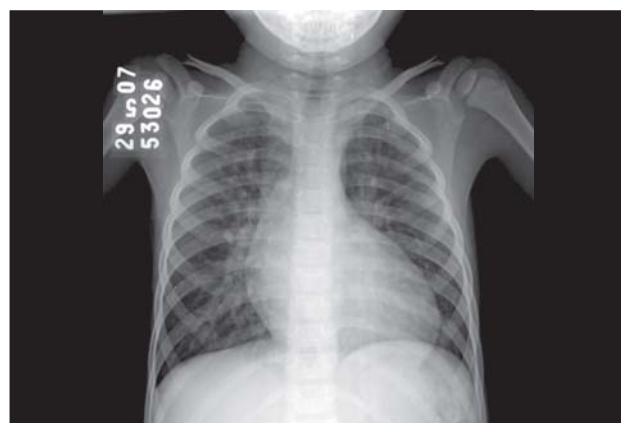


Fig.1 - A typical PA radiograph of thorax of patients undergone transposition of the great arteries

palpation; the liver lays at 4 cm from the right costal margin. Peripheral saturation of 58% with normal pulses.

### ELECTROCARDIOGRAM

Electrocardiogram evidenced: sinus rhythm of 107 beats/minute;  $\hat{A}QRS + 90^\circ C$ ; PR interval, 0.12 sec; QTc, 0.48 sec; QRS, 0.08 sec. Right ventricle overload with a pure R in V1.

### RADIOGRAM

Upon the radiogram revealed visceral situs solitus. The cardiothoracic index was 0.62. The second aortic arch was hollowed with tapering of the mediastinum structures. It

1. São José do Rio Preto Pediatric Cardiovascular Surgery Service – Hospital de Base – Medical School of São José do Rio Preto, São Paulo, Brazil

### Correspondence address:

Ulisses Alexandre Croti  
Hospital de Base – FAMERP – Avenida Brigadeiro Faria Lima, 5544.  
CEP 15090-000 – São José do Rio Preto – SP  
Fone (Fax): 17 - 3201 5025 / 3222 6450 / 9772 6560  
E-mail: uacroti@uol.com.br

was also noted a pulmonary vascular prominence with a discrete peripheral oligohemia (Figure 1).

#### ECHOCARDIOGRAM

Situs solitus was present at levocardia. It was observed TGA; 19-mm wide IAC, and 2.5-mm muscular/trabecular IVC. The aortic valve and the pulmonary annulus were 16.4 and 22.7, respectively; pulmonary arteries were confluent and hypoplastic with 9 mm to the right and 7.4 mm to the left. The echocardiogram revealed type III left ventricle geometry and bulging septum toward the left ventricle. The aortic arch had a normal echocardiographic aspect without an isthmic gradient. It was also revealed an absence of the ductus arteriosus.

#### DIAGNOSIS

In spite of the early diagnosis performed at the neonatal period, it is important to highlight that there was no local structure condition neither the viable possibility of referring to another reference Pediatric Service to have definitive medical care.

This is a very usual situation in Brazil. Therefore, the patient could have been submitted to the Jatene operation with correction of the coarctation of aorta. Without a previous hemodynamic study, the patient needed a two-stage treatment, at first with an aortoplasty and section of the ductus arteriosus followed by the Senning operation, which should have been performed earliest to avoid the cyanosis complications, such as thromboembolism and stroke, among others [1]. Nevertheless, the family socioeconomic conditions have rendered difficult to this approach.

#### OPERATION

Approach by longitudinal median sternotomy with establishment of cardiopulmonary bypass by introducing cannulas into the following: aorta, superior and inferior vena cava was performed. The sites of incision at the right atrium were marked. The right atrium was opened with a longitudinal incision toward the inferior vena cava. Resection of interatrial septum, opening of the left atrium along the right pulmonary veins (Figure 2A), and suture of the bovine pericardium below the mitral valve, by isolating the pulmonary veins (Figure 2B), which was named first plane, were performed. Together with the right atrium lateral wall, a suture was initiated along the valve of inferior vena cava (Eustachian valve), thus, forming the tunnel of inferior vena cava. This procedure was performed in the same very

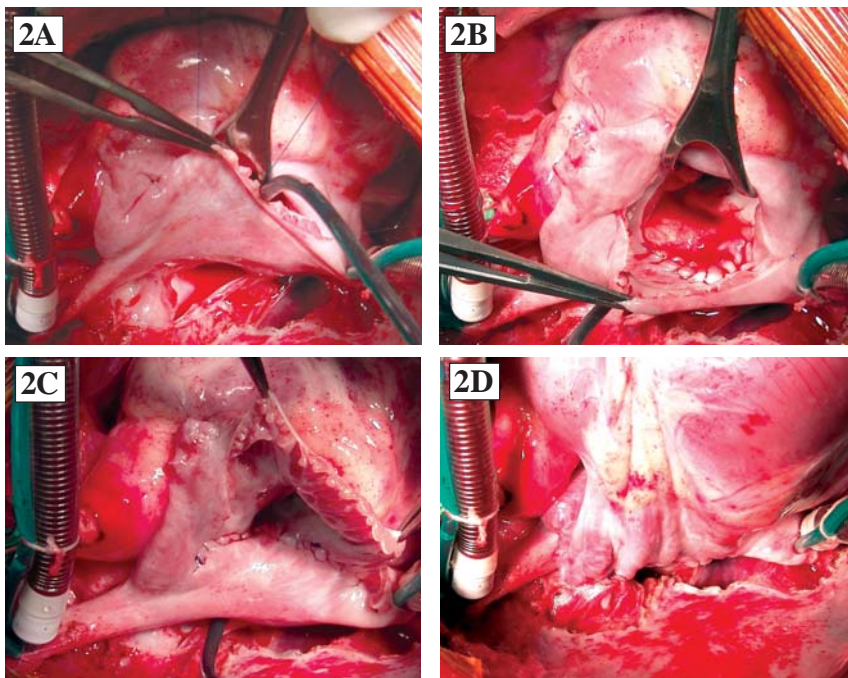


Fig.2 - Important moments during the surgery: 2A – Opening of the left atrium along with the right pulmonary veins. It can be observed a small incision towards the right superior pulmonary vein. 2B – First plane: isolating the pulmonary veins. 2C – Second plane: after the conclusion of the tunnel of the venae cavae. 2D – Third plane: final anastomosis of the medial wall of the right atrium to the incision in the left atrium close to the right pulmonary veins

way in the superior vena cava with the two sutures coming together, leaving the flow of the venae cavae and the coronary sinus toward the left atrioventricular valve (mitral valve) (Figure 2C), named second plane. Together with the right atrium medial wall, the suture along the right pulmonary veins were initiated, forming the so-called third plane, and directing the blood flow toward to the right atrioventricular valve (tricuspid valve) (Figure 2D). A 2.5-mm IVC was not corrected due to the hypoplasia of the pulmonary arteries. The perfusion time was 94 minutes; the myocardial ischemia was 68 minutes with 28°C-hypothermia. The child developed bronchopneumonia and remained at the hospital for 14 days to be treated with antibiotics. After three months, She was asymptomatic and the echocardiogram revealed an excellent surgical outcome, despite a residual IVC and the hypoplasia of the pulmonary arteries.

#### REFERENCE

1. Dodge-Khatami A, Kadner A, Berger Md F, Dave H, Turina MI, Prêtre R. In the footsteps of senning: lessons learned from atrial repair of transposition of the great arteries. *Ann Thorac Surg.* 2005;79(4):1433-44.