

Video-thoroscopic pericardial drainage in the treatment of pericardial effusions

Drenagem pericárdica videotoroscópica no tratamento dos derrames pericárdicos

José Honório PALMA¹, Diego Felipe GAIA², José Cícero Stocco GUILHEN³, João Nelson Rodrigues BRANCO¹, Enio BUFFOLO⁴

RBCCV 44205-1050

Abstract

Objectives: To assess efficacy and safety of video-thoroscopic pericardial drainage in the treatment and diagnostic of pericardial effusion through 26 cases review.

Methods: From April 2005 to December 2007, 26 patients with pericardial effusion underwent a video-thoroscopic pericardial window. Median age was 48.2 years old. Dyspnea was the most frequent symptom followed by thoracic pain. The procedure was performed in lateral decubitus, under general anesthesia and selective intubation with the aid of three trocars.

Results: Procedure accomplish was feasible in 25 cases. One conversion occurred. In 61.53% of the cases the procedure was able to modify the initial diagnosis. Microbiology and tissue culture were negative in all cases. Neoplasia was present in nine cases, tuberculosis in two, aspergillosis in one, postoperative heart surgeries in three; lupus in two, uremia in one and idiopathy in eight. Associated pleuropulmonary procedures were performed in four cases. No deaths related to the procedure occurred. One late recurrence was recorded.

Conclusion: The procedure is feasible, safe, reproducible and allowed an etiologic diagnostic. Specific treatment could

be initiated in some cases. The intervention could possibly be the new gold standard treatment of pericardial effusion in selected patients.

Descriptors: Pericardium. Thoracic surgery, video-assisted. Pericardial effusion/surgery.

Resumo

Objetivos: Analisar a eficácia e a segurança da drenagem pericárdica videotoroscópica no tratamento e diagnóstico etiológico dos derrames pericárdicos por meio da revisão de 26 casos.

Métodos: De abril de 2005 a dezembro de 2007, 26 pacientes com derrame pericárdico foram submetidos ao procedimento. A média etária foi de 48,2 anos. O sintoma mais comum foi dispnéia, seguida por dor torácica. O procedimento foi realizado em decúbito lateral, sob anestesia geral e intubação seletiva, com o auxílio de três trocateres.

Resultados: A realização do procedimento foi possível em 25 casos. Ocorreu uma conversão. Em 61,53% dos casos, o procedimento foi capaz de alterar o diagnóstico inicial. Culturas e microbiologia foram negativas em todos os casos.

1. PhD. Full Professor (Professor of the Discipline of Cardiovascular Surgery of UNIFESP - EPM).
2. Master's Degree (Physician of the Discipline of Cardiovascular Surgery of UNIFESP - EPM).
3. Cardiovascular Surgeon (Resident Physician of the Discipline of Cardiovascular Surgery of UNIFESP - EPM).
4. PhD. Full Professor (Professor of the Discipline of Cardiovascular Surgery of UNIFESP - EPM).
5. Titular Professor (Titular Professor of the Discipline of Cardiovascular Surgery of UNIFESP - EPM).

São Paulo Medical School. Rua Borges Lagoa 1080- 7º. and. - Vila Clementino - São Paulo - SP. CEP 04038-000

Correspondence address:

Diego Gaia. Disciplina de Cirurgia Cardiovascular
Rua Napoleão de Barros 715 - 3º Andar Vila Clementino
São Paulo - SP. CEP: 04038-000.
E-mail: drgaia@uol.com.br

Achados compatíveis com neoplasia estavam presentes em nove casos, tuberculose em dois, aspergilose em um, pós-cirúrgico em três, lúpico em dois, urêmico em um e oito idiopáticos. Em quatro casos, procedimentos pleuropulmonares concomitantes foram realizados. Não ocorreram óbitos relacionados ao procedimento. Ocorreu uma recidiva.

Conclusão: O procedimento demonstrou ser seguro,

reprodutível e eficaz, capaz de fornecer diagnóstico etiológico e mudar o curso terapêutico de alguns pacientes. O procedimento pode se tornar o padrão-ouro em doentes selecionados.

Descritores: Pericárdio. Cirurgia torácica vídeo-assistida. Derrame pericárdico/cirurgia.

INTRODUCTION

The pericardial effusion is a relatively frequent disease, and is related to infectious processes (tuberculosis, viral, fungal and bacterial), metabolic (uremia, induced by drugs, hypothyroidism and rheumatoid arthritis), radiation and cancer. Thus, the etiologic diagnosis of effusion becomes crucial. Many of these patients present associated pleural disease [1].

In addition, the pericardial effusion may have other etiologies that require cultures and/or specific histopathological exams.

Despite pericardial puncture and pericardial drainage using catheter are effective in relieving of symptoms and cardiac tamponade, these methods do not present the same efficiency of surgical drainage in recurrent and septate effusion, nor allow appropriate collection of material for biopsy [1].

In these cases, surgical drainage performed by subxiphoid approach is able to promote symptomatic relief through pericardial cavity decompression and allows collection of pericardial fluid for analysis. Unfortunately, the collection of biopsies is limited to the small area approached, thus reducing the diagnostic possibility. Moreover, the incidence of recurrence may reach 10% in some series [2-4].

The lateral thoracotomy can also be used, allowing wide access to the pericardial cavity, but without much possibility of appropriate pleural inspection and with more postoperative pain and slower recovering [3].

The video-thoroscopic pericardial drainage is a little invasive method used in the diagnosis and treatment of traumatic and non-traumatic pericardial effusion [5]. It allows a wide examination of the thoracic cavity and the pericardium, with excellent visualization of mediastinal and thoracic structures, unlike the subxiphoid window that allows only viewing and limited pericardial resection. In the procedure, it is possible to create a wide pleuropericardial window and theoretically able to reduce recurrences [6].

There is no consensus on the best alternative in the treatment of these disorders, but several groups have reported favorable results by using thoracoscopic drainage [3,4].

The aim of this study is to analyze the efficacy and safety of video-thoroscopic pericardial drainage in the treatment and diagnosis of pericardial effusion through the review of 26 cases performed in our Service.

METHODS

Between April 2005 and December 2007, 26 patients with pericardial effusion underwent video-thoroscopic pericardial drainage by making pleuropericardial window, after written informed consent and approval of the Research Ethics Committee. In the aforementioned period, all patients of the institution with indication for pericardial drainage - without exclusion criteria - underwent the procedure proposed.

The following inclusion and exclusion criteria were used:

Inclusion

1. Consent to participate;
2. Presence of pericardial effusion classified as at least moderate under transthoracic echocardiogram with or without signs of cardiac tamponade;
3. Chance of monopulmonary ventilation;
4. Absence of significant thoracic deformities;
5. Absence of coagulation disorder.

Exclusion

1. Not consent to participate;
2. Traumatic effusions;
3. Impossibility of single ventilation;
4. Presence of pleural adhesions;
5. Prior thoracic surgery at the side to be approached;
6. Need for simultaneous thoracic intervention not compatible with thoracoscopic treatment;

7. Severe hemodynamic instability, defined by need for intravenous vasopressors for maintenance of appropriate tissue perfusion pressure.

In the group studied, 14 patients were female. The mean age was 48.2 years (15-84 years). The symptoms included: dyspnea (n=21 / 80.8%), chest pain (n=2 / 7.7%), heart failure (n=2 / 7.7%) and test finding (n=1 / 3.8%). All patients had echocardiographic diagnosis before the procedure, and five patients underwent additional examinations such as computed tomography or magnetic resonance imaging in active search for neoplastic processes, due to the high clinical suspicion and analysis of pleural diseases that may preclude the procedure. Of these, two showed signs compatible with neoplasia (lung and breast) and the other showed no new findings. Eight patients (30.7%) presented signs and symptoms of cardiac tamponade. None of the patients presented prior isolated pericardial procedures or presented hemodynamically unstable under diagnosis.

The procedure was performed in all patients in lateral decubitus position under general anesthesia and selective intubation of the contralateral lung (Figure 1). The side to be approached was selected by the following criteria: too large heart areas, right side; associated pleural effusion, effusion side; adhesions, contralateral side.

Three trocars (Thoracoport - Ethicon - USA) were positioned for introduction of optics (Olympus - Japan, 10mm, 30.) and endoscopic instruments (Ethicon Endosurgery - United States, curved scissors, grip tweezers, vacuum and dissection forceps), one of 10 mm and two of 5 mm, located respectively in the fifth, fourth and sixth intercostal spaces in the middle (10 mm) and anterior (5 mm) axillary lines (Figure 1).

After insertion of the first 10mm trocar (optical), an inspection of the entire pleural cavity was performed in search for adhesions, effusions or signs of pleural diseases.

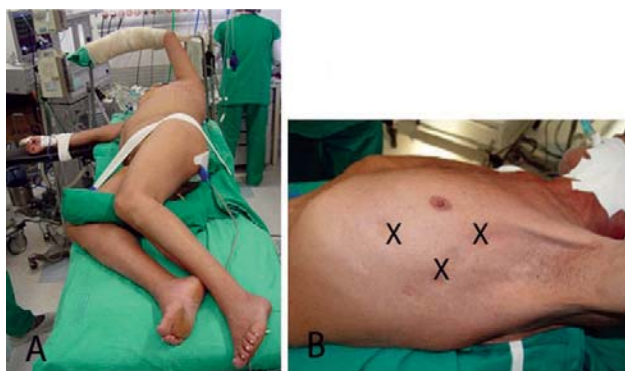


Fig. 1 – A- Patient in lateral decubitus position. B. Trocars position

Under thoracoscopic vision all trocars were placed. The identification of mediastinal structures was performed, with particular emphasis on the phrenic nerve (Figure 2). Then a stretched region was selected, below the phrenic nerve, which was punctured using an endoscopic needle with collection of material for culture, biochemistry and cytology. Subsequently, the pericardium was trapped by endoscopic forceps and then a pericardial window was performed using a curved endoscopic scissors. (Figure 3).

The fragment measuring about 4-5 cm in diameter was removed, taken from the chest and sent for histopathological examination entirely. An endoscopic suction device was then used to discard all liquid contents of the pericardial sac in order to discard any pericardial adhesions from the heart.

A chest drain was introduced and fixed through the orifice of the lower trocar. (Figure 4). Bipulmonary ventilation was restored through alveolar recruitment under thoracoscopic vision and aid of Valsalva maneuver. Patients were awakened from anesthesia, extubated and sent to the heart surgery postoperative unit and then to the ward.

Data on the time of thoracic drainage, intra- and postoperative complications and recurrence were collected. The thoracic drain was removed when the daily drainage was less than 100 ml.

After hospital discharge, patients were referred to usual outpatient follow up.

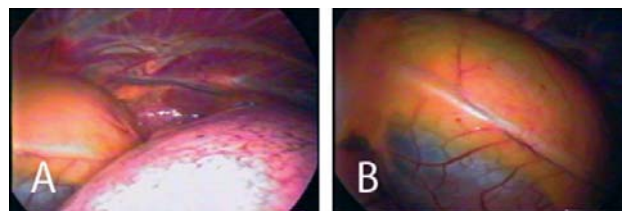


Fig. 2 – A- Mediastinal thoracoscopic vision. B- Mediastinal thoracoscopic vision. Observe the phrenic nerve (middle)

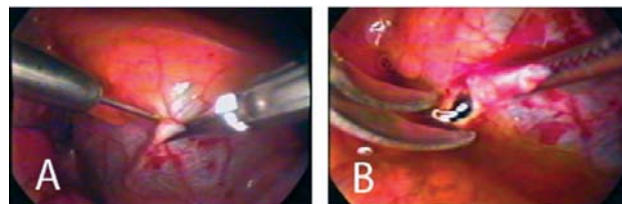


Fig. 3 – A- Pericardial sac puncture. B- Making of pericardial window and leaving of pericardial liquid

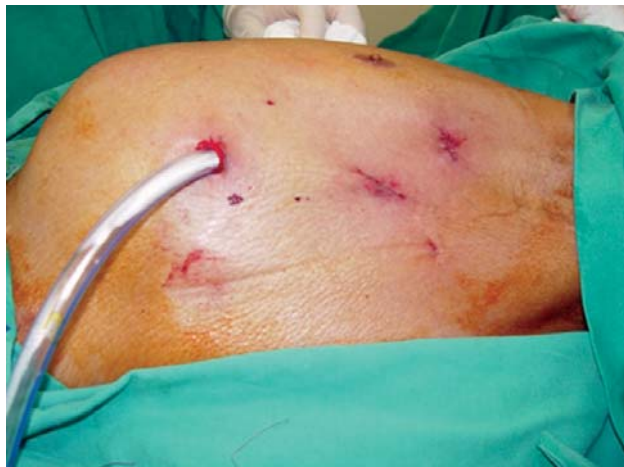

Fig. 4- Final appearance of the procedure. Thoracic drain positioned through the lower orifice

RESULTS

The satisfactory accomplishment of the procedure was possible in 25 cases. There was only one case of conversion to a mini-thoracotomy for increased intraoperative bleeding.

Four cases (15.4%) were emergently performed, or that is, with need for immediate accomplishment after diagnosis. The intraoperative variables are summarized in Table 1.

Table 1. Intraoperative variables

	N=26
Mean surgical time in minutes (Standard deviation)	52.45 ± 24.09
Extubation in surgical room (%)	22 (84.6)
Conversion (%)	1 (3.8)
Operative Mortality	0

The pre- and postoperative diagnosis are summarized in Table 2. Cultures and microbiology were negative in all cases. Two cases initially classified as of uremic origin showed to be neoplasms. Eight cases presented diagnosis of chronic nonspecific pericarditis. Three cases occurred in the heart surgery postoperative period, none of them under anticoagulation.

Table 2. Pre-and postoperative diagnosis

Diagnosis	Preoperative	Postoperative
Fungal	0	1
Idiopathic	14	8
Lupus	2	2
Neoplastic	4	9
Postoperative	3	3
Uremia	3	1
Tuberculosis	0	2
Total	26	26

In four cases, concomitant procedures (pleural and/or lung biopsy) were performed. In 16 cases (61.5%), the left side was approached and in any case the bilateral approach was necessary.

Less intraoperative complications have occurred in three cases: nonsustained ventricular tachycardia, acute pulmonary edema and need for prolonged orotracheal intubation in a patient with chronic obstructive pulmonary disease.

There were no deaths related to the procedure. A mortality rate equal to 19.2% (n=5) was found in the late follow-up, and four cases by advancing of neoplastic disease and one by aspergillosis.

There was only one recurrence (initial diagnosis of effusion secondary to uremia). The follow-up was performed with serial clinical and echocardiographic assessment.

DISCUSSION

Pericardial effusion is a relatively common disease in medical practice and especially in cardiovascular surgery. Its treatment is sometimes considered simple, when it is only considered the occasional symptomatic relief. However, the conventional intervention is often unable to provide sustainable results with a low rate of recurrence and high rate of diagnosis [3].

As the correct diagnosis may influence treatment, the achievement of a sure diagnosis is essential in appropriate management of these patients.

The best method to diagnose and treat the pericardial effusions remains a controversial subject. In recent years, with the advancement of minimally invasive procedures in cardiovascular surgery, increased emphasis has been given to this approach and increasing reports have shown the efficacy, safety and reproducibility of the thoroscopic procedure [4-7].

In addition to allow the drainage of pericardial effusions, the procedure is able to diagnose associated pleural processes that may be investigated and treated in the same

operative time, making the invasive evaluation more complete.

In our experience, the procedure has shown excellent mediastinal and chest inspection ability, and may be performed on a safe and fast manner, as well as to provide elements that could change the diagnosis and, consequently, the specific treatment of some patients. Our sample was able to show the procedure's ability to provide etiologic diagnostic able to change the therapeutic guidance, even with a substantial increase in the number of tumors initially identified as idiopathic effusions.

Before the procedure, 14 patients were classified as patients with idiopathic - or for clearing - effusions. This number was reduced to eight after intervention, showing their ability of positively affect the diagnosis.

We excluded patients with pleural adhesions and traumatic effusions due to it is the team's initial experience with the procedure, thereby avoiding potentially complicating factors in its achievement. Some centers no longer consider these findings as contraindications to perform the video-thoracoscopy pleuropericardial window [5].

The follow-up of our study was comparable with other authors by confirming a low or no rate of recurrences, possibly by performing wide pleuropericardial windows [8-11].

The intervention also did not require use of high cost devices, since the trocars and forceps used were permanent surgical instruments as well as the video device, making viable the intervention in many centers with limited resources in our country.

The time for performing the procedure was relatively short, but higher than the previously reported for conventional procedures via the subxiphoid window [4]. There was a clear learning curve, in which the first procedures were performed in larger time, not affecting, however, the number of complications related to it.

The video-thoroscopic pericardial drainage proved to be a safe procedure, and reproducible with non-fatal intraoperative complications, which did not alter the final outcome. The complication rate was similar to that reported by Geissbuhler et al. [12], however, higher than the reported in other series of thoracoscopy and subxiphoid intervention and may possibly reflect differences in the groups studied and the experience of the team with the procedure [13,14]. The intervention was effective in performing the diagnosis and treatment of pericardial effusions, and allows the accomplishment of associated pleural procedures.

The limitations of our study include the small number of patients, the absence of interventions in unstable patients and non-randomization based on the conventional procedure.

Despite this, we suppose – based on our findings and the increasing reports of safety and effectiveness on the literature - that, in selected cases, the approach of pericardial effusions by video-thoracoscopy may be preferred in order to prevent recurrence and to allow an increased rates of sure diagnosis.

REFERENCES

1. Moores DW, Dziuban SW Jr. Pericardial drainage procedures. *Chest Surg Clin N Am.* 1995;5(2):359-73.
2. Moores DW, Allen KB, Faber LP, Dziuban SW, Gillman DJ, Warren WH, et al. Subxiphoid pericardial drainage for pericardial tamponade. *J Thorac Cardiovasc Surg.* 1995;109(3):546-51.
3. Georghiou GP, Stamler A, Sharoni E, Fichman-Horn S, Berman M, Vidne BA, et al. Video-assisted thoracoscopic pericardial window for diagnosis and management of pericardial effusions. *Ann Thorac Surg.* 2005;80(2):607-10.
4. O'Brien PK, Kucharczuk JC, Marshall MB, Friedberg JS, Chen Z, Kaiser LR, et al. Comparative study of subxiphoid versus video-thoracoscopic pericardial "window". *Ann Thorac Surg.* 2005;80(6):2013-9.
5. Casós SR, Richardson JD. Role of thoracoscopy in acute management of chest injury. *Curr Opin Crit Care.* 2006;12(6):584-9.
6. Mack MJ, Landreneau RJ, Hazelrigg SR, Acuff TE. Video thoracoscopic management of benign and malignant pericardial effusions. *Chest.* 1993;103(4 Suppl):390S-3.
7. Piehler JM, Pluth JR, Schaff HV, Danielson GK, Orszulak TA, Puga FJ. Surgical management of effusive pericardial disease. Influence of extent of pericardial resection on clinical course. *J Thorac Cardiovasc Surg.* 1985;90(4):506-16.
8. Nataf P, Cacoub P, Regan M, Baron F, Dorent R, Pavie A, et al. Video-thoracoscopic pericardial window in the diagnosis and treatment of pericardial effusions. *Am J Cardiol.* 1998;82(1):124-6.

9. Liu HP, Chang CH, Lin PJ, Hsieh HC, Chang JP, Hsieh MJ. Thoracoscopic management of effusive pericardial disease: indications and technique. *Ann Thorac Surg.* 1994;58(6):1695-7.
10. Liberman M, Labos C, Sampalis JS, Sheiner NM, Mulder DS. Ten-year surgical experience with nontraumatic pericardial effusions: a comparison between the subxyphoid and transthoracic approaches to pericardial window. *Arch Surg.* 2005;140(2):191-5.
11. Lewis RJ, Caccavale RJ, Sisler GE, Mackenzie JW. One hundred consecutive patients undergoing video-assisted thoracic operations. *Ann Thorac Surg.* 1992;54(3):421-6.
12. Geissbühler K, Leiser A, Fuhrer J, Ris HB. Video-assisted thoracoscopic pericardial fenestration for loculated or recurrent effusions. *Eur J Cardiothorac Surg.* 1998;14(4):403-8.
13. Van Trigt P, Douglas J, Smith PK, Campbell PT, Wall TC, Kenney RT, et al. A prospective trial of subxyphoid pericardiotomy in the diagnosis and treatment of large pericardial effusion: a follow-up report. *Ann Surg.* 1993;218(6):777-82.
14. McDonald JM, Meyers BF, Guthrie TJ, Battafarano RJ, Cooper JD, Patterson GA. Comparison of open subxyphoid pericardial drainage with percutaneous catheter drainage for symptomatic pericardial effusion. *Ann Thorac Surg.* 2003;76(3):811-5.