

# Fontan postoperative complication: antegrade pulmonary flow

## *Complicação pós-operatória de Fontan: fluxo pulmonar anterógrado*

Carla TANAMATI<sup>1</sup>, Vanessa Alves GUIMARÃES<sup>2</sup>, Juliano Gomes PENHA<sup>3</sup>, Miguel Lorenzo BARBERO-MARCIAL<sup>4</sup>

RBCCV 44205-1259

### CLINICAL DATA

In the period from January 2003 to December 2008, 152 operations of total cavopulmonary connections were performed in our department, 106 (71.2%) with extracorporeal circulation and 46 (28.8%) without this procedure. The ligation of the pulmonary trunk was performed with the use of cardiac tape attached to the pulmonary trunk wall with three separate polypropylene sutures 5-0 in 131 cases (86.1%). The transthoracic echocardiography with color-flow mapping performed before hospital discharge showed no residual antegrade flow.

The suspected diagnosis of pulmonary residual flow was performed by auscultation of systolic murmur over the pulmonary area, and confirmed by echocardiogram.

### Case 1

An 11-year-old female, 24.9 kg, with a diagnosis of transposition of great arteries with hypoplastic left ventricle and pulmonary stenosis, who underwent atrial septostomy on her third day of life, a right modified Blalock when she was 1 year and 2 months, and bidirectional Glenn + Fontan operation with an extracardiac conduit and pulmonary artery ligation without extracorporeal circulation at 8 years old. In the late postoperative period, 2 years after surgery, the mother reported fatigue and eyelid edema in the morning.

During diagnostic investigation, doppler echocardiography showed antegrade pulmonary flow (gradient of 81 mmHg) and origin of the pulmonary arteries stenosis, especially on the left. The magnetic angioresonance showed critical stenosis of the left pulmonary artery and aneurysm of the proximal stump of the pulmonary trunk (Figure 1).

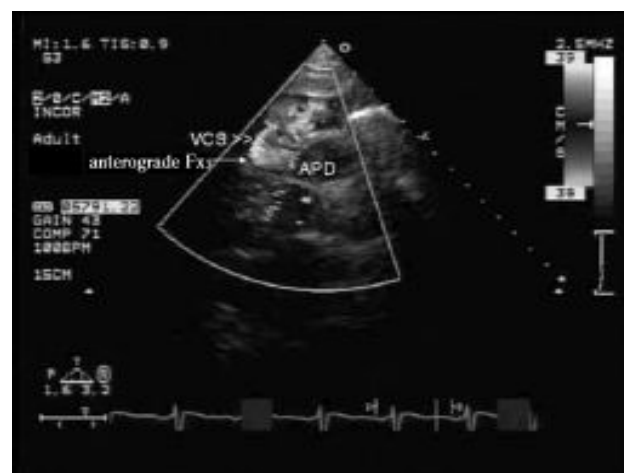


Fig. 1 - Aneurysms of the pulmonary trunk and branch pulmonary stenosis caused by banding  
SVC - superior vena cava, RPA - right pulmonary artery

1. Faculty Member of FMUSP; Medical Assistant - Pediatric Cardiac Surgery at the Heart Institute, Clinical Hospital at the University of Sao Paulo Medical School.
2. Medical Assistant - Postoperative Recovery at the Heart Institute - FMUSP; Medical Assistant - Postoperative Recovery at the Heart Institute - HCFMUSP.
3. Physician Assistant - Pediatric Cardiac Surgery at the Heart Institute - FMUSP Medical Assistant - Pediatric Cardiac Surgery at the Heart Institute - HCFMUSP.
4. Full Professor of Pediatric Cardiac Surgery, University of São Paulo; Full Professor of Pediatric Cardiac Surgery at the University of Sao Paulo and Coordinator of the Pediatric Heart Transplant.

Study conducted the Heart Institute of the University of São Paulo Medical School.

Correspondence address:  
Carla Tanamati.

44 Dr. Eneas de Carvalho Aguiar Street, Cerqueira Cesar, Sao Paulo, SP, Brazil. Zipcode: 05403-000.  
E-mail: ctanama@terra.com.br

Article received on June 18<sup>th</sup>, 2010  
Article approved on December 1<sup>st</sup>, 2010

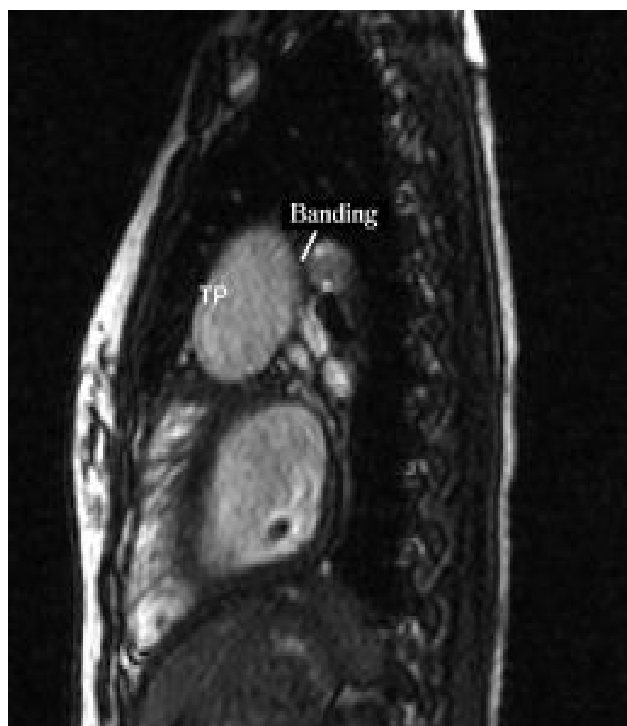


Fig. 2 - Transthoracic echocardiography with preoperative color flow mapping showing competition of flow between antegrade pulmonary flow and superior vena cava

During reoperation with extracorporeal circulation at 20 ° C, the aneurysmal pulmonary trunk (6 cm) was dissected and sectioned. The pulmonary valve became dilated and was closed with a pulmonary homograft patch and, the proximal stump of the pulmonary trunk was closed with a double suture. The distal stump of the pulmonary trunk was closed with a pulmonary homograft patch with suture (Figure 2). The left pulmonary artery was enlarged with a pulmonary homograft patch. The post-operative (PO) recovery was satisfactory, being extubated on the first PO day and discharged from the hospital on the 14th PO day.

### Case 2

A 12-year-old female, diagnosed with tricuspid atresia with pulmonary stenosis (IB) and right pulmonary artery stenosis. This patient underwent the bidirectional Glenn operation and enlargement of the right pulmonary artery at 2 years and Fontan operation with extracardiac conduit with extracorporeal circulation and ligation of the pulmonary trunk at 12 years old of age. On the 40th PO day, the patient was readmitted to the emergency room with signs of congestive heart failure with hepatomegaly and venous stasis. Auscultated systolic murmur was performed over the pulmonary area. The echocardiography with color-flow

mapping showed residual pulmonary flow and retrograde flow in vena cava (Figure 3). In surgical intervention with extracorporeal circulation, the section and suturing of the pulmonary trunk were performed, comprising the pulmonary valve. The postoperative evolution was satisfactory and on the 23rd PO day the patient was discharged.

**Case 3** A 12-year-old male, diagnosed with tricuspid atresia with dextrocardia, underwent atrial septectomy at 1 year and total cavopulmonary connection with extracardiac conduit with extracorporeal circulation 7 years old of age. In the 10th month of postoperative auscultated systolic murmur over the lung and, an attempt of pulmonary artery occlusion by catheterization were unsuccessful. Echocardiogram showed important flow competition with auto contrast in the superior vena cava and in the catheterization, origins of the pulmonary artery stenosis and anastomosis of the inferior vena cava with the extracardiac conduit. During reoperation, extracardiac conduit was changed, pulmonary arteries were enlarged with bovine pedicardim and the pulmonary trunk was sectioned and sutured. The patient has evolved in the postoperative period without intercurrent with echocardiogram showing normal ventricular systolic function and no signs of obstruction. He was discharged on the 14th day on the use of furosemide, marevan and enalapril.

### DISCUSSION

The ligation of the pulmonary trunk in total cavopulmonary operation was described by Fontan and Baudet [1] in 1970.

At the Heart Institute of the Clinical Hospital at the University of Sao Paulo Medical School, in three cases (2.3%) of ligation of the pulmonary trunk in Fontan operation (n = 131), surgical intervention was necessary due to the presence of residual antegrade pulmonary flow and / or pulmonary stenosis.

The presence of additional pulmonary flow in Fontan operations causes a competition between the pulmonary flow and venous return of vena cava, leading into increased pulmonary pressure, venous stasis and Fontan circulation failure [2].

The migration of the distal banding can lead to pulmonary branches stenosis, increasing the resistance to pulmonary flow, hampering the Fontan passive systemic venous drainage and increasing the "single ventricle" postload.

The diagnosis of clinical suspicion of recanalization of the pulmonary trunk is the presence of systolic murmur over the lung and clinical features of right congestive heart failure.

The echocardiography confirmed the presence of residual antegrade pulmonary flow and pulmonary branches

stenosis, and supplemented by angiotomography, angioresonance or cardiac catheterization.

The surgical reintervention should be carried out in clinical features with congestive heart failure or signs of pulmonary artery obstruction. During reoperation with the aid of extracorporeal circulation, the pulmonary trunk is dissected and sectioned. The proximal stump is closed comprising the pulmonary valve with double suture and, the same process happens to distal stump, or it is closed with a pulmonary homograft patch. The enlargement of the pulmonary arteries was performed using bovine pericardium (one case) and pulmonary homograft (one case). The postoperative evolution was satisfactory.

The risk of recanalization of the pulmonary trunk after ligation of the trunk can occur at any time during the postoperative period. The suspected diagnosis is performed by the presence of heart murmur over the lung and clinical features of congestive heart failure. The diagnosis is confirmed by echocardiography and branch pulmonary artery stenosis by angiotomography of pulmonary artery or catheterization.

Another complication related to the ligation of the pulmonary artery after Fontan operation is the thrombus formation in the proximal portions of the pulmonary trunk with systemic embolization [3]. The treatment consists of surgical removal of thrombus and pulmonary valve closure.

In our institution, the ligation of the pulmonary artery used to be routinely performed in the Fontan operation due to its technical ease, however, after these complications,

we have been seeking for direct pulmonary valve closure or a patch placement, or even the section and suturing of the pulmonary trunk.

#### CONCLUSION

The recanalization risk of the pulmonary trunk after ligation of the pulmonary trunk can occur at any time of the postoperative period. The diagnosis is performed †by the presence of heart murmur and clinical features of congestive heart failure and confirmed by echocardiography, pulmonary angiography or angiotomography of pulmonary arteries.

The patients with ligation of the pulmonary trunk should be monitored in order to assess these complications.

#### REFERENCES

1. Fontan F, Baudet E. Surgical repair of tricuspid atresia. *Thorax*. 1971;26(3):240-8.
2. Fantini FA, Gontijo B, Martins C, Lopes RM, Vrandecic EC, Goulart E, et al. Operação de Fontan: uma técnica em evolução. *Rev Bras Cir Cardiovasc*. 2009;24(4):463-9.
3. Madan N, Robinson BW, Jacobs ML. Thrombosis in the proximal pulmonary artery stump in a Fontan patient. *Heart*. 2002;88(4):396.