

Ventricular assist device implantation with CentriMag VAS[®] for biventricular mechanical support

Assistência ventricular com implante do dispositivo CentriMag VAS[®] para suporte mecânico biventricular

João Roberto Breda¹, MD, PhD; Diego Felipe Gaia¹, MD, PhD; Murilo Macedo¹, MD; Pedro Motta¹, MD; Márcio Martins¹, MD; Daniel Alves¹, MD; Andre Luppi¹, MD; José Honório Palma¹, MD, PhD

DOI: 10.5935/1678-9741.20130061

RBCCV 44205-1487

Abstract

Despite recent advances in acute heart failure treatment, actual results remain limited in refractory cardiogenic shock. Temporary ventricular assist devices have emerged as an alternative in this serious and challenging medical. The purpose of this communication is to present a case of refractory cardiogenic shock, underwent temporary left ventricular assistance device implantation, progressing to right ventricular failure and conversion to biventricular support.

Descriptors: Shock, cardiogenic. Ventricular dysfunction, right. Ventricular dysfunction, left.

Resumo

Apesar dos avanços no tratamento de portadores de insuficiência cardíaca aguda, os resultados permanecem insatisfatórios nos portadores de choque cardiogênico refratário. Uma opção para o tratamento dessa desafiadora e grave situação clínica é o implante de dispositivos de assistência ventricular temporária. O objetivo desta comunicação é apresentar um caso de choque cardiogênico refratário, com indicação de assistência ventricular, que evoluiu com falência ventricular direita após o implante de assistência esquerda com necessidade de conversão para o suporte biventricular.

Descritores: Choque cardiogênico. Disfunção ventricular direita. Disfunção ventricular esquerda.

INTRODUCTION

Despite recent advances in the treatment of acute heart failure, results remain unsatisfactory for patients with refractory cardiogenic shock. These patients are often referred to specialized centers when it is too late, which leads to adverse results. Temporary ventricular assist devices

offer an alternative for the treatment of this serious and challenging medical issue. Although there are still some doubts about the ideal type of assistance, the length of stay of the device, and the best time to start long-term treatment, this technology should be more employed and disseminated [1]. Initially, these devices were used in case of heart failure after the removal of cardiopulmonary bypass during open heart

¹ Universidade Federal de São Paulo (UNIFESP), São Paulo, SP, Brazil.

Work performed at Universidade Federal de São Paulo (UNIFESP), São Paulo, SP, Brazil.

Correspondence Address:

João Roberto Breda
UNIFESP - Rua Borges Lagoa, 1080 - Vila Clementino, São Paulo, SP, Brazil. Zip code: 04038-002.
E-mail: jrbreda@hotmail.com.br

Article received on November 22nd, 2012

Article accepted on March 7th, 2013

Abbreviations, acronyms & symbols

CI	Cardiac index
CO	Cardiac output
CPB	Cardiopulmonary bypass
RV	Right ventricle

surgery; however, their use has changed and spread to other kinds of therapy, such as support therapy for patients waiting for a heart transplant or as a choice of destination therapy.

The Levitronix CentriMag (Levitronix LLC, Waltham, Mass) - Ventricular Assist System (VAS)® device has been especially designed for the treatment of patients with acute cardiogenic shock of any kind, including: acute myocardial infarction, myocarditis, postcardiotomy, and complications after procedures carried out in the hemodynamic laboratory. It can be used for the support of the left or right ventricles as well as for biventricular support. In addition, since its handling and implantation are considered easy, the device can even be used in centers where prolonged ventricular assistance programs and heart transplants are not available [2].

Several authors have established an increase in mortality of patients with right ventricular dysfunction after they were treated with these devices. They concluded there is a need to identify factors predictive of right ventricular failure after left ventricular assist device implant, making it possible to decide for biventricular implantation preoperatively [3].

The purpose of this communication is to present a case of refractory cardiogenic shock, in which the patient underwent left ventricular assist device implantation, progressing to right ventricular failure, and subsequent conversion to biventricular support.

CLINICAL CASE

A 36-year-old male was admitted to the Intensive Care Unit after a two-week stay at another hospital with clinical, hemodynamic, and echocardiographic picture suggestive of severe refractory cardiogenic shock (he was using more than one vasoactive drug at optimized doses). The patient had had viral myocarditis two years before and had been suffering from progressive dyspnea, which had worsened in the previous six months. A month before being admitted, there was intensive worsening with dyspnea at rest, orthopnea, paroxysmal nocturnal dyspnea, and anasarca.

Upon admittance, hemodynamic monitoring was performed through the insertion of a Swan-Ganz catheter, with the following parameters: cardiac index (CI) at 1.3 L/min/m², cardiac output (CO) at 2.5 L/min, right atrium pressure at 18 mmHg, pulmonary artery pressure at 66x30 mmHg, and pulmonary capillary pressure at 23 mmHg. The chest radiograph can be seen in Figure 1. The two-dimensional transthoracic echocardiography showed severely impaired

left ventricular function (ejection fraction of 16%), with mild to moderate right ventricular dysfunction.

After discussing the refractory cardiogenic shock diagnosis with several experts, the recommended procedure was emergency temporary left ventricular assist device implantation, with the Levitronix CentriMag (VAS)® device. The procedure was performed with normothermic cardiopulmonary bypass (CPB), without aortic clamping. Suitable cannulas were inserted at the left ventricle apex and ascending aorta. After the removal of CPB, the device was set for 3200 rotations per minute (RPM) with a flow of 4.5 L/min/m² and continuous infusion of vasoactive drugs. Postoperative hemodynamic conditions were improved, with the return of diuresis (approximately 1 ml/Kg/hour), venous oxygen saturation of 75%, and serum lactate of 22 mmol/L. Six hours after the procedure, the patient was awake and had neither neurological deficits nor bleeding from coagulopathy.

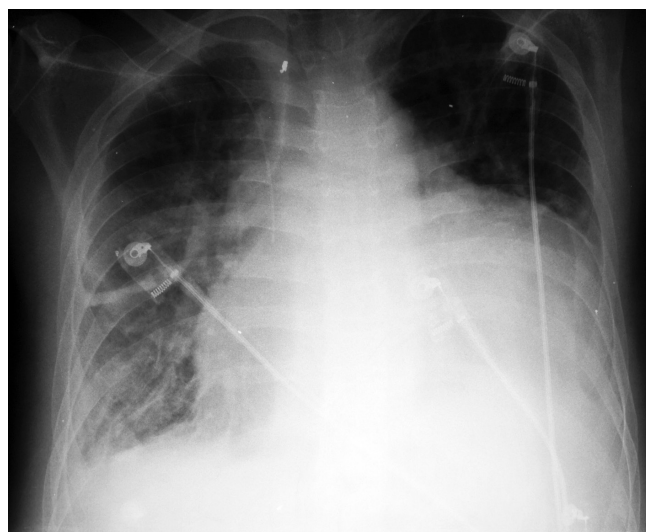


Fig. 1 – Chest radiograph

However, after 12 postoperative hours, there was substantial reduction in urine volume, increase in the right atrium pressure, and decrease in the pulmonary artery pressure. The right ventricular failure diagnosis was corroborated by the echocardiography, which showed there was a sharp decrease in right ventricular contractility. Consequently, the patient was once again taken to the operating room for right ventricular assist implantation, with pulmonary artery and right atrium cannulation, without CPB (Figure 2). Once appropriate flows were established (kept at 10% less on the right side), the patient was taken to the postoperative unit. Even though the biventricular assist device and the optimized vasoactive drugs were working properly, evolution was unsatisfactory with the development of anuria and a hard

to control coagulopathy (liver failure), leading to death 38 hours after the procedure.

The indication of the procedure was carried out according to ethical principles. Both the patient and his relatives agreed to the procedure and signed the informed consent form provided by the hospital.

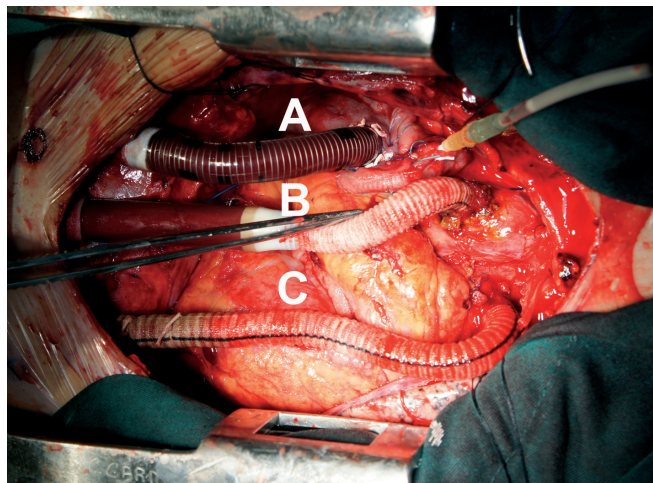


Fig. 2 – A – Right atrium cannula; B – Ascending aorta cannula; C – Pulmonary artery cannula

DISCUSSION

Temporary assist devices are used as rescue therapy in order to re-establish hemodynamic conditions and avoid multiple organ failure, until a decision is made regarding whether to have prolonged assistance or a heart transplant. It is important to note that clinical and hemodynamic criteria are used in the selection of candidates for mechanical circulatory support devices implantation. Some of the important clinical factors taken into consideration are: age (65 to 70 years-old), refractory cardiogenic shock due to the use of vasoactive drugs in high doses combined with persistent hypotension, and preoperative factors associated with poor prognosis (acute liver or renal failure, cerebrovascular disease, active infectious process, and thrombocytopenia). Hemodynamic factors are important for the likely identification of right, left, and/or biventricular failure, and are obtained by determining cardiac index, right atrium pressure, pulmonary capillary pressure, and systolic arterial pressure.

In the case being presented in this communication, the fact the patient was young was taken into consideration. In addition, despite the severity of the hemodynamic conditions at the time of admittance, no clinical criteria that would prevent a circulatory support device implantation were identified. On the contrary, there was the potential benefit of

avoiding multiple organ failure by re-establishing systemic perfusion. Preoperative laboratory evaluations did not reveal any alterations in liver and kidney function parameters, nor thrombocytopenia, underscoring the need for immediate support.

The choice of this device was based on its versatility, mono- or biventricular support, and the possibility of interposition of oxygenator for ventilatory support, if needed. Moreover, the device could be used for several weeks until destination therapy was chosen and cannulas that were exteriorized in the chest could be used for a long-term device. After a multidisciplinary discussion, it was decided a long-term device would be a better option than ECMO (Extracorporeal membrane oxygenation) considering that, currently, it takes a long time for a heart to be available for transplant.

Despite the great technological advances of these devices, mortality in this group of patients remains high due to complications such as infection, bleeding, and embolism [3]. In 2011, a multicenter study with the CentriMag (VAS)® device described the effectiveness of the pump in emptying both ventricles and acting as a biventricular circulatory support in cases of cardiogenic shock. Overall mortality was 47% out of 38 patients and the benefits of using the device included: easy handling and implantation, low incidence of complications related to the device, and support until final course of treatment [1]. In 2012, the results of the use of Centrimag (VAS)® in 12 patients with cardiogenic shock and multiple organ dysfunction, published by John et al., showed overall survival of 75% thirty days after the implantation [4].

In the present case, the ease of both handling and implantation of the Centrimag (VAS)® device was confirmed; however, right ventricular failure was considered a major factor in the adverse development which culminated in the employment of biventricular support. Although the initial intention was the immediate implantation of the biventricular device, it was decided not to do so because of the hemodynamic conditions after left ventricular support implantation (after removal of CPB, it was noted there was improvement in right ventricular contractility, as confirmed by clinical, hemodynamic, and echocardiography parameters). It seems essential to predict right ventricular failure. Fitzpatrick et al. [5] have shown that the conversion from left to biventricular support have worse results when compared to an insertion that had been previously indicated and performed at the same time. Furthermore, the authors demonstrated that despite a higher mortality in the biventricular support group, survival rate after transplant is the same in both groups (mono- or biventricular).

After reviewing the case, it became apparent the decision not to implant the biventricular support may have influenced the evolution, considering the subsequent conversion to the biventricular system. For this reason, in another related

publication, Fitzpatrick et al. [6] showed the main factors involved in right ventricular failure are: cardiac index (below 2.2 L/min/m²), right ventricular (RV) systolic work index (below 0.25 mmHg), severe preoperative RV dysfunction, higher levels of plasma creatinine (above de 1.9 mg/dL), previous cardiac surgery, and systolic arterial pressure below 96 mmHg.

There have been many advances in the treatment of patients with chronic heart failure; however, in cases of severe cardiogenic shock, results are still below expectations. Many times, unfavorable results are related to unavailability of mechanical ventricular support as well as the critical conditions of patients referred to specialized centers. In the case presented in this communication, the need for biventricular support after the mono-ventricular implantation was highlighted as a complicating factor.

Authors' roles & responsibilities	
JRB	Main author, writing and documentation
DFG	Review of the paper
MM	Data collection
PM	Data collection
MM	Data collection
DA	Data collection
AL	Bibliographic research
JHP	Review and guidance

REFERENCES

1. John R, Long JW, Massey HT, Griffith BP, Sun BC, Tector AJ, et al. Outcomes of a multicenter trial of the Levitronix CentriMag ventricular assist system for short-term circulatory support. *J Thorac Cardiovasc Surg.* 2011;141(4):932-9.
2. Mueller JP, Kuenzli A, Reuthbuch O, Dasse K, Kent S, Zuend G, et al. The CentriMag: a new optimized centrifugal blood pump with levitating impeller. *Heart Surg Forum.* 2004;7(5):E477-80.
3. Worku B, Naka Y, Pak SW, Cheema FH, Siddiqui OT, Jain J, et al. Predictors of mortality after short-term ventricular assist device placement. *Ann Thorac Surg.* 2011;92(5):1608-12.
4. John R, Liao K, Lietz K, Kamdar F, Colvin-Adams M, Boyle A, et al. Experience with the Levitronix CentriMag circulatory system as a bridge to decision in patients with refractory acute cardiogenic shock and multisystem organ failure. *J Thorac Cardiovasc Surg.* 2007;134(2):351-8.
5. Fitzpatrick JR 3rd, Frederick JR, Hiesinger W, Hsu VM, McCormick RC, Kozin ED, et al. Early planned institution of biventricular mechanical circulatory support results in improved outcomes compared with delayed conversion of a left ventricular assist device to a biventricular assist device. *J Thorac Cardiovasc Surg.* 2009;137(4):971-7.
6. Fitzpatrick JR 3rd, Frederick JR, Hsu VM, Kozin ED, O'Hara ML, Howell E, et al. Risk score derived from pre-operative data analysis predicts the need for biventricular mechanical circulatory support. *J Heart Lung Transplant.* 2008;27(12):1286-92.