

# Replacement of pulmonary artery trunk in sheep using tubular valved heterograft in non-aldehydic preservation

*Substituição do tronco da artéria pulmonar em carneiros utilizando heteroenxerto tubular valvado com preservação não-aldeídica*

Helmngton José Brito de Souza<sup>1</sup>, José Honório de Almeida Palma<sup>2</sup>, Ivan Sérgio Joviano Casagrande<sup>3</sup>, Sérgio Campos Christo<sup>4</sup>, Luiz Sérgio Alves-Silva<sup>5</sup>, Marco Antônio Cardoso de Almeida<sup>6</sup>, Diego Felipe Gaia<sup>7</sup>, Enio Buffolo<sup>8</sup>

DOI: 10.5935/1678-9741.20120071

RBCCV 44205-1402

## Abstract

**Introduction:** The cardiac bioprostheses are related to thromboembolic events, infectious and degenerative diseases. Wear is mainly attributed to the denaturation of collagen. Glutaraldehyde, the predominant method of preservation of bioprostheses, favors the calcification process and limits their durability. Several techniques try to contain the degenerative process of bioprostheses.

**Objectives:** To evaluate the process of calcification in vivo pulmonary valve heterografts preserved in non-aldehydic (L-Hydro®).

**Methods:** Seventeen sheep underwent replacement of the pulmonary artery valved tubular grafts of bovine

pericardium. The animals were divided into two groups: Group L-Hydro® (test / n = 14) and Group Glutaraldehyde (control / n = 3). About 150 days after implantation the animals were sacrificed, necropsied and implants subjected to a pathological study, radiological evaluation and measurement of calcium by atomic absorption spectrophotometry. Statistical analysis was obtained through the Fisher's exact test, Student's t or Mann-Whitney test (significance: 5%).

**Results:** The radiological evaluation, the macroscopic and microscopic measurement of serum calcium by atomic absorption spectrophotometry showed increased calcification of the prosthetic group Glutaraldehyde, when compared to

1. PhD in Cardiovascular Surgery, Surgeon, Federal University of São Paulo (UNIFESP), Paulo Medical School, São Paulo, SP, Brazil.
2. Tenured Professor, MD, Associate Professor of the Federal University of São Paulo (UNIFESP), Paulo Medical School, São Paulo, SP, Brazil.
3. Cardiovascular surgeon, Labcor Laboratory, Belo Horizonte, MG, Brazil.
4. Cardiovascular surgeon, Labcor Laboratory, Belo Horizonte, MG, Brazil.
5. Cardiologist.
6. Pathologist.
7. PhD in Cardiovascular Surgery; Associate Professor at the Federal University of São Paulo (UNIFESP), Paulo Medical School, São Paulo, SP, Brazil.

8. Titular Professor of Cardiovascular Surgery, Federal University of São Paulo (UNIFESP), Paulo Medical School, São Paulo, SP, Brazil.

Work carried out at Universidade Federal de São Paulo (UNIFESP), Escola Paulista de Medicina, São Paulo, SP, Brazil, and Centro de Pesquisa Labcor Laboratório, Belo Horizonte, MG, Brazil.

Correspondence adress: Helmngton José Brito de Souza  
Rua Napoleão de Barros, 715 - 3º andar  
São Paulo, SP, Brazil – Zip code: 04024-002  
E-mail: helmngton@uol.com.br

Article received on January 29<sup>th</sup>, 2012

Article accepted on June 25<sup>th</sup>, 2012

#### Abreviaturas, acrônimos e símbolos

PEG	Poliétilenoglicol
SPSS	Statistical Package for the Social Sciences
UNIFESP	Universidade Federal de São Paulo

denture-HydroR Group L ( $P = 0.001$ ). Seven animals in Group L-Hydro® (50%) had adherence of the leaflets to the wall of the tube ( $P = 0.228$ ).

**Conclusions:** Prostheses preserved in L-Hydro® were more resistant to calcification when compared with glutaraldehyde preserved.

**Descriptors:** Bioprosthesis. Glutaral. Polyethylene glycols. Heart valve prosthesis. Heart valve diseases/surgery.

#### Resumo

**Introdução:** As biopróteses valvares cardíacas estão relacionadas a eventos tromboembólicos, infecciosos e degenerativos. Seu desgaste é atribuído principalmente à desnaturação do colágeno. O glutaraldeído, método predominante de preservação de biopróteses, favorece o processo de calcificação e limita sua durabilidade. Diversas técnicas tentam conter o processo degenerativo das biopróteses.

**Objetivo:** Avaliar o processo de calcificação, *in vivo*, de heteroenxertos pulmonares valvados, preservados em meio não-aldeídico (L-Hydro®).

**Métodos:** Dezesete carneiros foram submetidos à substituição do tronco da artéria pulmonar por enxerto tubular valvado de pericárdio bovino. Os animais foram distribuídos em dois grupos: Grupo L-Hydro® (teste /  $n=14$ ) e Grupo Glutaraldeído (controle /  $n=3$ ). Cerca de 150 dias pós-implante os animais foram sacrificados, necropsiados e as próteses submetidas a estudo anatomopatológico, avaliação radiológica e dosagem do cálcio por espectrofotometria de absorção atômica. A análise estatística foi obtida por meio dos testes exato de Fisher, T de Student ou Mann-Whitney (significância: 5%).

**Resultados:** A avaliação radiológica, macroscopia, microscopia e dosagem de cálcio por espectrofotometria de absorção atômica demonstraram maior calcificação nas próteses do Grupo Glutaraldeído, quando comparadas às próteses do Grupo L-Hydro® ( $P=0,001$ ). Sete animais do Grupo L-Hydro® (50%) apresentaram aderência das cúspides à parede do tubo ( $P=0,228$ ).

**Conclusões:** As próteses preservadas em L-Hydro® demonstraram-se mais resistentes à calcificação, quando comparadas às preservadas em glutaraldeído.

**Descritores:** Bioprótese. Glutaral. Polietilenoglicóis. Próteses valvulares cardíacas. Doenças das valvas cardíacas/cirurgia.

## INTRODUCTION

Patients with heart valve disease, surgical treatment when indicated, deal with an important and sensitive issue - the choice of valve replacement. The existing substitute valve, however, has significant limitations. Because they are foreign tissue to the human body, valve prostheses are associated with the risk of thromboembolic complications, degenerative and infectious diseases [1]. While mechanical prostheses, highly thrombogenic, requires long-term anticoagulant therapy, the bioprosthesis, whether cryopreserved or fixed in glutaraldehyde, have limited durability dysfunction caused mainly by progressive tissue degeneration. The degeneration of bioprosthesis continues to figure among the main issues surrounding the treatment of patients with valvular heart disease. The search for the manufacture of valve replacement through tissues has been

the subject of studies by many authors over the last sixty years [2-8]. In an attempt to reduce the wear rate and thus prolong the life of prostheses, some preservation techniques have been proposed in order to reduce the calcification process [9-15]. The bioprosthesis commonly are preserved in glutaraldehyde. This method is associated with greater aggregation of fibrin, macrophages, calcium, and thrombotic material to the surface of the prosthesis [16,17]. Glutaraldehyde contained on the surface of the prosthetic tissue is cytotoxic. The main disadvantage of glutaraldehyde fixation of bioprosthesis is the resulting tissue calcification over time [1,16,17], which favors the dysfunction and the need for surgical replacement of the prosthesis. The current challenge of tissue engineering is to study and propose the creation of replacement tissue and heart valves from biological and artificial structures that are biocompatible, non-thrombogenic, non-teratogenic,

durable and permit monitoring of the growth of the host [18-20]. Theoretically, the alternative would be to use the prosthesis, treated, allow spontaneous epithelialization with host cells [21].

Nina et al. in 2005 [22] and Santos et al. in 2007 [23] tested the method of preservation in *L-Hydro*<sup>R</sup> (PEG). The first two prostheses compared by this method with glutaraldehyde preserved bioprosthesis implanted in the mitral and aortic valves, respectively, in juvenile sheep. The prostheses treated conventionally with glutaraldehyde showed macroscopic and microscopic calcification, and deposition of thrombotic material. Those already preserved in *L-Hydro*<sup>R</sup> had spontaneous repopulation by host cells, conferring greater resistance to calcification and thrombogenicity. Rey et al. in 2011 [24] compare morphologically and functionally preserved pulmonary homograft *L-Hydro*<sup>R</sup> method, with the fresh homograft implanted in juvenile sheep, and evaluated after a period of 320 days. The authors concluded that the homograft treated by *L-Hydro*<sup>R</sup> method showed histological evidence of interstitial and endothelial cell repopulation. Recently, Furlanetto et al. in 2009 (25) demonstrated that porcine pulmonary xenograft with *L-Hydro*<sup>R</sup> preservation placed in the pulmonary position of sheep newborns and followed into adulthood presents growth of the graft, absence of calcification and preservation of pulmonary valve function.

In this context, this study advances in the evaluation of the process of spontaneous endothelialization of valve replacement, this time testing the performance of the model for preservation polyethylene (*L-Hydro*<sup>R</sup>) in valved tubular prosthesis implanted in the pulmonary artery of sheep.

### Objective

Evaluate the processes of structural degeneration *in vivo* pulmonary valve heterografts preserved in *L-Hydro*<sup>R</sup> and implanted in sheep, with a minimum observation period of five months.

### METHODS

The study was approved by the Ethics Committee of UNIFESP. Fourteen (14) animals received implantation of the bioprosthesis to be tested (*L-Hydro*<sup>R</sup>) *L-Hydro*<sup>R</sup> group (test). Three (03) animals received implants of glutaraldehyde preserved bioprosthesis control - Glutaraldehyde group (control). Animals that died before 24 hours after surgery were considered surgical deaths and were excluded from the study. Additional animals were included in the study. Animals that died before the scheduled date of sacrifice were examined and necropsied.

The prosthesis is used in a patch of corrugated bovine pericardium treated by *L-Hydro*<sup>R</sup>. The closing of the tube is made with two suture lines. A valve made of bovine

pericardium, treatment with *L-Hydro*<sup>R</sup> is fixed inside the tube. Once assembled, the pipe is tested for the competence of the valve and not checked for leaks. Approved, the prosthesis is sterilized in a solution of hydrogen peroxide and ethanol and then packed in a solution of 50% ethanol. Sterility testing is done using samples incubated in culture media FTM, Middlebrook and STB for 14 days. As soon as it is proven sterility, the prosthesis is released. The preservation technique in *L-Hydro*<sup>R</sup> consists of three distinct steps: STEP 1: Extraction of the antigens and chemical oxidation of the remaining antigens with polyethylene glycol; STEP 2: Sterilization in hydrogen peroxide; STEP 3: Inventory of the prostheses in ethanol solution at 50%.

The animals were left fasting 24 hours before surgery. Anesthetic induction was done with Thiopental (IV). The animal was intubated, placed on mechanical ventilation, nasogastric tube passed, electrocardiographic monitoring and shaving the left chest. From a left thoracotomy at the fourth intercostal space, the left lung was removed, made the opening of the pericardial sac and dissection of the pulmonary trunk. Heparinization was performed after cannulation of the ascending aorta and right atrium with the establishment of cardiopulmonary bypass with total hemodilution, normothermia and without aortic clamping. After complete division of the pulmonary trunk, the native pulmonary valve leaflets were removed. A segment of the graft of approximately 4 cm, containing the cusp was anastomosed to the proximal portion of the outflow of the right ventricle and the pulmonary trunk portion related to the bifurcation, with a continuous suture using 5-0 polypropylene thread. After hemostasis, CPB was discontinued. After replacement of the entire blood volume of the cannulas were removed and administered protamine chloride. A chest drain was placed, the pericardium and the thoracic incision closed approx. The drain was removed when the animal begins to breathe spontaneously. The animal was left under observation for a period of 07 days, after which it was referred to the vivarium after surgery. The animal continued to be observed and evaluated daily during the predetermined period of 150 days, or while he survived. Evaluation of hematological and biochemical blood was held on the 7th and 90th postoperative day, and the day of sacrifice.

After sacrifice with an injection of potassium chloride, the prostheses were explanted and subjected to macroscopic evaluation. After fixation in 10% formaldehyde, the histological study was conducted to evaluate the deposition of calcium and thrombotic material on the surface of the prosthesis. Bioprostheses were cut, dehydrated in alcohol, embedded in paraffin and sectioned in four micromeres fragments and then were treated with hematoxylin-eosin for evaluation of calcium deposits. The

slides were observed under an optical microscope by a pathologist without knowing that the group would be analyzing (assessment “blind”). Both macroscopic and microscopic evaluation, the degree of calcification was quantified (semi quantitative assessment) by considering the anatomopathological examination graduation: 0 - absent calcification, 1 - mild calcification, 2 - moderate calcification, 3 – Important calcification .

The autopsies were performed in all cases. Samples were collected using swabs for bacteriology. The samples were subjected to radiological examination to determine the distribution and intensity of calcium deposits in the valve leaflets, as well as the tube, and used a Senographe DMR mammography unit (GE, Buc. France). The degree of calcification was rated from zero to three (0-3). Fragments of the tube and the leaflets were dehydrated in an oven at 50°C and mineralized in muffle furnace at 800°C, dissolved in nitric acid (HNO<sub>3</sub> - 2.5 M) determined the amount of calcium (expressed as ug / mg dry tissue) by method of atomic absorption spectrophotometry, using the Perkin Elmer spectrophotometer of 1.000 mg/L with addition of 1% lanthanum chloride (Baucia et al., 2006).

All categorical data are expressed as proportions, whereas quantitative variables are expressed as mean ±

standard deviation. Histograms were made to assess the normal distribution of quantitative data. We chose to use Fisher’s exact test to compare the observed frequencies in L-HydroR Group (test group) with the frequencies observed in the glutaraldehyde group (control group). To compare quantitative data between groups (cases versus controls), the Student t test or Mann-Whitney test were used when appropriate. The significance level was preset at 5%. The software used was SPSS<sup>R</sup>.

## RESULTS

Nineteen animals underwent the procedure for replacing the pulmonary valved tubular graft. The operative mortality rate was 10.53% (two animals). The cause of death was hypovolemic shock secondary to intra-operative bleeding. The seventeen remaining animals were included in the study. Chart 1 summarizes the information related to the study.

In Group *L-Hydro<sup>R</sup>* Group, two animals died before sacrifice. The first, on the 86<sup>th</sup> postoperative day, the cause of death was endocarditis, confirmed by autopsy. The second animal was found dead on the 165<sup>th</sup> postoperative day, while waiting for the sacrifice. Autopsy showed no

Chart 1. Surgical data

	Gender	Weight (kg)	Age (months)	CPB (min)	Survival (days)	Size Prosthesis	Status
<b>L-Hydro® group</b>							
1	F	34	8.13	76	165	17	Death
2	M	30	7.93	93	197	17	Sacrificed
3	F	35	6.77	79	194	17	Sacrificed
4	M	30	6.13	76	151	17	Sacrificed
5	M	27	6.20	62	168	15	Sacrificed
6	M	30	7.37	100	174	17	Sacrificed
7	M	35	6.73	49	162	17	Sacrificed
8	M	35	6.73	71	162	17	Sacrificed
9	M	33	6.60	48	86	17	Death
10	M	33	6.67	28	161	17	Sacrificed
11	M	32	6.77	34	161	17	Sacrificed
12	M	32	6.77	30	162	17	Sacrificed
16	F	30	7.67	39	154	19	Sacrificed
17	M	28	8.33	35	154	19	Sacrificed
	Gender	Weight (kg)	Age (months)	CPB (min)	Survival (days)	Size Prosthesis	Status
<b>Glutaraldehyde group</b>							
13	M	35	6.30	38	161	17	Sacrificed
14	M	33	6.30	30	161	17	Sacrificed
15	M	33	6.50	25	161	17	Sacrificed

M = male, F = female. CPB – Cardiopulmonary bypass

evidence of endocarditis. There were, however, signs of respiratory infection in the right lung (congestion and edema).

The detection of calcifications, mammographic technique, the prosthesis preserved in *L-Hydro*<sup>R</sup>, was limited to the sewing area of the prosthesis (Figure 1). As the prosthesis was already preserved in glutaraldehyde, the calcification occurred in all prostheses and spread to the wall of the tube and the valve leaflets (Figure 2). The case 13 showed calcification moderate (grade 2) and cases 14 and 15, significant calcification (grade 3) (Table 1).

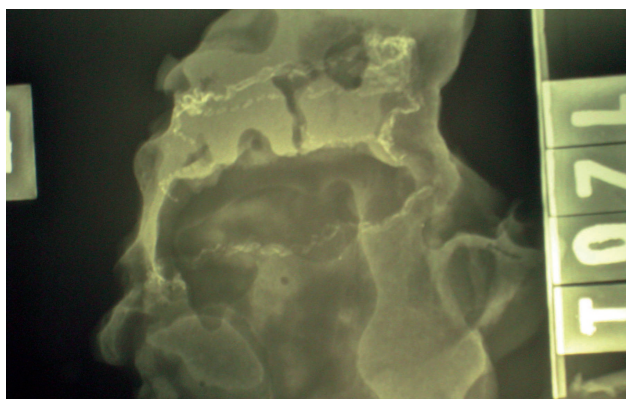


Fig. 1 - Appearance radiological graft preserved in *L-Hydro*® (no calcification)

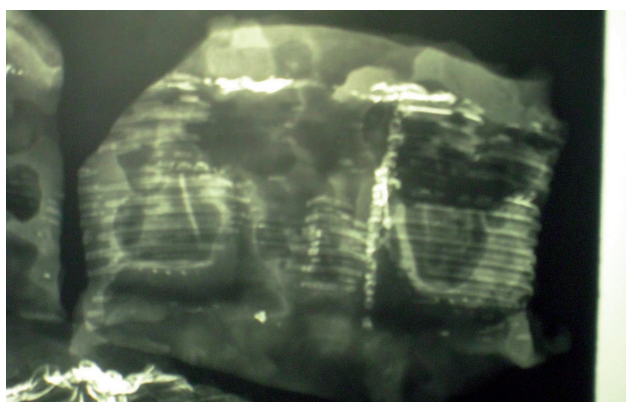


Fig. 2 - Radiological Appearance of prosthesis preserved in glutaraldehyde (diffuse calcification)

Table 1. Measurement of calcification: 0 - no calcification, 1 - mild calcification; 2 - moderate calcification, 3 - significant calcification.

L-Hydro® group	Calcification of leaflet mammography	Calcification of tube mammography
1	0	0
2	0	0
3	0	0
4	0	0
5	0	0
6	0	0
7	0	0
8	0	0
9	0	0
10	0	0
11	0	0
12	0	0
16	0	0
17	0	0
Glutaraldehyde group	Calcification of leaflet mammography	Calcification of tube mammography
13	2	2
14	3	3
15	3	3

Statistical analysis revealed significant difference ( $P = 0.001$ ) compared between groups and *L-Hydro*<sup>R</sup> Glutaraldehyde, as shown in Table 2.

Macroscopic evaluation of all prostheses in Glutaraldehyde Group showed gross calcification of the leaflets and the tube. In two of these prostheses calcification was classified as severe. But among the prostheses in *L-Hydro*<sup>R</sup> Group two (14.3%) showed calcification quantified as mild, tube. Only in one leaflet of a prosthesis was verified the presence of calcification, quantified as mild (Table 3).

Another finding was observed in the macroscopic partial or total adherence of the leaflets to the wall of the tube (Figure 3). This occurred in seven (50%) animals, all in *L-Hydro*<sup>R</sup> Group. In three animals (21.4%), all the prosthetic leaflets were attached to the tube wall. Two animals (14.3%) had adhered hum of brochures and other two animals (14.3%), two leaflets were attached to the tube wall. There

Table 2. Statical analysis of mammography (L-Hydro® and Glutaraldehyde groups).

Variable*	L-Hydro® group (n=14)	Glutaraldehyde group (n=3)	P Value†
Calcification (moderate / significant) of leaflets (mammography)	—	3 (100%)	0.001
Calcification (moderate / significant) of the tube (mammography)	—	3 (100%)	0.001

Table 3. Measurement of calcification: 0 - no calcification, 1 - mild calcification; 2 - moderate calcification, 3 - significant calcification. Assessment of adherence of leaflets.

L-Hydro® group	Calcification of leaflet	Calcification of tube	Adherence of leaflet (s)-(N)
1	0	0	3
2	0	1	0
3	0	0	0
4	0	0	2
5	1	0	0
6	0	1	0
7	0	0	1
8	0	0	1
9	0	0	3
10	0	0	0
11	0	0	3
12	0	0	2
16	0	0	0
17	0	0	0
Glutaraldehyde group	Calcification of leaflet	Calcification of tube	Adherence of leaflet (s)-(N)
13	2	2	0
14	3	3	0
15	3	3	0

(N = Number of leaflets adhered)

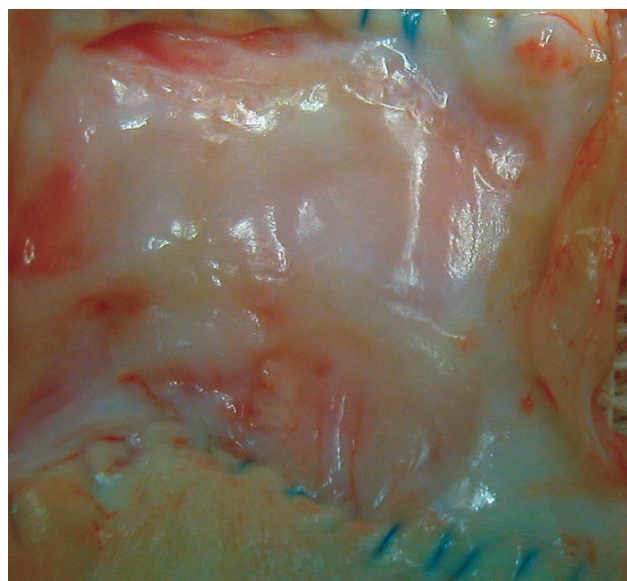


Fig. 3 - Macroscopic post-explant. Total adherence of the leaflets to the tube wall (Group L-Hydro®)

were no signs of adherence to the tube wall leaflets in the Glutaraldehyde Group.

Calcification in the variables of tubes and calcification of leaflets significant ( $P = 0.001$ ) in the comparison between *L-Hydro<sup>R</sup>* and Glutaraldehyde Groups. In the variable adherence of leaflets, this statistical difference was not observed ( $P = 0.228$ ), as shown in Table 4.

Microscopic evaluation was performed in 16 animals, 13 in *L-Hydro<sup>R</sup>* Group and three in Glutaraldehyde Group (Table 5). The staining by hematoxylin-eosin showed signs of calcification in the cusps of seven of the 13 animals in *L-Hydro<sup>R</sup>* Group (53.8%), and the tube of ten of the 13 animals of the same group (77%). This was calcification, but it was classified as mild in all cases. No animal in *L-Hydro<sup>R</sup>* Group had moderate or severe calcification of cusps or tube (Figure 4).

Microscopic examination of the animals in Glutaraldehyde Group showed significant calcification of all cusps and fragments of pipe measured. The microscopy

Table 4. Statistical analysis of macroscopy (L-Hydro® and Glutaraldehyde groups).

Variable*	L-Hydro® group (n=14)	Glutaraldehyde group (n=3)	P Value†
Calcification (moderate / significant) of the cusps (macroscopy)	—	3 (100%)	0.001
Calcification (moderate / significant) of the tube (macroscopy)	—	3 (100%)	0.001
Adherence of leaflets (microscopy)	7 (50%)	—	0.228

also showed macrophage inflammatory fibrinoid deposits and absence of thrombi or clots in the samples analyzed in both groups (Figure 5).

The statistical analysis shows significant difference ( $P = 0.001$ ) in the variables calcification of cusps and tube in the comparison between *L-Hydro*<sup>R</sup> and Glutaraldehyde

Groups (Table 6).

The dosage of calcium by atomic absorption spectrophotometry showed a higher concentration of calcium in the implants preserved in glutaraldehyde, compared to those preserved in *L-Hydro*<sup>R</sup> ( $P = 0.017$ ). Table 7 shows the values obtained from this technique.

Table 5. Measurement of calcification: 0 - no calcification, 1 - mild calcification, 2 - moderate calcification, 3 - significant calcification.

L-Hydro® group	Calcification of leaflet	Calcification of tube
1	NE	NE
2	1	1
3	1	1
4	0	0
5	1	1
6	0	1
7	0	1
8	0	0
9	1	1
10	0	1
11	1	1
12	1	1
16	1	1
17	0	0
Glutaraldehyde group	Calcification of leaflets	Calcification of tube
13	3	3
14	3	3
15	3	3

NE = Not evaluated

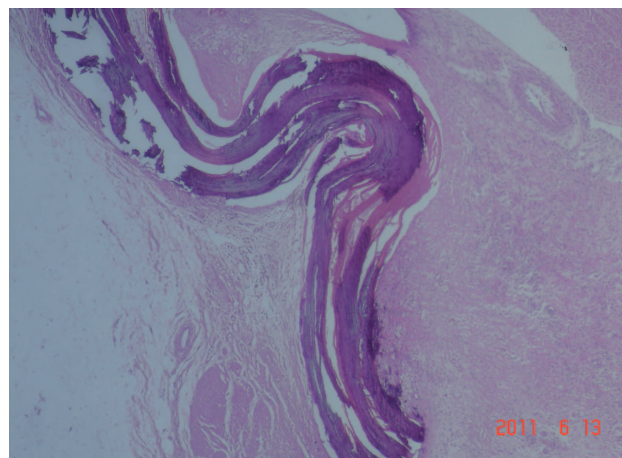


Fig. 4 - Microscopic view of the prosthesis preserved in *L-Hydro*<sup>®</sup>. Staining with hematoxylin-eosin. In lilac, isolated spots of calcification

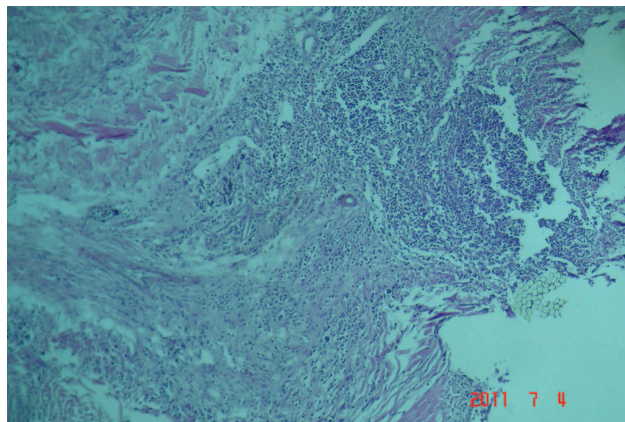


Fig. 5 - Microscopic (optical microscopy) prosthesis preserved in glutaraldehyde. Staining with hematoxylin-eosin. In lilac, diffuse regions of calcification and severe

Table 6. Statistical analysis of microscopy (*L-Hydro*<sup>®</sup> and Glutaraldehyde groups).

Variable*	L-Hydro® group (n=14)	Glutaraldehyde group (n=3)	P Value†
Calcification (moderate / significant) of the cusps (microscopy)	—	3 (100%)	0.001
Calcification (moderate / significant) of the tube (microscopy)	—	3 (100%)	0.001

Table 7. Dosing Calcium (mg/mg) by atomic absorption spectrophotometry.

L-Hydro group®	Atomic Absorption
1	43.84
2	139.44
3	48.7
4	14.2
5	25.7
6	240.9
7	206.6
8	98.3
9	58.39
10	53.76
11	38.97
12	22.4
16	64.04
17	50.01
Glutaraldehyde group	Atomic Absorption
13	318.3
14	193.32
15	720.3

## DISCUSSION

The implantation of biological valve prostheses that allow and promote spontaneous coating with host cells was proposed by Frater et al. [21] and is the principle behind the development of *L-Hydro*<sup>R</sup> preservation used in this study. In the present study, we used as a preserving agent *L-Hydro*<sup>R</sup> tube valved bovine pericardium implanted in the outflow of the right ventricle of sheep. These animals have been used by several authors and have the characteristic of being docile and allow easy handling during the test period. In the case of large animal and fast growth and development, pathophysiological changes resemble those that occur in man during life. The time of at least 150 days was necessary for the sheep present height and weight development compatible with the proper adulthood [26] can be verified or not the occurrence of calcification, as well as analyze, this type of bioprosthesis, the hemodynamic performance of the same, as far as wear.

Like the studies of Nina et al. in 2003 [22], Santos et al. in 2007 [23] and Rey et al. in 2011 [24], the radiological assessment, the present study demonstrate a significant difference in the verification of calcification of the prosthesis had preservation with *L-Hydro*<sup>R</sup>, versus those that were preserved in glutaraldehyde. The latter with a greater degree of calcification. Likewise, the example of these studies, macroscopic and microscopic evaluation showed a greater degree of calcification in bioprostheses preserved in glutaraldehyde. In relation to microscopy, the results show higher calcification of glutaraldehyde preserved grafts, as well as studies Nina et al. [22] and Santos et al. [23]. In the

case of prostheses preserved in *L-Hydro*<sup>R</sup>, Nina et al. [22], observed by scanning electron microscopy, the formation of a new endothelium-resistant exudation of plasma proteins and salts, which are precursors of bioprosthetic degeneration. In their his remarks, Nina et al. [22] concluded that the absence of toxicity, characteristic of *L-Hydro*<sup>R</sup> preservation, allowed the matrix of the prosthesis from the test group became biocompatible, allowing for spontaneous re-endothelialization, enhancing the resistance to calcification and thrombogenicity.

By scanning electron microscopy and transmission electron microscopy, Rey et al. [24] showed histological evidence of interstitial and endothelial repopulation on the surface of homografts preserved in *L-Hydro*<sup>R</sup> implanted in sheep. PEG is attributed to the immunosuppressive property, which is based on *L-Hydro*<sup>R</sup> preservation. As shown by Collins et al. in 1991 [11], antigens that are combined with PEG, have reduced antigenicity. Wicomb et al. in 1992 [15] demonstrated the reduced toxicity of PEG when added to the solution of this substance myocardial preservation, ensuring viability of the organ for a longer time when compared to conventional cardioplegic solutions.

It was observed the occurrence of adhesion of part or all of the prosthetic leaflets in *L-Hydro*<sup>R</sup> Group (seven animals), compared to Group Glutaraldehyde, where this event has not been verified. One possible explanation for this is the fact that bioprostheses preserved in *L-Hydro*<sup>R</sup> have, since its preparation, a feature thinner and more flexible compared to prostheses preserved in glutaraldehyde. As the outflow of the right ventricle a low pressure zone, the cusps more flexible would be susceptible to adhere to the tube wall. Changing the design of the prosthesis with the construction of breasts immediately above the valve could perhaps reduce the incidence of adhesions.

Accordingly, further studies testing this new type of prosthesis would allow evaluation of their performance. Rey et al. [24] in their experimental study with homografts preserved in *L-Hydro*<sup>R</sup> found from the optical microscopy, slightly retracted cusps with progressive thinning toward the free edge. The atomic absorption spectroscopy, as well as macro and microscopic evaluations, showed higher concentrations of calcium in the prosthetic Glutaraldehyde Group. There were significant, which proves the feasibility evaluation of calcium by this method [27].

This study presents a limitation to the inability to reproduce the effect of heart disease and coagulation profile comparable to that of man, like others who have used large animals in the evaluation of new technologies for preservation or replacement of cardiac tissues [5,17]. Moreover, animal models, although similar to the human anatomy, have different antigenicity, which may lead to non-reproducible results when the clinical use [12]. In the present study, replacing the pulmonary valve with atubular



graft preservation in *L-Hydro*<sup>R</sup> was suitable for evaluation as an experimental model as it allows analogy to what may occur with the human species. Preservation with *L-Hydro*<sup>R</sup> indicated significant reduction in the calcification of the tube and in the leaflets of the bioprosthesis used. New performance measures should be taken from this study, aiming at the observation and clinical applicability. The proof of the existence and viability of interstitial tissue and repopulation can be achieved through further studies.

#### CONCLUSION

The prostheses preserved in *L-Hydro*<sup>R</sup> (not aldehydic) were more resistant to the process of tissue degeneration, calcification especially when compared to those preserved in glutaraldehyde.

#### REFERENCES

1. Sodian R, Hoerstrup SP, Sperling JS, Daebritz S, Martin DP, Moran AM, et al. Early in vivo experience with tissue-engineered trileaflet heart valves. *Circulation*. 2000;102(19 Suppl 3):III22-9.
2. Barratt-Boyes BG. Homograft aortic valve replacement in aortic incompetence and stenosis. *Thorax*. 1964;19:131-50.
3. Buffolo E. Substituição da válvula aórtica ou mitral por válvula aórtica homóloga montada em suporte [Tese de doutoramento]. São Paulo:Escola Paulista de Medicina;1973.
4. Fischlein T, Fasol R. In vitro endothelialization of bioprosthetic heart valves. *J Heart Valve Dis*. 1996;5(1):58-65.
5. Schoen FJ. Future directions in tissue heart valves: impact of recent insights from biology and pathology. *J Heart Valve Dis*. 1999;8(4):350-8.
6. Palma JHF. Substituição da válvula mitral por válvula aórtica homóloga montada em suporte e conservada em glutaraldeído [Dissertação de mestrado]. São Paulo:Escola Paulista de Medicina;1988.
7. Puig LB, Verginelli G. Válvulas cardíacas de dura-máter homóloga. Nota prévia. *Rev Paul Med*. 1971;78(1):3335.
8. Puig LB, Verginelli G, Belotti G, Kawabe L, Frack CC, Pileggi F, et al. Homologous dura mater cardiac valve. *J Thorac Cardiovasc Surg*. 1972;64(1):154-60.
9. Bhayana JN, Tan ZT, Bergsland J, Balu D, Singh JK, Hoover EL. Beneficial effects of fluosol-polyethylene glycol cardioplegia on cold, preserved rabbit heart. *Ann Thorac Surg*. 1997;63(2):459-64.
10. Carpentier A, Deloche A, Relland J, Fabiani JN, Forman J, Camilleri JP, et al. Six-year follow-up of glutaraldehyde-preserved heterografts. With particular reference to the treatment of congenital valve malformations. *J Thorac Cardiovasc Surg*. 1974;68(5):771-82.
11. Collins GM, Wicomb WN, Levin BS, Verma S, Avery J, Hill JD. Heart preservation solution containing polyethyleneglycol: an immunosuppressive effect? *Lancet*. 1991;338(8771):890-1.
12. Lopes SAV, Costa FDA, Paula JB, Dhomen P, Phol F, Vilani R, et al. Análise do comportamento biológico de heteroenxertos descelularizados e homoenxertos criopreservados: estudo em ovinos. *Rev Bras Cir Cardiovasc*. 2009;24(1):15-22.
13. Schoen FJ, Levy RJ. Calcification of tissue heart valve substitutes: progress toward understanding and prevention. *Ann Thorac Surg*. 2005;79(3):1072-80.
14. Vesely I, Barber JE, Ratliff NB. Tissue damage and calcification may be independent mechanisms of bioprosthetic heart valve failure. *J Heart Valve Dis*. 2001;10(4):471-7.
15. Wicomb WN, Perey R, Portnoy V, Collins GM. The role of reduced glutathione in heart preservation using a polyethylene glycol solution, Cardiosol. *Transplantation*. 1992;54(1):181-2.
16. Grabenwöger M, Sider J, Fitzal F, Zelenka CJ, Windberger U, Grimm M, et al. Impact of glutaraldehyde on calcification of pericardial bioprosthetic heart valve material. *Ann Thorac Surg*. 1996;62(3):772-7.
17. Levy RJ. Glutaraldehyde and the calcification mechanism of bioprosthetic heart valves. *J Heart Valve Dis*. 1994;3(1):101-4.
18. Cebotari S, Tudorache I, Schilling T, Haverich A. Heart valve and myocardial tissue engineering. *Herz*. 2010;35(5):334-41.
19. Sacks MS, Schoen FJ, Mayer JE. Bioengineering challenges for heart valve tissue engineering. *Annu Rev Biomed Eng*. 2009;11:289-313.
20. Knight RL, Wilcox HE, Korossis SA, Fisher J, Ingham E. The use of acellular matrices for the tissue engineering of cardiac valves. *Proc Inst Mech Eng H*. 2008;222(1):129-43.
21. Frater RW, Gong G, Hoffman D, Liao K. Endothelial covering of biological artificial heart valves. *Ann Thorac Surg*. 1992;53(3):371-2.
22. Nina VJ, Pomerantzeff PM, Casagrande IS, Cheung DT, Brandão CM, Oliveira SA. Comparative study of the L-hydro process and glutaraldehyde preservation. *Asian Cardiovasc Thorac Ann*. 2005;13(3):203-7.

- 
23. Santos PC, Gerola LR, Casagrande I, Buffolo E, Cheung DT. Stentless valves treated by the L-hydro process in the aortic position in sheep. *Asian Cardiovasc Thorac Ann.* 2007;15(5):413-7.
  24. Rey NA, Moreira LFP, Cheung DT, Casagrande ISJ, Benvenuti LA, Stolf NAG. Estudo experimental comparativo do enxerto homólogo pulmonar tratado pelo processo L-Hydro com homoenxerto pulmonar a fresco. *Rev Bras Cir Cardiovasc.* 2011;26(2):282-90.
  25. Furlanetto G, Passerino CH, Siegel R, Chueng DT, Levitsky S, Casagrande IS. Biointegration and growth of porcine valved pulmonary conduits in a sheep model. *Asian Cardiovasc Thorac Ann.* 2009;7(4):350-6.
  26. Grehan JF, Casagrande I, Oliveira EL, Santos PC, Pessa CJ, Gerola LR, et al. A juvenile sheep model for the long-term evaluation of stentless bioprostheses implanted as aortic root replacements. *J Heart Valve Dis.* 2001;10(4):505-12.
  27. Baucia JA, Leal Neto RM, Rogero JR, Nascimento N. Tratamentos anticalcificantes do pericárdio bovino fixado com glutaraldeído: comparação e avaliação de possíveis efeitos sinérgicos. *Rev Bras Cir Cardiovasc.* 2006;21(2):180-7.