

# Coexistence of multiple mechanical complications from a single acute myocardial infarction: successful surgical treatment

*Coexistência de múltiplas complicações mecânicas decorrentes de episódio único de infarto agudo do miocárdio: tratamento cirúrgico com sucesso*

Luis Alberto Saraiva SANTOS, Marcelo Luiz Peixoto SOBRAL, Gilmar Geraldo dos SANTOS, Noedir Antonio Groppo STOLF

RBCCV 44205-783

## *Abstract*

Pseudoaneurysms of the left ventricle and subpericardial aneurysms are rare complications of acute myocardium infarctions. This article is based on the case of a 68-year-old patient who developed an interventricular communication after an acute myocardium infarction. Surgical repair of this complication resulted in the coexistence of a pseudoaneurysm and a true aneurysm of the left ventricle as a late complication. A second surgical procedure was successful, based on resection of both complications with subsequent geometric reconstruction.

*Descriptors:* Aneurysm false, surgery. Heart aneurysm, surgery. Heart ventricles, abnormalities.

## *Resumo*

Pseudoaneurisma (PsAn) de ventrículo esquerdo (VE) e aneurisma subpericárdico são complicações raras após o infarto agudo do miocárdio (IAM). Apresentamos, no presente trabalho, o caso de um paciente de 68 anos que após IAM desenvolveu comunicação interventricular (CIV). E que, após a cirurgia de correção de CIV, ocorreu a coexistência de PsAn e aneurisma verdadeiro de VE como complicação tardia. O tratamento cirúrgico foi realizado com sucesso e baseou-se na ressecção de ambas as complicações com subsequente reconstrução geométrica.

*Descritores:* Falso aneurisma, cirurgia. Aneurisma cardíaco, cirurgia. Ventriculos cardíacos, anormalidades.

Work performed in the Real and Benemérita Associação Portuguesa de Beneficência de São Paulo. São Paulo, SP, Brazil.

Correspondence address: Luis Alberto Saraiva Santos.  
Rua Dr. Alfredo Ellis, 210, apto 65. Bela Vista. São Paulo, SP.  
CEP: 01322-050.  
Phone: (11) 3262-4499 / (11)8346-9657.  
E-mail: l\_saraiva@ig.com.br

Article received in August, 2005  
Article accepted in November, 2005

## INTRODUCTION

Pseudoaneurysms (PsAn) of the left ventricle (LV) and subpericardial aneurysms are rare complications of acute myocardial infarction (AMI), with a treatment and prognosis that are still controversial [1-10]. The formation of a PsAn of the LV is most commonly found as a late complication of lower AMI [2], but may also occur after trauma, infection, surgical correction of true ventricular aneurysms, mitral valve surgery and after some other events [3-5]. When diagnosed, surgical treatment is recommended because of the risk of rupture, a potentially fatal complication [1,24-7,10].

In this work, we report on a case with an association of PsAn and true aneurysm of the LV, as a late complication of the surgical correction of an interventricular communication (IVC) after AMI.

## CARE REPORT

A 68-year-old male patient suffered AMI in February 1995, when he was successfully submitted to a primary angioplasty of the right coronary artery. The patient evolved with an interventricular communication on the following day which was diagnosed by echocardiography and surgical treatment was indicated. His evolution was satisfactory in the immediate postoperative period however, in the late postoperative period he presented with congestive heart failure (functional class III of the American Heart Association) and a residual interventricular communication was identified.

The patient was again operated on 11 months after the first surgery. He evolved asymptotically, although a control echocardiogram performed six months later showed the presence of a diskintetic area in the apical segment of the antero-lateral wall and slight mitral insufficiency. An angiographic study was performed demonstrating the coexistence of an infero-basal aneurysm and a large PsAn in the infero-lateral region (Figure 1), without any residual interventricular communication. The ejection fraction was estimated at 0.38 as there was still 90% obstruction of the anterior interventricular artery (AIV), 50% of the circumflex artery (CX) and irregularities in the right coronary artery (RC); indication for another surgical intervention.

The patient was submitted to resections of both the aneurysm and the PsAn as well as geometric reconstruction of the LV and closure with a bovine pericardium patch (BP). Additionally, revascularization of the AIV using an aorto-coronary saphenous graft was performed. The perfusion time was 100 minutes and the time of anoxia was 36 minutes, part of the procedure was achieved with the aorta clamped.

In the immediate postoperative period, the patient suffered from low cardiac output requiring high doses of vasoactive agents but evolving with hemodynamic

improvement. An echocardiogram was performed which demonstrated an improvement in the ventricular function and no IVC. The patient was released from the intensive care unit and the hospital on the 8<sup>th</sup> and 21<sup>st</sup> postoperative days, respectively. After two years of follow up the patient was in functional class I-II with an ejection fraction of 54%.

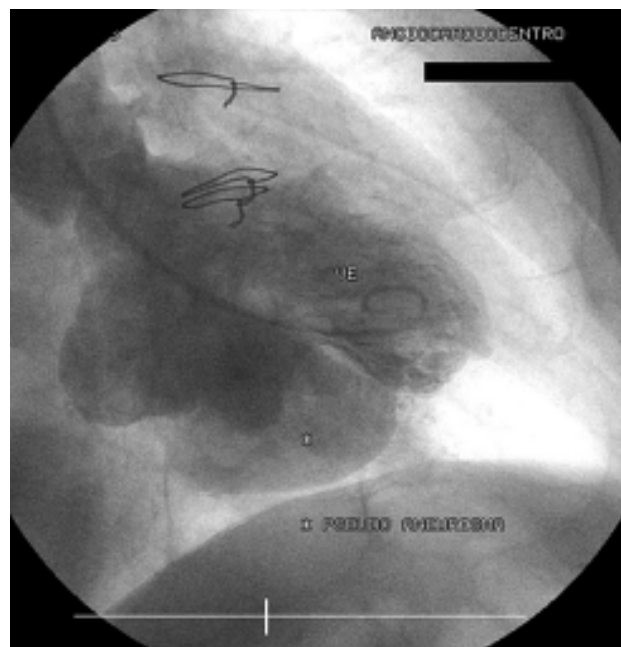


Fig. 1 - Angiographic study demonstrating the coexistence of aneurysm in the infero-basal region and a large pseudoaneurysm in the infero-lateral region

## DISCUSSION

Pseudoaneurysms of the LV occur as a late complication, normally discovered a few months after AMI. Pseudoaneurysms tend to undergo rapid increases in size making them prone to rupture indicating the necessity of surgical treatment [1,5,6,8,10,11]. The surgical mortality rate is around 7 to 23% [8].

Several etiologies related to the formation of PsAn have been identified with AMI being the most common (55% of cases) but they have been reported after heart surgery (33%), trauma (7%) and infection (5%) [7]. Postoperative PsAn are more frequent after mitral valve replacement surgeries and aneurysmectomy of the LV. These complications are etiologically related to some other factors including resection of the posterior cuspid of the mitral valve, excessive decalcification of the fibrous annulus and atrio-ventricular disjunction. In the case of postoperative resection of LV aneurysms, technical mistakes and friability of sutures are known factors that predispose patients to the formation of PsAn [7]. In the current report, the formation of

the PsAn was observed in the late postoperative period of surgery for the correction of a post-AMI IVC of the inferior wall, which we believe has never been reported before.

Perforation of the LV free wall after AMI with non-fatal evolution, is a rare complication that might result in a PsAn [2,5,6]. In rare cases, this perforation may be contained between the LV free wall and the pericardial fibrous tissue [2]. The exact diagnosis, the involved anatomic structures and the size of the perforation should be studied well for treatment to be efficacious. Apart from a detailed physical examination that may identify a systolic murmur and clinical signs of pulmonary congestion [6], complementary examinations are of fundamental importance.

In the current case, the diagnosis of PsAn was confirmed after coronary cineangiography. Moreno et al. [6] stressed the importance of echocardiography with contrast in the identification of perforations of the LV and the blood flow through this orifice.

The most common location of PsAn is the postero-lateral and lower walls of the LV; in the majority of cases related to the RC and CX arteries [5,6,11]. When the location is inferior, the echocardiogram is limited by technical difficulties [6]. In this case, the PsAn was in the inferior wall making the exact diagnosis using this examination difficult. Sorensen et al. [9] reported that magnetic nuclear resonance (MNR) may also assist in the diagnosis of diseases of this type. Harpaz et al. [8] affirmed that both MNR and transesophageal echocardiography have a diagnostic accuracy of about 75%.

The surgical strategy depends on factors such as its location and size of the perforation, the incidence of mitral insufficiency, the relationship between the orifice of the perforation and the subjacent papillary muscles, as well as the coexistence of true aneurysms [1]. Surgical management should be cautious due to the potential risk presented by possible existence of intracavitary thrombi and so the aorta should be clamped before handling the PsAn. Another alternative is to treat the PsAn during ventricular fibrillation [7]. Chronic PsAn can be closed with direct suturing due to the existence of a good region of fibrotic tissue, however when these PsAn are large and located on the inferior wall of the heart, or when they are discovered during the acute phase, the use of synthetic or bovine pericardium patches is advisable due to the excess of local traction and distortion of the CX, as well as of the coronary sinus [7]. In our department, in the majority of cases, we prefer to use patches for these defects. Repair of the mitral valve should be performed in cases of mitral insufficiency with significant hemodynamic repercussions.

The PsAn of the LV should be treated surgically and, in spite of the severity of this disease, may present with satisfactory results when correctly performed.

#### BIBLIOGRAPHIC REFERENCES

1. Fujii H, Hattori R, Osako M, Otani H, Imamura H. Patch repair of postinfarction pseudo-and subepicardial aneurysm of the left ventricle. *J Cardiovasc Surg*. 2001;42(1):49-51.
2. Kaya B, Uçanok K, Tasöz R, Ozisik K, Peker O, Tatlican O et al. Repair of a ruptured posterior left ventricular pseudoaneurysm. *Minerva Cardioangiol*. 2002;50(4):389-91.
3. Ginzo AA, Chen MH. Postoperative left ventricular pseudoaneurysm. *Tex Heart Inst J*. 2002;29(3):220-1.
4. Akinci E, Isik O, Tekümit H, Daglar B, Bozduga N, Oğus NT et al. Three ventriculoplasty techniques applied to three left ventricular pseudoaneurysms: in the same patient. *Tex Heart Inst J*. 1999;26(1):87-9.
5. Mahilmaran A, Nayar PG, Sheshadri M, Sudarsana G, Abraham KA. Left ventricular pseudoaneurysm caused by coronary spasm, myocardial infarction, and myocardial rupture. *Tex Heart Inst J*. 2002;29(2):122-5.
6. Moreno R, Zamorano JL, Almeria C, Rodrigo JL, Villate A, Serra V et al. Usefulness of contrast agents in the diagnosis of left ventricular pseudoaneurysm after acute myocardial infarction. *Eur J Echocardiogr*. 2002;3(2):111-6.
7. Prêtre R, Linka A, Jenni R, Turina MI. Surgical treatment of acquired left ventricular pseudoaneurysms. *Ann Thorac Surg*. 2000;70(2):553-7.
8. Harpaz D, Kriwisky M, Cohen AJ, Medalion B, Rozenman Y. Unusual form of cardiac rupture: sealed subacute left ventricular free wall rupture, evolving to intramyocardial dissecting hematoma and to pseudoaneurysm formation: a case report and review of the literature. *J Am Soc Echocardiogr*. 2001;14(3):219-27.
9. Sorensen MB, Moat NE, Mohiaddin RH. False left ventricular aneurysm documented by magnetic resonance imaging. *Circulation*. 2002;105(14):1734.
10. Gomes MC, Lima LCM, Gonçalves LAD, Motta GG, Reis FR, Rabelo RC et al. Pseudoaneurisma de ventrículo esquerdo por rotura cardíaca após infarto agudo do miocárdio: tratamento cirúrgico. *Rev Bras Cir Cardiovasc*. 1997;12(2):141-4.
11. Harada T, Ida T, Takano T. Cardiac pseudoaneurysm coupled with a rupture of the papillary muscle complicating myocardial infarction. *Acta Cardiol*. 2002;57(6):435-7.