

Coronary Artery Bypass Graft During the COVID-19 Pandemic

Lucas Molinari Veloso da Silveira¹, MD; Gustavo Pampolha Guerreiro¹, MD; Luiz Augusto Ferreira Lisboa¹, MD, PhD; Omar Asdrúbal Vilca Mejía¹, MD, PhD; Luís Roberto Palma Dallan¹, MD; Luís Alberto Oliveira Dallan¹, MD, PhD; Fabio B Jatene¹, MD, PhD



DOI: 10.21470/1678-9741-2020-0283

Abstract

Since the beginning of the coronavirus disease (COVID-19) pandemic, in March 2020, the number of people infected with COVID-19 worldwide increases continuously. Brazil is being followed with great concern in the international media, as it can, very soon, be the epicenter of the pandemic. Initial surgical data suggest that patients who acquire COVID-19 in the perioperative

period are prone to a higher morbidity and mortality, however, evidence in cardiac surgery is still scarce.

This article aims to aggregate to the growing evidence suggesting that perioperative infection with severe acute respiratory syndrome coronavirus 2 contributes to a more morbid evolution of the case.

Keywords: Cardiac Surgical Procedures. COVID-19. Coronavirus. Pandemia. SARS Virus. Perioperative Period.

Abbreviations, acronyms & symbols

COVID-19	= Coronavirus disease
CPB	= Cardiopulmonary bypass
ICU	= Intensive care unit
POD	= Postoperative day
SARS-CoV-2	= Severe acute respiratory syndrome coronavirus 2
STS	= Society of Thoracic Surgeons

INTRODUCTION

Since December 2019, the world is facing a unique situation: the coronavirus disease (COVID-19). COVID-19 is a viral infection caused by severe acute respiratory syndrome coronavirus 2 (SARS-CoV-2), considered a pandemic since March 11th, 2020. As of May 19th, 2020, there have been 4,731,458 confirmed cases and 316,169 deaths worldwide^[1]. In Brazil, the first case was confirmed in February 26th, 2020. Currently, Brazil is being considered the future epicenter of the pandemic, with 241,080 confirmed cases and 16,118 deaths until May 19th, 2020^[1].

As physicians are passing through real-time learning process on the management of COVID-19, patients continue to present

with other medical conditions. Unstable cardiovascular disease is one of these conditions, sometimes requiring urgent treatment.

Physicians will have to balance the risk of delaying medical (especially surgical) treatment for patients with significant cardiovascular disease—associated with high mortality in COVID-19 patients^[2]—against the risk of patients being infected with SARS-CoV-2 during the perioperative period and its consequences^[3].

There are few case reports of patients who underwent cardiac surgery and were diagnosed with COVID-19. The aim of this article is to draw the attention of adult cardiac surgeons and cardiologists regarding the management of patients considered for surgical procedures in the context of the current COVID-19 pandemic.

SCENARIO


A 63-year-old male patient with hypertension was admitted to the emergency room with non-ST-segment elevation myocardial infarction. Coronary angiogram showed severe multivessel coronary disease with a high syntax score (35.5). Transthoracic echocardiography showed preserved left ventricle ejection fraction and no other abnormalities. The calculated values of risk scores were: EuroSCORE II 1.62% and STS score

¹Cardiovascular Surgery Division, Instituto do Coração do Hospital das Clínicas da Faculdade de Medicina da Universidade de São Paulo (InCor-HCFMUSP), São Paulo, SP, Brazil.

This study was carried out at the Instituto do Coração do Hospital das Clínicas da Faculdade de Medicina da Universidade de São Paulo (InCor-HCFMUSP), São Paulo, SP, Brazil.

Correspondence Address:

Lucas Molinari Veloso da Silveira

 <https://orcid.org/0000-0002-3543-594X>

Cardiovascular Surgery Division, Instituto do Coração do Hospital das Clínicas da Faculdade de Medicina da Universidade de São Paulo (InCor-HCFMUSP)

Av. Dr. Enéas Carvalho de Aguiar, 44, São Paulo, SP, Brazil. - Zip code: 05403-900

E-mail: lucasmolinari93@gmail.com

Article received on June 4th, 2020.

Article accepted on June 24th, 2020.

0.97%. Based on the recommendations of the Brazilian health government organizations at the time, preoperative screening for COVID-19 was not performed.

Surgical procedure was performed 4 days after the patient's admission. The patient underwent CABG via full sternotomy, with cardiopulmonary bypass (CPB) and myocardial protection with intermittent cold blood cardioplegia. The targeted grafts were: left internal mammary artery to the left anterior descending artery and saphenous veins grafts to two diagonal branches and an obtuse marginal branch. The right coronary territory was not grafted due to poor targets. The patient was weaned from CPB without difficulty. After completion of the procedure, the patient was transferred to the intensive care unit (ICU)—timeline in Figure 1.

The initial postoperative course in ICU was uneventful. On postoperative day (POD) 4, the patient developed cough and atrial fibrillation with rapid ventricular response, which was controlled with amiodarone. Laboratory tests disclosed an increase in C-reactive protein of 147.50 mg/L and 5730 leukocytes/mm³ with lymphopenia—516 lymphocytes/mm³. On POD 9, he had shortness of breath and oxygen saturation of 78%. A chest computed tomography scan revealed multiple peripheral ground-glass opacities in both lungs (Figure 2 and Video 1). Quantitative reverse transcription–polymerase chain reaction for coronavirus was positive. The patient was transferred to the COVID-ICU and required mechanical ventilation.

In the COVID-ICU, he had difficulty breathing and multiple complications. The sternum became unstable and a small dehiscence of the lower segment of the sternal wound was evident, but without local signs of infection. Debridement of

sternal and subcutaneous tissues plus sternal refixation and installation of negative pressure wound therapy system were performed. Concerning his sternal wound, the patient showed a remarkable evolution and, 6 days after the first procedure, he underwent reconstruction of the sternal wound with a pectoralis muscle flap. The patient presented a favorable evolution with weaning from inotropic drugs and extubation. However, a new worsening, requiring a new intubation, occurred due to secondary pulmonary infection.

The patient persisted in the ICU with prolonged use of inotropes and mechanical ventilation, as well as multiple clinical complications until POD 40, when he died due to pulmonary infection and multiple organ failure.

DISCUSSION

Cardiac surgery has been particularly affected by the coronavirus outbreak since elective surgeries were cancelled and ward and ICU beds dedicated to cardiac surgery were reassigned to COVID-19 patients^[4]. Surgeons and cardiologists are facing a series of difficult decisions to be made, since it is necessary to balance the risk between postponing surgery in patients with significant cardiovascular disease and the risk of operating a patient in latent period of COVID-19 or acquiring nosocomial COVID-19 infection.

Data on surgical outcomes of patients with COVID-19 are rare. Lei et al.^[5] reported data from 34 patients who underwent different surgeries during the incubation period of COVID-19 and suggested that surgery may exacerbate disease progression, since the mortality rate in his cohort—20.6%—is higher than

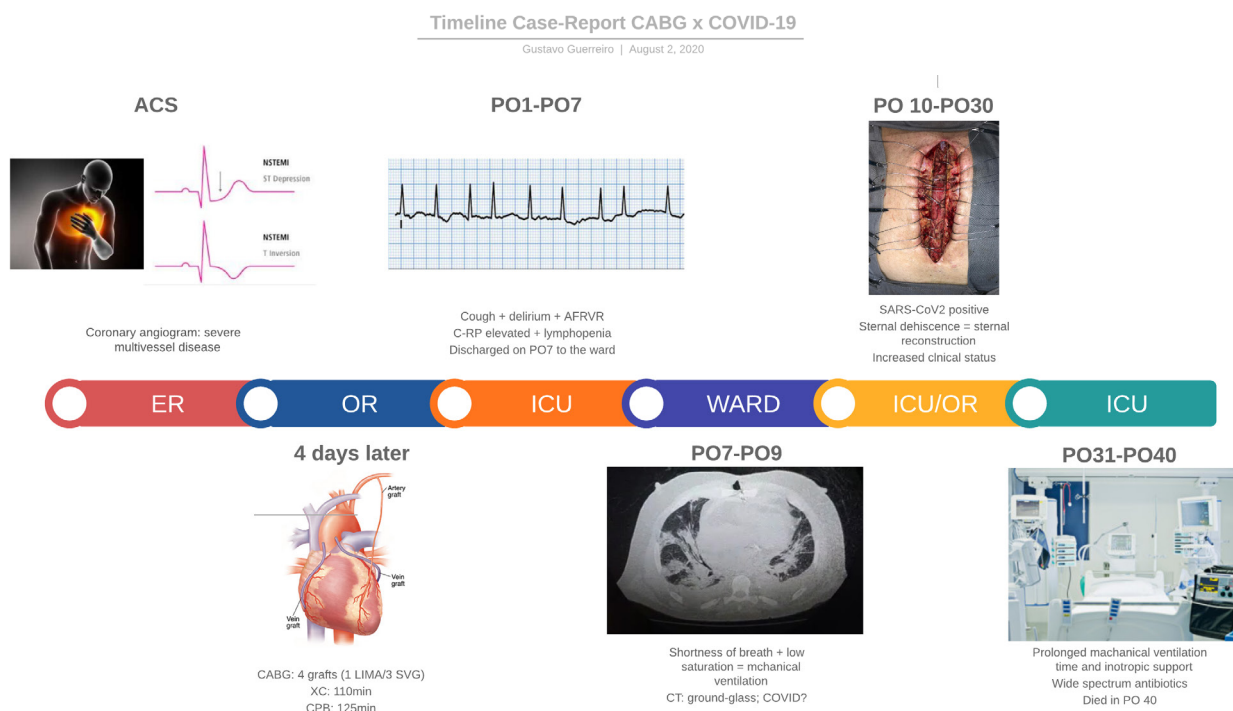


Fig. 1 – Timeline of events.

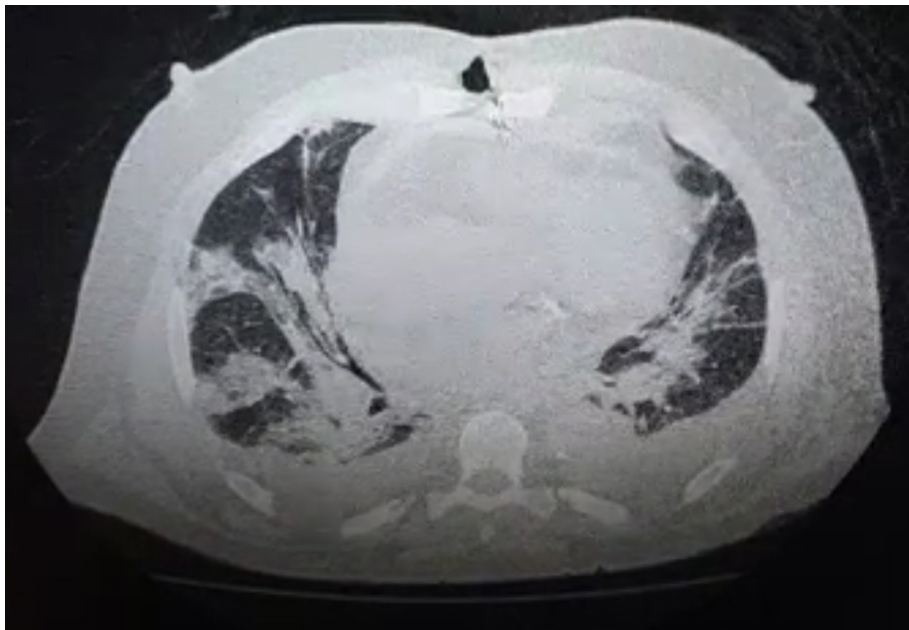

Fig. 2 - Chest CT revealing multiple peripheral ground-glass opacities.



Video 1 - Chest CT revealing multiple peripheral ground-glass opacities.

in surgical patients without COVID-19 as well as in COVID-19 patients without surgery. This may be related to impaired immune function^[6] and early systemic inflammatory response due to surgery^[7].

Patients who need cardiac surgery are likely to have a more severe presentation of COVID-19, due to their underlying cardiovascular disease, which is associated with high mortality in COVID-19^[2]. It is also suggested that these patients may be more susceptible to myocardial dysfunction—a possible complication of COVID-19—after surgery, especially if cardioplegic arrest is used^[8].

Currently, data on COVID-19 and cardiac surgery results are almost inexistent; there is only one report of in-hospital infection of a patient submitted to a CABG who died in POD 9 with COVID-19 pneumonia as a presumed cause of death^[9]. Despite the same outcome occurred in both cases, the death of our patient was due to indirect consequences—nosocomial infections—from prolonged hospital length of stay in COVID-19.

Due to the current situation, many scientific societies have published guidance statements for cardiac surgery institutions. Recommendations are based on inpatient COVID-19 load and operative capacity^[3]. Aiming to reduce perioperative morbidity, all patients should be tested preoperatively, and a positive result should elicit a Heart Team evaluation about the urgency of the case. Patients should be operated as soon as possible to reduce possible SARS-CoV-2 nosocomial infection. In this situation, some patients could be operated before the end of the period of discontinuation of antiplatelet medications.

This article adds evidence of a poor outcome in a low-risk urgent CABG patient infected with SARS-CoV-2 in the perioperative period. Unfortunately, the patient was not tested

preoperatively, and hence we cannot affirm that he was already infected when operated on. During COVID-19 pandemic, patients are liable to a more morbid postoperative course, reinforcing the importance of Heart Team evaluation for choosing the best treatment option, even in low-risk patients.

No financial support.

No conflict of interest.

Authors' roles & responsibilities

LMVS	Substantial contributions to the conception or design of the work; or the acquisition, analysis, or interpretation of data for the work; final approval of the version to be published
GPG	Substantial contributions to the conception or design of the work; or the acquisition, analysis, or interpretation of data for the work; final approval of the version to be published
L AFL	Drafting the work or revising it critically for important intellectual content; final approval of the version to be published
OAVM	Final approval of the version to be published
LRPD	Final approval of the version to be published
LAOD	Final approval of the version to be published
FBJ	Final approval of the version to be published

REFERENCES

1. World Health Organization. Coronavirus disease 2019 (COVID-19): situation report - 120. Geneva: WHO; May 2020 [cited 2020 Jul 29]. Available from: https://www.who.int/docs/default-source/coronaviruse/situation-reports/20200519-covid-19-sitrep-120.pdf?sfvrsn=515cabfb_2
2. Costa IBSDS, Bittar CS, Rizk SI, Araújo Filho AE, Santos KAQ, Machado TIV, et al. The heart and COVID-19: what cardiologists need to know. *Arq Bras Cardiol.* 2020;114(5):805-16. doi:10.36660/abc.20200279.
3. Haft JW, Atluri P, Ailawadi G, Engelman DT, Grant MC, Hassan A, et al. Adult cardiac surgery during the COVID-19 pandemic: a tiered patient triage guidance statement. *J Thorac Cardiovasc Surg.* 2020;160(2):452-5. doi:10.1016/j.jtcvs.2020.04.011.
4. Barros L, Rivetti LA, Furlanetto BH, Teixeira EM, Welikow A. COVID-19: General guidelines for cardiovascular surgeons (standard guidelines - subject to change). *Braz J Cardiovasc Surg.* 2020;35(2):I-III. doi:10.21470/1678-9741-1-2020-0604.
5. Lei S, Jiang F, Su W, Chen C, Chen J, Mei W, et al. Clinical characteristics and outcomes of patients undergoing surgeries during the incubation period of COVID-19 infection. Version 2. *EClinicalMedicine.* 2020;21:100331. doi:10.1016/j.eclinm.2020.100331.
6. Amodeo G, Bugada D, Franchi S, Moschetti G, Grimaldi S, Panerai A, et al. Immune function after major surgical interventions: the effect of postoperative pain treatment. *J Pain Res.* 2018;11:1297-305. doi:10.2147/JPR.S158230.
7. Ni Choileain N, Redmond HP. Cell response to surgery. *Arch Surg.* 2006;141(11):1132-40. doi:10.1001/archsurg.141.11.1132.
8. Aghagoli G, Gallo Marin B, Soliman LB, Sellke FW. Cardiac involvement in COVID-19 patients: risk factors, predictors, and complications: a review. *J Card Surg.* 2020;35(6):1302-5. doi:10.1111/jocs.14538.
9. Rescigno G, Firstenberg M, Rudez I, Uddin M, Nagarajan K, Nikolaidis N. A case of postoperative Covid-19 infection after cardiac surgery: lessons learned. *Heart Surg Forum.* 2020;23(2):E231-3. doi:10.1532/hcf.3011.



This is an open-access article distributed under the terms of the Creative Commons Attribution License.