

## Case 3/2007

# Aortic coarctation: Aortoplasty with interposition of the left subclavian artery (the Teles Mendonça Technique)

*Coarctação de aorta: aortoplastia com interposição da artéria subclávia esquerda (Técnica de Teles Mendonça)*

Ulisses Alexandre CROTI, Domingo Marcolino BRAILE, Carlos Henrique DE MARCHI, Lílian BEANI

RBCCV 44205-897

## CLINICAL DATA

The case of a 47-day-old white male weighing 3695 g is reported. The child was prescribed furosemide, digoxin and captopril and referred to our service with a diagnosis of severe congenital heart disease. Since birth, he became tired during breastfeeding that evolved with tachydyspnea leading to hospitalization in the intensive care unit with a diagnosis of bronchopneumonia requiring mechanical ventilation. He was in a moderate general state, ruddy, hydrated and intubated. His thorax was symmetrical with *ictus cordis* palpable at the 4<sup>th</sup> left intercostal space. His heart rhythm was regular with two normal sounds and an ejective murmur +/6+ at the left sternal edge. Pulmonary auscultation identified bilateral coarse crackles. The abdomen was rounded; the liver was 4 cm from the right costal edge and there were fluid sounds. The pulses of the lower limbs were diminished; the arterial pressures of the arms were 130 x 50 mmHg and of the legs 40 x 20 mmHg. Oximetry of the pulse of the upper limbs was 90%.

## ELECTROCARDIOGRAM

An electrocardiogram showed a heart rate of 125 bpm, SÂP + 60°, PR interval of 0.16 s, QTc of 50 s, QRS of 0.08 s, with signs of left ventricular repolarization and right ventricular overload.

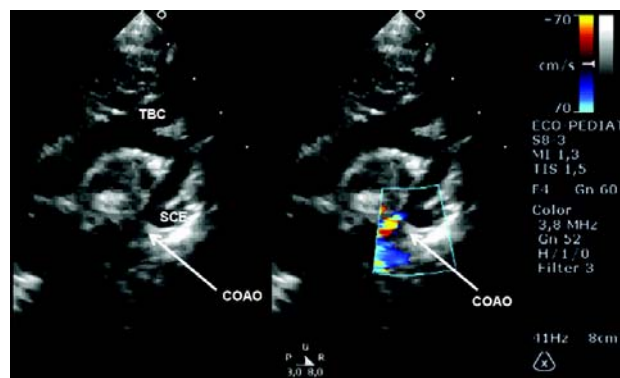


Fig. 1 - Preoperative echocardiogram. COAO: coarctation of the aorta; TBC: brachiocephalic trunk; SCE: Left subclavian artery

## RADIOGRAM

A radiogram demonstrated visceral *situs solitus* and a cardiothoracic ratio of 0.64 with prominence of the right chamber. The vascular network was increased and the diaphragm was free.

Pediatrics Cardiovascular Surgery Service of São José do Rio Preto – Hospital de Base – de Medicine School in São José do Rio Preto, SP.

Correspondence: Ulisses Alexandre Croti  
Hospital de Base – FAMERP – Avenida Brigadeiro Faria Lima, 5544  
CEP 15090-000 – São José do Rio Preto – São Paulo  
Phone (Fax): 17 - 3201 5025 / 3222 6450 / 9772 6560  
E-mail: uacroti@uol.com.br

Article received in Abril 19<sup>th</sup>, 2007  
Article accepted in May 16<sup>th</sup>, 2007

## ECHOCARDIOGRAM

An echocardiogram identified aortic coarctation with important hemodynamic repercussions; a gradient of 80 mmHg was located after the emergence of the left subclavian artery with an internal diameter of 1.7 mm; the diameter of the aorta was 5.1 mm (Figure 1). There was slight aortic valvar stenosis with a peak pressure of 29 mmHg. The *foramen ovale* was patent. The infant had slight pulmonary artery hypertension with a systolic pressure of 43 mmHg. The arterial channel was closed and there was a small pulmonary-systemic shunt from the descending aorta to the pulmonary artery.

## DIAGNOSIS

The clinical history and the physical examination were extremely suggestive of aortic coarctation which was confirmed by the echocardiographic findings that provided rich anatomical details. The clinical state and the start of organ failure stressed the urgency of the operation.

## OPERATION

Left lateral-posterior thoracotomy was performed with extensive dissection of the aortic arch, subclavian artery and the descending aorta providing ample mobilization. The arterial channel was ligated and sectioned (Figure 2). Crosswise sectioning of the aorta was performed above and below the coarcted section, the subclavian artery was sectioned, a lengthwise incision was made in the anterior aortic wall and posterior subclavian artery wall, End-to-end anastomosis was performed of the posterior aortic wall (Figure 3) and final construction with the left subclavian artery in "roof", enlarging the anterior region in the resected region and maintaining the blood flow to the left upper limb [1,2]. All the anastomoses were achieved using absorbable 6-0 polydioxanone threads with the aorta remaining without flow for 37 minutes due to the little experience with the technique, however no neurological lesions were reported. An echocardiogram after 45 days demonstrated the treated region with a residual gradient of 22 mmHg but without clinical implications and the infant is being followed up with periodic examinations as the technique provides a high potential of growth of the tissues and a low probability of restenosis.

## REFERENCES

1. Mendonça JT, Carvalho MR, Costa RK, Franco Filho E. Coarctation of the aorta: a new surgical technique. *J Thorac Cardiovasc Surg.* 1985;90(3):445-7.
2. Meier MA, Lucchese FA, Jazbik W, Nesralla IA, Mendonça JT. A new technique for repair of aortic coarctation. Subclavian flap aortoplasty with preservation of arterial blood flow to the left arm. *J Thorac Cardiovasc Surg.* 1986;92(6):1005-12.

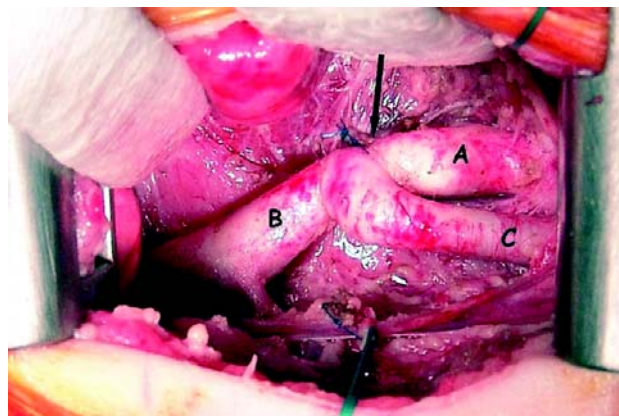


Fig. 2 - Initial aspect after dissection of the structures and ligation of the arterial channel. The coarcted region is indicated by the arrow; A: aortic arch; B: descending aorta; C: left subclavian artery

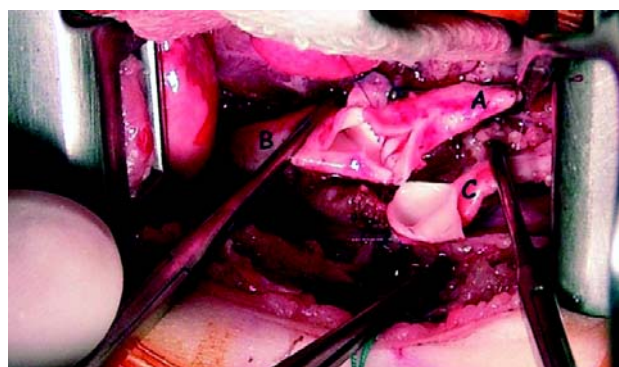


Fig. 3 - Posterior wall of the aorta at the end-to-end anastomosis. Lengthwise incision on the anterior wall of the aorta and posterior incision of the subclavian artery A: aortic arch; B: descending aorta; C: left subclavian artery

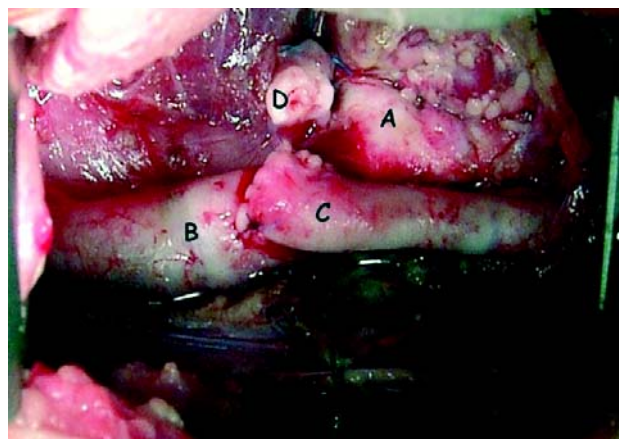


Fig. 4 - Final aspect A: aortic arch; B: descending aorta; C: left subclavian artery; D: remains of the coarcted region near the ligated arterial channel